CASE INFO

CLASS II

LARGE OVERJET

OPEN BITE

DOLICHO FACIAL

ORTHODONTIC CASE ANALYSIS REPORT

MALAK HASSAN, AHMED (BFNNDDJKL)

Female 13 years, 0 months

Recording date: 2026-04-11

WEBCEPH Free version

NOTES:

Eastman

1. SNA(Eastman)
2. SNB(Eastman)
3. ANB(Eastman)
4. SN to maxillary plane
5. Wits appraisal
6. U1 to maxillary plane angle
7. L1 to mandibular plane angle
8. Interincisal angle(Eastman)
9. Maxillary mandibular planes angle
10. Upper anterior face height
11. Lower anterior face height
12. Lower AFH ratio
13. L1 to A-Pog(Eastman)
14. Lower lip to E-plane(Eastman)
15. Nasolabial angle



WEBCEPH Free version

Standard

Patient

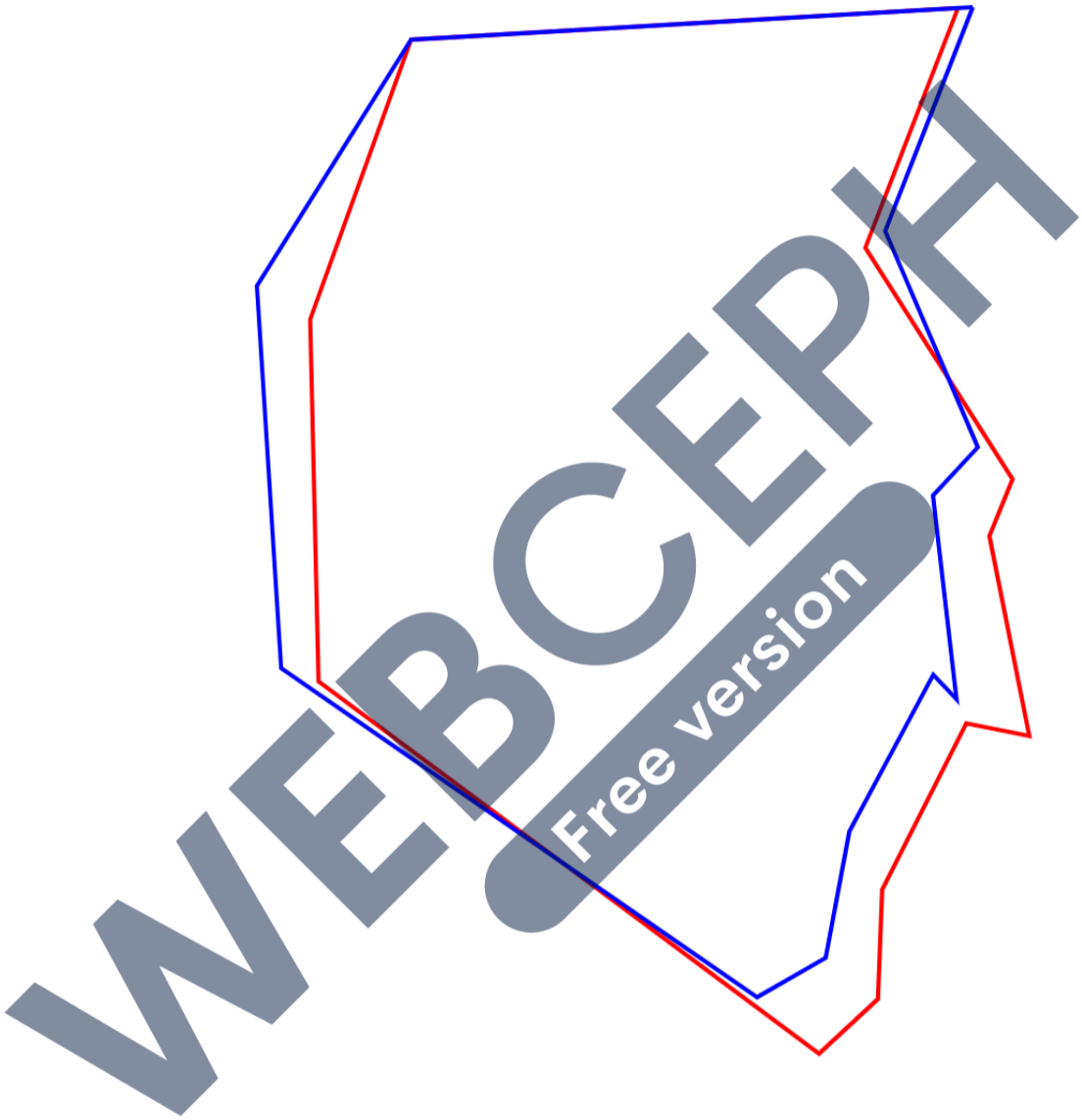

Eastman

	Mean	S.D.	Result	Severity	Polygonal chart	Meaning
SNA(Eastman)	82	3.0	90.1	**	70 75 80 85 90	Protruded maxilla
SNB(Eastman)	79	3.0	81.8		70 75 80 85 90	Normal mandible
ANB(Eastman)	3	1.0	8.3	***	-10 -5 0 5 10 15	Skeletal Class II
SN to maxillary plane	8	3.0	7.2		0 5 10 15 20	Normal Sn-MxPl angle
Wits appraisal	-0.3	3.0	2.7	*	-10 -5 0 5 10	Skeletal Class II
U1 to maxillary plane angle	108	5.0	115.9	*	100 105 110 115	Proclined upper incisor
L1 to mandibular plane angle	92	5.0	89.3		85 90 95 100	Normal lower incisor
Interincisal angle(Eastman)	133	10.0	122.9	*	125 130 135 140	Proclined interincisal angle
Maxillary mandibular planes angle	27	5.0	31.9		20 25 30 35	Normodivergent pattern
Upper anterior face height	54	5.0	53.1		45 50 55 60	Normal upper AFH
Lower anterior face height	65	5.0	66.7		55 60 65 70 75	Normal lower AFH
Lower AFH ratio	55	2.0	55.7		45 50 55 60 65	Normal Lower AFH
L1 to A-Pog(Eastman)	1	1.0	2.4	*	-10 -5 0 5 10 15	Protruded lower incisor
Lower lip to E-plane(Eastman)	-2	1.0	0.9	**	-15 -10 -5 0 5 10	Protruded lower lip
Nasolabial angle	95	5.0	98.6		85 90 95 100 105	Normal lip

WEBCEPH Free version

Problem List :

Save

Skeletal

Skeletal Class II (severe)

- Maxilla: Protrusion (severe)
- Mandible: Normal
- Chin point: Normal

Hyperdivergent(dolichocephalic) facial pattern (moderate)

Dental

Class I molar relationship

Overjet: Large overjet (moderate)

Overbite: Anterior openbite (mild)

Upper incisor inclination: Normal

Lower incisor inclination: Normal

Interincisal angle: Normal

Upper incisal display: Normal

Soft-tissue

Upper lip:Normal

Lower lip: Normal

Treatment Plan :

Save

WEBCEPH Free version

Note: This report was generated with WebCeph using Artificial Intelligence.
The contents in this report can not be considered a medical diagnosis and must be interpreted by the attending dentist.