Pregnancy: Diagnosis of DVT and PE

Objective:

To provide a diagnostic approach to the evaluation of pregnant patients with a clinical suspicion of deep vein thrombosis (DVT) or pulmonary embolism (PE).

Background:

Pregnancy is a well-established risk factor for venous thromboembolism (VTE). DVT complicates approximately 1 per 1,000 pregnancies, while PE complicates 0.5 per 1,000 pregnancies. VTE occurs in all trimesters of pregnancy and the postpartum period. The daily risk of VTE is increased 5- to 10-fold during pregnancy and 15- to 35-fold early after delivery compared to non-pregnant women of similar age. Although most studies have reported that the elevated risk of VTE returns to baseline by the end of the sixth postpartum week, there is evidence that a small residual increase in risk may persist for 12 weeks after delivery.

Signs and Symptoms of DVT and PE in Pregnancy:

The presentation of DVT in pregnancy differs from that in non-pregnant patients. The left leg is affected in >80% of cases and pregnant patients are much more likely to present with isolated iliac and/or femoral vein thrombosis, i.e. not arising by contiguous extension of a thrombus in the calf. These isolated iliofemoral thrombi often present with swelling of the entire leg with flank, buttock, or back pain rather than symptoms lower in the leg and carry a greater risk of post-thrombotic syndrome.

Symptoms that mimic VTE, such as leg swelling, groin discomfort, and dyspnea are common in normal pregnancy. Therefore, the majority of pregnant women investigated for VTE (>90%) will not have VTE. However, the suspicion of VTE must be increased in patients with unilateral leg swelling (particularly of the left leg), previous history of VTE, family history of VTE, high risk thrombophilia, bedrest for 7 days (especially with increased body mass index) or medical illness. Since the consequences of failing to diagnose VTE in pregnancy are significant, the threshold for investigating pregnant women with suspected DVT or PE must be low. In addition, the consequences of assuming VTE is present when it is not are also significant because: 1) prolonged anticoagulation throughout pregnancy is costly, requires daily subcutaneous injection, and complicates delivery, 2) VTE prophylaxis with LMWH would be recommended in subsequent pregnancies, and 3) combined oral contraceptives would be subsequently contraindicated. Therefore, the investigation of DVT and PE in pregnancy should accurately diagnose (or exclude) clinically significant VTE.

Investigative Strategies:

Although it has been shown that physicians are able to risk stratify pregnant women with suspected DVT using the LEFt rule (in which 1 point is provided for each of left leg symptoms, edema of affected leg with more than a 2 cm difference (between legs), and presentation in the first trimester of pregnancy), there have been no published management studies demonstrating the safety of using this rule alone or with D-dimer testing to exclude DVT in this patient population. A prospective validation of a diagnostic strategy to diagnose DVT during pregnancy using the LEFt rule is ongoing (NCT01708239). As a result, compression ultrasound is the first choice for investigation of DVT, as it is safe for mother and fetus and is readily available. Compression ultrasound should [illegible] proximal venous system, including the iliac veins, to rule out DVT. However, good visualizatior

with compression ultrasound can be limited in many pregnant women. A recent meta-analysis negative frequency of a single leg ultrasound with iliac imaging in pregnant women with suspe at less than 2%. However, the safety of performing only a single test has not been well validat management studies so additional testing (as outlined in Figure 1) is generally recommended if the initial ultrasound is negative.

Figure 1: Diagnosis of Suspected DVT in Pregnant Women

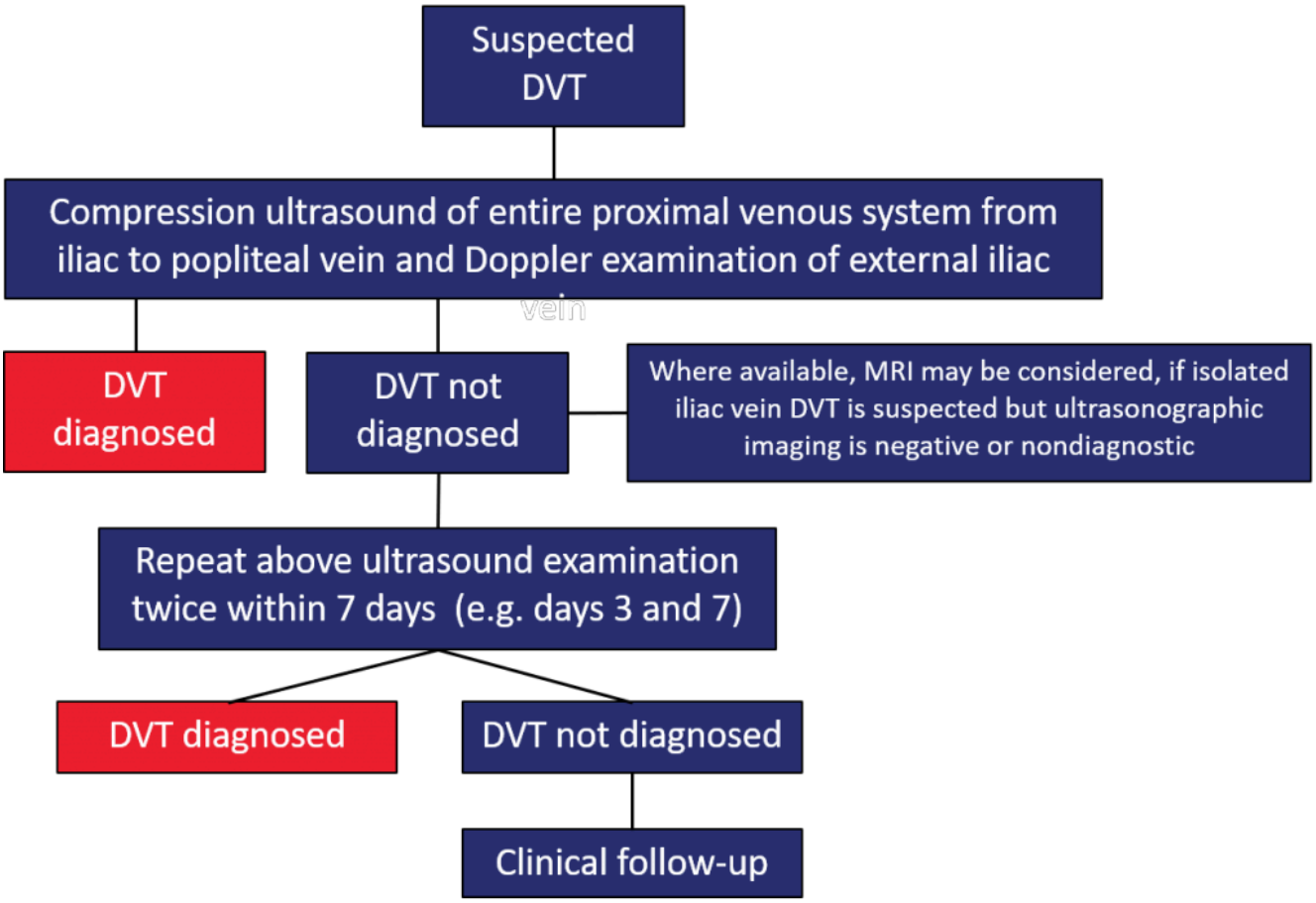

Adapted from Figure 1: Society of Obstetricians and Gynaecologists of Canada (SOGC) algorithm for investigation of suspected DVT in pregnant patients. Chan WS, et al. Venous thromboembolism and antithrombotic therapy in pregnancy: SOGC Clinical Practice Guideline. J Obstet Gynaecol Can 2014;36(6):527–553.

In patients in whom the iliac system cannot be visualized and in whom symptoms are suggestive of isolated iliac vein thrombosis - such as whole leg swelling, buttock, back, or flank pain - magnetic resonance imaging (MRI) should be considered, if available. Direct thrombus imaging (MRDTI), if available, eliminates the need for gadolinium. Alternatively, if MRI is not available, anticoagulation should be started and compression ultrasound repeated in 2 to 3 days; at that time, if the iliac veins are visualized and there is no evidence of DVT, anticoagulants can be stopped. MRI can be safely carried out in pregnant patients although the exact specificity and sensitivity of this technique is unclear.

Investigative Strategies for PE:

Two prospective diagnostic management outcome studies investigating diagnostic algorithms for diagnosis of PE during pregnancy have been published. Taken together, these studies suggest D-dimer measurement and pretest probability calculation can be used to safely direct investigation of pregnant patients with susp

recent study, the pregnancy-adapted YEARS protocol (see Figure 2), which was evaluated in
with suspected PE, is the best validated method for diagnosing and excluding PE in pregnanc
starts with performance of a sensitive D-dimer test and calculation of the YEARS score (3 iten
assigned for each: clinical signs of DVT, hemoptysis, PE as most likely diagnosis). All women with clinical signs of DVT (the first criterion on the YEARS score) should undergo a single leg ultrasound. If DVT is diagnosed, therapeutic anticoagulation is started and testing stopped. Patients with a negative ultrasound and those not requiring ultrasound are evaluated according to their YEARS criteria. The D-dimer threshold for excluding PE is dependent on the number of YEARS criteria satisfied. For patients with one or more positive criteria, the threshold for performance of radiologic testing is 500 ng/mL, while for those with no positive criteria, the threshold is 1000 ng/mL. In the validation study, the 3-month false negative rate for this protocol was 0.21% (95% confidence interval, 0.04 – 1.2%) and pulmonary diagnostic imaging was avoided in 39% of patients. The safety and effictiveness of this method has been externally validated in a retrospectives cohort of 371 patients.

Use of D-dimers in pregnancy has been discouraged as D-dimers increase through normal pregnancy with highest levels in the 3rd trimester. However, a systematic review and meta-analysis found D-dimers are highly sensitive to rule out VTE with a very high negative predictive value of 100% (95% confidence interval, 99.1 – 100.0%). This further supports its use in diagnostic algorithm as described above.

Figure 2: Diagnosis of Suspected PE in Pregnant Patients using the YEARS Protocol

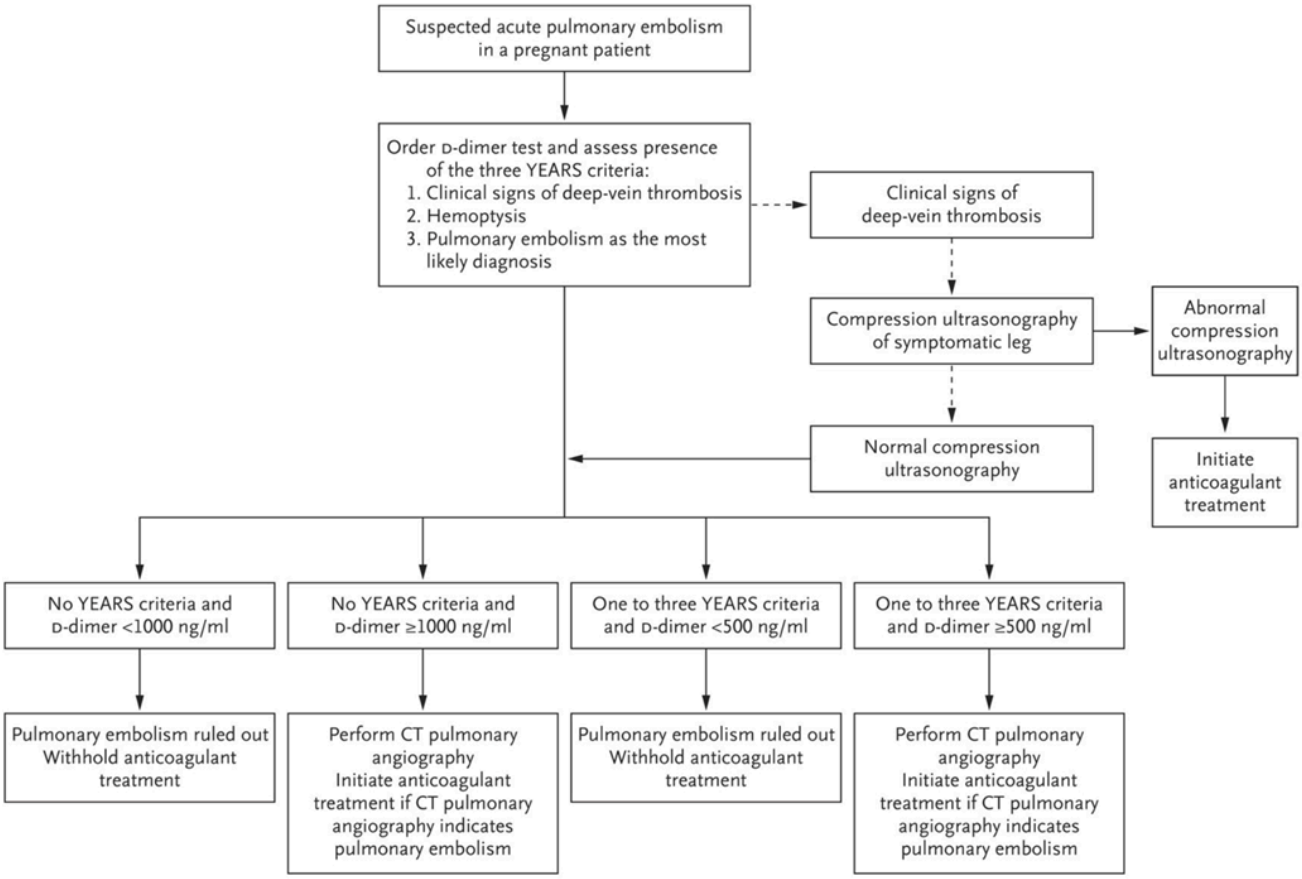

Reproduced with permission from https://www.nejm.org/doi/full/10.1056/NEJMoa1813865 (Van der Pol LM, et al. Pregnancy-Adapted YEARS Algorithm for Diagnosis of Suspected Pulmonary Embolism. N Engl J Med 2019;380:1139-1149).

Options for diagnostic imaging include ventilation/perfusion (V/Q) lung scan and computed tomographic pulmonary angiography (CTPA). The ranging average calculated radiation dose to the fetus with V/Q scan is 0.2-0.7 mGy and for CTPA is 0.002-0.51 mGy, well below the threshold of 50 mGy associated with increased ris

problems. However, the calculated minimum radiation dose to each breast for an average 60 k
significantly higher for CTPA (10 to 70 mGy, although that number can be reduced by approxin
use of bismuth breast shields) than for V/Q scan (<1.5 mGy, depending on technique), raising
of increased breast cancer risk in pregnant women exposed to CTPA. As a result, some physicians prefer V/Q scanning (especially in women with normal chest radiography), if available. Nevertheless, in a large population-based cohort study, exposure to either CTPA or V/Q scan during pregnancy or the postpartum period did not lead to a detectable short-term excess rishk of maternal breast cancer. In some centres, additional modifications of V/Q or CT techniques are available that can further reduce radiation exposure, so discussing with radiology and nuclear medicine can be helpful. Both CTPA and V/Q scan have a low false negative rage, and a similar non-diagnostic testing rate. The non-diagnostic CTPA testing rate, however, may be further reduced by using a specific protocol adapted to hemodynamic effects of pregnancy.

Investigation of suspected PE in pregnancy often creates anxiety in patients and physicians because of the radiation exposure to the mother and fetus. Clinical likelihood of PE, availability of timely imaging modalities, local expertise (ability to perform pregnancy-adapted CTPA) availability of V/Q, and patient preference should all be taken into consideration. It is essential that patients and physicians understand the risks and consequences of not pursuing imaging and that patients and physicians are accurately informed of the potential radiation risks to mother and fetus before decisions are made.

Special Considerations:

If DVT or PE is suspected in the postpartum period, the patient should be investigated as in non-pregnant patients, remembering that the pretest probability will be higher as this is the highest risk time for VTE in pregnant patients. CT scan is safe in breastfeeding; however, radioisotopes used in V/Q scanning may contaminate breastmilk for 24-48 hrs.

Other Relevant Guides:

- Deep Vein Thrombosis: Diagnosis
- Pregnancy: Thromboprophylaxis
- Pregnancy: Venous Thromboembolism Treatment
- Pulmonary Embolism: Diagnosis

s clinical guides remain current and reliable. Your support helps protect the quality and continuity of these resources for clinicians nationwide.

References:

Al Lawati K, et al. Ability of a single negative ultrasound to rule out deep vein thrombosis in pre
systematic review and meta-analysis. J Thromb Haemost 2020;18(2):373-380.

Bates SM, et al. American Society of Hematology 2018 guidelines for management of venous thromboembolism: venous thromboembolism in the context of pregnancy. Blood Adv 2018;2(22):3317-3359.

Bellesini M, et al. D-Dimer to rule out venous thromboembolism during pregnancy: a systematic review and meta-analysis. J Thromb Haemost 2021;00:1–14.

Burton KR, et al. Risk of early-onset breast cancer among women exposed to thoracic computed tomography in pregnancy or early postpartum. J Thromb Haemost. 2018;16(5):876-85.

Chan W, et al. Predicting deep venous thrombosis in pregnancy: out in “LEFt” field? Ann Intern Med 2009;151:85–92.

Chan WS, et al. Venous thromboembolism and antithrombotic therapy in pregnancy: SOGC Clinical Practice Guideline. J Obstet Gynaecol Can 2014;36(6):527–553.

Eddy M, et al. External validation of the YEARS diagnostic algorithm for suspected pulmonary embolism. J Thromb Haemostas 2020;(12):3289-3295.

Fraser DG, et al. Diagnosis of lower-limb deep venous thrombosis: a prospective blinded study of magnetic resonance direct thrombus imaging. Ann Intern Med 2002;136(2):89-98.

Langlois E, et al. Could the YEARS algorithm be used to exclude pulmonary embolism during pregnancy? Data from the CT-PE-pregnancy study. J Thromb Haemost. 2019;17(8):1329-34.

Middeldorp S,Ganzevoort W. How I treat venous thromboembolism in pregnancy. Blood 2020;136(19):2133-2142.

Radiation and Pregnancy: A Fact Sheet for Clinicians (2014)
https://emergency.cdc.gov/radiation/prenatalphysician.asp

Ridge CA, et al. Pulmonary CT angiography protocol adapted to the hemodynamic effects of pregnancy. AJR Am J Roentgenol. 2011;197(5):1058-63.

Righini M, et al. Predicting deep venous thrombosis in pregnancy: external validation of the LEFT clinical prediction rule. Haematologica 2013;98(4):545-548.

Righini M, et al. Diagnosis of pulmonary embolism during pregnancy: a multicenter prospective management outcome study. Ann Intern Med 2018;169(11):766-773.

Schembri GP, et al. Radiation dosimetry and safety issues in the investigation of pulmonary embolism. Sem Nucl Med 2011;40:442-454.

Tromeur C, et al. Computed tomography pulmonary angiography versus ventilation-perfusion lung scanning for diagnosing pulmonary embolism during pregnancy: a systematic review and meta-analysis. Haematologica. 2019;104(1):176-88.

Van der Pol LM, et al. Pregnancy-adapted YEARS algorithm for diagnosis of suspected pulmonary embolism. N Engl J Med 2019;380:1139-1149.

Date of version: 06January2026

Please note that the information contained herein is not to be interpreted as an alternative to medical advice from your doctor or other professional healthcare provider. If you have any specific questions about any medical matter, you should consult your doctor or other professional healthcare providers, and as such you should never delay seeking medical advice, disregard medical advice or discontinue medical treatment because of the information contained herein.