Automated Radiology Impression Generation Using a Fine-Tuned Medical Language Model

Multi-Agent Design, Fine-Tuning, and Evaluation Summary

Abstract

This report describes a medical NLP task focused on generating radiology impressions from free-text findings. We present a baseline model, a multi-agent scoring system, and a LoRA fine-tuning workflow. Quantitative results show improved n-gram overlap and recall-based similarity after fine-tuning, while qualitative analysis highlights where baseline outputs remain limited in differential diagnosis and management recommendations.

1. Multi-Agent Design and Baseline Performance

Task 1.1 – Baseline model. We used the pretrained `m42-health/Llama3-Med42-8B` model to generate impression lists from radiology findings. The baseline pipeline loads the findings, performs deterministic generation, and writes outputs to a CSV file with `case_id` and `generated_impression` fields.

Prompt strategy. The prompt explicitly requests a list of concise disease impressions, formal terminology, and no extra explanation. This improves consistency with the ground-truth format.

Task 1.2 – Multi-agent scoring. A second evaluation agent scores each generated impression across eight criteria on a 0–5 scale. Table 1 and Figure 1 summarize the average scores.

Criterion	Average score
Scientific terminology	4.15
Coherence	4.14
Specific diagnosis	3.71
Differential diagnosis	1.90
Management recommendations	1.34
Correctness	3.83
Comprehensiveness	3.69
Harmlessness / Bias	4.98

Table 1: Multi-agent evaluation of baseline impressions.

Interpretation. The baseline demonstrates strong terminology and safety, but weak differential diagnosis and management guidance, suggesting the model is competent at concise descriptions yet misses alternative explanations and follow-up recommendations.

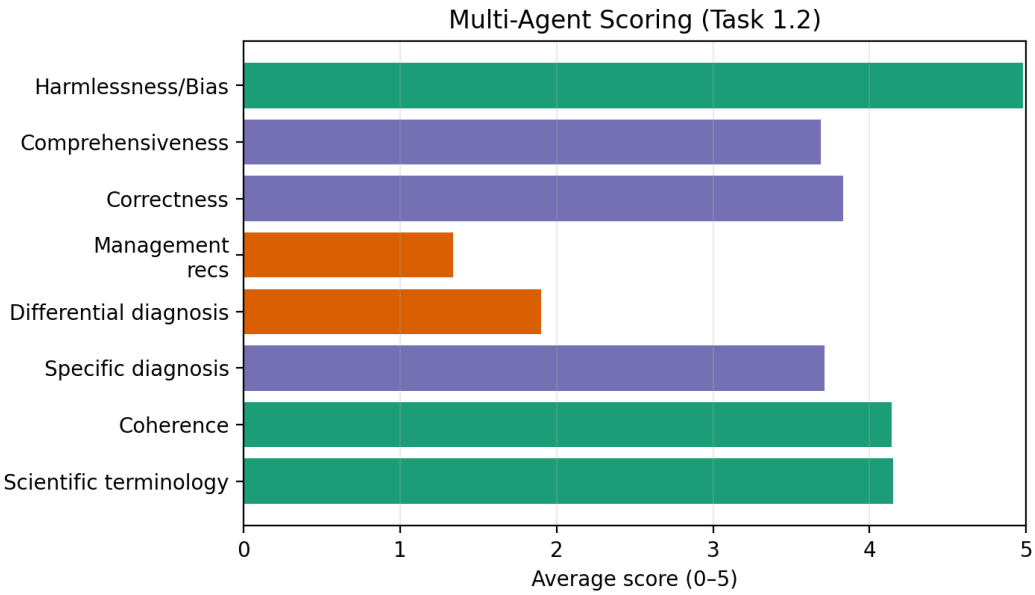

Figure 1: Baseline performance across eight evaluation criteria.

2. Task 2 – Fine-Tuning Methodology

Baseline vs. fine-tuned. We compared the baseline model to a LoRA fine-tuned version. LoRA updates a small subset of attention weights, enabling efficient adaptation.

Training setup	Value
Epochs	7
Learning rate	1×10^{-5}
Batch size	8
LoRA rank r	8
LoRA α	16
Dropout	0.1
Target modules	`q_proj, k_proj, v_proj, o_proj`

Table 2: Fine-tuning configuration.

Evaluation metrics (380 test samples). Table 3 and Figure 2 show improvements across EM, BLEU, and ROUGE.

Qualitative comparison. The fine-tuned model produces longer, more complete impressions and includes occasional management suggestions. This aligns with the higher ROUGE metrics.

Model	EM	BLEU	ROUGE-1	ROUGE-2	ROUGE-L
Baseline	0.000	0.0456	0.1895	0.0900	0.1770
Fine-tuned	0.026	0.1420	0.4650	0.2590	0.4520

Table 3: Quantitative comparison of baseline and fine-tuned models.

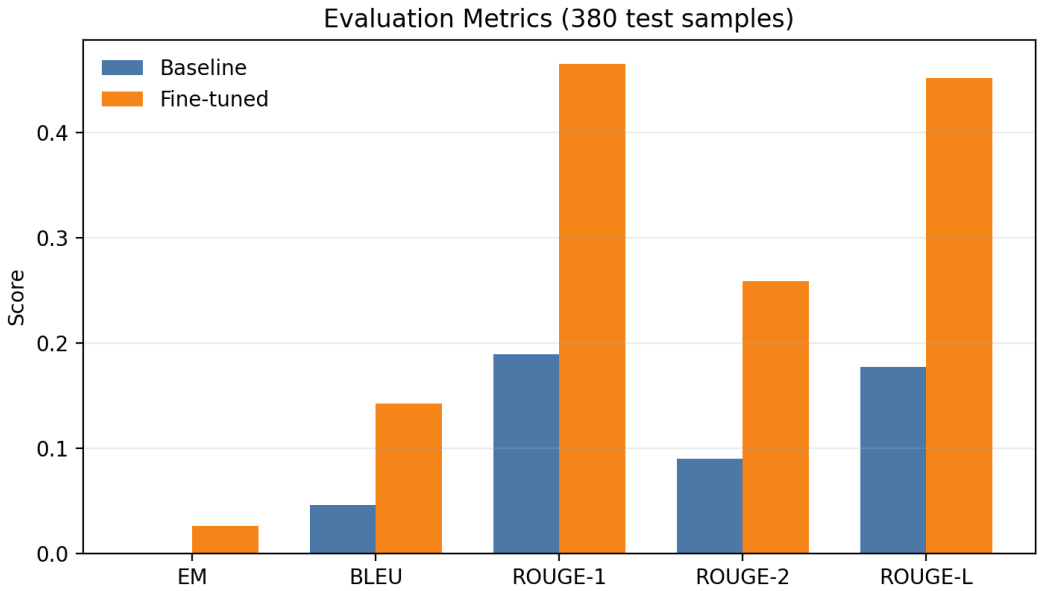

Figure 2: Baseline vs. fine-tuned evaluation metrics.

3. Failure Mode Analysis

Degenerate outputs. Early experiments produced outputs such as "!!!!!". Root cause analysis traced this to incorrectly masked labels and occasional NaN losses. Fixes included correct masking of prompt/padding tokens, skipping invalid batches, and deterministic decoding with a mild repetition penalty. After fixes, generation stabilized and produced clinically plausible impressions.

4. Example Outputs

5. AI-Assisted Workflow

AI assistance supported coding (baseline pipeline scaffolding), debugging (identifying degenerate output causes), and report drafting (summarizing metrics and comparing models). This reduced time spent on repetitive tasks and improved clarity of the final report.

Input findings	Baseline impression	Fine-tuned impression
Stone in distal right ureter with right ureteral and renal hydronephrosis.	Normal liver parenchyma with no evidence of intrahepatic or extrahepatic bile duct dilation.	Normal abdominal CT scan.
Fatty liver; hepatic calcification; multiple cysts in bilateral kidneys possible; appendicitis.	Multiple renal lesions, likely benign, need further evaluation.	Multiple renal lesions likely benign; thickened intestinal wall and appendix, possible inflammatory changes; liver nodule needs evaluation; recommend CT/US/MRI as appropriate.

Table 4: Example outputs illustrating concise baseline text and more comprehensive fine-tuned responses.

Summary

- The baseline model is strong in terminology and harmlessness but weak in differential diagnosis and management guidance.
- LoRA fine-tuning substantially improves BLEU and ROUGE, indicating closer alignment with reference impressions.
- Correct label masking and deterministic decoding eliminate degenerate outputs.
- AI assistance accelerates coding, debugging, and report composition.