Asian Journal of Cardiology Research

Volume 9, Issue 1, Page 1-7, 2026; Article no.AJCR.150336

The Silent Ventricle: Late Diagnosis of Single Ventricle in an Asymptomatic 50-Year-Old Man

O. Taoussi [a*], H. Rabii [a], H. Kamri [a], Z. Azeddoug [a], M. Mokhtari [a], FZ. Merzouk [a] and G. Benouna [a]

[a] *Department of Cardiology, Cheikh Khalifa International University Hospital, Mohammed VI University of Health Sciences, Mohammed VI Foundation of Health Sciences, Casablanca, Morocco.*

Authors' contributions

This work was carried out in collaboration among all authors. Author OT collected all clinical and imaging data, performed the literature review, and wrote the first draft of the manuscript. Authors OT, HR, HK, ZA, MM, and FZM evaluated the patient, conducted the clinical assessment, and contributed to case management as members of the cardiology team. All authors read and approved the final manuscript.

Article Information

DOI: https://doi.org/10.9734/ajcr/2026/v9i1345

Open Peer Review History:
This journal follows the Advanced Open Peer Review policy. Identity of the Reviewers, Editor(s) and additional Reviewers, peer review comments, different versions of the manuscript, comments of the editors, etc are available here: https://pr.sdiarticle5.com/review-history/150336

Case Report

Received: 26/10/2025
Published: 03/01/2026

Abstract

Aims: To report an exceptional case of a previously undiagnosed single ventricle congenital heart disease presenting in the fifth decade of life, and to discuss the challenges of late diagnosis in the context of established, inoperable pulmonary hypertension.
Introduction: Single ventricle physiology represents a complex spectrum of congenital heart diseases typically diagnosed and palliated in infancy. Survival into adulthood without prior surgical intervention is exceedingly rare and poses unique diagnostic and management challenges, often complicated by irreversible pulmonary vascular disease.

**Corresponding author: Email: taoussi75@gmail.com;*

Cite as: *O. Taoussi, H. Rabii, H. Kamri, Z. Azeddoug, M. Mokhtari, FZ. Merzouk, and G. Benouna. 2026. "The Silent Ventricle: Late Diagnosis of Single Ventricle in an Asymptomatic 50-Year-Old Man". Asian Journal of Cardiology Research 9 (1):1–7. https://doi.org/10.9734/ajcr/2026/v9i1345.*

Case Presentation: A 50-year-old man with no prior medical history presented to the emergency department with acute-onset dyspnea and cyanosis. He was a father of four and had been gainfully employed without functional limitation. Electrocardiography revealed atrial flutter. Echocardiography and subsequent advanced imaging diagnosed a complex single ventricle anomaly (likely a double-inlet left ventricle with transposition) with severe, fixed pulmonary hypertension. Despite medical management of acute heart failure, he was deemed ineligible for surgical palliation due to advanced pulmonary vascular disease and was discharged on guideline-directed medical therapy and anticoagulation.

Discussion: This case underscores a profound failure of the healthcare system, where a life-threatening congenital anomaly remained undetected for five decades. The patient's remarkable adaptation and compensation highlight the body's physiological reserve, but also mask a condition where timely, childhood surgical intervention (e.g., Fontan procedure) could have offered a survival pathway. The development of irreversible pulmonary hypertension is the direct consequence of delayed diagnosis, transforming a potentially palliable condition into an inoperable one. This emphasizes the critical, non-negotiable importance of neonatal and childhood cardiac screening.

Conclusion: The asymptomatic survival of an adult with unoperated single ventricle physiology is a medical curiosity that carries a sobering message. It serves as a powerful reminder that the window for successful surgical palliation in complex congenital heart disease is often narrow and defined by the status of the pulmonary vasculature. Early diagnosis is not merely beneficial—it is a prerequisite for curative or palliative surgical strategy.

Keywords: Single ventricle; congenital heart disease; late diagnosis; pulmonary hypertension; Fontan; Eisenmenger syndrome.

Abbreviations

CHD : Congenital Heart Disease
ECG : Electrocardiogram
EF : Ejection Fraction
ICU : Intensive Care Unit
MRI : Magnetic Resonance Imaging
NYHA: New York Heart Association
PAH : Pulmonary Arterial Hypertension
RV : Right Ventricle
SV : Single Ventricle
TTE : Transthoracic Echocardiography
VSD: Ventricular Septal Defect

1. Introduction

Single-ventricle physiology is among the most complex forms of congenital heart disease, in which the heart relies on a single ventricular chamber to support both systemic and pulmonary circulations. In contemporary practice, these conditions are typically diagnosed in infancy, with most patients undergoing staged surgical palliation beginning in the first few months of life (Gewillig & Brown, 2016). Survival into adulthood without surgical intervention is exceptionally uncommon, with most untreated patients succumbing in childhood from progressive cyanosis, heart failure, or complications of pulmonary hypertension (Moodie et al., 1984).

When diagnosis occurs in adulthood, it often presents with advanced complications, including irreversible pulmonary vascular disease, arrhythmias, and ventricular dysfunction, which significantly limit therapeutic options (Khairy et al., 2007). The transition from a potentially surgically palliable condition to one managed medically represents a critical missed opportunity in the patient's clinical course. This report describes a remarkable case of a 50-year-old man with previously undiagnosed single ventricle physiology who presented with acute decompensated heart failure, highlighting the challenges of late diagnosis and the importance of early detection in congenital heart disease.

2. Case Presentation

A 50-year-old man with no known medical history presented to the emergency department with acute-onset dyspnea at rest and progressive cyanosis. Despite his previous lack of symptoms, he had maintained full-time employment as an office administrator and was a father of four healthy children. He denied any prior cardiac symptoms.

On admission, physical examination revealed central and peripheral cyanosis, elevated jugular venous pressure, a loud single second heart sound, and a pansystolic murmur. Bilateral lower extremity edema and hepatomegaly were present. Oxygen saturation on room air was 82%, confirming significant hypoxemia.

A 12-lead electrocardiogram demonstrated a regular, non-sinus rhythm consistent with atrial

tachyarrhythmia compatible with atrial flutter (atrial rate approximately 180 bpm with a variable ventricular response), associated with widespread deep T-wave inversions and widened QRS complexes (Fig. 1).

Transthoracic echocardiography revealed a complex single ventricle anatomy with two separate atrioventricular valves opening into a single, dominant ventricular chamber. Apical and two-chamber views demonstrated the single ventricle, moderate systolic dysfunction, and the presence of two distinct atrioventricular valves (Figs. 2 and 3).

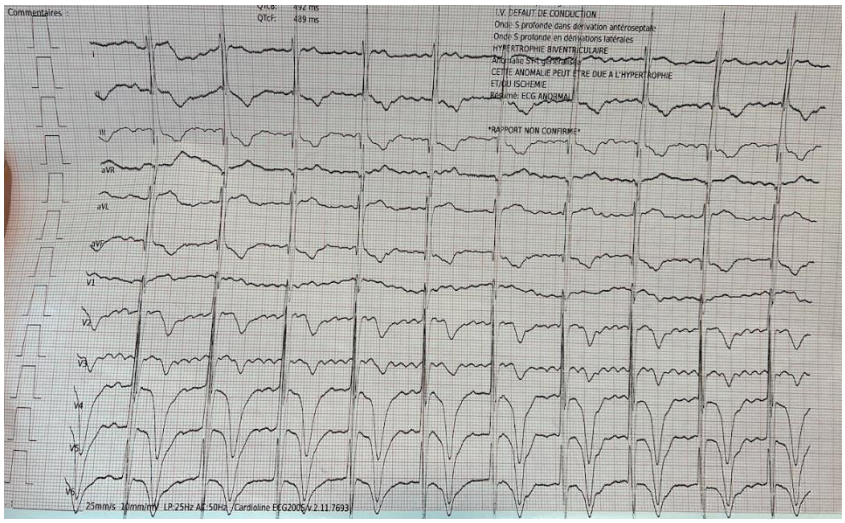

Fig. 1. Admission electrocardiogram: resting 12-lead ECG showing a regular, non-sinus rhythm consistent with atrial flutter with widespread deep T-wave inversions and widened QRS complexes

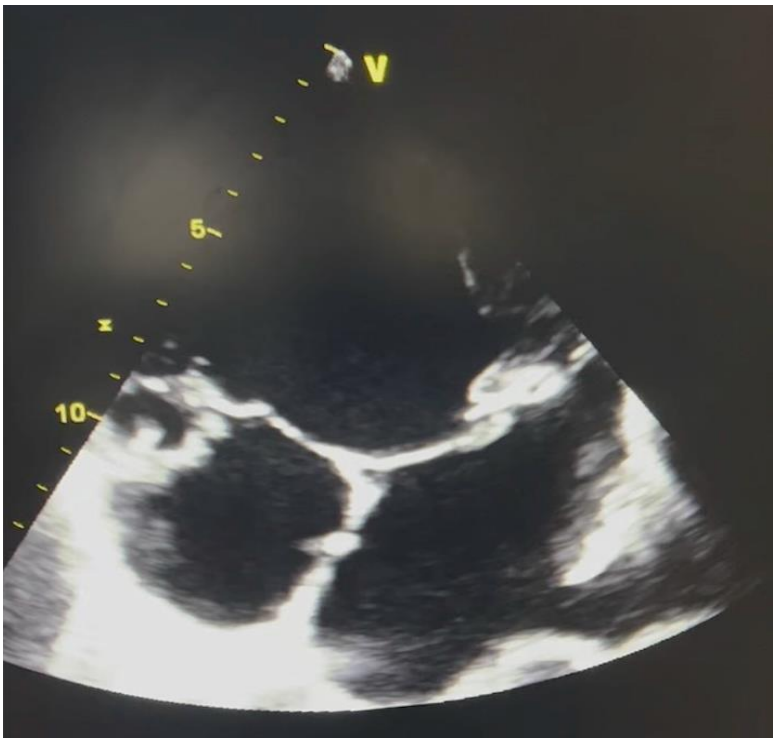

Fig. 2. Transthoracic Echocardiography: ***Apical view demonstrating the single ventricular chamber with severe dilation and trabeculated morphology consistent with double inlet left ventricle anatomy***

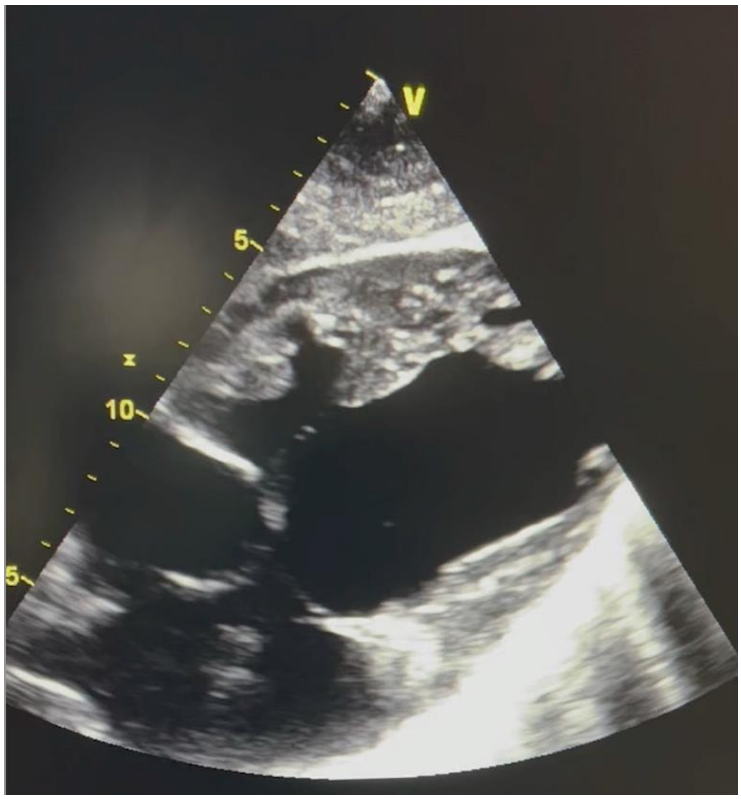

Fig. 3. Transthoracic Echocardiography: ***Two-chamber view further illustrating the trabeculated single ventricular morphology, absence of a developed second ventricle***

The anatomy showed an absent second ventricle, with both atrioventricular valves opening into the main ventricular chamber and a significant ventricular septal defect. Doppler evaluation estimated severe pulmonary hypertension with a systolic pulmonary artery pressure of 85 mmHg.

Cardiac magnetic resonance imaging confirmed the anatomical diagnosis and quantified ventricular function (systemic ventricular ejection fraction 35%) while demonstrating severely elevated, fixed pulmonary vascular resistance on subsequent catheterization.

The patient was admitted to the cardiac intensive care unit, where acute heart failure was managed with intravenous diuretics. Given the fixed, irreversible pulmonary hypertension (Eisenmenger physiology) confirmed by non-reactive vasodilator testing, he was deemed not a candidate for surgical intervention. After stabilization, he was discharged on guideline-directed medical therapy, including diuretics, oral anticoagulation with a vitamin K antagonist (warfarin), and referral to a specialized adult congenital heart disease center.

3. Discussion

This exceptional case of a 50-year-old man with previously undiagnosed single-ventricle physiology, presenting with double-inlet morphology and two distinct atrioventricular valves, provides a stark illustration of both remarkable physiological adaptation and a critical failure in the healthcare system. Survival to middle age without surgical palliation is exceedingly rare, with historical data and a recent systematic review confirming that long-term survival without intervention is exceptional and is associated with a significantly altered natural history (Moodie et al., 1984). The patient's prolonged asymptomatic period likely resulted from a uniquely balanced circulation, in which pulmonary blood flow was sufficient to prevent severe cyanosis yet sufficiently restricted to protect the pulmonary vasculature from early hypertensive damage—a precarious equilibrium possibly maintained by dynamic sub pulmonary obstruction or collateral vessels (Gewillig et al., 2010). However, this delicate balance inevitably fails, leading to the classic triad of cyanosis, ventricular dysfunction, and pulmonary hypertension that precipitated his acute presentation.

The central and irreversible complication in this case is the development of fixed pulmonary vascular disease. In single ventricle physiology, the pulmonary vasculature is chronically exposed to systemic pressures, leading to progressive arteriopathy. The non-reactive, severely elevated pulmonary vascular resistance confirmed by catheterization in this patient represents the point of no return, permanently contraindicating surgical palliation strategies like the Fontan procedure (Khairy et al., 2007). This transition from a potentially operable condition in childhood to an inoperable state in adulthood is the most devastating consequence of delayed diagnosis, transforming management from proactive surgical staging to reactive, palliative medical care focused solely on symptom control and complication prevention (Brida & Gatzoulis, 2019).

This case underscores persistent deficiencies in the early detection of congenital heart disease. While dramatic presentations are identified in infancy, subtler forms with balanced physiology can evade diagnosis without systematic screening. Although universal neonatal pulse oximetry screening has improved detection rates for critical congenital heart disease, as evidenced by national studies, cases such as this one, with initially compensated physiology, may still be missed, underscoring the need for continued vigilance and awareness across all healthcare encounters in childhood (Peterson et al., 2014, Mery et al., 2019).

For this patient and others with inoperable single ventricle physiology and established Eisenmenger syndrome, management is complex and palliative. It requires a multidisciplinary approach focused on optimizing quality of life through diuretics for volume management, anticoagulation to mitigate high thromboembolic risk, and careful arrhythmia control (Stout et al., 2019). Equally critical are the profound psychosocial implications of a late diagnosis. Patients must navigate a sudden identity shift from perceiving themselves as healthy to managing a severe, chronic illness, affecting employment, family dynamics, and mental health, thus necessitating integrated psychological and social support services (Kovacs et al., 2009). In addition, patients with single ventricle physiology and Eisenmenger syndrome are at increased risk of sudden cardiac death, driven by ventricular arrhythmias, atrial tachyarrhythmias, chronic hypoxemia, and progressive myocardial fibrosis. The presence of atrial arrhythmia at presentation in our patient further underscores this risk. Although preventive strategies are limited, close rhythm surveillance and follow-up in specialized adult congenital heart disease centers are essential to mitigate the risk of sudden cardiac death.

Renal impairment represents another major prognostic determinant in cyanotic congenital heart disease. Chronic hypoxemia, reduced renal perfusion, venous congestion, and secondary erythrocytosis contribute to progressive renal dysfunction, which has been strongly associated with increased morbidity and mortality in patients with Eisenmenger physiology **(**Buelow et al., 2015). Regular monitoring of renal function is therefore a critical component of long-term management.

Long-term follow-up of patients with inoperable single-ventricle physiology should be conducted at specialized adult congenital heart disease centers, which are best equipped to address the multifaceted care gaps and care fragmentation identified in this vulnerable population (Gurvitz et al., 2013; Gewillig et al., 2025; Khan et al., 2021). Follow-up strategies include surveillance of ventricular function, arrhythmia burden, thromboembolic risk, renal function, and psychosocial well-being.

Ultimately, this case serves as a powerful reminder that in congenital heart disease, time is vascular tissue; early diagnosis is not merely advantageous but is the fundamental determinant that separates a path toward surgical palliation from a destiny of managing irreversible complications.

4. Conclusion

The diagnosis of single ventricle physiology in a 50-year-old man represents both a medical curiosity and a systems failure. While his survival to adulthood demonstrates remarkable physiological adaptation, his presentation with irreversible complications underscores the critical importance of early diagnosis in congenital heart disease. This case serves as a potent reminder that congenital heart disease may remain silent for decades before presenting with advanced, inoperable complications. It reinforces the need for vigilant screening in infancy and childhood, as timely identification remains the single most crucial factor determining long-term outcomes in patients with complex congenital heart defects. For those diagnosed late, comprehensive care in

specialized centers is the most effective approach to managing their complex medical and psychosocial needs.

Consent

All authors declare that written informed consent was obtained from the patient for publication of this case report and the accompanying images.

Ethical Approval

As per international standards or university standards written ethical approval has been collected and preserved by the author(s).

Disclaimer (Artificial Intelligence)

The authors hereby declare that no generative artificial intelligence tools (ChatGPT, Copilot, etc.) were used in the writing, editing, or production of this manuscript.

Acknowledgements

The authors would like to thank the cardiology teams at Cheikh Khalifa International University Hospital for their assistance. The authors also acknowledge the contributions of the cardiology department staff for their support in the patient's clinical evaluation and management.

Competing Interests

Authors have declared that no competing interests exist.

References

Brida, M., & Gatzoulis, M. A. (2019). Adult congenital heart disease: Past, present, and future. *Acta Paediatrica, 108*(10), 1757–1764. https://doi.org/10.1111/apa.14921

Gewillig, M., & Brown, S. C. (2016). The Fontan circulation after 45 years: Update in physiology. *Heart, 102*(14), 1081–1086. https://doi.org/10.1136/heartjnl-2015-307467

Gewillig, M., Brown, S. C., Heying, R., Eyskens, B., Ganame, J., Boshoff, D. E., Budts, W., & Gorenflo, M. (2010). Volume load paradox in Fontan preparation: Not too much for the ventricle, not too little for the lungs. *Interactive Cardiovascular and Thoracic Surgery, 10*(2), 262–265. https://doi.org/10.1510/icvts.2009.218586

Gurvitz, M., Valente, A. M., Broberg, C., Cook, S., Stout, K., Kay, J., Ting, J., Kuehl, K., Earing, M., Webb, G., Houser, L., Opotowsky, A., Harmon, A., Graham, D., Khairy, P., Gianola, A., Verstappen, A., & Landzberg, M.; Alliance for Adult Research in Congenital Cardiology (AARCC) and Adult Congenital Heart Association. (2013). Prevalence and predictors of gaps in care among adult congenital heart disease patients: HEART-ACHD (The Health, Education, and Access Research Trial). *Journal of the American College of Cardiology, 61*(21), 2180–2184. https://doi.org/10.1016/j.jacc.2013.02.048

Marc Gewillig, Thomas Salaets, Alexander Van de Bruaene, Stephen C Brown. Fontan Circulation: How a Model can Hinder or Help to Understand and Manage a Complex Problem. J Surg Res 2025 DOI:10.26502/jsr.10020428 (2025): 123-127.

Khairy, P., Poirier, N., & Mercier, L. A. (2007). Univentricular heart. *Circulation, 115*(6), 800–812. https://doi.org/10.1161/CIRCULATIONAHA.105.592378

Khan, A. M., McGrath, L. B., Ramsey, K., Agarwal, A., & Broberg, C. S. (2021). Association of adults with congenital heart disease–specific care with clinical characteristics and healthcare use. *Journal of the American Heart Association, 10*(11), e019598. https://doi.org/10.1161/JAHA.120.019598

Kovacs, A. H., Saidi, A. S., Kuhl, E. A., Sears, S. F., Silversides, C., Harrison, J. L., Ong, L., Colman, J., Oechslin, E., & Nolan, R. P. (2009). Depression and anxiety in adult congenital heart disease: Predictors and prevalence. *International Journal of Cardiology, 137*(2), 158–164. https://doi.org/10.1016/j.ijcard.2008.06.042

Buelow, M. W., Cohen, S. B., & Earing, M. G. Renal dysfunction in adults with congenital heart disease. *Progress in Pediatric Cardiology*. https://doi.org/10.1016/j.ppedcard.2015.11.003

Mery, C. M., De León, L. E., Trujillo-Diaz, D., Ocampo, E. C., Dickerson, H. A., Zhu, H., Adachi, I., Heinle, J. S., Fraser, C. D., Jr., & Ermis, P. R. (2019). Contemporary outcomes of the Fontan operation: A large single-institution cohort. *The Annals of Thoracic Surgery, 108*(5), 1439–1446.

https://doi.org/10.1016/j.athoracsur.2019.05.039

Moodie, D. S., Ritter, D. G., Tajik, A. J., & O'Fallon, W. M. (1984). Long-term follow-up in the unoperated univentricular heart. *American Journal of Cardiology, 53*(8), 1124–1128. https://doi.org/10.1016/0002-9149(84)90648-9

Peterson, C., Ailes, E., Riehle-Colarusso, T., Oster, M. E., Olney, R. S., Cassell, C. H., Fixler, D. E., Carmichael, S. L., Shaw, G. M., & Gilboa, S. M. (2014). Late detection of critical congenital heart disease among US infants: Estimation of the potential impact of proposed universal screening using pulse oximetry. *JAMA Pediatrics, 168*(4), 361–370. https://doi.org/10.1001/jamapediatrics.2013.4779

Stout, K. K., Daniels, C. J., Aboulhosn, J. A., Bozkurt, B., Broberg, C. S., Colman, J. M., Crumb, S. R., Dearani, J. A., Fuller, S., Gurvitz, M., Khairy, P., Landzberg, M. J., Saidi, A., Valente, A. M., & Van Hare, G. F. (2019). 2018 AHA/ACC guideline for the management of adults with congenital heart disease: A report of the American College of Cardiology/American Heart Association Task Force on Clinical Practice Guidelines. *Circulation, 139*(14), e698–e800. https://doi.org/10.1161/CIR.0000000000000603

Disclaimer/Publisher's Note: The statements, opinions and data contained in all publications are solely those of the individual author(s) and contributor(s) and not of the publisher and/or the editor(s). This publisher and/or the editor(s) disclaim responsibility for any injury to people or property resulting from any ideas, methods, instructions or products referred to in the content.

© Copyright (2026): Author(s). The licensee is the journal publisher. This is an Open Access article distributed under the terms of the Creative Commons Attribution License (http://creativecommons.org/licenses/by/4.0), which permits unrestricted use, distribution, and reproduction in any medium, provided the original work is properly cited.

Peer-review history:
The peer review history for this paper can be accessed here:
https://pr.sdiarticle5.com/review-history/150336