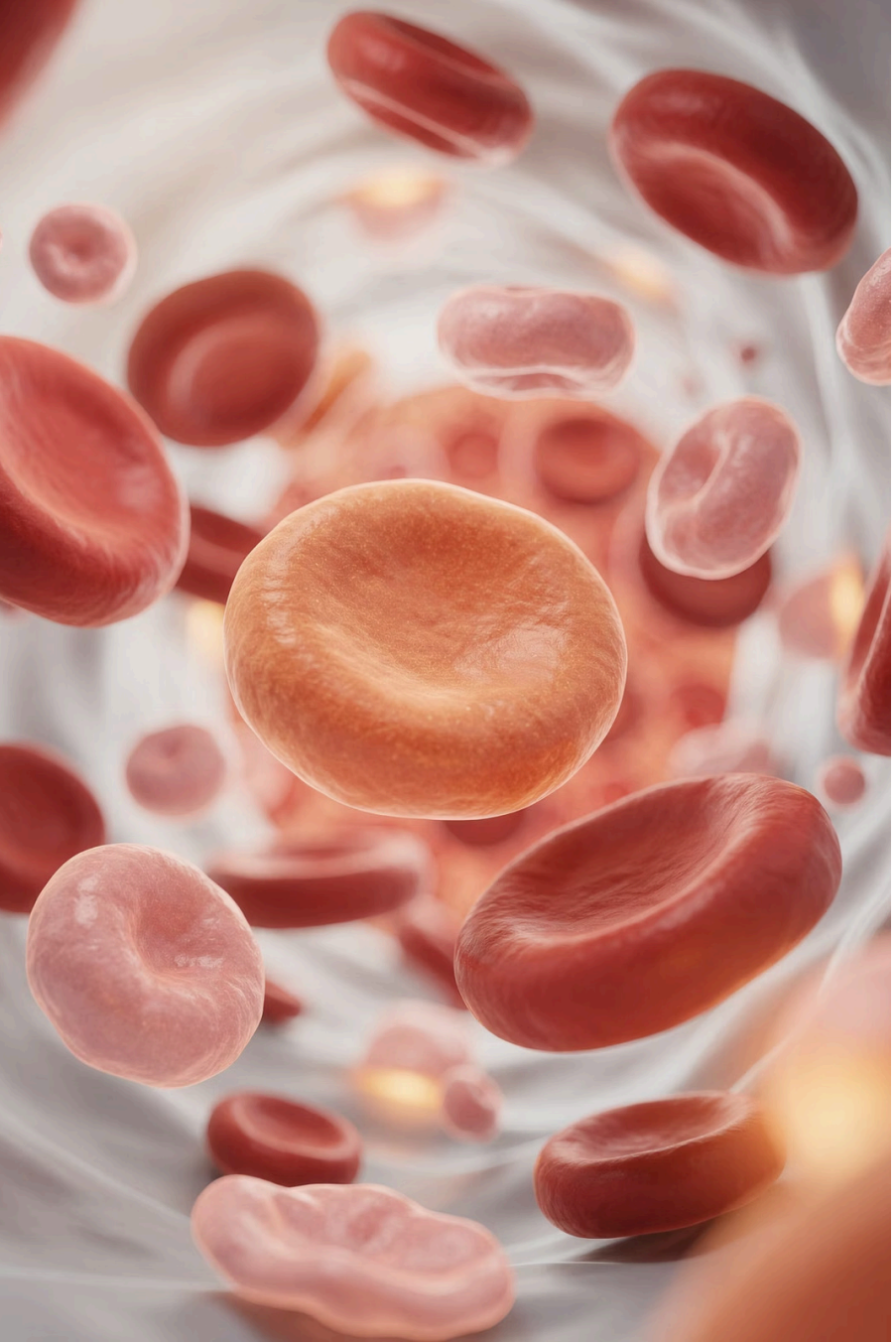

Hypochromic Microcytic Anemia: Understanding Causes, Diagnosis & Iron Metabolism

A comprehensive guide to understanding the pathophysiology, differential diagnosis, and clinical management of microcytic anemias

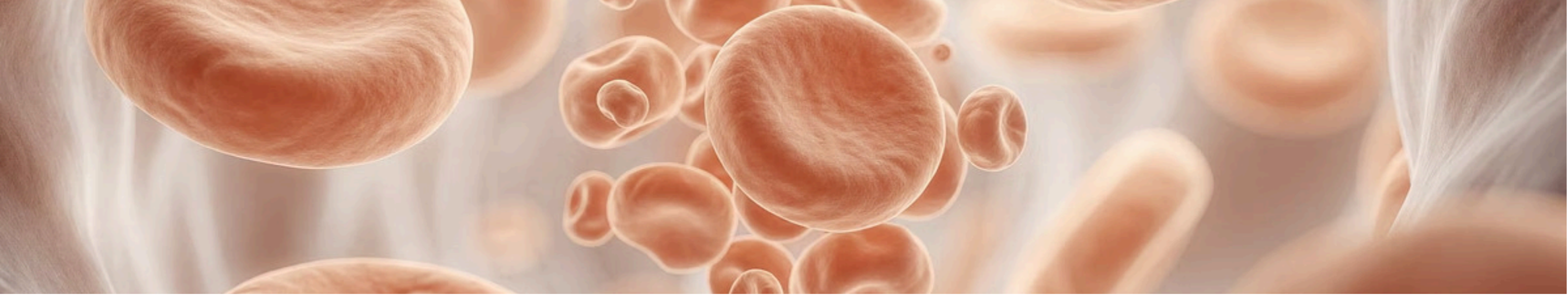

What is Hypochromic Microcytic Anemia?

Clinical Impact

Reduction in the rate of synthesis of hemoglobin which result from the reduction in the rate of synthesis of haem or globin. This will lead to less O2 reaching to tissues throughout the body, resulting in characteristic symptoms including:

- Persistent fatigue and weakness
- Pallor of skin and mucous membranes
- Shortness of breath with exertion
- Decreased exercise tolerance

Key Characteristics

Hypochromic microcytic anemia is defined by red blood cells that are both smaller (microcytic) and paler (hypochromic) than normal. These changes reflect impaired hemoglobin synthesis within the developing red blood cells.

The underlying cause typically involves either insufficient iron availability for heme production or genetic defects affecting globin chain synthesis.

Differential Diagnosis of Hypochromic Microcytic Anemia

1

Iron Deficiency Anemia

The most common cause worldwide. Laboratory findings include low serum ferritin (depleted stores), low serum iron, and elevated total iron-binding capacity (TIBC) reflecting increased transferrin production.

2

Thalassemia

Inherited genetic disorders affecting globin chain synthesis. Distinguished by normal or elevated serum iron levels, family history, and characteristic hemoglobin electrophoresis patterns.

3

Anemia of Chronic Disease

Inflammatory conditions cause iron sequestration within the reticuloendothelial system. Features low serum iron despite normal or elevated ferritin stores.

4

Sideroblastic Anemia

Defective heme synthesis results in characteristic ring sideroblasts—erythroblasts with iron-loaded mitochondria forming rings around the nucleus visible on bone marrow examination.

Main Dietary Sources of Iron

Heme Iron Sources

Highly bioavailable iron absorbed at 15-35% efficiency. Found exclusively in animal products including red meat, poultry, fish, and organ meats. This form doesn't require reduction and is less affected by dietary inhibitors.

Non-Heme Iron Sources

Absorbed at only 2-20% efficiency. Present in plant-based foods such as legumes, dark leafy greens like spinach, fortified breakfast cereals, nuts, seeds, and dried fruits. Requires more careful dietary planning.

Absorption Enhancement: Vitamin C-rich foods (citrus, tomatoes, peppers) can increase non-heme iron absorption up to 3-fold. Conversely, calcium in dairy products, tannins in tea/coffee, and phytates in whole grains inhibit absorption.

Site and Mechanism of Iron Absorption

Primary Absorption Site

Iron absorption occurs predominantly in the **duodenum and proximal jejunum**, where specialized enterocytes equipped with iron transport machinery line the intestinal wall.

01

Iron Reduction

Non-heme iron must be reduced from the ferric (Fe^{3+}) state to ferrous (Fe^{2+}) form.

02

Cellular Uptake

The reduced Fe^{2+} is transported across the apical membrane into enterocytes via **Divalent Metal Transporter 1 (DMT1)**, a proton-coupled transporter.

03

Storage or Export

Within enterocytes, iron can be stored as ferritin or exported across the basolateral membrane through **ferroportin**, the only known iron exporter.

04

Plasma Transport

Exported iron is oxidized to Fe^{3+} and immediately bound by transferrin for safe transport throughout the circulation to target tissues.

Distribution of Iron in the Body

The human body contains approximately 3.5-4.5 grams of iron in healthy adults, carefully distributed across functional and storage compartments. This iron is constantly recycled, with only 1-2 mg lost daily through skin and intestinal cell shedding.

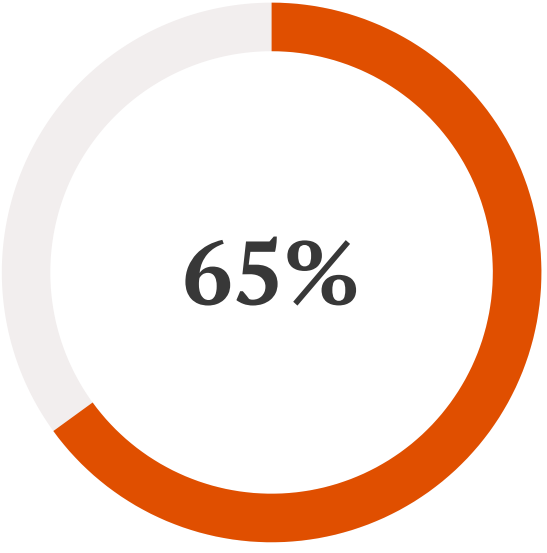

Hemoglobin in Red Blood Cells

Approximately 2-2.5 grams contained in circulating erythrocytes, responsible for oxygen transport

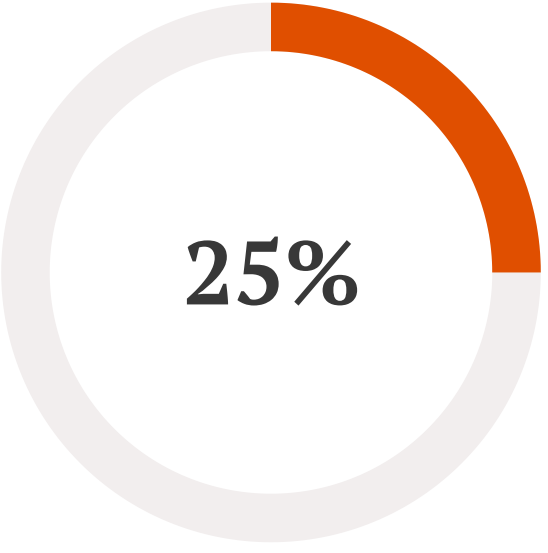

Storage Iron

1-1.5 grams stored as ferritin and hemosiderin in liver, spleen, and bone marrow macrophages

Other Functional Iron

Myoglobin in muscles, iron-containing enzymes (cytochromes), and plasma transferrin-bound iron

Iron uptake of 1 mg /day is needed in adult men while menstruating women need about 2 mg /day .Pregnant and lactating women need higher amount.Growing infants , children and adolescents have greater requirements.Gastric acid plays a role in liberation of iron from food and facilitated the conversion of ferric form to ferrous.

Body iron can be viewed as belonging to 3 pools :

1-The functional pool : Hb , myoglobin. Most of the iron in the body is contained in circulating hemoglobin.

2-The storage pool : Ferritin and Hemosiderin.Ferritin is a water - soluble protein-iron complex and its not visible by microscope.

Hemosiderin is an insoluble protein-iron complex and is visible in macrophages and other cells by light microscope after staining by Perl's reaction (Prussian blue).

3-The transit pool : bound to transferrin in plasma

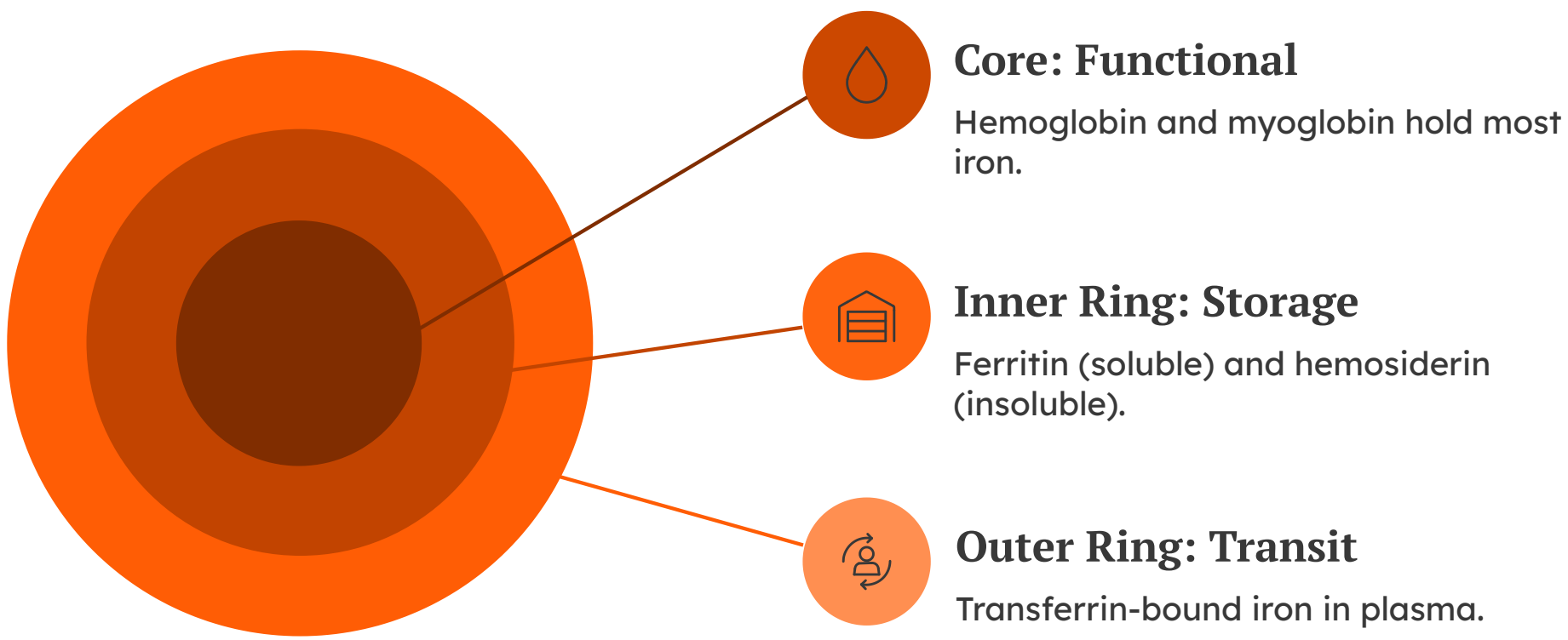

.

Causes of Iron Deficiency Anemia

Iron deficiency anemia develops when iron losses exceed intake and absorption over time. Understanding the underlying cause is essential for appropriate treatment and preventing recurrence.

Blood Loss

Most common cause in adults. Sources include:

- Menorrhagia (heavy menstrual bleeding)
- Gastrointestinal bleeding from ulcers, polyps, or malignancies
- Occult bleeding from colon cancer or inflammatory bowel disease
- Parasitic infections (hookworm in endemic areas)

Inadequate Dietary Intake and increase demand

Common in resource-limited settings. Risk factors include:

- Poor dietary diversity and malnutrition
- Strict vegetarian or vegan diets without supplementation
- Food insecurity and poverty
- Elderly with poor nutritional status
- Prematurity , Pregnancy

Malabsorption

Impaired intestinal iron uptake. Conditions include:

- Celiac disease damaging duodenal mucosa
- Gastric surgery (gastrectomy, bypass) reducing acid and absorptive surface
- Helicobacter pylori infection
- Inflammatory bowel disease

Iron distribution :

Duodenum : 1-2 mg/day

Plasma transferrin : 3 mg

Myoglobin : 300 mg

Circulating Hb in RBCs : 1800 mg

Liver : 1000 mg

Reticuloendothelial cells (Macrophages) : 600 mg

Sloughed mucosal cells , menstruation , Desquamation : 1-2 mg/day loss

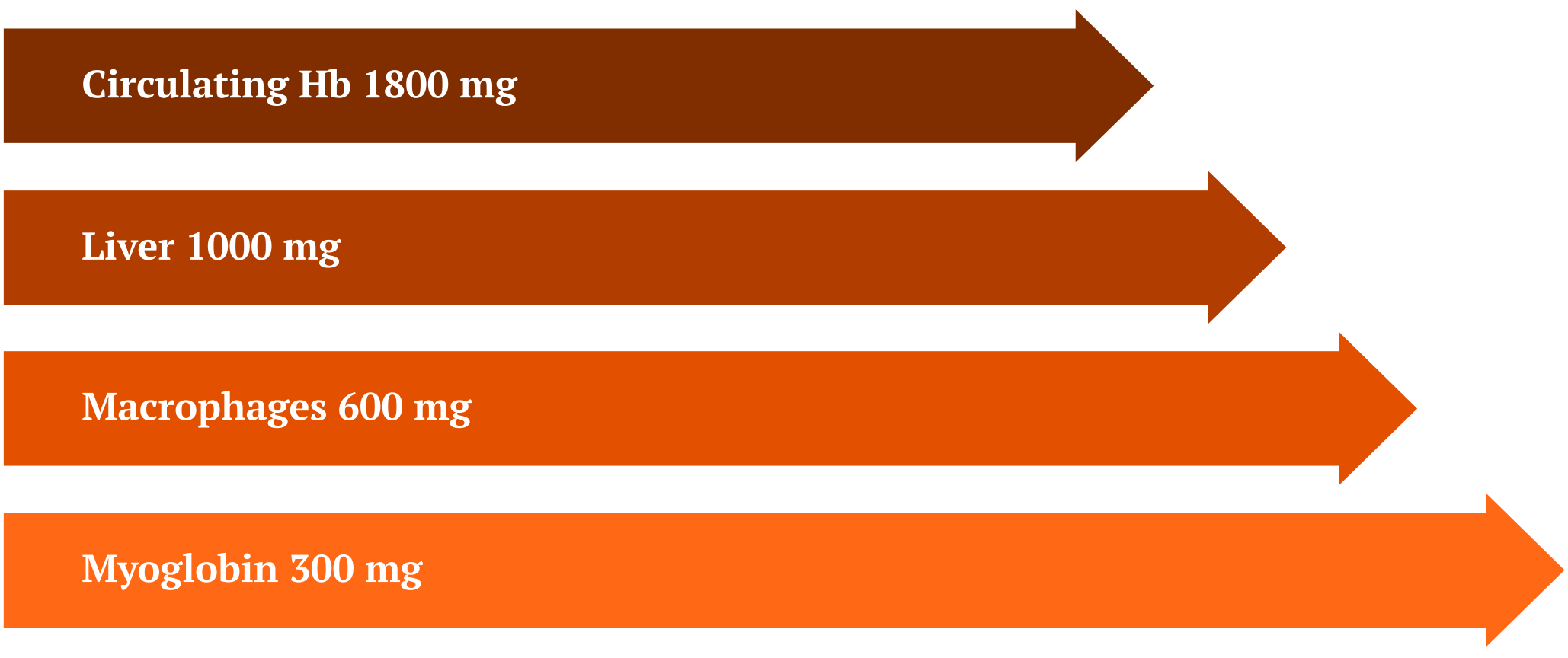

Clinical Features and Laboratory Findings

Iron deficiency anemia presents with a range of symptoms and distinctive laboratory markers, crucial for accurate diagnosis.

Laboratory Diagnosis

A combination of blood tests provides definitive evidence of iron deficiency anemia and helps differentiate it from other anemias.

- **Complete Blood Count (CBC):**
  - ↓ **Hemoglobin (Hb), Hematocrit (Hct):** Indicating anemia.
  - ↓ **MCV (Microcytic):** Mean corpuscular volume is low.
  - ↓ **MCH (Hypochromic):** Mean corpuscular hemoglobin is low.
  - ↑ **RDW (Red Cell Distribution Width):** Indicates variation in red blood cell size.
- **Iron Studies:**
  - ↓ **Serum Iron:** Low circulating iron.
  - ↓ **Ferritin:** The best indicator of depleted iron stores.
  - ↑ **Total Iron-Binding Capacity (TIBC):** More binding sites available due to low iron.
  - ↓ **Transferrin Saturation:** Percentage of transferrin binding sites occupied by iron.

Clinical Manifestations

Symptoms of iron deficiency anemia often develop gradually and can be non-specific, reflecting reduced oxygen delivery to tissues.

- **Fatigue & Weakness:** Most common, profound tiredness.
- **Pallor:** Noticeable in conjunctiva, nail beds, and skin.
- **Dyspnea:** Shortness of breath, especially on exertion.
- **Pica:** Unusual cravings for non-nutritive substances (e.g., ice, dirt).
- **Koilonychia:** Spoon-shaped, brittle fingernails.
- **Glossitis & Angular Stomatitis:** Sore tongue and cracks at mouth corners.
- **Restless Legs Syndrome:** Common, particularly at night.

Bone Marrow Findings in Iron Deficiency Anemia

While often diagnosed through peripheral blood tests, bone marrow examination can provide definitive confirmation of iron deficiency, revealing specific cellular changes and depleted iron stores.

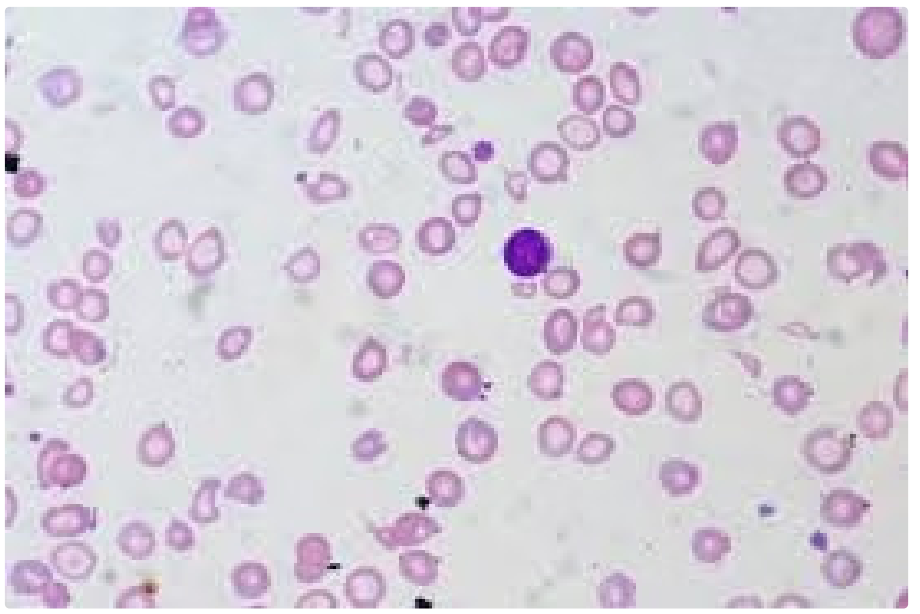

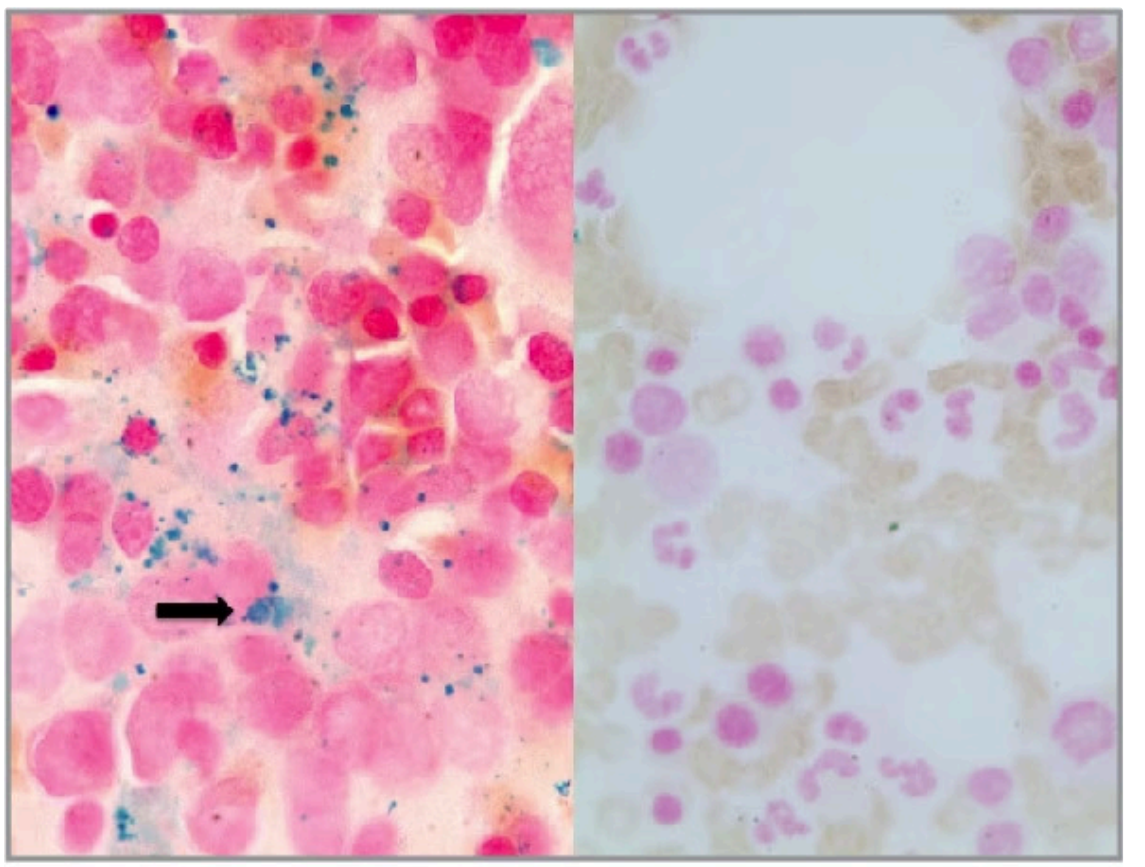

Figure 1 Prussian-blue staining of bone marrow. Positive

Thalassemia: Overview and Main Classification

Thalassemias are inherited hemoglobinopathies characterized by reduced or absent synthesis of either α or β globin chains, leading to imbalanced globin chain production and ineffective erythropoiesis. They represent the most common single-gene disorders worldwide, with highest prevalence in Mediterranean, Middle Eastern, African, and Southeast Asian populations.

Beta Thalassemia

Results from point mutations in the β-globin gene on chromosome 11. Each person inherits 2 β-globin genes (1 per chromosome).

- **β-thalassemia minor:** One mutated gene, asymptomatic or mild anemia
- **β-thalassemia intermedia:** Variable severity, occasional transfusions needed
- **β-thalassemia major:** Both genes severely affected, transfusion-dependent since infancy

Mutations classified as β^0 (no β-globin) or β^+ (reduced β-globin production).

Alpha Thalassemia

Results from deletions or mutations affecting α-globin genes on chromosome 16. Each person inherits 4 α-globin genes (2 per chromosome).

- **Silent carrier (αα/α-):** One gene deletion, asymptomatic
- **α-thal trait (αα/--):** Two gene deletions, mild microcytic anemia
- **HbH disease (α-/--):** Three gene deletions, moderate hemolytic anemia
- **Hb Bart's (--/--):** Four gene deletions, incompatible with life (hydrops fetalis)

Pathophysiology of Alpha and Beta Thalassemia

Alpha Thalassemia Mechanism

Deficiency of α-globin chains creates an excess of β-globin chains (in adults) or γ-globin chains (in fetuses/newborns). These unpaired chains form abnormal tetramers: β4 (HbH) in adults or γ4 (Hb Bart's) in fetuses.

These tetramers are unstable and precipitate within red blood cells, causing membrane damage, hemolysis, and shortened red cell survival. The precipitation also damages erythroid precursors in the bone marrow, leading to ineffective erythropoiesis where many developing cells die before maturation.

Beta Thalassemia Mechanism

Deficiency or absence of β-globin chains results in excess unpaired α-globin chains, which are highly unstable and precipitate in erythroid precursors in the bone marrow.

These precipitated α-chains cause oxidative damage to cell membranes and organelles, triggering apoptosis of developing erythroblasts—the hallmark of ineffective erythropoiesis. Surviving cells that reach circulation are microcytic, hypochromic, and fragile, leading to peripheral hemolysis.

The severe anemia triggers compensatory mechanisms including massive expansion of erythroid marrow (causing bone deformities) and increased iron absorption, leading to progressive iron overload even without transfusions.

Clinical Consequences of Thalassemia

1

Chronic Severe Anemia

Persistent low hemoglobin causes growth retardation, delayed puberty, exercise intolerance, cardiac stress, and high-output heart failure in severe cases.

2

Bone Marrow Expansion

Massive erythroid hyperplasia causes facial bone deformities ("chipmunk facies"), skull bossing, and osteoporosis with pathological fractures due to cortical thinning.

3

Iron Overload

Combination of increased intestinal absorption and chronic transfusions leads to hemosiderosis affecting the heart (cardiomyopathy), liver (cirrhosis), and endocrine glands (diabetes, hypogonadism).

4

Extramedullary Hematopoiesis

Blood formation expands outside the bone marrow into the liver, spleen, and even paravertebral masses, causing hepatosplenomegaly and compression syndromes.

Laboratory Diagnosis: Key Differentiating Features

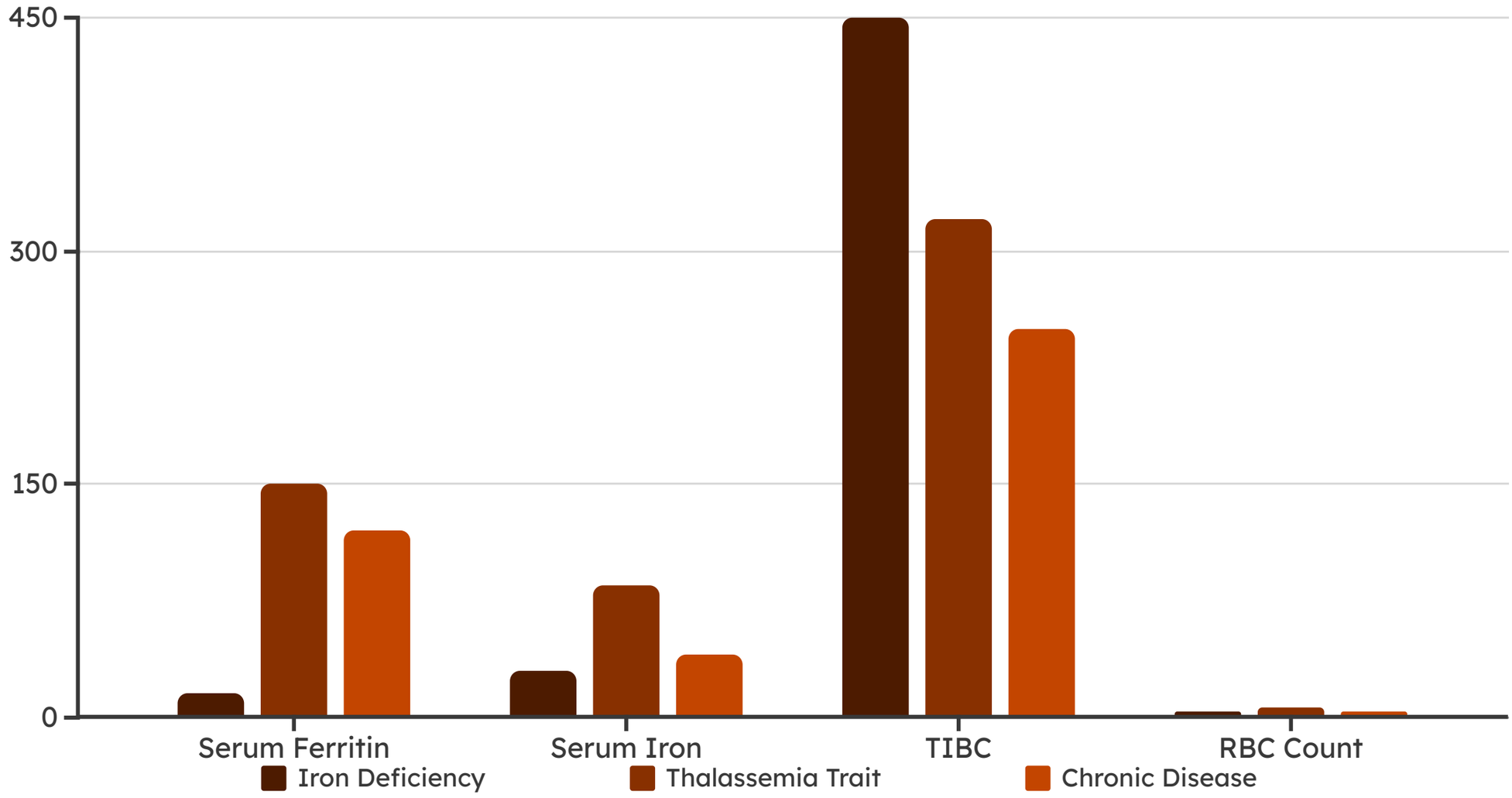

Note: Values are representative examples. Ferritin in ng/mL, iron and TIBC in µg/dL, RBC count in million/µL. The **Mentzer Index** (MCV/RBC count) helps distinguish: <11 suggests thalassemia, >13 suggests iron deficiency.

Advanced Diagnostic Testing

Hemoglobin Electrophoresis

Essential for thalassemia diagnosis. Separates different hemoglobin types based on electrical charge.

Beta thalassemia trait: Elevated HbA2 (>3.5%) and sometimes elevated HbF

Beta thalassemia major: Absent or markedly reduced HbA, very high HbF, elevated HbA2

Alpha thalassemia: Normal pattern in carriers; HbH or Hb Bart's detected in more severe forms

Genetic Testing

Definitive diagnosis through PCR-based methods detecting specific mutations and deletions. Essential for genetic counseling and prenatal diagnosis.

Bone Marrow Examination

Shows erythroid hyperplasia in thalassemia. Ring sideroblasts pathognomonic for sideroblastic anemia. Usually not needed for routine diagnosis.

Reticulocyte Count

Inappropriately normal or low in iron deficiency despite anemia. May be elevated in thalassemia due to hemolysis and ineffective erythropoiesis.

Blood Film Findings in Thalassemia

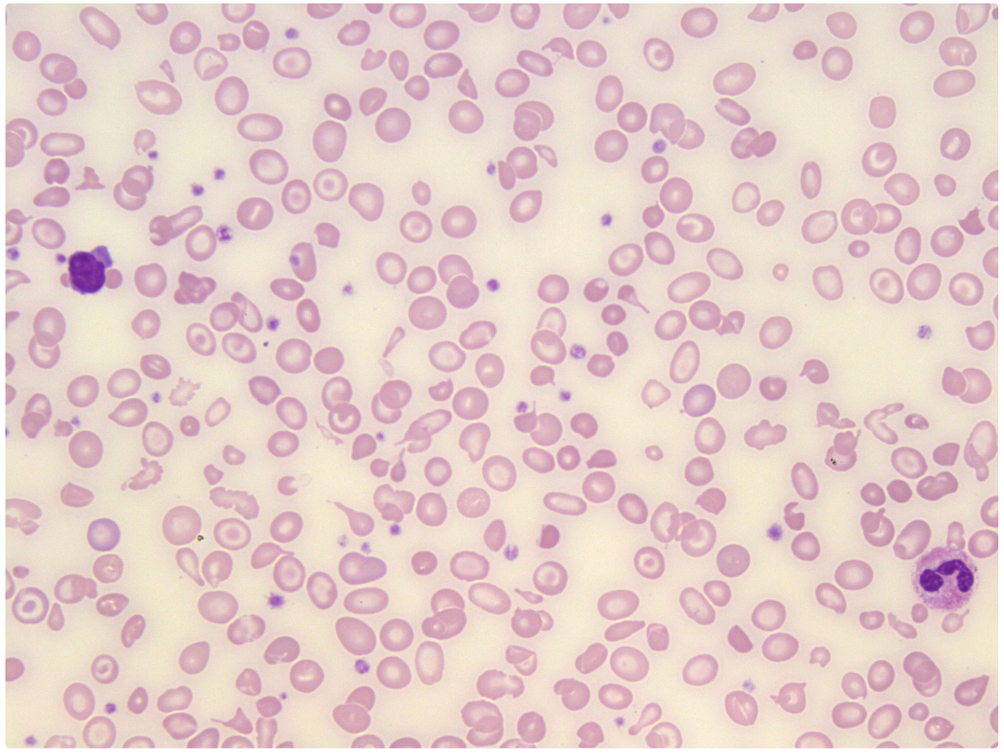

A peripheral blood film examination is a crucial initial step in diagnosing thalassemia, revealing characteristic morphological abnormalities of red blood cells.

- **Microcytic Hypochromic Red Blood Cells:** Red blood cells are smaller than normal (microcytic) and appear paler than usual (hypochromic) due to reduced hemoglobin content.
- **Target Cells:** These distinctive cells have a central area of hemoglobin surrounded by a pale ring and an outer ring of hemoglobin, resembling a target.
- **Anisopoikilocytosis:** Significant variation in the size (anisocytosis) and shape (poikilocytosis) of red blood cells is common.
- **Basophilic Stippling:** Presence of small, dark blue granular inclusions within red blood cells, representing aggregated ribosomes.
- **Nucleated Red Blood Cells (NRBCs):** Immature red blood cells containing a nucleus may be seen, especially in more severe forms, indicating increased erythropoietic activity.

Clinical Features of Beta Thalassemia

Beta thalassemia manifests across a spectrum of severity, primarily categorized into minor, intermedia, and major forms, each with distinct clinical presentations and management needs.

1

Beta-thalassemia Minor (Trait)

Individuals with beta-thalassemia minor typically carry one mutated beta-globin gene. They are often asymptomatic and discovered incidentally during routine blood tests or family screening.

- Mild microcytic, hypochromic anemia
- Normal or slightly increased red blood cell count
- Generally no significant clinical complications
- Often mistaken for iron deficiency anemia

2

Beta-thalassemia Intermedia

This form presents with variable clinical severity, usually requiring occasional blood transfusions, particularly during periods of stress, infection, or pregnancy.

- Moderate to severe anemia (Hb typically 7-10 g/dL)
- Hepatosplenomegaly and jaundice
- Growth retardation and delayed puberty
- Risk of progressive iron overload over time, even without regular transfusions

3

Beta-thalassemia Major (Cooley's Anemia)

This is the most severe form, where both beta-globin genes are severely affected or absent, leading to life-threatening anemia that requires lifelong medical intervention.

- Presents in infancy (4-6 months old) with severe anemia and pallor
- Failure to thrive, poor feeding, and jaundice
- Marked hepatosplenomegaly (enlarged liver and spleen)
- Characteristic bone deformities ("chipmunk facies") due to erythroid hyperplasia
- Requires lifelong regular blood transfusions and iron chelation therapy

Complications of Untreated or Poorly Managed Thalassemia

Other Complications

- Hepatic cirrhosis and liver failure
- Splenic sequestration crises
- Gallstones and cholecystitis
- Thrombotic events
- Transfusion reactions and infections

Endocrine Dysfunction

- Diabetes mellitus from pancreatic iron deposition
- Hypogonadism and delayed puberty
- Hypothyroidism and hypoparathyroidism
- Growth hormone deficiency
- Osteoporosis

Cardiac Complications

- Iron cardiomyopathy leading to heart failure
- Arrhythmias and conduction defects
- Pericarditis
- Leading cause of mortality in thalassemia major

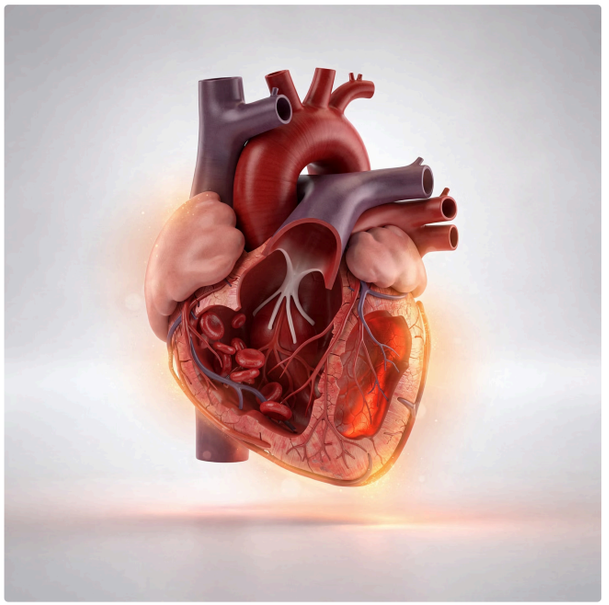

Prevention and Genetic Counseling

Thalassemia prevention programs have successfully reduced disease incidence in high-prevalence regions through carrier screening, genetic counseling, and prenatal diagnosis. These programs raise awareness and provide couples with information to make informed reproductive decisions.

Population Screening

Identify carriers through complete blood count and hemoglobin electrophoresis, especially in high-risk ethnic groups and premarital screening programs.

Preimplantation Testing

Genetic diagnosis during IVF allows selection of unaffected embryos, avoiding affected pregnancies and need for prenatal diagnosis decisions.

Genetic Counseling

When both partners are carriers (25% risk per pregnancy), provide information about inheritance patterns, disease severity, and reproductive options.

Prenatal Diagnosis

Offer chorionic villus sampling (10-12 weeks) or amniocentesis (15-18 weeks) with DNA analysis to determine fetal status in at-risk pregnancies.

Thank You

Questions?

Understanding the differential diagnosis and pathophysiology of hypochromic microcytic anemias enables clinicians to provide accurate diagnosis and targeted treatment, improving patient outcomes and preventing complications.

Key Takeaway: Always consider the full clinical picture—patient history, ethnicity, laboratory indices, and iron studies—before diagnosing and treating microcytic anemia. When in doubt, hemoglobin electrophoresis and genetic testing provide definitive answers.