2024 FMRC
8th FAMILY MEDICINE REVIEW COURSE
LIVE WEBINAR

KFMR

Kuwait Family Medicine Residency Program

KIMS

KAFGP
الرابطة الكويتية لطب العائلة
KUWAIT ASSOCIATION FAMILY AND GENERAL PRACTITIONERS

Dermatological conditions

Dr. Asma AL Shidhani
Consultant family medicine
Sultan Qaboos University Hospital

Outline

- Skin rash
- Fungal infections
- Dermatitis
- Acne
- Rosacea
- Psoriasis

Skin rash

To reach diagnosis of the skin rash, look at:

Appearance of the rash

Location of the rash

The clinical course

Associated symptoms

History and Physical Examination

History:

1. Duration of the rash
2. Initial appearance and progression
3. Location
4. Contact
5. Medication/ environmental exposures
6. +/- other symptoms (fever, Pruritus)

Physical examination:

1. Type of lesions
2. Location/ distribution
3. Arrangement
4. Shape
5. Color
6. +/- scale.

A 12-month-old infant with no past medical problems presents to the clinic with his mother. According to the mother, the child developed a high fever (40°C) four days back. On the third day, the patient's fever resolved, and he began to exhibit a diffuse rash. The eruption started on the patient's chest and moved peripherally to the abdomen, upper extremities, neck, and face. No other symptoms apart from mild rhinorrhea and a non-productive cough.

- Describe the rash
- What is the most likely diagnosis ?
- How to treat?

Roseola Infantum (Exanthema Subitum)

- Roseola is most commonly caused by human herpesvirus 6

Looks like measles

The differences are:

1. Rash progression: Roseola rash begins in the trunk and spreads out, while the measles rash starts on the face and moves downwards.

2. Children with Roseola usually appear well, while those with measles usually appear unwell.

starting on the trunk and spreading peripherally.

- Roseola is a self-limited illness requiring no treatment, and the diagnosis is clinical.

A 10-year-old boy presents with skin rash on the trunk for two weeks. The rash is associated with mild itching. There is no history of contact with similar rash. He has no fever. Examination reveals the following:

- Describe the rash
- What is the most likely diagnosis ?
- How to treat?

Pityriasis Rosea

- Pityriasis rosea present with a single oval-shaped, rose-colored patch (herald patch), usually on the trunk (80% of cases).

Looks like Tinea Corporis (Ringworm)

The differences are:

1. Rash : Pityriasis rosea most commonly occurs on the chest or back. while Ringworm can occur anywhere on the body, including the scalp, fingernails, face, or legs.

2. A potassium hydroxide preparation can help distinguish Pityriasis rosea from Tinea infection or other rashes.

- Although the etiology is not fully known, it is thought to be infectious, with some studies implicating human herpesvirus 6 and 7.

An 8-year-old girl is brought by her mother with history of a sore throat. 2 days ago she started to notice pain on swallowing and had a temperature of 38 °C. Her mother noticed a skin rash on the girl trunk and the inside of her elbows. Her anterior-cervical nodes are swollen & tender.

- Describe the rash
- What is the most likely diagnosis ?
- How to treat?

Scarlet Fever

- Scarlet fever present in 10% of children with streptococcal tonsillopharyngitis.
- It is caused by certain strains of group A beta-hemolytic streptococci.
- Incubation period: 1 – 4 days
- Fever and sore throat one to two days before the rash.

Scarlet Fever Rash

- The rash develops on the upper trunk then spreads throughout the body, sparing the palms and soles.
- Skin: diffusely erythematous (sandpaper rash): confluent maculo-papulous (6 – 9 days)
- Petechiae on the soft palate, on the upper abdomen and trunk.
- Circumoral pallor
- Desquamation (peeling) on the face: end of the first week, then generalized may last for four to six weeks.
- Strawberry tongue

Scarlet Fever Management

- Throat culture is the first-choice method for diagnosis of group A streptococcal infection, if not practical → Rapid antigen tests (sensitivity of approximately 86%)

- Cultures may be ordered when the suspicion for group A streptococcal infection is high, but the rapid antigen test result is negative.

- Treatment: Penicillin is the therapy of choice for streptococcal infection. Those allergic to penicillin and cephalosporins may be treated with oral macrolides (erythromycin, azithromycin) or clindamycin.

A 7-year-old boy presents with a 3-day history of sores on his chin. The sores began as small red papules but have progressed in size and now are crusting and weeping.

- Describe the rash
- What is the most likely diagnosis ?
- How to treat?

Impetigo

- Impetigo is a primary or secondary bacterial infection of the epidermis of the skin.
- There are bullous and non-bullous forms of the infection, with the bullous form typically occurring in neonates and the non-bullous form most common in preschool-and school-aged children.
- *Streptococcus pyogenes* is the most common cause of non-bullous impetigo and *S. aureus* is the main source of bullous impetigo.
- Rash: Initially, patients develop vesicles or pustules that form a thick, yellow crust. With autoinoculation, the lesions may quickly spread.
- The face and extremities are most commonly affected.

Impetigo

- Impetigo is usually a self-limited disease, but antibiotics are often prescribed to prevent complications and spread of the infection.

- Antibiotics: Topical mupirocin or retapamulin is adequate treatment for single lesions of non-bullous impetigo or small areas of involvement.

- Systemic antibiotics are indicated for:
  - Non-bullous impetigo with extensive involvement
  - In athletic teams
  - Childcare clusters
  - Multiple family members
  - Bullous impetigo.

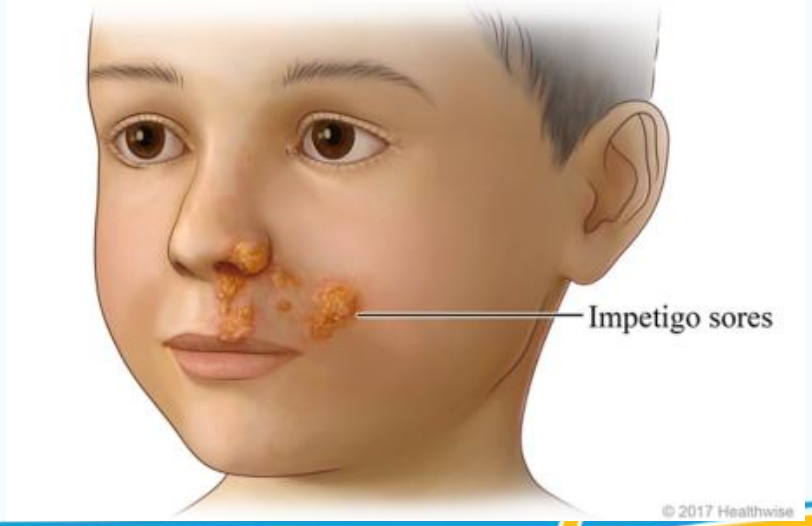

A 7-year-old girl brought by her mother with history of fever and headache. A three days later, she developed bright red cheeks and today she started to have a skin rash that appears on the arms, legs, trunk and buttocks.

- Describe the rash
- What is the most likely diagnosis ?
- How to treat?

Erythema Infectiosum (Fifth disease)

- Erythema Infectiosum, or, is caused by parvovirus B19.
- It is a common childhood infection
- Incubation period 4–21 days after exposure
- Rash:
  1. Start with a prodrome of low-grade fever, malaise, sore throat, headache, and nausea
  2. Followed several days later by an erythematous “slapped cheek” facial rash.
  3. After two to four days, the facial rash fades.
  4. Then pink patches and macules may develop in a lacy, reticular pattern, most often on the extremities.
  5. After one to six weeks, the rash resolves but may reappear with sun exposure, heat, or stress.

Erythema Infectiosum (Fifth disease)

- Arthralgias occur in approximately 8% of young children with the disease but are much more common in teens and young adults.

- Should an infected person be excluded from school, day care or work?

No, as long as the person is feeling well enough to participate in normal activities. Patients are no longer considered infectious once the body rash appears and fever subsides.

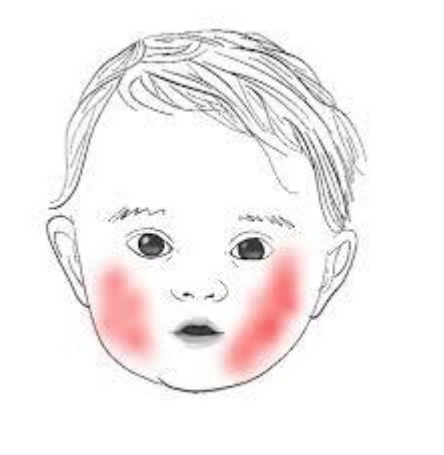

- Treatment is symptomatic and includes NSAIDs for arthralgias and antihistamines for pruritus.

A 7-year-old boy presents with multiple small painless lesions on his face for the last one month.

- Describe the rash
- What is the most likely diagnosis ?
- How to treat?

Molluscum Contagiosum

- Molluscum contagiosum is highly contagious viral infection caused by a poxvirus.
- Most commonly affects children 2-11 years of age and in sexually active adolescents.
- The lesions are flesh-colored or pearly white, small papules with central umbilication.
- The oral mucosa is rarely affected, but lesions may appear on the genital region and conjunctiva.
- Typically, children have 10 to 20 lesions, but occasionally there may be up to hundreds.
- It can erupt and spread quickly in a child with underlying atopic dermatitis, or it can induce dermatitis in a child with previously clear skin (molluscum dermatitis).

Molluscum Contagiosum

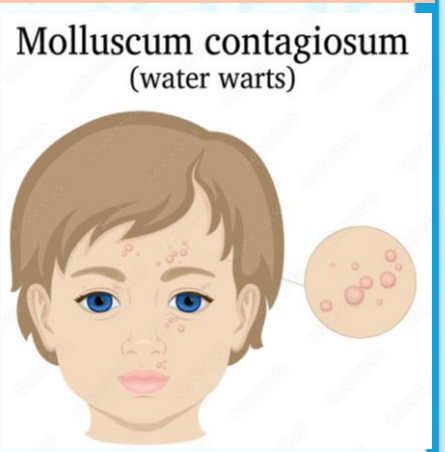

- The diagnosis is made clinically.
- The condition is self-limited, lesions may last for months or up to 2-4 years.
- Treatment options if physical appearance is a concern, including cryotherapy, Imiquimod and intralesional immunotherapy.
- Dermatitis (occurring as molluscum dermatitis or a flare-up of atopic dermatitis) requires treatment to resolve pruritus and limit spread of the molluscum.

A 25-year-old woman presents with history of red, scaly patches on her arm for the last 10 days.

- Describe the rash
- What is the most likely diagnosis ?
- How to treat?

Tinea Infection

- Tinea capitis (scalp)
- Tinea corporis (body)
- Tinea versicolor
- Tinea cruris (groin)
- Tinea pedis (feet)
- Tinea manus (hands)
- Tinea unguium (nails)

Tinea capitis (scalp)

- It most commonly affects children.

Presentation:

- Early disease (itching and scaling)
- Classic presentation involves one or more of scaling, alopecia, and adenopathy
- It may progress to kerion (boggy tender plaques and pustules).

Diagnosis:

- If typical presentation, diagnosis is **clinical**
- In atypical cases, a KOH, culture.

Tinea capitis (scalp)

Treatment:

- Systemic antifungal as topical agents do not penetrate the hair shaft + 1% or 2.5% selenium sulfide shampoo or 2% ketoconazole shampoo for the first two weeks to reduce transmission.

- Rx. Options of systemic antifungal : Griseofulvin, Terbinafine and Fluconazole have equal effectiveness.

Advice:

- The child can return to school once treatment started.

- 14 days should not share combs, brushes, helmets, hats, or pillowcases, or participate in sports that involve head-to-head contact.

Tinea corporis, Ringworm (body)

- It most commonly affects children.

Presentation:

- Typically presents as a red, annular, scaly, pruritic patch with central clearing and an active border.
- Lesions may be single or multiple

Diagnosis:

- If typical presentation, diagnosis is **clinical**
- In atypical cases, a KOH.

Tinea corporis, Ringworm (body)

Treatment:

- Topical antifungal for two to four weeks.
- Rx. Options of topical agents: Terbinafine and Butenafine or azoles.
- Oral antifungal agents may be indicated if extensive disease, failed topical treatment or immunocompromised patients.

Advice:

- The child can return to school once treatment started.
- Should not share clothes, or participate in sports that involve body contact like boxing.

Tinea Versicolor (pityriasis versicolor)

- It is a superficial fungal skin infection, caused by Malassezia spp.

Presentation:

- It presents as hypopigmented (common) or hyperpigmented plaques with fine scale
- common sites: neck, chest, back, abdomen, and proximal extremities.

Diagnosis:

- If typical presentation, diagnosis is **clinical**
- In atypical cases, a KOH.

Tinea Versicolor (pityriasis versicolor)

Treatment:

- Topical treatment for at least two weeks:
- Options:
  - ❑Clotrimazole
  - ❑Miconazole
  - ❑Selenium sulfide lotion
  - ❑Terbinafine
  - ❑Zinc pyrithione soap

- Oral antifungal treatment may be used if topical treatment is unsuccessful or impractical.

Tinea cruris, jock itch (groin)

- It most commonly affects adolescent and young adult males.

Presentation:

- Involves the portion of the upper thigh opposite the scrotum (Scrotum is usually spared).
- Classic presentation involves Erythematous, scaly, sharply demarcated pruritic rash in the groin, possibly with central clearing.

Diagnosis:

- If typical presentation, diagnosis is **clinical**
- In atypical cases, a KOH, culture.

Tinea cruris, jock itch (groin)

Treatment:

- Topical antifungal for two to four weeks.
- Rx. Options of topical agents: Terbinafine and Butenafine or azoles.
- Oral antifungal agents may be indicated if extensive disease, failed topical treatment or immunocompromised patients.

Advice:

- Wear loose-fitting, non-restrictive garments and clothing.

Tinea pedis, athlete's foot (feet)

- It most commonly affects people who have sweaty feet while wearing tight-fitting shoes..

Presentation:

- Involves the skin between the toes, but can spread to the sole, sides, and dorsum of the foot
- Presents with erythema and maceration between the toes, sometimes accompanied by painful vesicles.
- The chronic form is characterized by scaling, peeling, and erythema between the toes.

Diagnosis:

- If typical presentation, diagnosis is **clinical**
- In atypical cases, a KOH, culture.

Tinea pedis, athlete's foot (feet)

Treatment:

- Topical antifungal for two to four weeks.
- Rx. Options of topical agents: Terbinafine and Butenafine or azoles.
- Oral antifungal agents may be indicated if extensive disease, failed topical treatment or immunocompromised patients.

Advice:

- Wear wide shoes, dry between the toes after bathing, and place lamb's wool between toes.

Tinea manus (hands)

Presentation:

- The palmar surface is diffusely dry and hyperkeratotic.
- If the fingernails are involved, vesicles and scant scaling may be present.
- It often occurs in patients with tinea pedis and relapses may be frequent if onychomycosis or tinea pedis is not resolved.

Diagnosis:

- If typical presentation, diagnosis is **clinical**
- In atypical cases, a KOH, culture.

Management:

- Topical antifungal therapy
- Application of emollients containing lactic acid .

Tinea unguium (Onychomycosis) (nails)

- It is characterized by thickened, brittle, discolored nails
- The diagnosis usually confirmed with a KOH, culture, or PAS stain because the treatment is long and potentially expensive, and the nonfungal mimics are common (chronic trauma and psoriasis).
- The involvement of multiple toenails, or presence of tinea pedis, may justify treatment without confirming the diagnosis.

Tinea unguium (Onychomycosis) (nails)

Oral therapy:

- Oral therapy is the most effective treatment for onychomycosis of any severity.
- It have higher cure rates and shorter treatment periods than topical therapy.

- **Terbinafine:** is the most effective and considered as first-line therapy. Chronic or active liver disease is the main contraindication to Terbinafine use because of reports of mild and severe liver injuries. The (FDA) recommends LFT before initiating therapy. Subsequent laboratory monitoring is not necessary for immunocompetent patients.
- **Itraconazole:** Continuous Itraconazole or pulse dosing regimen (i.e., interval treatment cycles) is used for fingernail/toenail onychomycosis.
- **Fluconazole**: 150 mg weekly for at least six months for fingernails and toenails, may be used if the patient is unable to tolerate Terbinafine or Itraconazole.

Tinea unguium (Onychomycosis) (nails)

Topical therapy:

- Topical therapy is less effective and more expensive than oral therapy
- It can be used as an alternative first-line treatment in patients with superficial onychomycosis or early distal lateral subungual onychomycosis.
- The recommended duration of topical therapy is 24 weeks for fingernails and 48 weeks for toenails.

➢ **Ciclopirox 8%** topical solution is FDA approved for mild to moderate fingernail and toenail onychomycosis.

➢ **Efinaconazole 10%:** Once-daily treatment for mild to moderate onychomycosis.

➢ **Amorolfine 5%** lacquer can be used for onychomycosis without matrix involvement and for mild distal lateral subungual onychomycosis that affects up to two nails.

Tinea unguium (Onychomycosis) (nails)

Surgical therapy

- Nail trimming and debridement can be used with oral or topical pharmacologic therapy to increase treatment effectiveness and for severe infection or when medical therapy fails.
- Dual-wavelength infrared and fractional carbon-dioxide laser therapy are FDA approved for temporary cosmetic improvement of nails based on low-level evidence.
- Combining laser therapy with topical therapy increases overall treatment effectiveness.
- Treatment courses for onychomycosis are long (three to six months), failure rates are high, and recurrences are common (up to 50%).

A 4-year-old boy is brought by his mother with history of a rash over the face and arms. The mother is upset as the rash is resolving only temporarily when using topical steroid creams. Examination reveals scaly pruritic, erythematous lesions over the face and the flexural surfaces of both arms.

- Describe the rash
- What is the most likely diagnosis ?
- How to treat?

Dermatitis

- Types
  - Atopic dermatitis
  - Contact dermatitis
    - Irritant
    - Allergic
  - Seborrheic dermatitis
  - Exfoliative dermatitis

	Endogenous	Exogenous	
	Atopic Dermatitis	**Irritant Contact Dermatitis**	**Allergic Contact Dermatitis**
Relevant features	Erythematous, edematous rash which follows an age-dependent distribution Chronically relapsing course Positive family history	Well-demarcated erythematous, edematous rash with vesiculation Improves with rest and worsens with repeated irritant exposure	Typically a well-demarcated erythematous, edematous rash with vesiculation Systemic exposure may produce a diffuse rash on distal surfaces
Skin distribution	Infants: facial and extensor involvement Children: flexural surfaces Adult: flexural surfaces, neck, face, anterior chest	Most commonly hands and feet	
Diagnosis	Clinical	Clinical	Clinical and patch testing Patch testing is the standard for diagnosis; however, a negative result does not rule out ACD
Symptoms	Intense pruritus	Burning/irritation, soreness	Pruritus
Duration of onset	May appear anytime in life Preferentially affects areas of dryness	May appear acutely within 8–24 h of exposure No sensitizing exposure is required	Lesions appear 24–72 h after exposure Requires sensitizing exposure
Treatment	Emollients Topical corticosteroids Topical calcineurin inhibitors Crisaborole	Irritant avoidance Emollients Topical corticosteroids	Allergen avoidance Emollients Topical corticosteroids Topical calcineurin inhibitors
Systemic therapies	Systemic corticosteroids Phototherapy/psoralen and UV-A Dupilumab	Not typically used	Systemic corticosteroids Phototherapy/psoralen and UV-A

American Academy of Dermatology Diagnostic Criteria for Atopic Dermatitis

Essential features: must be present for diagnosis

- Chronic or relapsing.
- Eczema (acute, subacute, chronic)
- Pruritus
- Typical morphology and age-specific patterns (facial, neck, and extensors in infants & children flexural lesions in any age group, sparing of the groin and axillary regions.

Important features: support the diagnosis (observed in most cases)

- Atopy (personal or family history)
- Early age at onset
- Immunoglobulin E reactivity
- Xerosis

Associated features: suggestive of the diagnosis but nonspecific

- Atypical vascular responses (facial pallor, white dermographism)
- Keratosis pilaris, pityriasis alba, hyperlinear palms, or ichthyosis
- Ocular or periorbital changes
- Perifollicular accentuation, lichenification, or prurigo lesions

Dermatitis management

The goals of treatment are:

- ❑Resolve the current skin eruption
- ❑Relieve symptoms
- ❑Treat the underlying epithelial dysfunction
- ❑Engage in maintenance therapy

- Oral antihistamines are not recommended because they do not reduce pruritus.

Patient education is the cornerstone of management:

- ▪Avoid known exacerbating factors like known irritants.
- ▪Regular skin care routine
- ▪Use of moisturizers to protect against dry skin. Using moisturizers reduces xerosis, pruritus, erythema, fissuring, and lichenification.

Atopic Dermatitis

Indications for Specialist Referral for Patients with Atopic Dermatitis

- ❑Candidates for allergen-specific immunotherapy
- ❑Consideration for systemic immunosuppressive therapy
- ❑Poor disease control with appropriate first-line treatments
- ❑Severe or recurrent skin infections (viral or bacterial)
- ❑Significant psychosocial problems due to atopic dermatitis
- ❑Uncertain diagnosis
- ❑Uncontrolled facial atopic dermatitis

A 18-year-old woman presents with skin rash on the face for one year. She has no chronic medical problems and is not on any medications.

- Describe the rash.
- What is the most likely diagnosis ?
- How to treat?

Acne

Pathogenesis: Four interrelated processes are involved:

1. Sebum overproduction
2. Abnormal shedding of follicular epithelium
3. Follicular colonization by *Cutibacterium acnes* and
4. Inflammation

- **Causes:**

1. Excessive androgen hormones or a heightened sebaceous gland sensitivity to normal levels.
2. Genetic predisposition.
3. Certain foods particularly those with a high glycemic index (e.g., sugary drinks, starchy foods, highly processed foods) and skim milk, seem to affect acne severity.
4. Other factors include: psychological stress, tobacco smoke, and damaged or unhealthy skin.
5. Medications side effects

Acne

Location: typically occur on the face, chest, or upper back.

Types of lesions :

- Non-inflammatory closed comedones (whiteheads);
- Open comedones (blackheads)
- Inflammatory papules, nodules, pustules, and cysts.

Goals of therapy:

- Reduction in comedones and inflammatory lesions
- Improvement of psychosocial symptoms
- Avoidance of scarring.

Acne

Treatment options

Topical agents

1. *Benzoyl Peroxide/ Salicylic Acid.*
2. *Topical Antibiotics*
3. *Topical Retinoids*
4. *Azelaic Acid.*

Oral agents

1. *Systemic antibiotics*
2. *Isotretinoin*
3. *Combined oral contraceptives*

- Acne severity classified as mild, moderate, or severe based on the extent and types of lesions.
- Selection of treatment option depends on acne severity and types of lesions.

Figure 2: Global Alliance Acne Treatment Algorithm

Acne Severity	MILD		MODERATE		SEVERE
	Comedonal	Mixed and Papular/pustular	Mixed and Papular/pustular	Nodular[2]	Nodular/Conglobate
1st Choice	Topical Retinoid	Topical Retinoid + Topical Antimicrobial	Oral Antibiotic + Topical Retinoid +/- BPO	Oral Antibiotic + Topical Retinoid + BPO	Oral Isotretinoin[2]
Alternatives[1]	Alt. Topical Retinoid or Azelaic acid* or Salicyclic acid	Alt. Topical Retinoid Antimicrobial Agent + Alt. Topical Retinoid or Azelaic Acid*	Alt. Oral Antibiotic + Alt. Topical Retinoid +/- BPO	Oral Isotretinoin or Alt. Oral Antibiotic + Alt. Topical Retinoid	High Dose Oral Antiobiotic +Topical Retinoid + BPO
Alternatives for Females[1,4]	See 1st Choice	See 1st Choice	Oral Antiandrogen + Topical Retinoid/ Azelaic Acid* +/- Topical Antimicrobial	Oral Antiandrogen[3] + Topical Retinoid/ +/- Oral Antibiotic +/- Alt. Antimicrobial	High Dose Oral Antiandrogen[3] + Topical Retinoid +/- Alt. Topical Antimicrobial
Maintenance Therapy	Topical Retinoid		Topical Retinoid +/- BPO		

Antibiotics for acne

Topical

- **Clindamycin or erythromycin**
- To reduce the risk of resistance:
  1. Avoid use of topical antibiotics as monotherapy or maintenance therapy.
  2. Limit the duration of therapy to 12 weeks.

Systemic

- **Doxycycline as first-line**
- **Tetracycline**
- **Azithromycin**

Limit the duration of therapy to 12 weeks except in select recalcitrant cases.

Isotretinoin

Common dose-dependent adverse effects include:

- Xerosis
- Cheilitis
- Acne flare-up
- Dry eyes
- Headache
- Elevated lipid and hepatic enzyme levels.

- Patients receiving isotretinoin should be counseled about associated risks.
- LFT and lipid panels monitoring until stability is assured.
- All female patients must have pretreatment and posttreatment contraceptive counseling and monthly urine pregnancy tests.

Others

Physical modalities

- Laser, light-based modalities, chemical peels and comedo extraction is lacking high-quality evidence.

Complementary therapies

- Dietary interventions (i.e., low-glycemic-load diets and avoidance of dairy or skim milk), acupuncture, cupping, herbal medicines, tea tree oil, and purified bee venom have is lacking high-quality evidence.

A 50-year-old woman presents with skin rash on the face for one year. She has no chronic medical problems and is not on any medications.

- Describe the rash.
- What is the most likely diagnosis ?
- How to treat?

Rosacea

- Rosacea is a chronic facial skin condition of unknown cause.
- Rash characteristics:
  - ❑ Involvement of the central face
  - ❑ Transient or persistent erythema with a feeling of warmth
  - ❑ Telangiectasia
  - ❑ Inflammatory papules and pustules
  - ❑ Hyperplasia of the connective tissue.

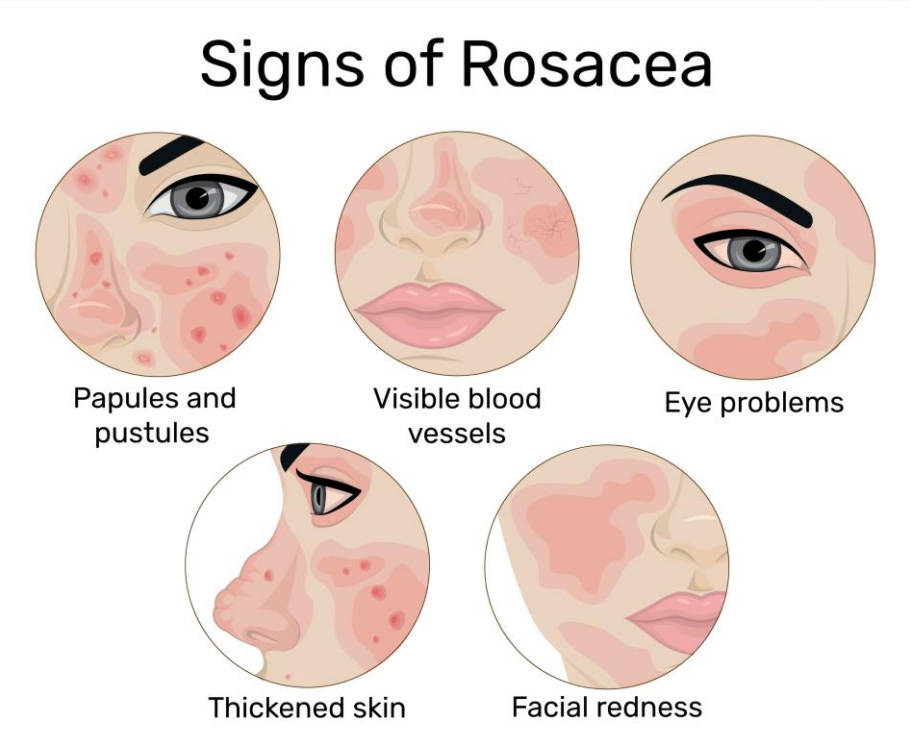

Rosacea management

Non-pharmacological:

- Avoidance of triggers
- Use of mild cleansing agents
- Moisturization
- Photoprotection (with wide-brimmed hats and broad-spectrum sunscreens)

Pharmacological:

- Topical metronidazole or azelaic acid: for inflammatory lesions and erythema
- Topical brimonidine, a is effective in reducing erythema.
- Papulopustular rosacea: systemic antibiotics
- Phymatous rosacea: laser or light-based therapies.
- Ocular rosacea is managed with lid hygiene, topical cyclosporine, and topical or systemic antibiotics.

A 30-year-old man presents with skin rash on both forearms for 3 months. the rash is itchy and he has no chronic medical problems and is not on any medications.

- Describe the rash.
- What is the most likely diagnosis ?
- How to treat?

Psoriasis

- Psoriasis is an immune-mediated process triggered by an interplay of genetic, environmental, physical (e.g., skin trauma), and infectious factors.
- It can be associated with CVD disease, obesity, metabolic syndrome, diabetes mellitus, and inflammatory bowel disease.
- Psoriasis forms: plaque, guttate, erythrodermic, pustular, inverse, nail, and psoriatic arthritis.
- 90% of psoriasis is plaque psoriasis
- Psoriasis is diagnosed clinically based on the presence of characteristic erythematous, scaly skin plaques in typical locations, with associated history and systemic symptoms.

Psoriasis Treatment Strategies

Non-pharmacological:

- Maintaining ideal body weight
- avoiding tobacco products
- Limiting alcohol
- Practicing stress reduction techniques.
- The Psoriasis Area and Severity Index is a tool to assess severity and monitor treatment effectiveness over time.

Pharmacological:

- Topical corticosteroids, vitamin D analogues, and tazarotene are used to treat mild to moderate disease.
- Systemic treatment with nonbiologic and biologic agents and ultraviolet B phototherapy are used for moderate to severe disease

Psoriasis management

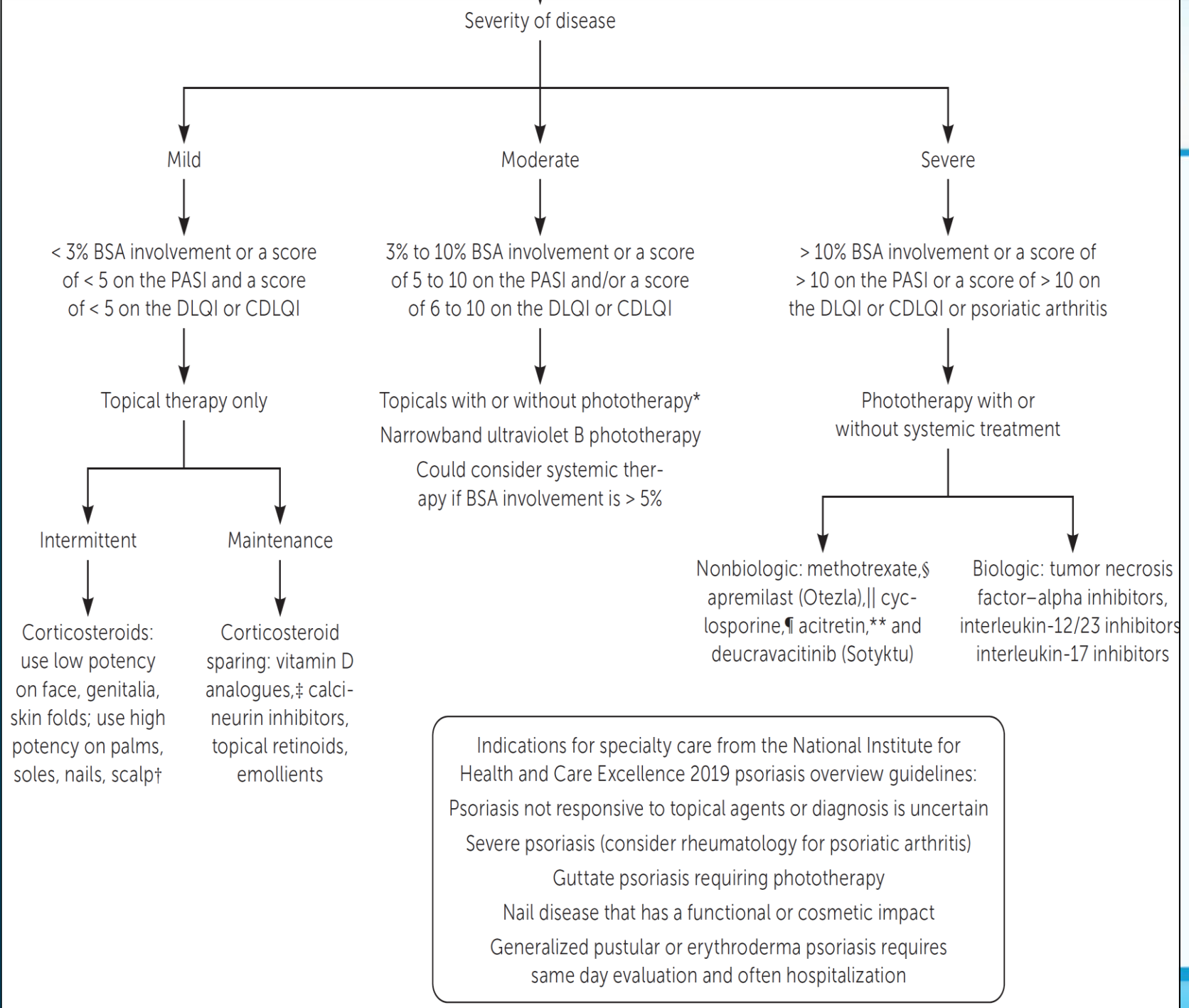

Determine disease severity:

- Assess BSA involvement or PASI score
- Consider impact of disease on physical, psychosocial, and social well-being with the DLQI or, if younger than 16 years, the CDLQI
- Evaluate for psoriatic arthritis; if present, the disease is considered severe

Skin Malignancies: Urgent Referrals

- Skin Malignancies: Melanomas, non-melanoma skin cancer (squamous cell carcinoma, sarcomas, lymphomas, Merkel cell carcinomas)

- Atypical mole:
  - Odd or ugly duckling mole
  - Change in appearance (size, shape, color)
  - Change in symptoms (itchy, painful or bleeding)
  - Changing lesion, asymmetry, irregular boarders.
  - Pigmented, multiple colors which may extend beyond the broader
  - Larger than 6mm

Thank You