**Standard Operating Procedure (SOP) for Quality Control (QC) of MALP-EM (Multi-Atlas Label Propagation with Expectation Maximisation) segmented regions of interest (ROIs) Analysis**

The purpose of this SOP is to establish a standardized, systematic approach for performing QC on 132 MALP-EM ROIs, which include both cortical (98) and subcortical (34) brain structures. This process ensures the accuracy, reliability, and consistency of segmentations used for downstream statistical and neuroanatomical analyses. High-confidence segmentations are critical for deriving meaningful results; therefore, this SOP integrates detailed visual inspection, structured grading, documentation, and validation steps to maintain data integrity.

**Dataset Overview**

This QC protocol is applied to a longitudinal neuroimaging dataset of HD-YAS consisting of structural brain MRI scans processed through the MALP-EM segmentation pipeline. The key dataset characteristics for my project are as follows:

- Total Number of participants - 88
- Longitudinal Timepoints **-** Each participant underwent two MRI scanning sessions, referred to as:
    - Visit 1 (v1): Baseline scan
    - Visit 2 (v2): Follow-up scan, conducted approximately four years after v1

  This longitudinal design allows assessment of structural brain changes over time and necessitates careful intra-subject consistency during QC.
- Imaging Sequence: T1-weighted high-resolution structural MRI scans (preprocessed).
- Preprocessing - All T1 images have undergone skull-stripping to remove non-brain tissues, improving anatomical visibility and reducing segmentation errors.
- Segmentation Output:
    - Each scan is processed using the MALP-EM segmentation framework.
    - Resulting segmentations are stored in a single file per scan: participantID_MALPEM.nii.gz
    - This file includes 132 individual regions of interest (ROIs):
        - 34 non-cortical ROIs
        - 98 cortical ROIs (139 - 41)

| **NON-CORTICAL ROIs – 34 in Total** |
| --- |

| | |
|---|---|
| **Ventricular System ROIs (6)** | Third ventricle |
| | Fourth Ventricle |
| | Inferior Lateral Ventricle (Right, Left) |
| | Lateral ventricle (Right, Left) |
| **Basal Ganglia ROIs (8)** | Accumbens Area (Right, Left) |
| | Caudate (Right, Left) |
| | Putamen (Right, Left) |
| | Pallidum (Right, Left) |
| **Limbic System ROIs (6)** | Amygdala (Right, Left) |
| | Hippocampus (Right, Left) |
| | Basal Forebrain (Right, Left) |
| **Thalamic structure ROIs (4)** | Thalamus Proper (Right, Left) |
| | Ventral Dorsal Column (Right, Left) |
| **Brainstem ROI (1)** | Brainstem |
| **Cerebellum (7)** | Cerebellum Exterior (Right, Left) |
| | Cerebellum White Matter (Right, Left) |
| | Cerebellar Vermal Lobules I - V |
| | Cerebellar Vermal Lobules VI - VII |
| | Cerebellar Vermal Lobules VIII - X |
| **White Matter ROIs (2)** | Cerebral White Matter (Right, Left) |
| **CORTICAL ROIs BY LOBE – 98 in Total** | |
| **Frontal lobe ROIs (36)** | Frontal Pole (Right, Left) |
| | Superior Frontal Gyrus (Right, Left) |
| | Superior Frontal Gyrus Medial Segment (Right, Left) |
| | Middle Frontal Gyrus (Right, Left) |
| | Precentral Gyrus (Right, Left) |
| | Precentral Gyrus Medial Segment (Right, Left) |
| | Supplementary Motor Cortex (Right, Left) |
| | Opercular part of the Inferior Frontal Gyrus (Right, Left) |
| | Orbital part of the Inferior Frontal Gyrus (Right, Left) |
| | Triangular part of the Inferior Frontal Gyrus (Right, Left) |
| | Frontal Operculum (Right, Left) |
| | Anterior Orbital Gyrus (Right, Left) |
| | Lateral Orbital Gyrus (Right, Left) |
| | Medial Orbital Gyrus (Right, Left) |
| | Posterior Orbital Gyrus (Right, Left) |
| | Medial Frontal Cortex (Right, Left) |
| | Subcallosal Area (Right, Left) |
| | Gyrus Rectus (Right, Left) |
| **Parietal Lobe ROIs (14)** | Post Central Gyrus (Right, Left) |

| | |
|---|---|
| | Post Central Gyrus Medial Segment (Right, Left) |
| | Superior Parietal Lobule (Right, Left) |
| | Supramarginal Gyrus (Right, Left) |
| | Angular Gyrus (Right, Left) |
| | Precuneus (Right, Left) |
| | Parietal Operculum (Right, Left) |
| **Temporal Lobe ROIs (22)** | Superior Temporal Gyrus (Right, Left) |
| | Middle Temporal Gyrus (Right, Left) |
| | Inferior Temporal Gyrus (Right, Left) |
| | Temporal Pole (Right, Left) |
| | Transverse Temporal Gyrus (Right, Left) |
| | Planum Temporale (Right, Left) |
| | Planum Polare (Right, Left) |
| | Para hippocampal Gyrus (Right, Left) |
| | Ententorhinal Area (Right, Left) |
| | Anterior Insula (Right, Left) |
| | Posterior Insula (Right, Left) |
| **Occipital Lobe (18)** | Calcarine cortex (Right, Left) |
| | Cuneus (Right, Left) |
| | Lingual Gyrus (Right, Left) |
| | Fusiform Gyrus (Right, Left) |
| | Occipital Pole (Right, Left) |
| | Superior Occipital Gyrus (Right, Left) |
| | Middle Occipital Gyrus (Right, Left) |
| | Inferior Occipital Gyrus (Right, Left) |
| | Occipital Fusiform Gyrus (Right, Left) |
| **Cingulate Lobe ROIs (6)** | Anterior Cingulate Gyrus (Right, Left) |
| | Middle Cingulate Gyrus (Right, Left) |
| | Posterior Cingulate Gyrus (Right, Left) |
| **Opercular region ROIs (2)** | Central Operculum (Right, Left) |

**QC Workflow Overview**

This section outlines the visual inspection process for reviewing the MALP-EM segmentations. The QC protocol emphasizes both anatomical accuracy and longitudinal consistency to ensure the reliability of downstream statistical analysis.

- Sequential Review Strategy: Per-Participant Pairwise Review is done to minimize rater drift, inter-session variability, and batch effects, we adopt a within-subject, across-timepoint review model.
  - QC is performed by reviewing each participant's v1 and v2 scans consecutively (e.g., v1 followed immediately by v2).
  - This paired review allows direct comparison of segmentations:
    - Highlights inconsistencies across timepoints
    - Aids in identifying longitudinal segmentation artefacts

    - Maintains a stable internal rating reference for each rater

**Visualization Methodology**

- Freeview (from the FreeSurfer suite) is used as the primary tool for visualization and manual inspection of segmentations.
- For each scan, a single file named participantID_MALPEM.nii.gz is loaded.
- This file contains all 132 ROIs pre-labelled, rendered with distinct colour overlays for clarity.
- ROIs are overlaid on the skull stripped T1 structural image, ensuring optimal visualization of boundaries and reducing non-brain interference.
- All ROIs are displayed simultaneously, using outline-only coloured overlays, different for both the left and right hemispheres.
    - This approach avoids masking underlying anatomical detail.
    - It improves visibility in regions where ROIs overlap (e.g., adjacent cortical areas).
    - Each ROI is visually distinct, reducing ambiguity during grading.
- Segmentation QC is conducted across all three orthogonal anatomical planes to ensure spatial coherence of ROIs:
    - Sagittal – Best for medial and lateral cortical structures

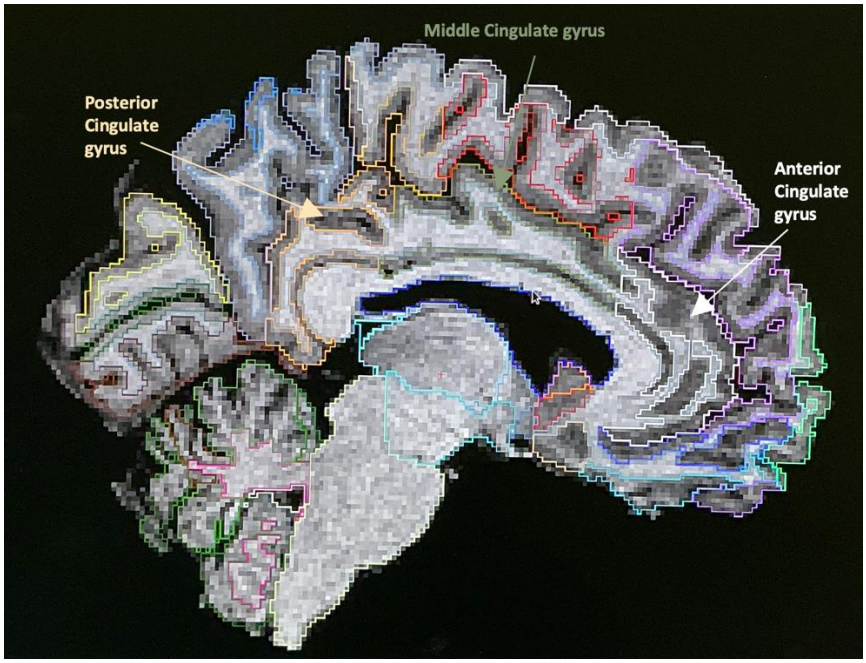


    - Axial – Best for cortical folding and surface structures

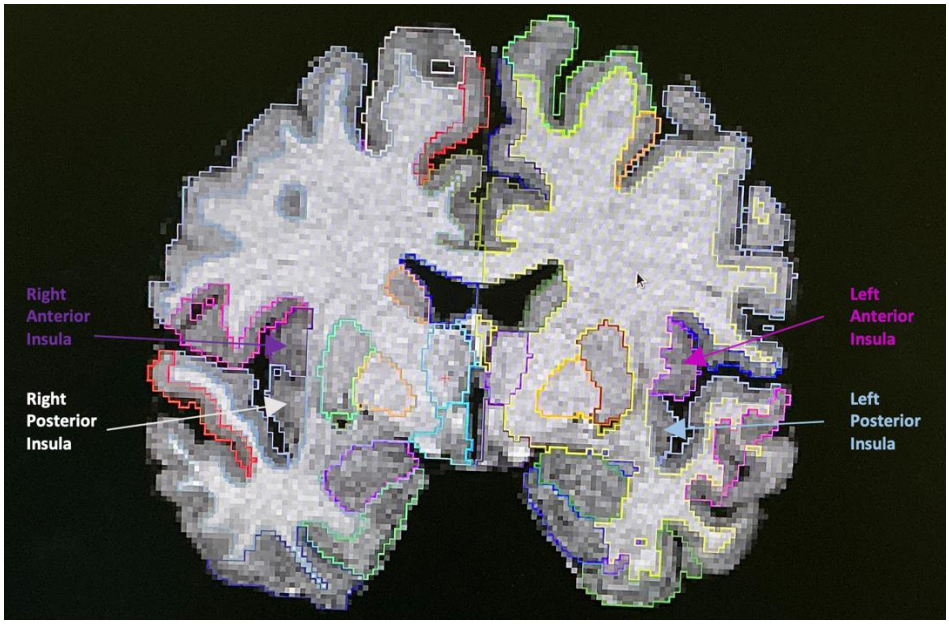


- Coronal (Horizontal) – Best for subcortical ROI evaluation (e.g. thalamus, basal ganglia). Also enables to view the ROIs in both hemispheres simultaneously.

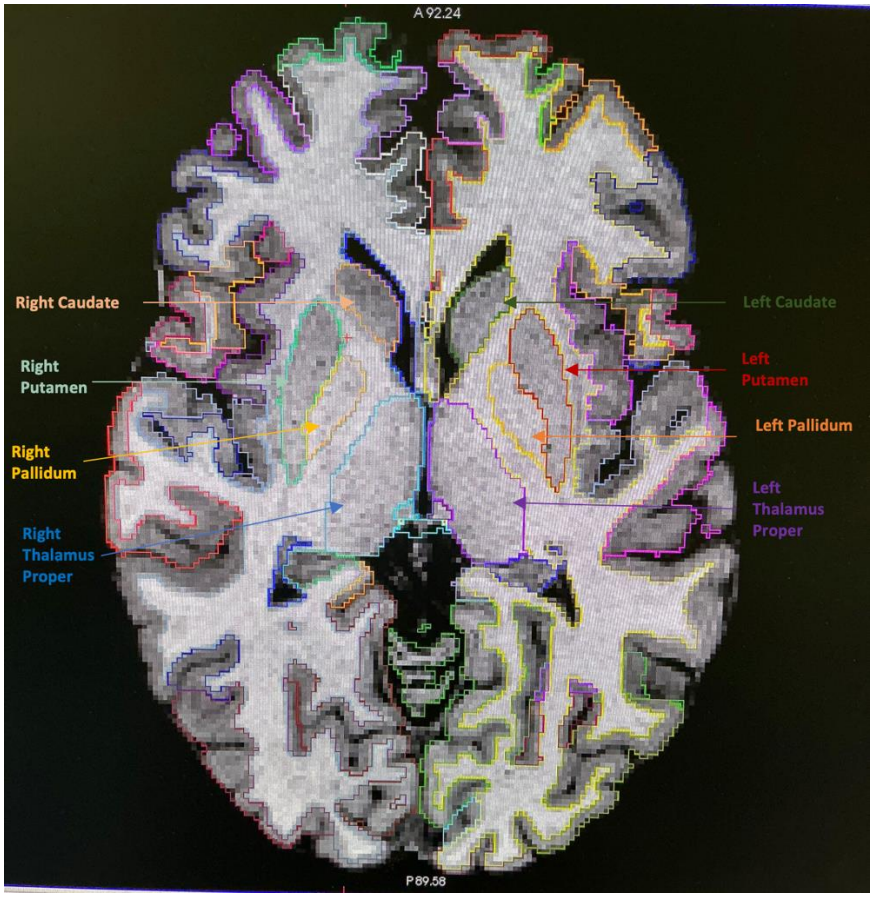


All three planes are viewed simultaneously in Freeview to enable cross-verification and reduce plane-specific misjudgements.

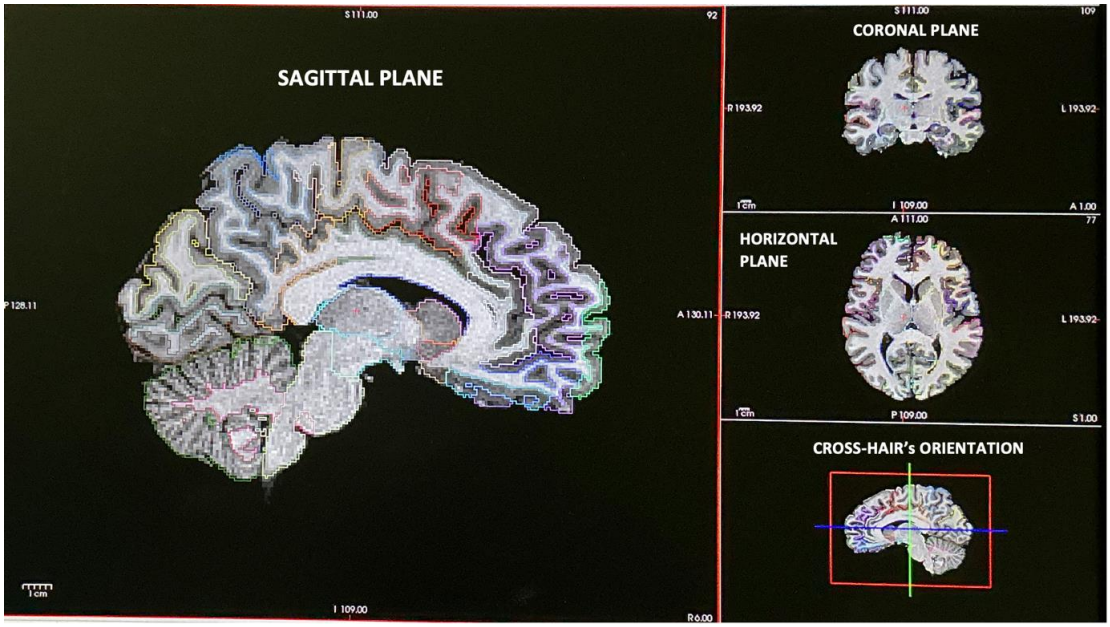


- To streamline the QC process and ensure organized navigation through 132 ROIs, segmentations are reviewed in functional groups based on anatomical lobes:
  - **Frontal Lobe**: Includes superior, middle, and inferior frontal gyri, orbitofrontal cortex, and medial regions.
  - **Parietal Lobe**: Includes postcentral gyrus, praecuneus, and supramarginal gyrus.
  - **Temporal Lobe**: Includes superior/middle/inferior temporal gyri, hippocampus, fusiform gyrus.
  - **Occipital Lobe**: Includes calcarine cortex, cuneus, lingual gyrus, and lateral occipital areas.

  Subcortical structures (e.g., basal ganglia, thalamus, brainstem, cerebellum) are grouped and reviewed separately from cortical lobes, with specific visual strategies.

- Cerebral white matter regions of interest (ROIs) were loaded individually to ensure a clear and detailed assessment for grading purposes.

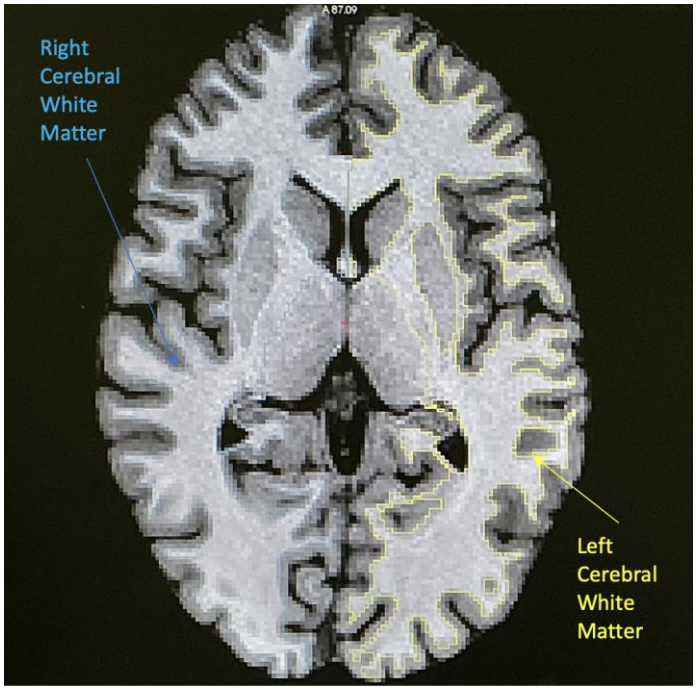


- The middle temporal gyrus ROI did not load in Freeview due to technical issues. Consequently, individual probabilistic heat maps were used to evaluate the ROI quality across all participants, applying a threshold range from 0.5 to 1.

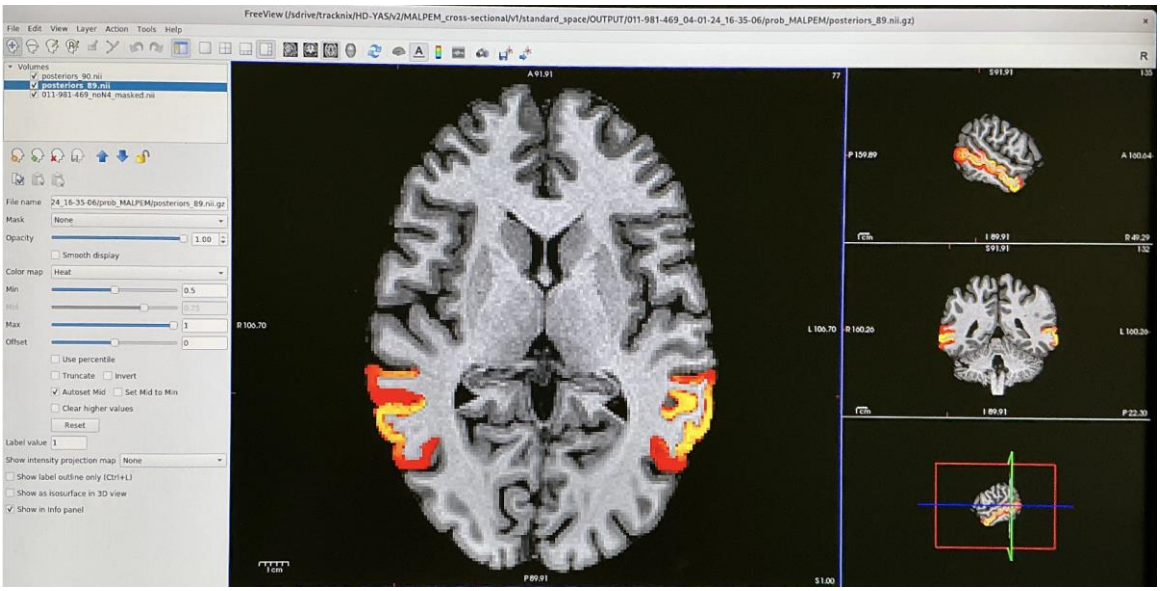

**Grading and Review of ROIs:**

The ROIs will be initially graded according to the following classification scheme to determine their suitability for inclusion in statistical analysis:

| Grade | Score | Peer Reviewed | Used in Statistical Analysis | Description |
|---|---|---|---|---|
| **Fail** | 0 | No | No | Significant errors in ROI delineation. This includes *gross segmentation errors*, *pipeline failure*, or *extreme misregistration*. These images are not usable in their current state. |
| **Borderline-Fail** | 1 | No | No | The ROI is consistently too tight or too loose across slices, or there's moderate misregistration. Errors are noticeable but not catastrophic. Needs revision before inclusion. |
| **Borderline-Pass** | 1 | Yes | Yes | Minor issues with ROI boundary (e.g., slight over/under-segmentation), but generally acceptable for analysis. Documented and reviewed. |
| **Pass** | 2 | Yes | Yes | The ROI segmentation is accurate with no significant issues. Fully suitable for statistical analysis. Peer-reviewed and quality-checked. |

| KEY | | | |
|---|---|---|---|
| SCORE | RATING | COLOUR CODE | ANALYSIS INCLUSION |
| 0 | Fail | | Excluded from analysis |
| 1 | Borderline Fail | | Excluded from analysis |
| 2 | Borderline Pass | | Included in analysis |
| 3 | Pass | | Included in analysis |

Any segmentation marked as *Borderline* will undergo a secondary review by a second rater (either Rachael or Nicky) to resolve ambiguity. This review will take place **prior to data extraction or plotting**, ensuring that only high-confidence segmentations are carried forward for analysis.

Fail ROI

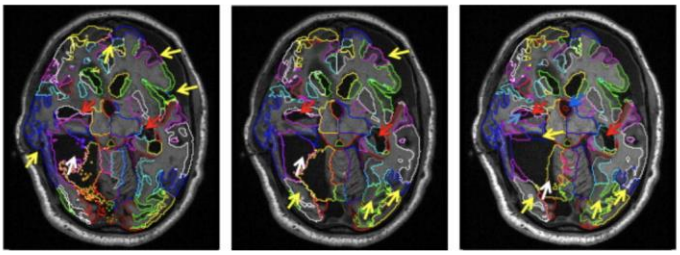

Download: Download high-res image (656KB)
Download: Download full-size image

Fig. 1. Example of segmentation results obtained on a subject with highly abnormal brain configuration. Segmentations calculated with MAPER using majority voting (left, Heckemann et al. (2010)) and SyN (Avants et al., 2008) from the ANTs toolkit using either majority voting (middle) or the joint label fusion (right, Wang et al. (2013)). Red arrows: substantial oversegmentation of the hippocampus; yellow arrows: inaccurate cortex segmentation due to gross brain deformation; blue arrows: ventricles incorrectly labelled as background; white arrows: region of missing tissue prohibits reasonable one-to-one mapping of the atlases. Segmentation contours are shown in a colour scheme that provides good colour contrast between neighbouring structures. (For interpretation of the references to colour in this figure legend, the reader is referred to the web version of this article.)

**Comment Section for Justification:**

A comment section will clearly document the rationale for excluding any data points or note any observed patterns, supporting transparency and traceability.

**Outlier Detection and validation:**

- **Volumetric outlier detection** will be performed by plotting ROI volumes across the cohort to visually identify extreme values.
- The **top and bottom 2%** of volumetric values—particularly for key regions like the **caudate** and **putamen**—will be **reviewed**.
- These segmentations will be **compared with a randomly selected reference subject** to validate segmentation quality, confirm dataset consistency, and ensure the absence of systematic bias.
- This QC process will be conducted **prior to statistical analysis** to ensure that only high-quality data contributes to effect size estimation.

**Ongoing Observations and trends in QC**

1. **Cerebellar structure**

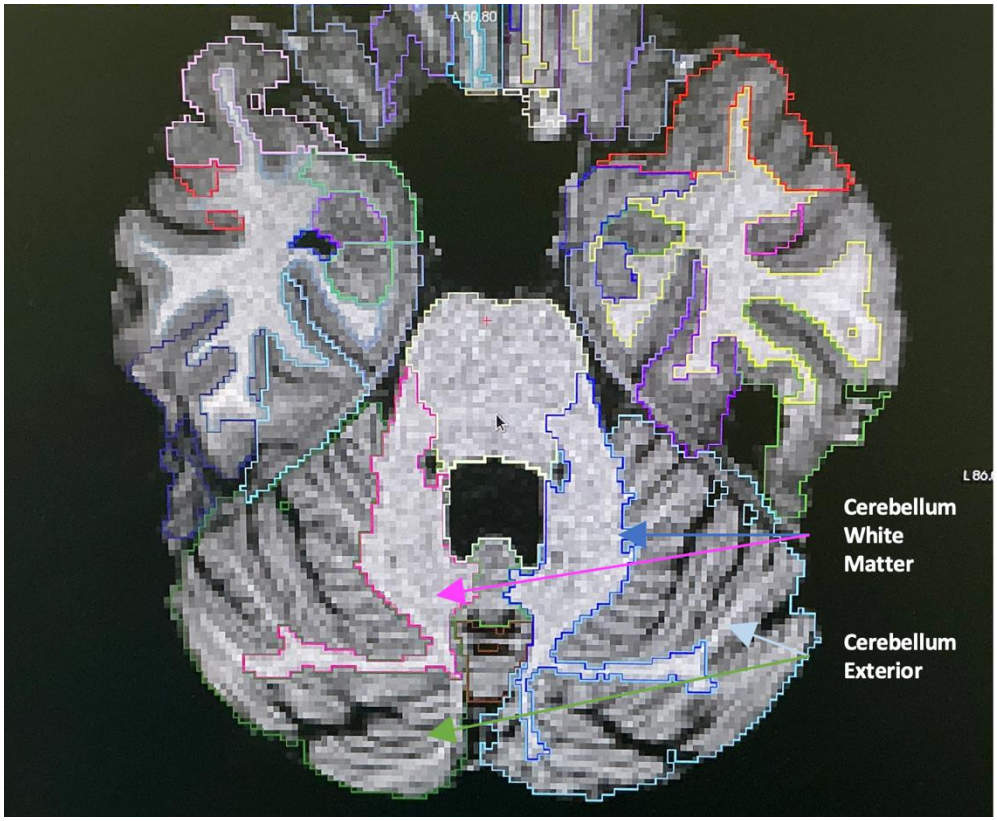


- **Cerebellar white matter**
  - Segmentation generally appear tight-fitting, closely aligning with the central white matter core.
  - However, due to the limited spatial resolution of the scans, finer white matter branches and arborized extensions into the folia may be underrepresented.
  - This could lead to a slight underestimation of total cerebellar WM volume, especially in highly folded posterior regions.
- **Cerebellar grey matter**
  - Segmentation sometimes include cerebrospinal fluid (CSF) within deep sulci between folia, due to partial volume effects and insufficient boundary resolution.
  - This can result in overestimation of grey matter volume, particularly in posterior lobe regions where the sulcal depth is greater.

2. **Occipital lobe – notable underfitting**
   - ROIs for calcarine cortex and lingual gyrus in the occipital lobe are consistently underfitted:
     - Boundaries do not fully encompass the expected anatomical extent, particularly at medial and inferior aspects.
     - This may be due to difficulty in segmenting areas with cortical folds or low tissue contrast near the midline and ventral surface.
     - These regions are flagged for further evaluation.

RIGHT CALCARINE CORTEX

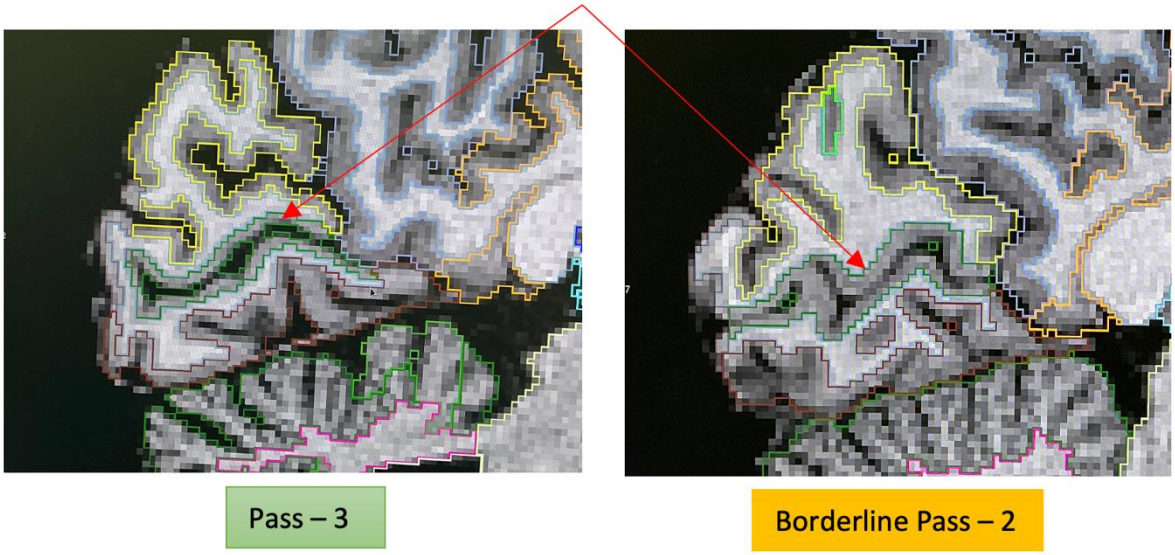


3. **Frontal, Temporal, and Parietal Lobes – high quality**
   - ROIs in these lobes—including the superior frontal gyrus, temporal pole, and inferior parietal lobule—tend to be well-aligned with cortical landmarks.
   - Segmentation outlines conform closely to grey-white boundaries with minimal CSF leakage or boundary ambiguity.
   - Consistent accuracy across participants supports reliable volumetric analysis in these regions.
4. **Subcortical/Deep Grey Matter Structures**
   - The segmentation quality of subcortical regions are good as the overlay adhere well to anatomical landmarks.
   - Some ROIs in these regions exhibit black voids, which are likely due to the presence of perivascular spaces
   - These voids are especially visible in inferior axial slices (e.g. slices ~ 90-92), most notably in the palladium, putamen and thalamus
   - In some cases, the ROI appears to terminate prematurely on one hemisphere, despite being clearly visible and complete on the contralateral side.

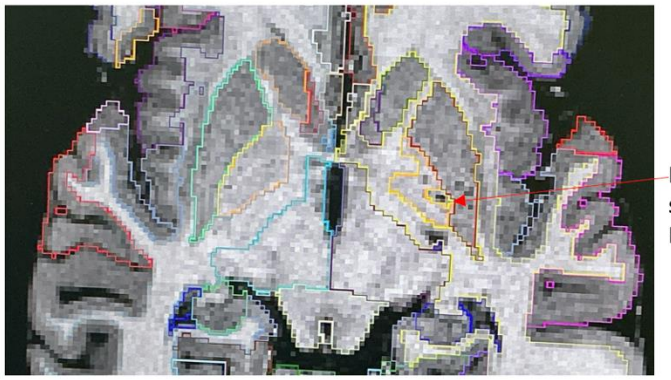

Perivascular space in Palladium

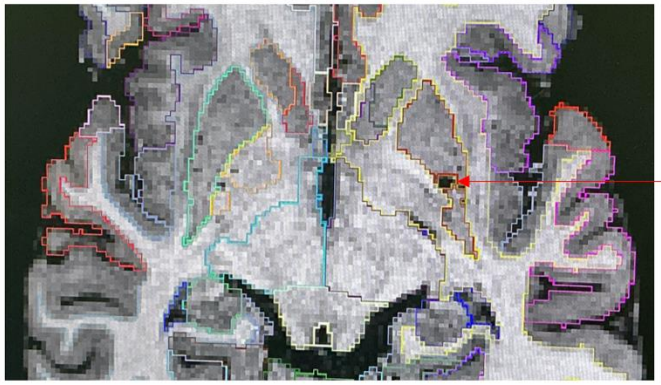

Perivascular space in putamen

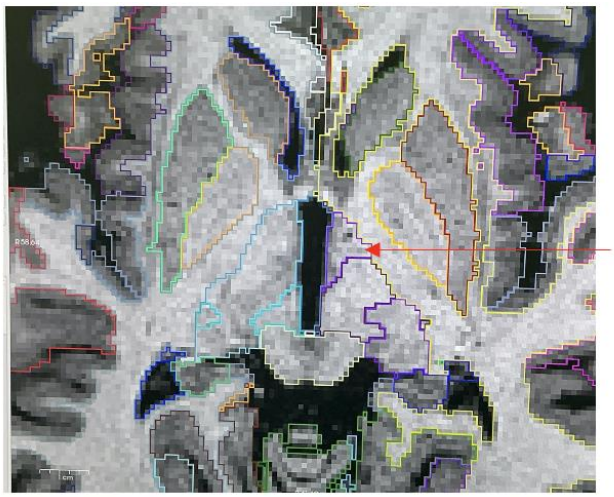

Perivascular space in Left Thalamus Proper

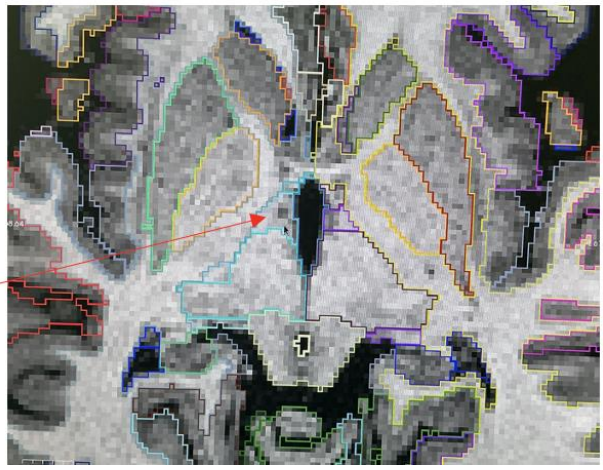

Perivascular space in Right Thalamus Proper

- It is essential to assess each ROI **across adjacent slices** to determine whether segmentation anomalies (e.g., underfitting or overfitting) are isolated or resolved in neighbouring slices.
- An ROI may appear to include excess CSF in one plane, but if this is corrected in adjacent planes (e.g., more accurate boundaries in superior or inferior slices), it may still warrant a **"Pass" (Score 3)**, based on overall **3D anatomical integrity**.
- Conversely, if the anomaly persists across multiple planes and slices, it should be rated as **"Borderline Pass" (Score 2)** or lower.

**Segmentation Trends in Subcortical Structures**

- **Caudate nucleus**
  - Exhibits clear GM-CSF and GM-WM boundaries.
  - Enables reliable and reproducible segmentation.
- **Putamen**
  - Shows a continuous GM-WM boundary, which is slightly less distinct than the caudate
  - Still demonstrates sufficient contrast for relatively accurate segmentations.
- **Thalamus and Pallidum**
  - Has poor GM-WM contrast on T1-weighted MRI
  - Less distinct boundaries make it more difficult to segment reliably but the software has done quite a reliable job in generating these segmentations based of it anatomical landmarks for example
- How well-defined the regions are will have an impact on the reliability and accuracy of the segmentations.

- **Perivascular spaces (PVS)** are typically more prominent in deep GM regions such as the basal ganglia which includes the caudate, putamen, pallidum and thalamus where they've been observed. Although PVS may cause some errors with segmentation, but no gross error was observed in the ROIs pipeline/map since they

were mostly observed in the inferior slices (~ 85 to 90) where boundaries between the structures are harder to distinguish.

- **Using binary and probabilistic outputs for segmentation assessment –**
    - The *_MALPEM.nii file contains all regions as binary masks generated by MALP-EM, which are images where each voxel is either inside or outside a ROI, that is each voxel is assigned a value of 1 (belongs to the ROI) or 0 (does not belong). This gives a clear-cut, yes/no segmentation.
        - This file serves as a practical too for assessing the overall quality of the segmentation in one place.
    - However, since our volume estimates are based on probabilistic segmentations, it is also important to examine the corresponding probabilistic maps.
        - These maps assign each voxel a probability value (between 0 and 1) representing how likely it is to belong to that ROI.
        - This reflects uncertainty or partial volume effects, meaning some voxels might partly belong to multiple regions.
        - These maps provide additional information by showing how different voxels contribute to the final volume estimates based on their probability values.
        - These details are not visible in the binary *_MALPEM.nii file
        - This is particularly helpful for understanding partial volume effects and refining interpretations of the segmentation output.

- **Visual QC trends observed**
    - **Cerebellum**
        - Visual inspection of the binary regions highlighted a tendency for the cerebellar GM region to be slightly loose for all the participants, which would result in an over-estimate of volume.
        - Similarly, the WM regions appeared tightly fitted across all the participants, which would likely lead to an under-estimate of their volumes.
        - This was further investigated by looking at the probabilistic maps of the WM and GM regions to further investigate these trends.
        - Two different threshold ranges were tested to improve ROI accuracy, one with a more lenient range (minimum reduced from 0.5 to 0.05, maximum at 1), and another with a more stringent range (minimum increased to 0.9, maximum at 1); however, neither adjustment resulted in a significant improvement in the ROI output.
        - These findings highlight a limitation of the technique, likely driven by the cerebellum's intricate and tightly folded anatomy. The dense foliation of the cerebellar cortex increases the likelihood of partial volume effects, making accurate segmentation particularly challenging in this region.

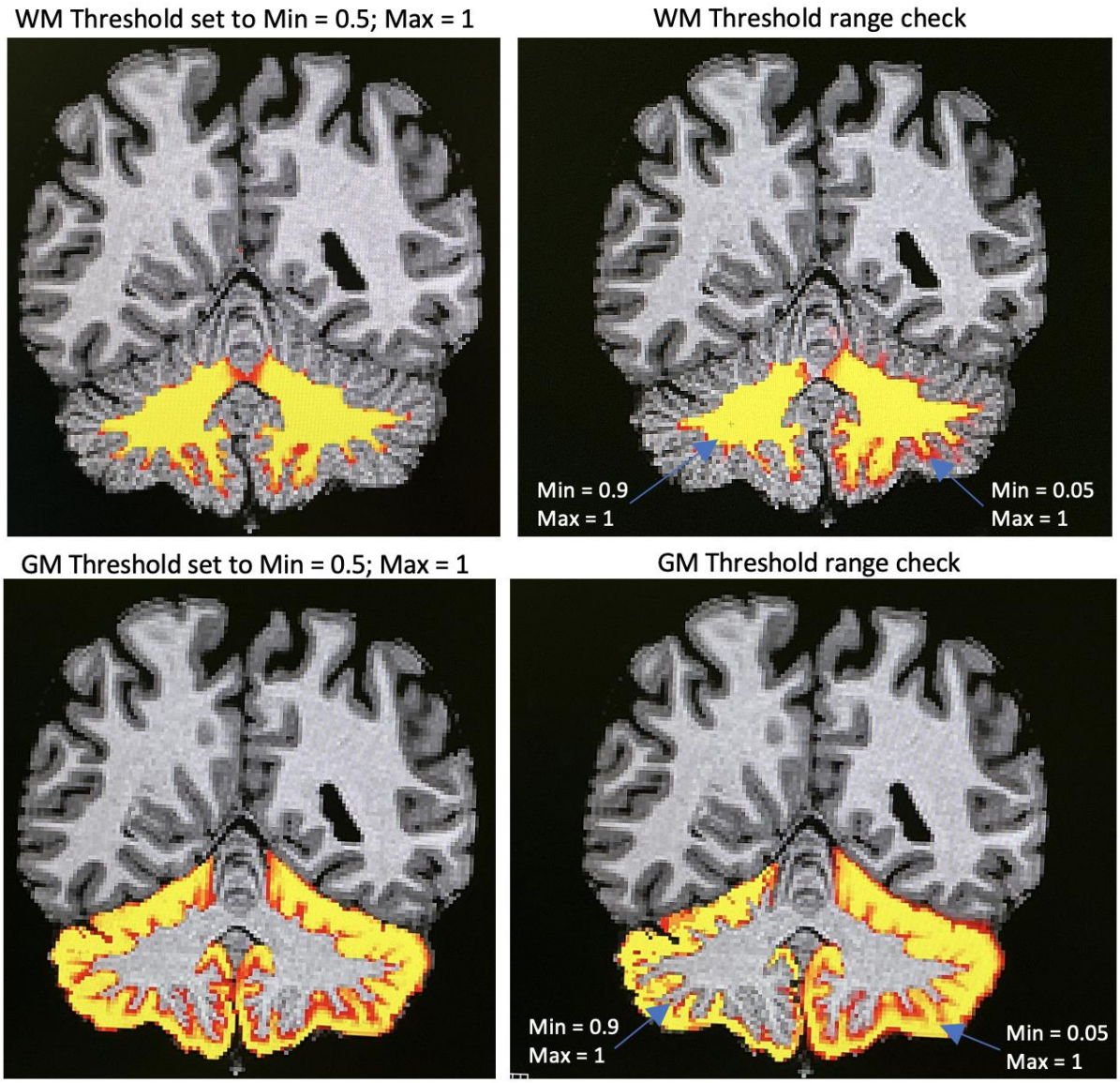


- **Asymmetrical brain**
    - Two datasets of note included one where the participants had enlarged ventricles (Figure ) and another where the participant had relatively pronounced asymmetry (Figure ).
        - However, visual inspection of the MALP-EM ROIs showed that the segmentations were of high quality, that is, similar to those generated on the other datasets. This is confidence inducing and supports the robustness of the technique given the fact that this software was developed and validated for use in populations with traumatic brain injury (TBI), where anatomical variability is common (Ledig, 2015 paper).

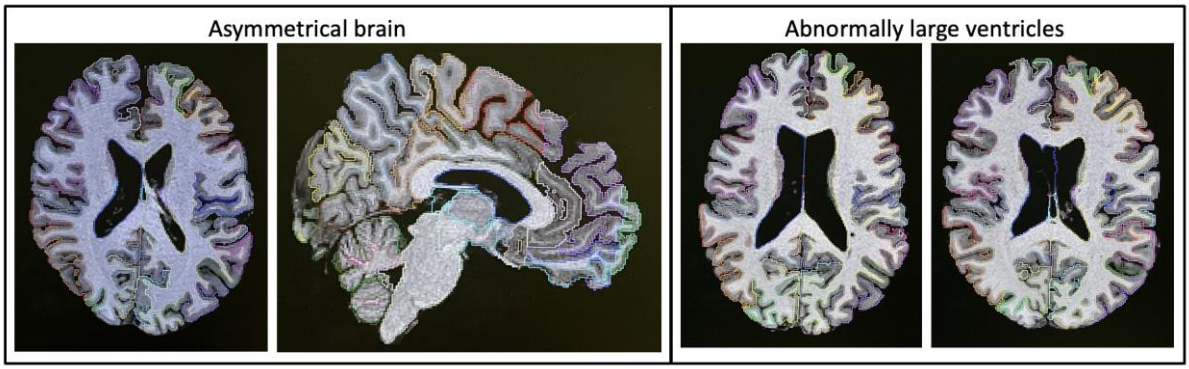

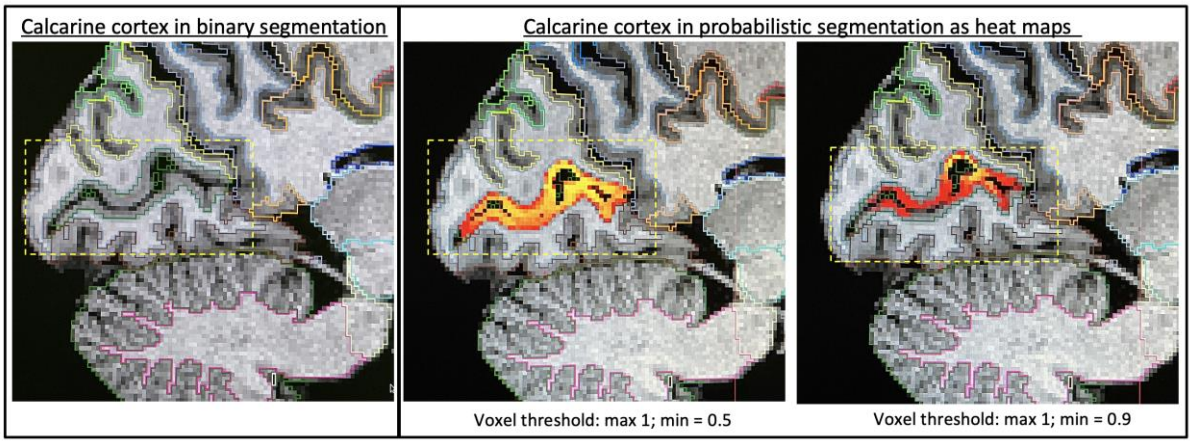
- **Is volume change of a specific brain region a suitable biomarker of disease progression –** as it is a function of the underlying pathology of the disease, combined with the reliability and the sensitivity of the measurement technique applied.
    - A significant trend that was observed was the impact of atrophy (eg. Tissue shrinkage due to disease) and how it influences partial volume effect, that is, where a voxel contains a mix of tissue types (eg. GM and CSF) particularly in the regions like the calcarine cortex and lingual gyrus in the occipital lobe
        - Atrophy appears to reduce partial volume effects, which is more noticeable when using binary segmentation. When using binary segmentations (where each voxel is either fully included or excluded from the region), this effect appears more accentuated – meaning the chnages caused by atrophy can lead to abrupt misclassification of voxels, exaggerating the apparent volume loss.
        - In contrast, this effect is less pronounced when using probabilistic segmentations, as it assigns each voxel a likelihood of belonging to a region, which allows for a more gradual, nuanced measurement of atrophy. As a result, the effect of partial volume loss is less pronounced, giving a more sensitive and accurate picture of subtle structural changes.
        - The lingual gyrus exhibited a similar trend in segmentation characteristics.
        - This highlights the contrast between a step-change effect in binary ROIs versus graded response in probabilistic ROIs