

Review**Orofacial Pain**

DR.Litha, MDS; [1] DR, Vidya N, BDS, (MDS). [2]



Correspondence: Dr.Vidya N, Postgraduate Student,
Department of Oral Pathology and
Microbiology, Farooqia Dental College and Hospital,
Mysore, Karnataka, INDIA. drvidya.aradhya@gmail.com

1. Reader,
2. 2nd-year Postgraduate Student,
1 and 2, Department of Oral Pathology and Microbiology,
Farooqia Dental College and Hospital, Mysore,
Karnataka, INDIA

Keywords: Orofacial pain, Burning mouth syndrome, Trigeminal Neuralgia

ABSTRACT

Background and Setting: Oral health influences general health that in turn improves the quality of life. It is said to be a state where a person is free from oral infection and sores, tooth decay, oral and facial pain, oral and throat cancer, tooth loss, periodontal disease, and other disorders and diseases that restrict an individual from speaking, smiling, etc. and even affecting his psychological state.

Orofacial pain in its comprehensive cataloguing can affect up to 7% of the people. The responsibility of early diagnosis and managing it lies on the doctors, dentists and those who belong to the minor care segment, like the oral physicians, pain physicians, and headache neurologists. Facial pain is usually chronic and similar to the other chronic pain and is commonly associated with a large number of co-morbidities and treating it would involve the treatment of associated conditions such as the anxiety, depression, and the presence of other chronic pain; which must be attended to; as a part of management. Though the majority of chronic pains are continuous, there are some that are intermittent. Most of the pain is intraoral, and among them; odontalgia and burning mouth syndrome are common; whereas many of the pain could manifest both intra and extra orally. Among the extra oral pain, the most common are the musculoskeletal pain, in relation to the muscles of mastication, which may

be associated with disc problems. Neuralgias include the trigeminal neuralgia, and the less common glossopharyngeal neuralgia, having well-defined care pathways. Trigeminal neuropathic pain may also be caused by trauma; and may be secondary to such conditions as infection, malignancies and auto-immune diseases. The condition is normally managed along the lines of other neuropathic pain; by using the commonly used drugs besides the psychological support. If the type of pain cannot be categorised as occurring due to any specific cause, then a diagnosis of insistent or chronic idiopathic facial pain is made and the treatment given, may include a combination of cognitive behavioural therapy and antidepressants. A multidisciplinary team should be the one normally managing the facial pain. In order to establish an accurate diagnosis a thorough knowledge of a wide spectrum of diagnostic characteristics of orofacial pain which includes the source and type of pain (psychogenic, somatic and neurogenic); period (acute or chronic); and how the pain originated (nociceptive, psychosomatic and neuropathic); and their differentiation. This article stresses on the most common painful conditions of oral mucosa, their clinical manifestations and treatment.

INTRODUCTION

Pain is ,An unpleasant sensory and emotional experience associated with actual or potential tissue damage, or described in terms of such damage'. [1] Pain of the oral mucosa is co-associated with multiple lesions of the oral mucosa, caused by local and systemic diseases. It is usually associated with a known cause of tissue damage, e.g. an erosion or mucosal ulcer, off which some may be caused by physicians, e.g., Medications, trauma following surgery, or after radiotherapy to the head and neck; and responds mostly to treatment; which disappears after healing. Chronic pain lasts much longer and continues for months or years after the causative factor has healed, and attempts to eliminate this pain is challenging. Patients with intermittent or persistent, painful sensations in the oral mucosa often represent a substantial clinical challenge with regard to diagnosis and management. [2]

The oral cavity is thickly innervated as compared to the other parts of the body and has an elaborate sensorimotor presence in the central nervous system (CNS). This rich somatosensory supply controls the eating, swallowing, drinking, and speaking, and also a large number of oral sensations, including, pain. [3]

Physiology of Pain

Noxious stimuli in the orofacial region depolarize the high threshold free nerve endings: A δ (thinly myelinated) and C-fibers (unmyelinated); that may further be sensitised and excited by a large number of chemicals such as prostaglandins, histamine, bradykinin, substance P, etc. The fibers transmit the nociceptive stimuli along the trigeminal pathway to primarily synapse with the second-order neurons (nociceptive specific and/or wide dynamic) located in the caudalis nucleus of the trigeminal spinal tract within the brain stem. These signals are subjected to modulation here. It undergoes further modulation when the second-order fibers cross the midline, and climb the synapse in the thalamus, and plays a role in the perception of pain. Finally, the noxious impulse is directed to the somatic sensory areas of the cerebral cortex, where determination and discrimination of the nociceptive stimulus are intensified. This stimulus under the influence of cognitive behavioural and affective motivational factors: past experiences etc., is interpreted; hence, pain is understood as a complex mixture of sensory, cognitive

and affective process, making it "personal experience" for each. [2]

Oral mucosal pain may also manifest in the absence of any visible pathology or reason as in the case of a previous trauma and is termed idiopathic pain.

Pain is a multidimensional subjective experience, and more than just tissue damage, it contributes to the patient's expression and rating of pain response. Patients state that their oral pain is unbearable, yet may present with only very mild or clinically, barely evident mucosal changes. On the other hand patients with severe, extensive mucosal lesions report minimal oral pain and can function normally. The reaction of different people exposed to the same stimuli to pain is different, and it has been seen that some people are less sensitive to pain than others, which can further be elaborated by a recent scientific discovery.

Nature Medicine has cited a major new discovery into the molecular mechanisms of pain. A "pain gene" that explains why certain individuals are less sensitive to acute pain and less likely to develop chronic pain has been unearthed. The relevant gene that is affected is called GCH1, which encodes for GTP cyclohydrolase an enzyme. This enzyme initiates the production of a chemical called tetrahydrobiopterin or BH4. They found that a pathway that produces BH4 was significantly activated during pain-states. When the researchers' inhibited BH4 production in experimental models the pain was relieved; whereas the administration of BH4 produced pain. The authors also identified a connection between people carrying a mutation in the human gene responsible for BH4 production and reduced pain sensitivity. Twenty to twenty-five percent of the population have at least one copy of this pain protective form of the gene where as 3% of those who carry 2 copies of the gene undergo a significantly less pain after for, e.g., A disc surgery; than those having a single copy. Administering inhibitors of GTP cyclohydrolase (the critical enzyme in BH4 production) to reduce the elevated BH4 levels in pain conditions, could mimic the effects of the pain protective function of the gene and lead to a disease;-modifying the pain therapy. Therefore this data also suggests that individuals who say they feel less pain are not just stoics but genuinely have inherited molecular machinery that reduces their perception of pain. This

difference results, not from personality or culture, but real differences in the biology of the sensory nervous system. [5]

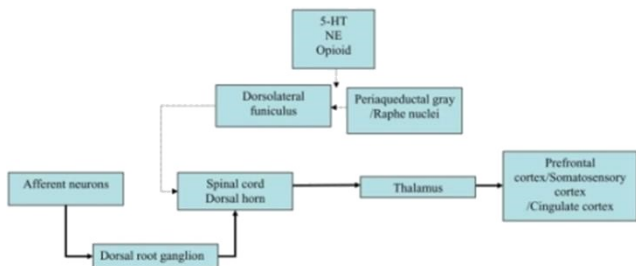


FIGURE 1: Circuit of pain modulatory pathway. Abbreviations: 5-HT, serotonin; NE, norepinephrine. Thick arrow indicates ascending pain pathway, and the thin arrow represents descending inhibitory pain pathway.

Courtesy: Marks DM, et al. - *Curr Neuropharmacol* (2009)

Review

Agarwal et al., in a population-based study in the UK, using a postal questionnaire, looked at frequently unexplained pains and found that 7% of patients reported having a chronic oro-facial pain; 15% reported chronic widespread pain, 8% chronic fatigue and 9% had the irritable bowel syndrome. Of these, 9% reported more than one of these pains. A German population study and another one from Netherlands using strictly defined criteria by headache neurologists found that the trigeminal neuralgia is commoner than persistent idiopathic facial pain, but both were rare with a lifetime prevalence (0.3%) of trigeminal neuralgia versus 0.03% for persistent idiopathic facial pain. Koopman et al. found an incidence rate of 38.7 per 100,000 people. The diagnosis was validated by pain experts as they found up to 48% had been misdiagnosed by the primary care physicians. Trigeminal neuralgia and cluster headaches were the most common types and the temporomandibular pain and muscle disorder-type pain (TMD) were also found to be common; population-based studies among adults reported that approximately 10–15% have these disorders.

When making a diagnosis, it is useful to make the distinction if the diagnosis is definite, possible or even probable; as this allows for a change in diagnosis, once number of facts comes to light.

Type and causes of non-dental chronic oro-facial pain

Benliel et al. showed in their clinic population of 328 patients, that, chronic

oro-facial pain could be defined in the same way as a chronic daily headache but stresses that chronic oro-facial pain includes a very heterogeneous group of symptoms. Conditions that can result in neuropathy include autoimmune disorders, for e.g. Systemic sclerosis, trauma, Sjogren's syndrome, multiple sclerosis, sarcoidosis, rare vascular malformations, Lyme disease, neoplasia anywhere along the trigeminal nerve and infections such as syphilis, leprosy and viral, syphilis. (Table 1 and Table 2) [5]

DIAGNOSTICS OF ORAL MUCOSAL PAIN Diagnostic evaluation of patients with oral mucosal pain requires a careful and thorough medical and dental history, physical examination and the review of systems and functioning of the oral mucosa and surrounding structures with special examination of the temporomandibular joint (TMJ) and muscles; and the cranial and cervical muscles and nerves.

In the case of pain, it has been found that the history taking is most important part of the diagnostic procedure based on which the diagnosis and treatment are planned.

They include information about:

- Origin of pain,
- Time
- Location and intensity,
- Type of tissue affected by pain and its etiology. [1] (Table 2)

An acute type of pain occurs in relation to the accidental injury, inflammation, or following surgery. Most conditions manifesting an acute pain can be treated, and usually, subside when healing of the tissue has taken place. Chronic pain remains for a longer period even after the apparent tissue has healed; and attempts to lessen pain are often futile. The chronic pain may also cause practical and physical alterations within the CNS. It is important that acute pain does not turn into a chronic pain condition which would impair the quality of life and result in depression. [3]

For the purpose of proper treatment, it is important to determine the duration of pain and distinguish acute pain from chronic. (Table 3)

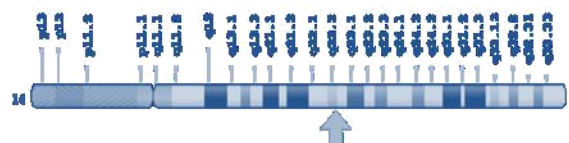
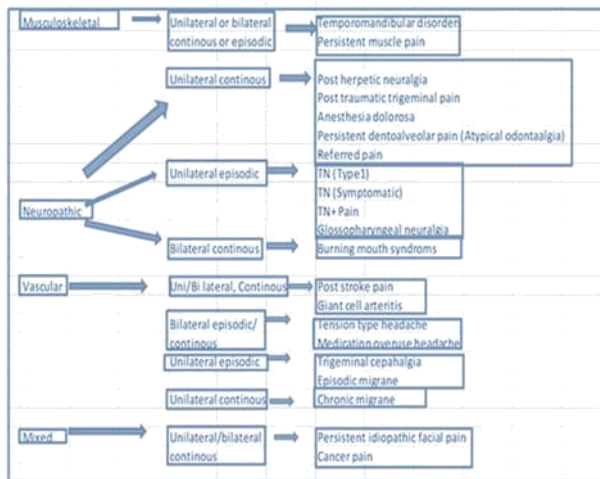


FIGURE 2: Chromosomal Location:-Cytogenetic Location: 14q22.2; Long (q) arm of chromosome 14 at position 22.2; (NCBI)

TABLE 1: Classification of Oro-facial Pain



PAIN CATEGORIES

Using information obtained from the diagnostic process, oro-facial pain can be classified

- By duration
 - o Acute and
 - o Chronic pain and (Table 3)
- by its origin into three basic categories:
 - o Somatic,
 - o Neuropathic, and
 - o Psychogenic pain.
 - o Vascular
 - o Mixed [4] (Table 1)

Dental pain

The most common cause of lower face pain is related to the teeth and their neighbouring structures. Given the high occurrence of chronic dental pain, it needs to be kept in mind while considering patients with other chronic pain especially those who report an alteration in their symptoms which does not arise from the main disease. (Discussed in Part II)

Temporomandibular disorders (TMD)

The TMJ pain may be musculoskeletal with its pain being felt in the retromolar area. TMD has been researched by dentists with a specific interest in facial pain. The Research Diagnostic Criteria (RDC) for TMD was published in 1992 has been used as a source for research globally. This will be discussed in Part II of this article.

Non-dental pain

There may be other causes of oral pain that are not related to teeth. These include oral mucosal lesions such as (RAU) recurrent oral ulcerations, blistering conditions, and lichen planus that cause

chronic pain but whose manifestations are very standard and diagnosis is easy. Another common cause of oral pain is the salivary stone that causes sporadic pain of relatively low intensity, and which commonly occurs when eating; or at the thought of food.

Pain may sometimes be due to nerve damage, and in some cases, it remains impossible to determine the cause of the pain. To solve the confusing nomenclature regarding the oral pain, recently, a group of experts from the international community suggested the use of the term 'insistent dento-alveolar pain disorders' to include all conditions that cause persistent pain without the presence of any local disease (other names include phantom tooth pain or atypical odontalgia). When it has been attempted to understand the patients' experience of pain, some common excuses have emerged e.g. complex description of the pain, difficult to obtain a clear history, and presence of well localised deep pain. [6]

Atypical odontalgia

In a typical odontalgia, the location of the pain is adjacent to the dentoalveolar structure; either in relation to existing teeth or at a site where they have been extracted. [7] It may arise either before or after the dental treatment. The pain may be itinerant and may be a dull, throbbing; continuous pain which may exacerbate. It is provoked when touched even lightly. Baad-Hansen postulated that it is most likely to be a neuropathic pain that has different features from TMD.

Treatment

- Drugs for the same may be both topical and systemic. If the pain is localized to a peripheral origin, the diagnostic block gives an ambiguous response; but whenever there is a decrease in pain, a topical drug may be used, and a neurosensory stent can be fabricated. [5]
- Systemic drugs such as tricyclic antidepressants, sodium channel blockers (carbamazepine), calcium channel blockers (gabapentin and pregabalin), and topiramate an antiepileptic topiramate, can be used for the management of this condition.
- The management of AO is very challenging, and a multidisciplinary approach is necessary. [2]

Burning mouth syndrome/ glossodynia, stomatodynia [3]glossopyrosis, glossalgia, stomatopyrosis, and oral dysesthesia.[2] This is an intraoral condition affecting exclusively the oral cavity; that presents with a burning discomfort of the oral

mucosa; [8] especially the tongue; and no [3] discernable medical or dental causes have been found. Its prevalence ranges

from 0.7 % to 4.6 %; which increases with age;

	Post-traumatic trigeminal neuropathy	Buring mouth syndrome	Trigeminal neuralgia	Persistent idiopathic facial pain	Trigeminal post-herpetic Neuralgia
Epidemiology	Common	Rare	rare	Rare	Rare
Onset	3-6 months after the traumatic event	Slow	Sudden	Slow	slow post-herpes zoster
Character	Dull, tingling, burning, pins and needles. At times sharp	Burning, stinging, sore	Sharp shooting	Dull, nagging, sharp pain	Burning, pins and needles feeling
Duration	Continuous with minor fluctuations; in some sporadic episodes	Continuous	Intermittent; seconds to minutes, Sudden	Constant	Constant
Severity	Moderate to severe	Mild to severe	Moderate to severe	Moderate to severe	Moderate to severe
Site	Along a nerve branch, tooth or tooth socket	Tongue, lips, palate	V2, V3 most common intraoral and extra orally	non anatomical gradually gets larger	anatomic distribution, most common ophthalmic branch
Radiation	None	Entire oral mucosa	only within the trigeminal distribution	can spread over whole face, head,	little
Periodicity	Constant	Can vary throughout the day	Refractory periods	Varies. With periods of no pain	May be exacerbations
Aggravating factors	touch	sometimes certain food,	feather touch, eating, some attacks are instant	tiredness, strain	mild touch,
Accompanying factors	may be reduced sensation, and poor quality of life, dental treatment or trauma	altered taste, dry mouth, depression, anxiety, poor quality of life	very rare autonomic features, fear of pain return, depression, poor quality of life	often other chronic pain, significant life events, vulnerable personalities,	may be altered sensation, skin changes
Examination	allodynia, hypoesthesia	nil, sometimes geographic	may initiate an attack on mild touch, very	n	hypoesthesia,

		tongue	rarely sensory changes		allodynia, hyperaesthesia
Management	drugs for neuropathic pain benefits from CBT	neuropathic drugs, clonazepam, CBT	carbamazepine or even oxycarbazepine	CBT, antidepressant drugs	pregabalin, gabapentin, nortriptyline, lidocaine patches.
CBT cognitive behaviour therapy.					

TABLE 2: The main characteristics of the most common chronic non-dental pains and their management

ACUTE PAIN	CHRONIC PAIN
<ol style="list-style-type: none"> 1. Acute pain is almost always associated with a known cause of tissue damage following exposure to local irritation, local injury, infection or inflammation and exacerbation due to the presence or due to an underlying systemic disease. 2. Acute pain commonly disappears after removing the aetiology; it has primarily a biological purpose; therefore being considered as a "good" pain; serving as a warning sign or as a protective mechanism 3. Acute pain normally responds to the common medical and dental treatments 4. Acute pain is a manifestation of an illness, and 5. Treatment for both pains varies and may sometimes even be contraindicated 	<ol style="list-style-type: none"> 1. Acute pain may become chronic if not attended to, on time. 2. Pain is considered chronic when it lasts longer than 3 months, and persists even after the stimulus is removed. 3. Chronic pain, is continuous, has no biological purpose and it is not self-limiting. 4. Chronic pain represents disease of itself

TABLE 3: Differences between acute and chronic oral pain

highest in women (12%) in the age range 60-69 years. [5] It is said to be related to anxiety and depression and is especially common in post-menopausal women. Involvement includes the anterior part of the hard palate, tongue, and the lips are the most frequently affected. Pricking, tingling, itching, annealing to paresthetic sensations are experienced.

Pathophysiology of BMS

- Disturbances in the somatosensory system especially in the small fibres of the trigeminal nerve are thought to be responsible for the pathophysiology of primary BMS. Others have reported evidence for chorda tympani hypofunction in BMS.

- CNS pathology also seems also seems to play a role in the generation of BMS symptoms. Cerebral reorganisation showed an altered grey and white matter volumes and disturbed functional connectivity patterns in BMS.
- A decline in endogenous dopamine levels has been suggested to be another cause for BMS, causing deficiencies in central pain modulation. [2]

Causes of burning mouth. [5]

Xerostomia is predominantly seen with disturbances in taste: phantom tastes, taste perception and/or dysgeusia (usually bitter or metallic). [2]

Treatment

Management is initiated by accepting the symptoms as real and convincing the patient that it is a common yet rare condition,

- Cognitive behaviour therapy has shown desired results and is the mainstay management
- Clonazepam as a topical and systemic agent has received mixed reviews and exhibits significant side effects of

drowsiness. The chances for addiction need to be prevented.

Several RCTs have been suggested such as the:-

- Use of alpha-lipoic acid, an antioxidant, but the outcomes are controversial.

Since this condition is mainly a neuropathic pain, drugs for neuropathic pain.

TABLE 4: Most common etiologic factors in burning mouth syndrome

Local factors	Systemic factors	Psychological factors	Idiopathic factors
Poorly fitting dentures	Endocranial disturbances (Anxiety	
Parafunctional habits	hypothyroidism, diabetes mellitus,	Depression	
Dental anomalies	menopause	Compulsive disorder	
Contact allergic reactions	Deficiencies (Fe, Vit B complex,	Psychological stress	
Infection	zinc)	Cancerphobia	
Chemical factors	Anemia		
Galvanism	GI reflux		
Taste alterations	Eosophageal reflux		
Xerostomia	Medication		
	Neuropathy		
	Sjogren's syndrome		

- e.g. tricyclic antidepressants, gabapentin, pregablin can be tried.

There is little data on the prognosis.

Somatic pain

Somatic pain results from the toxic excitement of normal neural structures that innervate the affected areas and pain may be either superficial or deep somatic. Superficial somatic pain has a bright and stimulating quality, is primarily involved in acute painful conditions and usually does not exhibit any diagnostic difficulty. Numerous local and systemic factors can cause damage and consequently acute inflammatory reaction in the oral mucosa with the release of inflammatory substances, act, causing pain. The nature of painful symptoms depends on the type of stimuli, the extent and location of the injury, the injured tissue reactivity and stage of inflammation. Pain due to inflammation occurs mainly due to the action of histamine and bradykinins; substances that are released during inflammation; stimulate nociceptors and reduce their threshold. These substances together increase the local vasodilatation and capillary permeability, causing edema that mechanically stimulates receptors and causes pain. As the threshold of pain decreases, nociceptors become more sensitive to stimuli. As a result,

stimulus-induced primary hyperalgesia and spontaneous pain occur which has been classified as superficial somatic pain or mucogingival pain and occurs in the damaged oral mucosa. In contrast, deep somatic pain arises from damaged deeper body structure; has a dull, deep, depressing quality, and frequently exhibits CNS secondary excitatory effects such as referred pain to other sites and local autonomic effects (e.g., odontogenic pain, musculoskeletal pain), [2]

Mucositis vs Stomatitis

The terms stomatitis and oral mucositis are often used as synonyms, but their processes are not identical. Stomatitis is any inflammatory condition of oral mucosa as a consequence of local infections or injuries or underlying systemic diseases. Mucositis on the other hand and oral tissue damage can be a grave problem for patients undergoing anticancer therapy.

Oral Mucositis is the term used to describe inflammation of oral mucosa as a result of chemotherapeutic agents or ionising radiation. Mucositis can differ considerably with the dose and type of therapy. The pathophysiology of oral mucositis is said to be multiple. Mucositis is said to occur in 75-80% of

patients who needs to undergo high-dose chemotherapy before hematopoietic cell transplantation and in patients subjected to 22% of 1236 cycles of chemotherapy.

Mucositis manifest as painful ulcerations or erythema that appear 7 to 10 days after introduction of high-dose anticancer therapy. Mucositis may be aggravated by secondary infections and local factors. Infections may even cause life-threatening systemic sepsis when there is weekend immunity. Mucositis usually heals within 2 to 4 weeks after cessation of cytotoxic chemotherapy when uncomplicated by infection, while oral complications primarily are associated with discomfort and interference with oral function, and quality of life in patients who are also immune-compromised or debilitated, these complications can become life threatening. Thus, management of mucositis pain is the primary component of any mucositis management strategy. [2]

Neuropathic Pain without Visible Mucosal Lesion

Patients, who have no evident clinical lesions or pathological changes of oral mucosa and suffer pain, are the most difficult patients for treatment. In such cases, pain initiating from a structural anomaly in one or more elements of the nervous system that innervate the affected area; is therefore termed as neuropathic pain. The most common neuropathic pain syndromes in the orofacial region include trigeminal neuralgia; traumatic neuropathy; trigeminal neuroma; postherpetic neuralgia; diabetic neuropathy; cancer-related neuropathy, neuropathy induced by acquired immunodeficiency syndrome or AIDS; and chronic continuous trigeminal nociceptor neuropathy (with and without sympathetic mediation),

Acute herpetic neuralgia (AHN) and post-herpetic one commonly involve one of three divisions of the trigeminal nerve and involvement of the mouth is due to the maxilla and mandibular branch involvement. Virus reactivation in Varicella Zoster Virus (VZV) infection cause occurrence of vesicles on affected oral mucosa and skin which are innervated by an affected branch of the trigeminal nerve. Pain is always unilateral, recurrent, together with

lancinating episodes; and is described as burning or itching; well-localized to the affected site; frequently associated with hyperesthesia and hyperalgesia. The most common complication of HZ is post-herpetic neuralgia. [2]

Neuropathic Pain

Neuropathic pain occurs due to structural abnormalities [9] in one or more components of the nervous system that innervate the affected area. It can arise extemporaneously in the absenteeism of any obvious harmful stimulation and is usually described as a burning pain.

Neuropathic pain together with paraesthesia is seen along a distinct nerve distribution [10]. The severity of the pain is compared to the degree of stimulation, and even the slightest touch may result in intense pain. Neuropathic pain may be

- spasmodic (paroxysmal) and
- continuous, (Table 5) and
 - The most common paroxysmal facial pain is trigeminal neuralgia (TN).
 - An example of a continuous neuropathic disorder is atypical odontalgia (AO), also known as phantom tooth pain. Continuous neuropathic disorders have an unremitting, constant pain of variable intensity. The pain is burning and may be accompanied by paraesthesia or dysesthesia. AO refers to persistent pain in apparently normal teeth and surrounding alveolar bone, or at extraction sites from which teeth have been removed because of pain, (Table 5).

Paroxysmal	Continuous
Trigeminal neuralgia	Postherpetic neuralgia
Glossopharyngeal neuralgia	Post-traumatic Neuralgia
Nervus intermedius neuralgia	Atypical odontalgia Occipital neuralgia
Neuroma	

TABLE 5: Causes for Neuropathic Pain

Trigeminal neuralgia

The International Association for the Study of Pain (IASP) has defined the trigeminal neuralgia "as sudden usually unilateral severe brief, stabbing, recurrent pain; shown to have a significant impact on quality of life". TN is caused by a disturbance in the

lower two branches of the trigeminal nerve [11]. The trigger zone for the same may be localised close to teeth, and sometimes the patients may be subjected to unwanted treatments due to this.

TN is often misdiagnosed as TMD especially in cases where the TMD is unilateral; due to its relative frequency. The reason for the misdiagnosis may be due to its varied presentation and due to the reduced intensity of the burning or dull pain after the initial lancinating attack, which may be apparent in more than 50% of the cases. These have been labelled as type 2 or TN with concomitant pain. Neurosurgeons state a different outcome, in these individuals. Of the trigeminal autonomic cephalalgias SUNA (short unilateral neuralgiform pain with autonomic symptoms) needs to be reflected as a likely differential; being present in the lower face. [5] The most prominent feature of trigeminal neuralgia is the existence of trigger points often located in the skin of the lips, cheeks or gums and when touched may provoke a painful stimulus. Onset is frequently triggered by mechanical stimulation such as talking, chewing, or touch. Attacks can last from seconds to a few minutes.

Benign tumours, multiple sclerosis and A-V malformations need to be considered in the symptomatic causes of TN. Imaging is now mandatory as a part of the routine practice whereas some centres practice qualitative sensory testing.

Treatment

- Initial drugs such as carbamazepine or oxcarbazepine
- Second-line drugs namely the lamotrigine and baclofen.
- Surgery, if the patient suffers side effects or has poor pain control. Not much data is available on the outcome of surgical treatment though.
- Microvascular decompression that is non-destructive and which gives the longest pain-free interval (70% pain free at 10 years) has also been recommended.
- Other procedures include the ablative procedure such as balloon

compression or Gamma knife and radiofrequency thermocoagulation glycerol rhizotomy, which gives the patient 50% pain relief for four years; but patients, may have sensory changes which may hinder the quality of life. [3]

Post-traumatic trigeminal neuropathy/Peripheral painful, traumatic trigeminal neuropathy

A dental extraction, local anaesthetic, root canal filling, implants, and facial trauma can result in a nerve injury, with the injury being of varying degrees; and these conditions could be called as post-traumatic trigeminal neuropathy or peripheral painful, traumatic trigeminal neuropathy (PPTTN); proposed by Benoliel et al. He also found that only 50% had continuous pain, whereas others had daily pain that was of less than 4 hours duration; some even had very short attacks that were similar to TN like pain. Pain is often described as burning and stabbing; but patients with definite nerve injury such as lingual and inferior alveolar nerve, describe it as a feeling of pins and needles; fizzing and swollen sensations. Pain is elicited on being evoked, and in other cases, it may be spontaneous while some sensory changes can be identified on clinical testing; and somatosensory testing will often show evidence of hypoaesthesia or allodynia; most imaging is negative. Pain need not be a manifestation of all traumatic injuries; some manifest only sensory changes.

Treatment

- Although, the inferior alveolar nerve can be surgically repaired; most patients would require the guidelines for neuropathic pain to be adhered to. [5]

Anaesthesia Dolorosa/post-traumatic trigeminal neuropathy

There is a likely complication called as anaesthesia dolorosa, [12] encountered by the neurosurgeons while performing ablative procedures for TN most commonly at the level of the Gasserian Ganglion. When the cause is due to trauma e.g.

fractures; the term used for the same is the post-traumatic trigeminal neuropathy

Both of these conditions manifest within 3–6 months of the traumatic incident. The dissemination varies depending on the amount of the trauma, but in cases of the trigeminal neuralgia, it may extend to all the three divisions of the trigeminal nerve. The patients normally complain of hyperalgesia, hypoaesthesia; where the patient's experience "ants crawling over the face" experience, allodynia, and hypoalgesia. Management is difficult in cases where psychological anomalies co-exist such as anger and depression. Trauma patients manifest symptoms that are often less severe and more localised.

Treatment

- Drugs for neuropathic pain show a poor response and
- Addition of cognitive behaviour therapy may be of value. [3]

Persistent Idiopathic Facial Pain (PIPF)

Extraoral and/or intraoral pain along the course of the trigeminal nerve [13] that is not similar to the classic presentation of other cranial neuralgias or other disorders. Most patients with PIPF suffer from other symptoms such as a headache [14], backache, neck ache, irritable bowel, dermatitis, and uterine bleeding. [15]

Treatment

- Amitriptyline (25–100 mg/day). [2]

Glossopharyngeal neuralgia

A condition very similar to the TN is the glossopharyngeal neuralgia [16]; except for its location; and in some cases the two conditions may co-exist. The patient suffers from a pain deep within the ear [17] but may also suffer from pain in the back of the throat and the tongue. Swallowing and talking may trigger this pain. [18]

Treatment

- Drugs similar to that for TN
- Micro vascular decompression is suggested when the patient is

resistant to the other therapies. [3]

Nervus Intermedius Neuralgia or Facial Nerve Neuralgia

It is described as a rare condition, that manifests as pain; anterior to the external auditory region. It may arise as a complication of Herpes Zoster (Ramsay Hunt Syndrome) infection of the facial nerve.

Treatment

- Medications used for TN may be tried
- Surgery of the nervus intermedius for the pain relief or the chorda tympani nerves or MVD [2]

Post herpetic neuralgia (PHN)

The condition is defined as pain remaining for over a month after the mucocutaneous lesions of Herpes zoster have healed. The pain of PHN is diffuse, dull, and aching, with a superficial allodynic sensation evoked by touch and clothes. Diagnosis is clinical and based on the presence or past presence of vesicles. A more difficult diagnostic problem is severe pain caused by VZ virus without lesions, developing along the course of the nerve (zoster sine herpete; zoster sine eruption). Diagnosis in these cases is based on clinical symptoms and serologic evidence of a rising antibody titer. (Table 5). [2]

Superior Laryngeal Neuralgia

Severe spasmodic pain experienced in the submandibular, throat or under the ear within minutes to hours following damage to the superior laryngeal nerve from a common viral infection, or a scarring following a surgical procedure for tonsils, or a repeated trauma to the larynx from swallowing, singing or even talking.

Treatment

- Similar to that as for TN. [2]

Peripheral Neuritis

Inflammation of the nerves following some invasive dental procedures, periapical

inflammation or a misplaced dental implant associated with a nerve trunk may occur; and is typically asymptomatic.

Treatment

- Eliminate cause of inflammation
- Administration of corticosteroids or non-steroidal anti-inflammatory drugs [2]

Persistent Idiopathic Facial Pain/Atypical facial pain

A bucket term used to describe all other facial pains that cannot be categorised into any other criteria; due to the absence of any sensory or physical signs in these patients. A recent small study done using voxel-based morphometry on these patients indicate a similar change in the pain control centres of their brains, like other chronic pains. Data has indicated that the pain in these patients is mostly psychological and that many of these patients most likely have other chronic pain elsewhere. [3] There is a definite history of emotional or personality disorder in these patients. The degree of pain the patient expresses is often exaggerated, and response to treatment is usually inconsistent. [5] There is no fixed neurological distribution for the pain. The pain continues to spread and starts to involve a larger part of the head and neck. Though the pain is nagging and dull, it may exhibit sharp exacerbations. On neurophysiological testing, it has been observed that these patients have abnormalities and Forssell et al. have reported abnormalities similar to trigeminal neuropathic pain in some patients labelled with this condition. [3]

Treatment

Management is difficult.

Other methods that have been tried include:

- Pharmacotherapy and behavioural therapy.
- Using a combination of drugs such as antidepressants and cognitive behaviour therapy as a multidisciplinary approach.

Facial migraine/Neurovascular oro-facial pain

Studies have documented migraine like features of the lower face or as Benoliel et al. have called them; neurovascular oro-facial pain. As per Yoon et al., Benoliel et al., the migraine like the pain is chronic and of high severity; and also episodic, predominantly located in the lower half of the face, (bilateral or unilateral): other manifestations being photophobia and nausea, and autonomic features. Nothing much is known about this condition.

Treatment

- Reports of prognosis following anti-migraine therapy such as Triptans are not available although Oberman in their series showed a good response to Triptans. [3]

Migraine Headache and Facial Migraine

A migraine is thought of as a unilateral headache that causes pain posterior to the neck, eye, and cranium [19]; but it may also be experienced in the lower part of the face, particularly in the teeth. A Migraine [20] is a neurovascular disorder of the brain in which neural events cause meningeal blood vessel dilation, causing further nociceptive activation of the trigeminovascular system.

Treatment

- Non pharmacological: Here the patients need to be convinced that the pain they are experiencing is not a dental pain. Relaxation techniques, hypnosis, etc.
- Pharmacological: NSAIDS such as naproxen sodium and ibuprofen, Ergotamine derivatives, such as dihydroergotamine (DHE), triptans, and sumatriptan (Serotonin 5-HT). [1]

Giant cell arteritis/Horton disease/Temporal arteritis

This is a pain that primarily affects the temple region and aggravates following any jaw movement [21], to become widespread, and involve the tongue, causing it to undergo cyanosis. Biopsy of the temporal artery has been used as the gold standard

for diagnosis, but ultrasonography and MRI scanning have been found equally diagnostic.

Treatment

- Immediate commencement of systematic steroids to prevent blindness and other systemic effects. [2]

Neck-Tongue Syndrome

A rare type of pain is the neck-tongue syndrome (NTS) where cervical spine involvement is misdiagnosed or unrecognised source of oro-facial pain; which manifests as paraesthesia in the tongue. The syndrome is characterised by ipsilateral paraesthesia (numbness) of the tongue together with unilateral paroxysmal neck pain. The neck rotates the same side as the sensory sign; is the triggering factor for the syndrome. The tongue manifestations arise from sensory fibers, including proprioceptive afferents originating in the lingual nerve, which joins the dorsal roots of C2 by way of the hypoglossal nerve. Neck and Tongue symptoms dissipate in approximately 60 seconds.

The typical presentation of symptoms is brought on by a sudden axial rotation of the head and may be associated with pathologic findings in the region of the first two cervical vertebrae. Tumours, malformations, and degenerative processes may result in compression and irritation of the C2 root. NTS has been reported over a wide age range for which there is no clear sex or age predilection. Cases arise before 20 years of age. The communication of the hypoglossal nerve with the sympathetic trunk, the vagus, and the first and second cervical and lingual nerves explains the sensory signs in the oropharyngeal area. Since the trigeminal nerve is not anatomically close to the hypoglossal nerve or the upper cervical roots involvement; it may play no role.

Treatment

- Conservative management includes avoidance of neck trauma and the use of anti-inflammatory agents and drugs to ease neuropathic pain which has been effective. [2]

Mucogingival Pain with Recognised Oral Lesions

Over a third of acute oro-facial pain is caused due to bacterial infections, local injuries and inflammation as well as underlying systemic diseases. [22]

Oral infections

Some bacterial, fungal and viral infections may cause blisters, vesicles, erosions and ulcers that result in mucosal pain. The predominant diseases and their management are described in Table 7.

The oral cavity plays a key role in the life strategy of several viruses. A recent case report has stated that HSV-1 can be responsible for BMS-like symptoms. These patients have been found to have a high titre of the virus in saliva, and the disappearance of the pain on antiviral treatment.

Many studies have reported an association between oro-facial pain, systemic diseases and general pain conditions. Medical conditions manifesting oro-facial pain include a headache, cardiovascular disease, ear, nose and throat symptoms, gastrointestinal disorders, neck pain, and musculoskeletal conditions such as fibromyalgia, chronic rheumatoid arthritis, chronic fatigue syndrome, and psychological disturbances. A possible hypothesis may be that the pathophysiologies for both are similar, whereas on the other hand; treatment of systemic disease does not always eradicate the oral symptoms. Therefore, diagnosing the cause of oral pain may help in the diagnosis of some hidden systemic diseases. Although in some diseases, such as Paget's disease, hyperparathyroidism, plasmacytoma, and metastatic diseases; are mostly diagnosed by radiological and laboratory findings; in some cases, the systemic disease may manifest in the form of oral pain. (e.g. Jaw pain in angina pectoris), Craniofacial pain -site being the throat, mandible, TMJ, ear, neck and teeth aches may sometimes be the only manifestation of an acute myocardial infarction (AMI) and cardiac ischemia. Jaw pain induced by cardiac ischemia tends to

occur bilaterally as opposed to the pain of odontogenic origin, which rarely crosses the midline. Therefore, craniofacial pain due to cardiac ischemia should be considered in the differential diagnosis of orofacial and dental pain. Any failure to recognise it can put the patient's life at risk. Hence the patients with more medically complicated orofacial pain would require a multidisciplinary treatment.

Referred Pain

Referred pain to the oro-facial region is an important clinical consideration. The location of pain, therefore, will not always correspond to its source. The pathophysiology for this has been proposed as the convergence of different primary afferent fibers from different sites on the same second-order neuron in the brainstem nucleus. [2]

- As pain lasts, it gives rise to more responses of the central nervous system, and associated psychological factors exaggerate clinical characteristics.
- During history, it is necessary to collect relevant data about the existence of systematic diseases; including the results of earlier examinations and treatment and a list of drugs that patient takes. This is particularly important while many systemic diseases contribute to the development of painful oral conditions (Table 1). It is also well documented that some medications (lisinopril, isoniazid, vincristine, phenytoin, nitrofurantoin, cisplatinum, amiodarone; oral contraceptive, etc.) may cause peripheral neuropathy and paraesthesia.
- Furthermore, it is necessary to detect factors associated with present pain, that cause pain, worsen or reduce it or pain is its negative consequence.
- Evaluation should include a review of a history of primary headaches, surgeries, traumas, and stressors.

- A review of daily activities, habits as well as parafunctional oral habits, and sleep patterns should be included.
- Examination of the oral cavity should include inspection of all regions of oral mucosa to detect mucosal lesions and palpation to examine the sensitivity of oral mucosa and trigger points as well as other diagnostic procedures to determine the presence of unpleasant and painful symptoms. [5]

DIAGNOSTIC AIDS

MRI and computed tomography (CT) scan of the TMJs may be necessary to evaluate possible advanced degenerative pathologies or tumours in the oro-facial region in the case of neuropathic pain, treatment-resistant chronic pain and unusual pain patterns.

Consideration of other diagnoses by history and physical exam and laboratory studies will dictate additional studies and referral to the appropriate specialist. [2]

Differential Diagnostics Of Oro-Facial Pain

Obtaining a medical history from each patient with oro-facial pain should be a routine procedure in the dental office. It gives the dentist an insight into the past and presents physical health of the patient, and this information is of great importance regarding diagnosis and treatment of oro-facial pain. [5]

Because of the complexity of anatomy and the diversity of causes, patients with oral pain represent a diagnostic and therapeutic challenge to dental professionals. Dentists encounter 10-50% of patients with pain, on a daily and increasing frequency. This makes the role of the dentists extremely important in the treatment of oro-facial pain. [2]

Patients may experience more than one pain diagnosis and may also have an underlying psychiatric or personality

disorder which will influence the chronic pain and which may change the presentation and severity.

When problems arise in the pain area, the patients are unsure about the speciality of the practitioner who would solve their problem. The health care specialists including the dentists are only familiar with the oro-dental pain and are not with the pain that is bio- psychosocial and are also unsure about the drugs they need to prescribe. Hence as Hals et al. pointed out; what is needed is a multi-professional team to handle such pain. A recent study on the chronic orofacial pain patients in the UK; their healthcare 'journey' showed that the patients had attended a number of health care settings, seen specialists and only 24% were satisfied with the treatment provided, whereas the study from Germany showed a poor response rate of 45% on 34,242 patients that showed that patients were incompetently treated, though standard guidelines were adhered to. Thirty% even had a treatment, focus on the psychology,

[4] but wrongly, all were approached similarly. [3]

Differential Diagnostics of Oro-facial Pain in Elderly

Older people often have a variety of simultaneous health problems, although ageing does not necessarily mean disease and many take a variety of medications, often making it difficult for a dentist to make a definitive diagnosis of oral pain. Differential diagnosis of oral pain in the elderly should include:

- Infections, Neoplasms, gastroenterological, cardiovascular, traumatic, neurologic, psychological and musculoskeletal diseases.
- Angina pain is located primarily in the lower jaw and even occasionally the upper jaw.
- Cranial (giant cell or temporal) arteritis is a granulomatous vascular inflammatory disorder that affects medium or large cranial arteries.

- Perioral symptoms include pain of the masticatory muscles; facial edema can mimic infection or muscular hypertrophy. In addition, claudication of the tongue can occur due to the involvement of the lingual artery.
- Paget's disease of the bone usually affects an elderly population. The disease is characterised by facial pain but also signs of atypical trigeminal neuralgia may be present in addition to possible facial nerve palsies and hearing deficits.
- As the age advances the prevalence of cancer rises and many manifests with pain as a common complaint. The elderly patients older than 85, are at high risk for under treatment of pain. Oral cancer present with a variety of symptoms among which pain is not the first sign, rather it occurs late in the course of the disease. Local tumour growth and invasion result in local tissue destruction, secondary infection, nerve compression and myofascial pain.
- Pain occurs after surgery due to nerve damage, and inadequate vascularization of myocutaneous flaps; after radiation and chemotherapy due to neuritis, osteoradionecrosis, damaged salivary glands, secondary infection and mucositis.
- The physical condition may be complicated by psychogenic factors, fear and anxiety of tumour recurrence, which along with emotional distress regarding cosmetic concerns may contribute to the overall pain response.

Therefore, the approach in the diagnosis and treatment of these patients is always multidisciplinary. [2]

CONCLUSION

There are various etiologies of oral mucosal pain, and many of them manifest with similar clinical symptoms and features which make the diagnosis difficult. However, it is important that

these patients are properly diagnosed, in order to initiate an adequate treatment. The diagnosis and treatment of patients with chronic oral mucosal pain like BMS, is often more challenging, and generally requires a multidisciplinary approach ; and they are handled in units that have a multi-disciplinary team of pain specialists, oral surgeons, liaison psychiatrists, headache neurologists, neurosurgeons, clinical psychologists, physiotherapists and radiologists to successfully handle the pain.

COMPETING INTERESTS: The authors have no competing interest regarding the article

REFERENCES

1. Janina Christofor, Ramesh Balasubramaniam, Gary D. Klasser. Neuropathic Orofacial Pain. *Current Oral Health Reports*. September 2015; 2(3):148-157
2. Marinka Mravak-Stipetić. Differential Diagnostics of Painful Conditions of Oral Mucosa. Department of Oral Medicine, School Of Dental Medicine, University Of Zagreb, Zagreb, Croatia
3. Anne Marie Lynge Pedersen, Heli Forssell and Bjørn Grinde. Oro-facial pain conditions - Pain and oral mucosa. *The Norwegian Dental Association Journal*, Tidend. 2016; 116: 96-102
4. Patrick Haggard, Lieke de Boer. Oral somatosensory awareness. *Neuroscience and Biobehavioral Reviews*. November 2014; 47: 469-484
5. Joanna M Zakrzewska. *The Journal of Headache and Pain*. 2013; 14(1):37
6. Marcela Romero-Reyes and James M Uyanik. Orofacial pain management: current perspectives. *J Pain Res*. 2014; 7: 99-115
7. Yoshihiro Abiko, Hirofumi Matsuoka, Itsuo Chiba, and Akira Toyofuku Current Evidence on Atypical Odontalgia: Diagnosis and Clinical Management. *International Journal of Dentistry*. 2012. Volume 2012, Article ID 518548, 6 pages
8. Dimos D. Mitsikostas, Srdjan Ljubisavljevic and Christina I. Deligiann. Refractory burning mouth syndrome: clinical and paraclinical evaluation, comorbidities, treatment and outcome. *The Journal of Headache and Pain*. 2017;18:49
9. Luana Colloca, Taylor Ludman, Didier Bouhassira, et.al. Neuropathic pain.2017; *Nature Reviews Disease Primers* 3, Article number: 17002
10. Moore R, Derry S, Aldington D, Cole P, Wiffen PJ. Amitriptyline for neuropathic pain in adults. *Cochrane Database of Systematic Reviews* 2015, Issue 7. Art. No.: CD008242
11. Jeffrey Cohen. Trigeminal Neuralgia. *NORD. National Organisation for Rare Disorders*.2014
12. María Peñarrocha, David Peñarrocha, José V. Bagán, and Miguel Peñarrocha. Post-traumatic trigeminal neuropathy. A study of 63 cases. *Med Oral Patol Oral Cir Bucal*. 2012 Mar; 17(2): e297-e300.
13. Gary D. Klasser. Management of Persistent Idiopathic Facial Pain. *Can Dent Assoc* 2013; 79:d71
14. Rigmor Jensen, Dimos D, Mitsikostas, Christian Wöbe. Persistent Idiopathic Facial Pain. Page 505-513. *Handbook of Headache*. 2011. Springer Link.
15. Zakrzewska JM. Chronic/Persistent Idiopathic Facial Pain. *Neurosurg Clin N Am*. 2016 Jul; 27(3):345-51.
16. Fischer, S. M. Ludin, K. Puente de la Vega, and M. Sturzenegger. Neuralgia of the Glossopharyngeal Nerve in a Patient with Post-tonsillectomy scarring: Recovery after local Infiltration of Procaine-Case Report and Pathophysiologic Discussion. *Case Reports in Neurological Medicine*. Volume 2015 (2015), Article ID 560546, 5 pages
17. P. M. Singh, Manpreet Kaur,1 and Anjan Trikha. An uncommonly common: Glossopharyngeal neuralgia. *Ann Indian Acad Neurol*. 2013 Jan-Mar; 16(1): 1-8.
18. Dr Owen Kang and Dr Mohammed Wahba et. al. Glossopharyngeal neuralgia. *Radiopedia*. 2017

19. Yoon MS, Mueller D, Hansen N, Poitz F, 21. Dr Alfred MAHR. Giant Cell Arteritis. et.al. Prevalence of facial pain in migraine: Orphanet for Rare Diseases. Oct 2009L a population-based study. Cephalalgia. 2010 Jan;30(1):92-6
20. Debruyne F, Herroelen L. Migraine presenting as chronic facial pain. Acta Neurol Belg. 2009 Sep; 109(3):235-7.
22. Wanda C. Gonsalves, Angela C. Chi, and Brad Neville. Common Oral Lesions: Part