Segmentation of White Blood Cells (WBCs) in Blood

Student:
Petrăreanu Alexandra-Raluca

București
March 2025

INTRODUCTION

In this project, we will study the segmentation of white blood cells, which is of particular importance in medical image analysis both from the perspective of diagnosis and scientific research.
In this case, we will study the segmentation of white blood cells through a condition called leukemia. Leukemia is a clonal proliferation of hematopoietic stem cells in the bone marrow, representing one of the most common malignant hematological diseases. It can be classified into four main subtypes most commonly encountered in medical practice: acute lymphoblastic leukemia, acute myelogenous leukemia, chronic lymphocytic leukemia, and chronic myelogenous leukemia. [1]

Among these, acute lymphoblastic leukemia occurs more frequently in children, while the other forms are predominant in adults. The risk factors involved in the development of the disease include both genetic predisposition and environmental factors, such as exposure to ionizing radiation.

The symptoms of leukemia are often nonspecific and may include fever, fatigue, weight loss, bone pain, the appearance of bruises, or spontaneous bleeding. The diagnosis is suggested by changes identified in the complete blood count, which may indicate leukocytosis and other hematological abnormalities. Confirmation of the diagnosis requires additional investigations, such as bone marrow examination or peripheral blood analysis.

Depending on the subtype and severity of the disease, treatment may include chemotherapy, radiotherapy, administration of monoclonal antibodies, or hematopoietic stem cell transplantation. However, therapeutic interventions may be accompanied by serious complications, such as tumor lysis syndrome or severe infections caused by immunosuppression. In the long term, leukemia survivors must be carefully monitored for possible side effects, including secondary malignancies, cardiovascular complications, and endocrine disorders such as metabolic syndrome, hypothyroidism, and hypogonadism. [2]

Globally, leukemia affects approximately 250,000 people annually, representing 2.5% of all cancer cases. At the same time, other malignant hematological conditions, such as malignant lymphomas and multiple myeloma, also show a significant incidence. For example, malignant Hodgkin lymphoma (MHL) has an incidence of approximately 3% in the USA and Western Europe, while non-Hodgkin malignant lymphomas (NHML) have recorded an alarming increase of nearly 80% in recent decades, becoming one of the leading causes of cancer in children, women, and men. On the other hand, multiple myeloma has an incidence of approximately 6% in the European Union, representing 1% of all cancers and 10% of all malignant hematological diseases. [3]

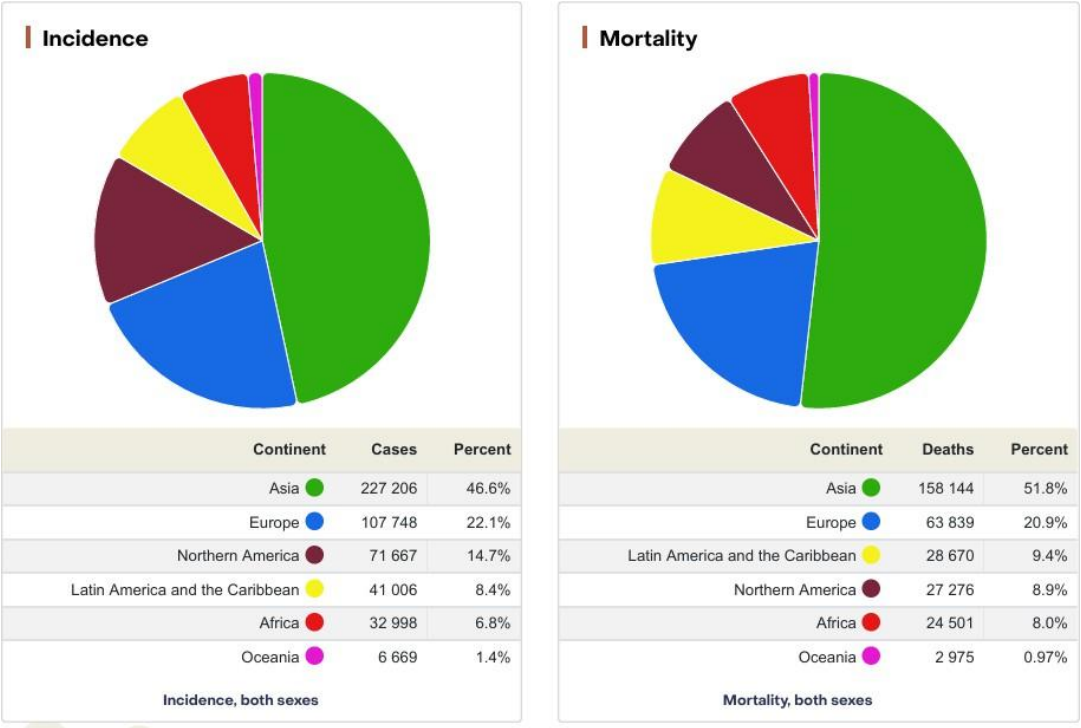

Fig 1. Incidence and mortality table for both sexes, by continent [4]

To obtain images with segmented white blood cells, several methods can be used, which we will list below:

1. Double threshold method

The double threshold segmentation method is an image processing technique used for the automatic separation of objects from the background in a digital image by applying two different thresholds for more precise detection. It combines information from different color channels or image transformations to identify and more clearly delineate the regions of interest. In the case of leukocyte segmentation from microscopic images, the method involves background extraction, separation of erythrocytes, and the selection of an optimal threshold for highlighting white blood cells, being complemented by post-processing techniques to reduce errors and improve segmentation accuracy.

2. Flow Cytometry

This cellular analysis technique is used to identify, classify, and quantify leukocytes based on their physical and fluorescent properties. The process involves the passage of cells in suspension through an optical-laser system, where each cell is excited and the resulting signals are collected and analyzed in order to distinguish different types of leukocytes (lymphocytes, monocytes, neutrophils, etc.). Segmentation in this context refers to the separation and identification of each cell type based on parameters such as forward scatter (FSC – Forward Scatter), side scatter (SSC – Side Scatter), and fluorescent markers associated with surface antigens.

3. Immunofluorescence

• Uses fluorescently labeled antibodies to specifically stain certain types of leukocytes.
• It can be combined with advanced microscopy (confocal, super-resolution).

4. Techniques based on artificial intelligence (Deep Learning & Machine Learning)

• Previously processed histopathological image databases are used, on which neural networks are trained for automatic segmentation.
• Examples of architectures used: U-Net, Mask R-CNN, DeepLabV3+.

State of the art

1.1 Double Threshold Method

This method improves the segmentation of leukocytes from microscopic blood images by using a double-threshold–based technique.
The process includes three stages: preprocessing, threshold-based segmentation, and post-processing. In the preprocessing stage, two images are extracted: one grayscale image with enhanced contrast and another from the H channel of the HSV color space. Segmentation is performed by separating the background, delimiting erythrocytes, and selecting the optimal threshold using the golden section search method. In the post-processing stage, morphological operators and median filtering are applied to eliminate noise and incomplete cells. The method was tested on a set of microscopic images and evaluated using the Dice coefficient, accuracy, and mean error, demonstrating superior performance compared to other existing techniques.

The database used comes from a collection of microscopic blood images, and the evaluation metrics are accuracy, the Dice coefficient, and the mean error.

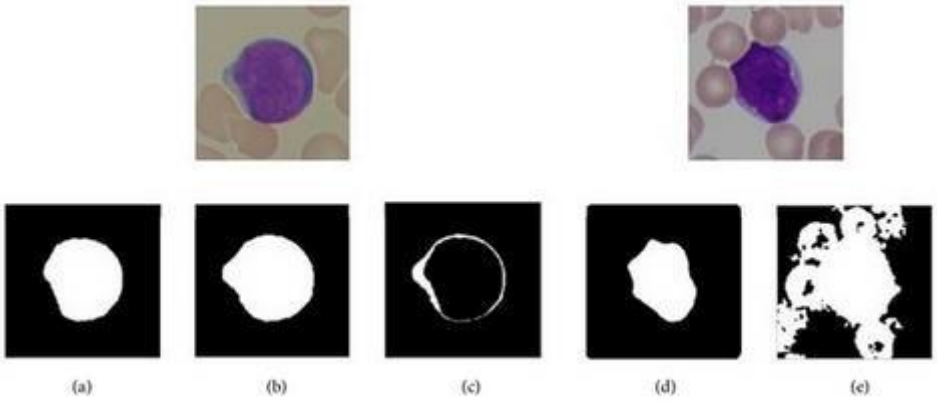

Fig. 2 Principle of the double threshold method:

(a, d) Segmentation results using the single-threshold method applied to the RGB color space or to the S channel of the HSV color space (only the nucleus is extracted).

(b) Segmentation result of a uniform image using the single-threshold method applied to the H channel of the HSV color space (both the nucleus and the cytoplasm are extracted).

(c) Expected result of cytoplasm segmentation.

(e) Segmentation result of an image with illumination variations using the single-threshold method applied to the H channel of the HSV color space (the segmentation result contains a large amount of noise). [5]

2.2 Flow Cytometry

There are three main methods of fluorescent cell labeling used for in vivo monitoring.

The first method involves the injection of a fluorescent dye bound to antibodies or antibody fragments that target specific cell surface receptors. This allows the detection of cells that are in the cell cycle, but it has disadvantages such as cell depletion through antibody–antigen binding and the loss of the fluorescent signal, which limits long-term monitoring.

The second method consists of labeling cells in vitro with fluorescent tracers, followed by their reinjection into the organism. The fluorescence intensity gradually decreases as the cells divide, but the signal persists longer than in the first method, allowing the monitoring of cells for several weeks.

The third method uses the introduction of genes that encode fluorescent proteins (FP) directly into the cells. As long as FP expression is stable, fluorescence does not decrease after cell division, allowing continuous in vivo monitoring. This method is the most suitable for the long-term tracking of tumor growth.

The database used in this method is BCData (Blood Cell Data), and the evaluation metrics are accuracy, Dice coefficient, sensitivity, specificity, and precision. [6]

Description of the Database

The dataset used in this work was created in response to the SegPC-2021 challenge, organized as part of the IEEE ISBI 2021 Challenge, with the aim of segmenting plasma cells from bone marrow aspirates of patients diagnosed with multiple myeloma. This dataset provides microscopic images stained with Jenner–Giemsa, ground-truth annotations for the cells of interest, and a standardized framework for evaluating the performance of segmentation algorithms.
The automatic segmentation of these cells in microscopic images represents a crucial step in the computer-assisted analysis of biological samples, supporting early and accurate diagnosis. The images were obtained from bone marrow smear samples stained with Jenner–Giemsa, using two acquisition systems:

- Olympus camera with a size of 2040×1536 px and the cellSens v2.1 software,
- Nikon camera with a resolution of 1920×2560 px.

Preprocessing included stain color normalization, performed using a proprietary algorithm previously published in Medical Image Analysis Journal (https://doi.org/10.1016/j.media.2020.101788).

The dataset is divided into:

- Training set: 298 images + labels (GT) for the cells of interest.
- Validation set: 200 images + GT.
- Final test set: 277 images (without GT), evaluated on the official platform.

Important: Ground truth (GT) is provided only for the pre-identified plasma cells. Other types of cells may be present in the images but are not included in the evaluation.

Description of the Proposed Methods

Algorithm Implementation

The algorithm is applied to the entire dataset, using the same procedure for all images in the database/folder, as can be observed in the code.
To illustrate each operation performed in this project, this particular image was selected, which highlights the presence of acute leukemia due to the massive presence of blast cells. Nearly all white blood cells in the image are very large, with a voluminous, dark nucleus and reduced cytoplasm—characteristics typical of hematopoietic blasts. Some of these cells also show prominent nucleoli, indicating clonal proliferation, which is typical for leukemia. Red blood cells are relatively few, while white blood cells completely dominate the visual field.

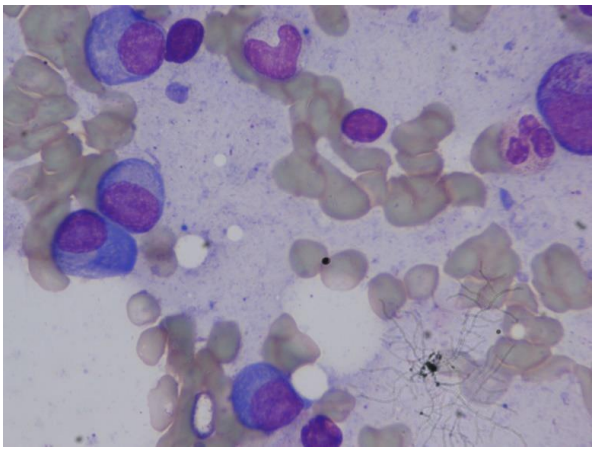

Image Enhancement – Contrast Adjustment Operation

1. Logarithmic Transformation

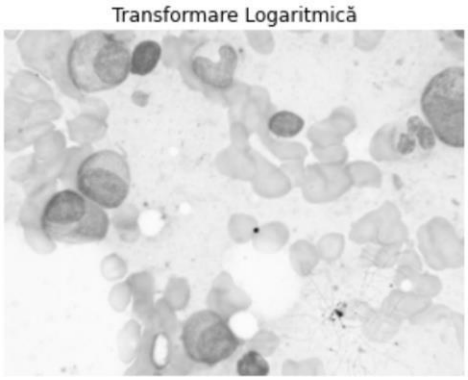

This method compresses high-intensity values and amplifies low-intensity values. It is

useful when there are details in very dark areas, allowing structures like nuclei or cytoplasm in microscopic images to become more visible.

2. Power-Law (Gamma) Transformation (Gamma = 2.0)

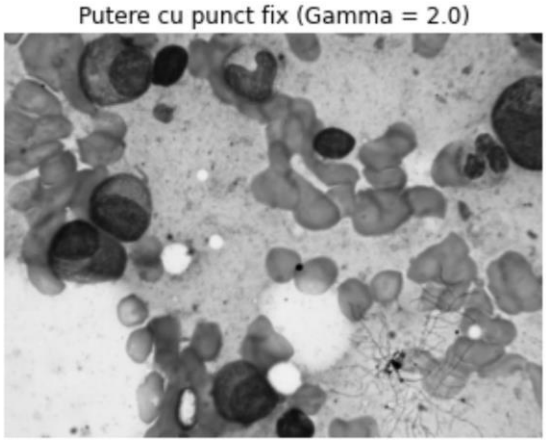

- A gamma value greater than 1 darkens the overall image while emphasizing the already bright regions. It is useful for images that are too bright, helping to reveal details that would otherwise be washed out.

3. Clipping (50–200)

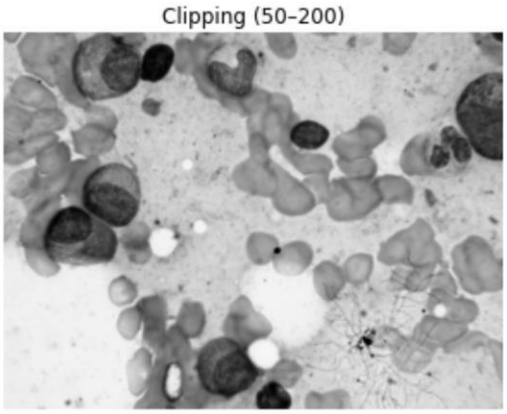

- This method clips values below 50 and above 200, stretching the remaining values between 0 and 255. It drastically enhances the contrast in the mid-range regions of the image.

4. Slicing



Slicing is an image segmentation technique that involves selecting a range of intensity values (thresholds) and marking the pixels that fall within that range. Specifically:

- Two thresholds are chosen — 100 and 180.
- Pixels with values within this range are set to a constant value (usually 255 – white).
- Pixels outside the range are set to 0 (black).

This method isolates structures that have a characteristic intensity within a certain range, such as white blood cells in specific staining techniques.



Morphological Operations

Based on the image obtained through slicing, the following observations can be made:

- White blood cells appear as compact white regions on a black background.
- There is noise (small dots or shapes) and discontinuities in some structures.
- Some cells appear slightly fragmented or incomplete. The most suitable operation is closing because:
    - In the sliced image, cells are fragmented or have small gaps inside — closing restores their shape without excessively deforming them.
    - Closing also helps connect broken edges and smooth contours, which is ideal for counting or further morphological analysis.

Morphological closing is an operation used in binary image processing, composed of two steps: dilation followed by erosion.
This combination has the effect of:

- Filling small holes in white objects.
- Connecting nearby components.
- Smoothing edges without drastically altering the object shapes.

Main goal: Restore interrupted or fragmented shapes and reduce discontinuities in large objects.



Feature Extraction Based on the Final Images

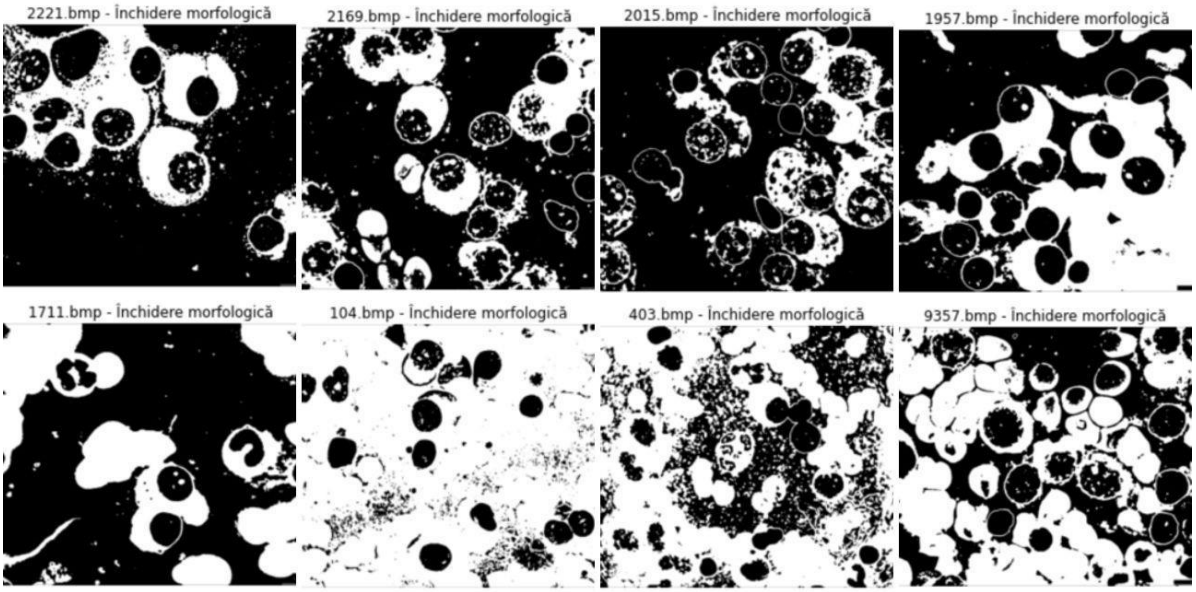

Observable Morphological and Pathological Features

I. Clearer and continuous cell contours

- White blood cells, visible as dark spots, now have smoother and more defined contours.
- This allows automatic identification of cell shapes, which is essential in leukemia diagnosis where atypical cells appear.

II. Filled internal gaps

- Affected leukocytes may show intracellular inclusions or vacuoles, which appear as "gaps" during segmentation.
- Morphological closing reduces these gaps, making the cell shape more compact — useful for automated classification.

III. Clearer separation of individual cells

- Without closing, some cells may appear fragmented. After closing, they are consolidated into distinct units, facilitating:
    - Cell counting
    - Analysis of the ratio between cell types
    - Detection of abnormal leukocyte counts, characteristic of leukemia.

IV. Reduction of Artifacts

- Areas of noise or digital debris are visually diminished, which increases segmentation accuracy.

V. Possibility of Extracting Quantitative Features

- The following measurements can be performed:
    - Cell count – to detect leukocytosis (abnormally high white blood cell count).
    - Area of each cell – useful for detecting immature lymphocytes.
    - Shape, roundness, compactness – leukemia often produces deformed cells.

Leukemia involves abnormal proliferation of leukocytes, often accompanied by:

- Larger, irregular white blood cells.
- Immature appearances (blasts).
- Increased cell density in the blood smear.

By applying morphological closing:

- Cell shapes become well-defined → enables distinction between normal and suspicious leukocytes.
- Noise is reduced → increases the likelihood of correct automatic detection.
- Fragmented cells are consolidated → eliminates segmentation errors that could distort medical statistics.

Obtained Results

1. Logarithmic Transformation
   - Observation: The image appears relatively uniform, but large blasts are somewhat lost in the background. Contours are not well-defined, and the contrast between nucleus and cytoplasm is weak.
   - Problems: Leukemic cells (lesions) do not stand out clearly. The background has a similar tone to the blasts.

2. Power-Law (Gamma = 2.0) Transformation
   - Observation: Contrast is acceptable, but the background becomes darker, and some leukemic cells merge with it. Shapes are preserved, but detail clarity is low.
   - Problems: The difference between pathological cells and background is not clearly visible.

3. Clipping (50–200)
   - Observation: This is the most contrast-enhanced image. Blasts are very well defined, with preserved shapes, clearly separable from the background. Nuclear details (nucleoli, irregular edges) are visible.
   - Advantage: Lesions are clearly highlighted, with preserved shape and structure.

Conclusion: The winning operation is method 3: Clipping, as it provides the best visualization of leukemic cells, with clear contours, strong differentiation from the background, and preserved cell shape — essential for accurate diagnosis.

Satisfactory Cases Using Slicing (examples: 9706, 2221, 104, 2015)
- White blood cells are well contoured, with minimal background noise.
- Most background pixels are removed, facilitating automatic identification.
- Round and dense shapes (typical of leukocytes) are clearly highlighted.

Unsatisfactory Cases (examples: 407, 1927, 403)
- Some cells appear partially segmented — not all components fall within the 100–180 intensity range.
- Cells with very different intensity (too light or too dark) are not detected and may be completely missed.
- Artifacts in the bottom-left corner indicate noise that still falls within the selected intensity range.

Cause of Unsatisfactory Behavior:
- Variability in staining (not all white cells have the same intensity, especially in pathological samples).
- Fixed slicing interval, which may not capture all cells.
- Presence of noise or artifacts, which can lead to false positives if their intensities fall within the selected range.

CONCLUSIONS

1. Segmentation is essential for highlighting atypical leukemic cells
   - The analyzed images show an abundance of blast cells, typical of leukemia, characterized by a large, dark nucleus, reduced cytoplasm, and sometimes prominent nucleoli.
   - Segmentation visually separates these cells from the background and other elements (red blood cells or artifacts), facilitating accurate and automated detection.

2. Clipping provides the best results for contrast enhancement
   - Among the tested methods (logarithmic transformation, gamma correction, and clipping), Clipping (50–200) gave the best results in:
     - Clearly separating blasts from the background.
     - Highlighting nuclear details (nucleoli, irregular contours).
     - Preserving cell shape, which is essential for diagnosis.

3. Slicing technique is effective but limited by intensity variation
   - Slicing, based on intensity thresholds (100–180), allows efficient segmentation of white blood cells in many cases (e.g., images 9706, 2221, etc.).
   - However, in unsatisfactory cases, some cells fall outside the chosen intensity range, leading to:
     - Fragmented cells.
     - Complete omission of some leukocytes.
     - Misidentification of artifacts as cells.

4. Morphological operations (closing) refine segmentation results
   - Morphological closing improves segmentation by:
     - Repairing broken cell edges.
     - Filling internal gaps in cells.
     - Eliminating noise and background artifacts.
   - This allows more precise automatic morphological analysis and increases algorithm accuracy in detecting atypical cells.

5. High-quality segmentation enables automatic quantitative analysis
   - After image processing, clinically useful features can be extracted:
     - Leukocyte count – for detecting leukocytosis.
     - Cell area, shape, roundness – useful in classifying immature or deformed cells in leukemia.
   - Segmentation thus contributes not only to visual detection but also to computer-assisted diagnosis.

6. Segmentation quality depends on color standardization and threshold adaptability
   - Variability in cell intensity caused by staining differences or pathological conditions negatively affects segmentation.
   - A fixed threshold in slicing is not ideal for all images — adaptive or machine learning–based methods are recommended.

Final Remark:
Correct segmentation of white blood cells, especially leukemic blasts, is crucial for automated detection and computer-assisted leukemia diagnosis. Image preprocessing, threshold-based segmentation, and morphological refinement form a critical chain of steps that, if properly calibrated, can lead to a robust automated system for analyzing blood smears.

BIBLIOGRAPHY

[1] AMANDA S. DAVIS, MD, ANTHONY J. VIERA, MD, MPH, AND MONICA D. MEAD, MD, Leukemia: An Overview for Primary Care.

[2] Salim Arslan, Emel Ozyurek, Cigdem Gunduz-Demir, A color and shape based algorithm for segmentation of white blood cells in peripheral blood and bone marrow images.

[3] NICULESCU IRINA[1], CUPŞA, A.[1], DIACONESCU, I.[1], ROMANESCU AMALIA[2], STOIAN ANDREEA[2], GIUBELAN, L.[1], DUMITRESCU FLORENTINA[1], DINESCU, S.[1], MUŞA MANUELA[2], Infecţii la pacienţii cu boli hematologice maligne.

[4] Website citation Ferlay J, Ervik M, Lam F, Laversanne M, Colombet M, Mery L, Piñeros M, Znaor A, Soerjomataram I, Bray F (2024). Global Cancer Observatory: Cancer Today. Lyon, France: International Agency for Research on Cancer. Available from: https://gco.iarc.who.int/today, accessed [22 03 2025]. Cancer incidence and mortality data Sung H, Ferlay J, Siegel RL, Laversanne M, Soerjomataram I, Jemal A, Bray F. Global cancer statistics 2020: GLOBOCAN estimates of incidence and mortality worldwide for 36 cancers in 185 countries. CA Cancer J Clin. 2021 Feb 4. doi: 10.3322/caac.21660. Epub ahead of print. PMID: 33538338. Ferlay J, Colombet M, Soerjomataram I, Parkin DM, Piñeros M, Znaor A, Bray F. Cancer statistics for the year 2020: An overview. Int J Cancer. 2021 Apr 5. doi: 10.1002/ijc.33588. Epub ahead of print. PMID: 33818764.

[5] Yan Li, Rui Zhu, Lei Mi, Yihui Cao, Di Yao, Segmentation of White Blood Cell from Acute Lymphoblastic Leukemia Images Using Dual-Threshold Method.

[6] Yingsi Yu, Yimei Zheng, Caizhong Guan, Min Yi, Yunzhao Chen, Yaguang Zeng, Honglian Xiong, Xuehua Wang, Junping Zhong, Wenzheng Ding, Mingyi Wang, and Xunbin Wei, Detection of cells by flow cytometry: Counting, imaging, and cell classification.

```
import matplotlib.pyplot as plt
import numpy as np
import os
from scipy.ndimage import binary_closing

cale_folder = r'C:\Users\alexa\Desktop\Tx_BulaiAdina_PetrareanuRaluca_Set-ales'
lista_imagini = [f for f in os.listdir(cale_folder) if f.endswith('.bmp')]

def show_result(title, image):
    plt.figure()
    plt.imshow(image, cmap='gray')
    plt.title(title)
    plt.axis('off')
    plt.show()

for nume_imagine in lista_imagini:
    print(f'Procesez {nume_imagine}...')
    cale_img = os.path.join(cale_folder, nume_imagine)
    img_color = plt.imread(cale_img)

    if img_color.ndim == 3:
        img = np.dot(img_color[..., :3], [0.2989, 0.5870, 0.1140])
    else:
        img = img_color

    img = (img * 255) if img.max() <= 1.0 else img
    img = img.astype(np.uint8)

    # === 1. Funcția LOGARITMICĂ ===
    c_log = 255 / np.log(1 + np.max(img))
    log_img = c_log * np.log(1 + img.astype(np.float32))
    log_img = np.uint8(np.clip(log_img, 0, 255))
    show_result(f"{nume_imagine} - Transformare Logaritmică", log_img)

    # === 2. Funcția PUTERE CU PUNCT FIX ===
    gamma_fp = 2.0
    fp_img = np.power(img.astype(np.float32) / 255.0, gamma_fp)
    fp_img = np.uint8(np.clip(fp_img * 255, 0, 255))
    show_result(f"{nume_imagine} - Putere cu punct fix (Gamma = {gamma_fp})", fp_img)

    # === 3. Funcția CLIPPING ===
    low, high = 50, 200
    clipped = np.clip(img, low, high)
    clipped = ((clipped - low) / (high - low)) * 255
    clipped = np.uint8(np.clip(clipped, 0, 255))
    show_result(f"{nume_imagine} - Clipping ({low}–{high})", clipped)
```

```
# === 4. Slicing ===
low_s, high_s = 100, 180
constanta = 1
sliced = np.where((img >= low_s) & (img <= high_s), constanta, 0).astype(np.uint8)
show_result(f"{nume_imagine} - Slicing ({low_s}-{high_s})", sliced)

# === 5. Închidere morfologică ===
sliced_bool = sliced.astype(bool)
structura = np.ones((3, 3), dtype=bool)
inchidere = binary_closing(sliced_bool, structure=structura)
inchidere_uint8 = (inchidere.astype(np.uint8)) * 255
show_result(f"{nume_imagine} - Închidere morfologică", inchidere_uint8)
```