OSTEOMYELITIS

Nick Blanas, BSc,DDS,FRCD(C)
Email: nick.blanas@sunnybrook.ca

SUNNYBROOK
& WOMEN'S
Sunnybrook and Women's College Health Sciences Centre

Definitions

- Inflammation of bone marrow (cancellous bone).
- Usually due to infection.
- Can involve cortical bone, periosteum and soft tissues.
- Has a tendency to progression.

Predilection

- Mandible >>>maxilla.
- Mandible:
  - Dense cortical plates.
  - Limited blood supply.
- Maxilla:
  - Loose cancellous bone.
  - Thin cortical plates.
  - Rich vascular supply.

Predilection

- Immunosuppressed.
- Any condition that impairs blood flow (i.e. osteopetrosis).

Incidence

- Fairly common in the pre-antibiotic era.
- Recent resurgence in numbers.

Pathophysiology

- Origin is usually contiguous – odontogenic infection or trauma.
- Haematogenous origin almost always seen in the very young.

Pathophysiology

- Bacteria enter cancellous bone.
- Inflammatory response.
- Usually the host response eliminates the pathogens.

Pathophysiology

- In some cases:
  - Inflammation further decreases blood supply.
  - Bacterial growth continues.
  - Pus forms and spreads through Haversian system.
  - Perforates through cortical bone and collects under the periosteum further reducing blood supply.
  - Pus can collect in the soft tissues or drain through a fistula.

Microbiology

- Mixed.
- Anaerobes dominate.

Classification

- Many schemes; often quite complex and clinically cumbersome.
- Acute vs. chronic.
- Suppurative vs. non-supporative.
- Contiguous vs. haematogenous.

Classification

- Focus will be on adult, acute, suppurative osteomyelitis.

Signs and Symptoms

- Same as those seen in any infection – local, regional and systemic.
- Disproportional pain.
- Paraesthesia.

Radiographic Findings

- Plain films.
- CBCT/CT.
- Nuclear medicine.

Plain films

- “moth-eaten” bone.
- Lytic changes.
- Periosteal new bone.

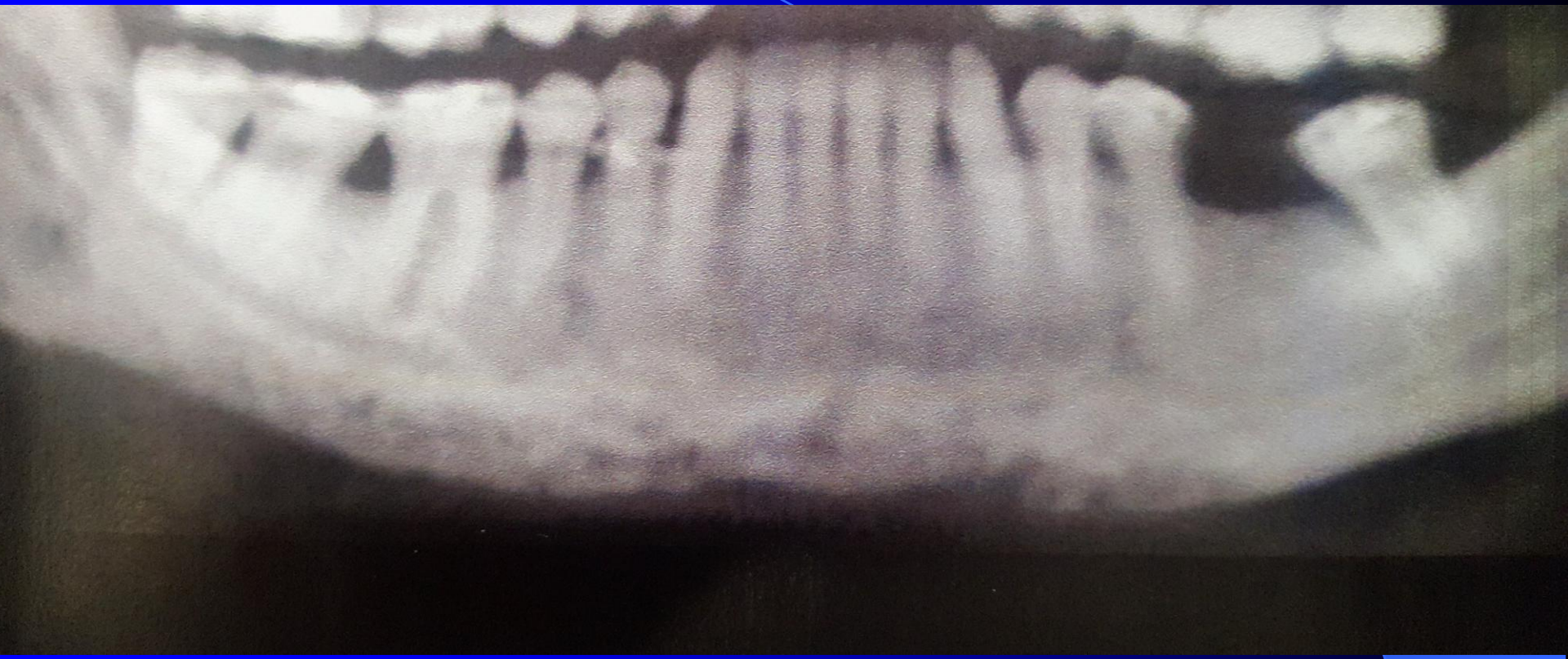

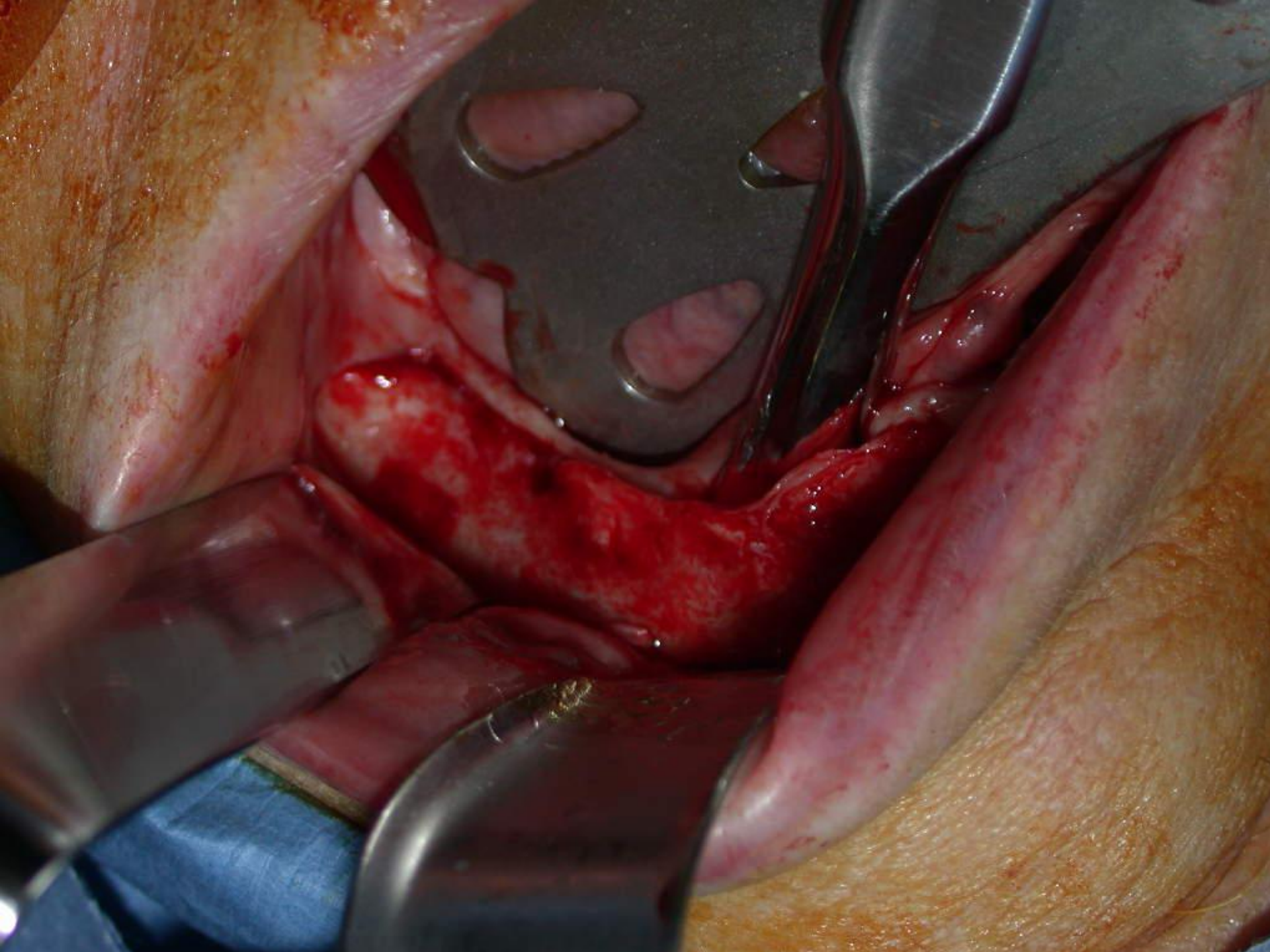

CBCT/CT

- More detailed.
- More sensitive – better shows cortical disruption.

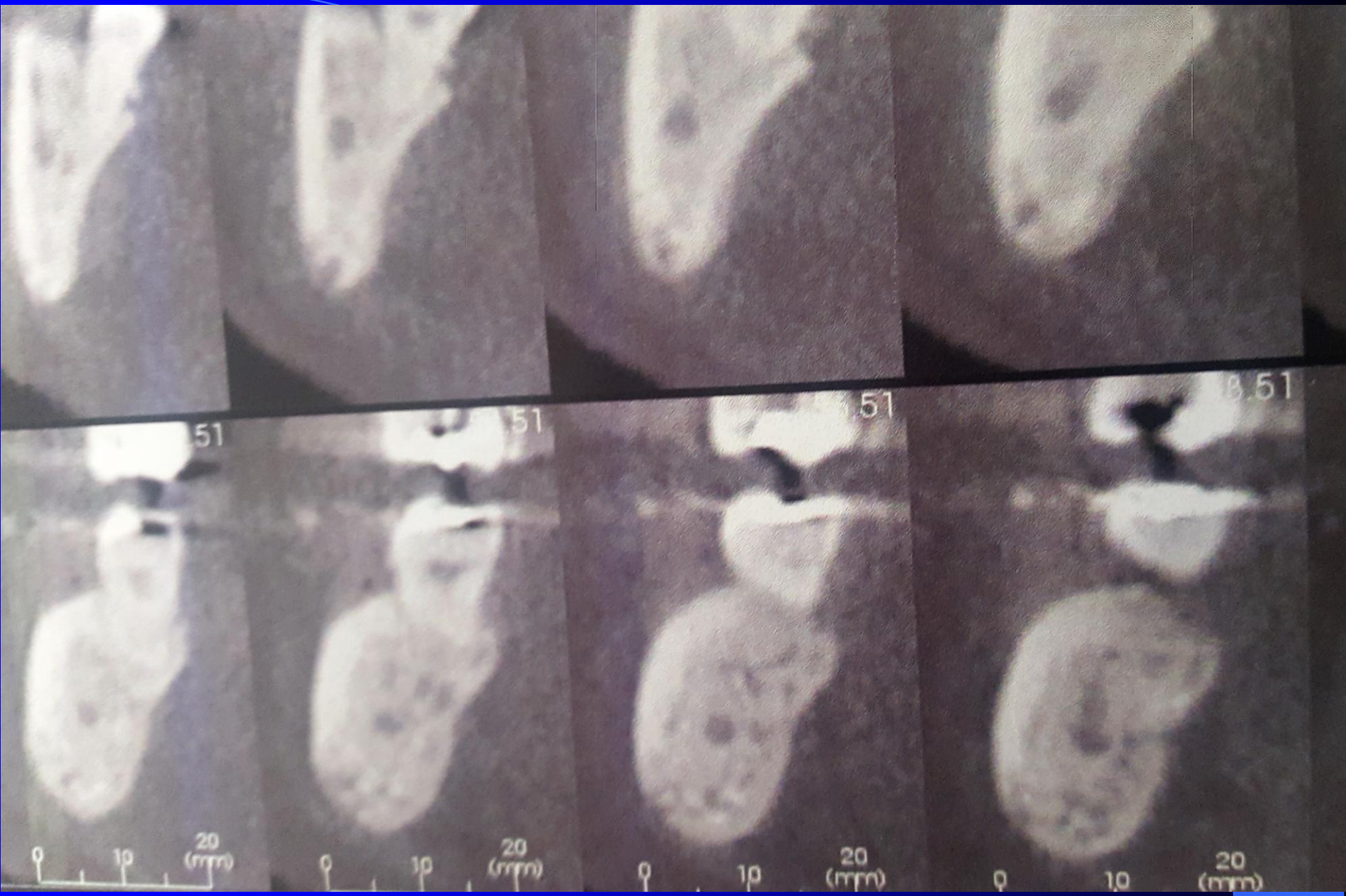
51
51
51
8.51
0
10
20
(mm)

74.51
76.51
78.51
80.51
86.51
88.51
90.51
92.51
98.51
100.51
102.51
104.51

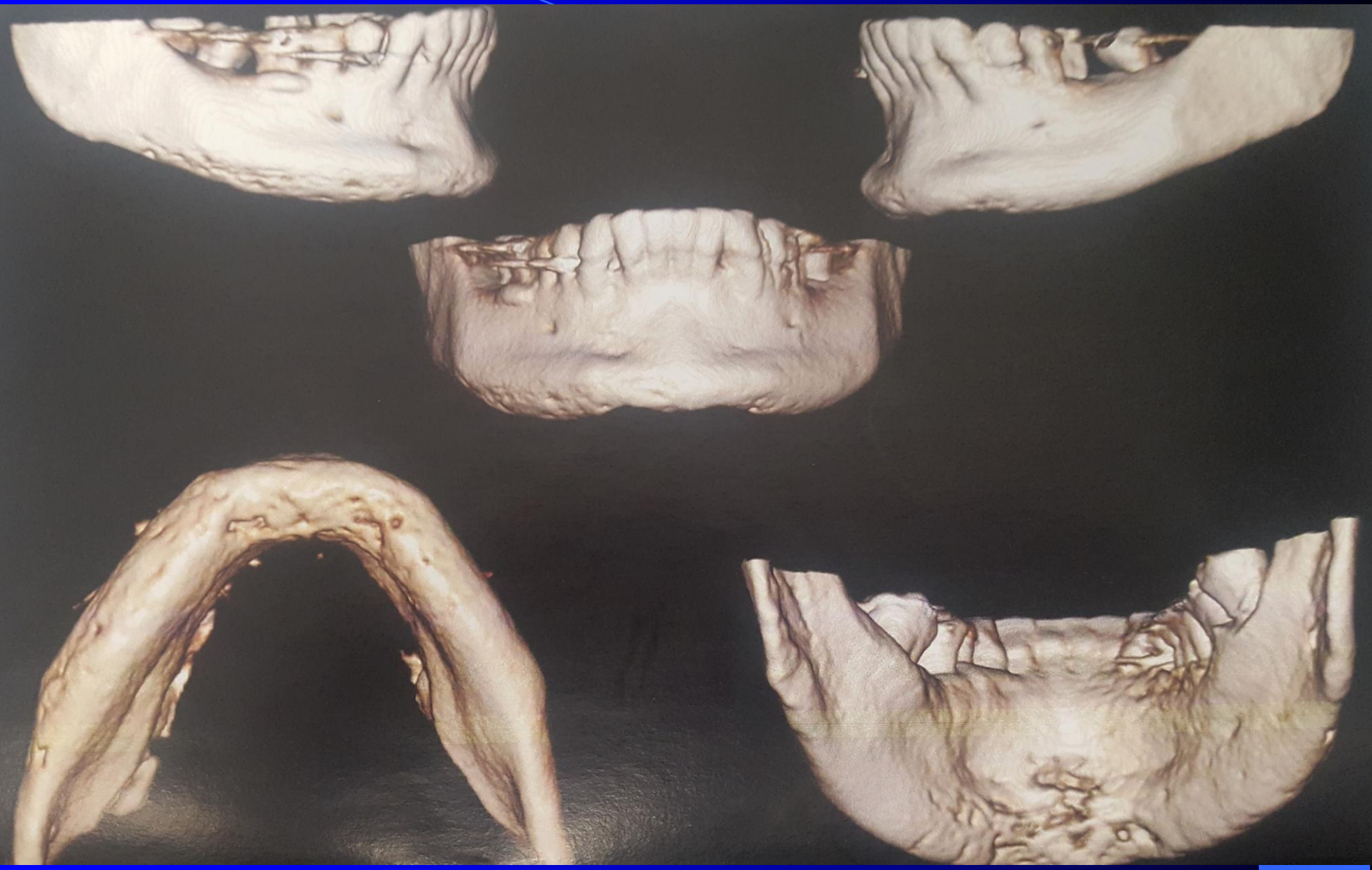

Nuclear Medicine

- “Bone scans”
  - Technitium 99 labels bone turnover.
  - Gallium labels white blood cells.

Management

- Medical:
  - As with all infections.
  - Prolonged IV antibiotics.
  - Hyperbaric oxygen.

Management

- Surgical:
  - Biopsy to rule out malignancy.
  - Samples for microbiologic studies.
  - Elimination of cause.
  - Sequestrectomy.
  - Saucerization.
  - Stabilization.
  - Resection.

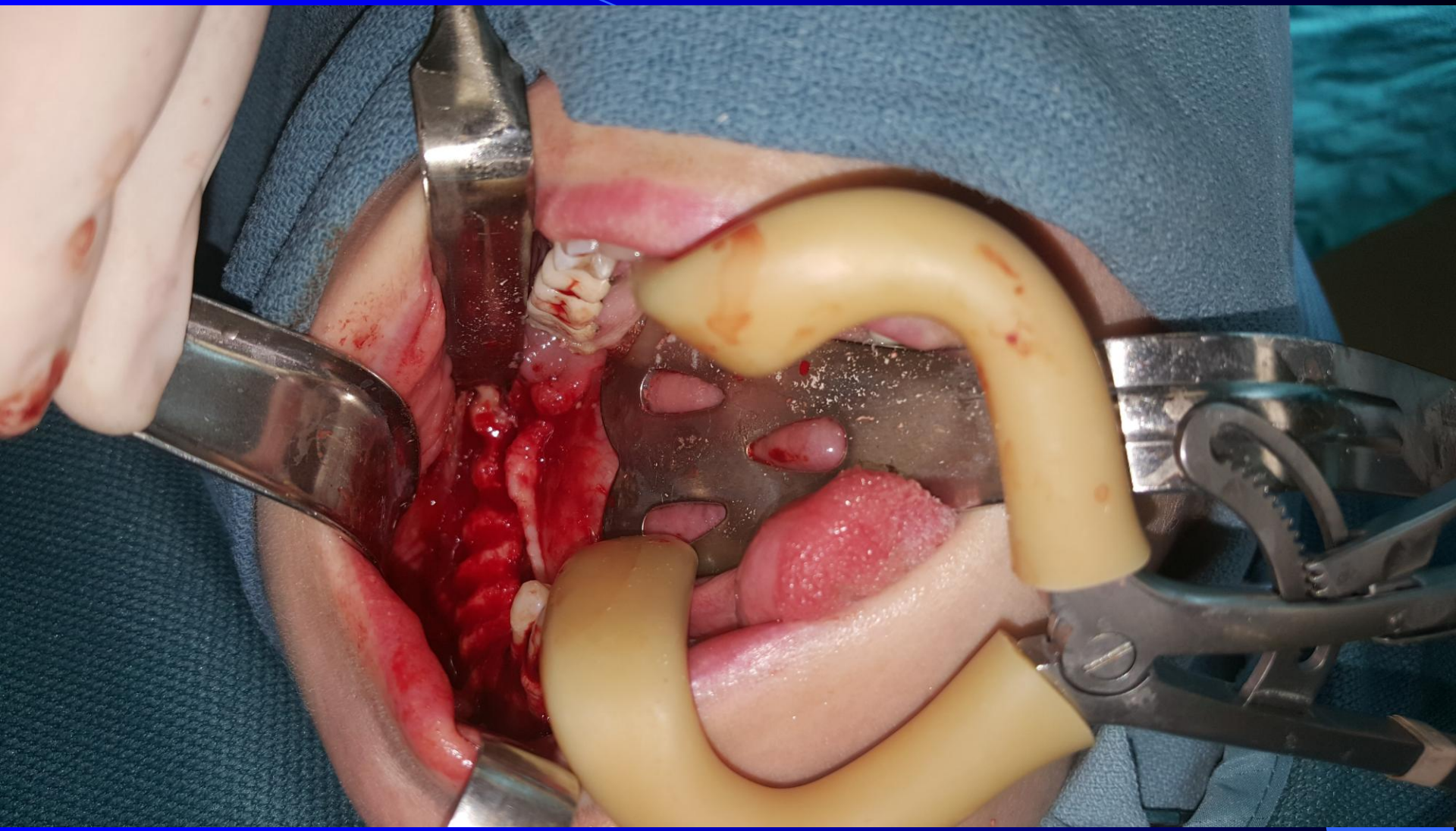

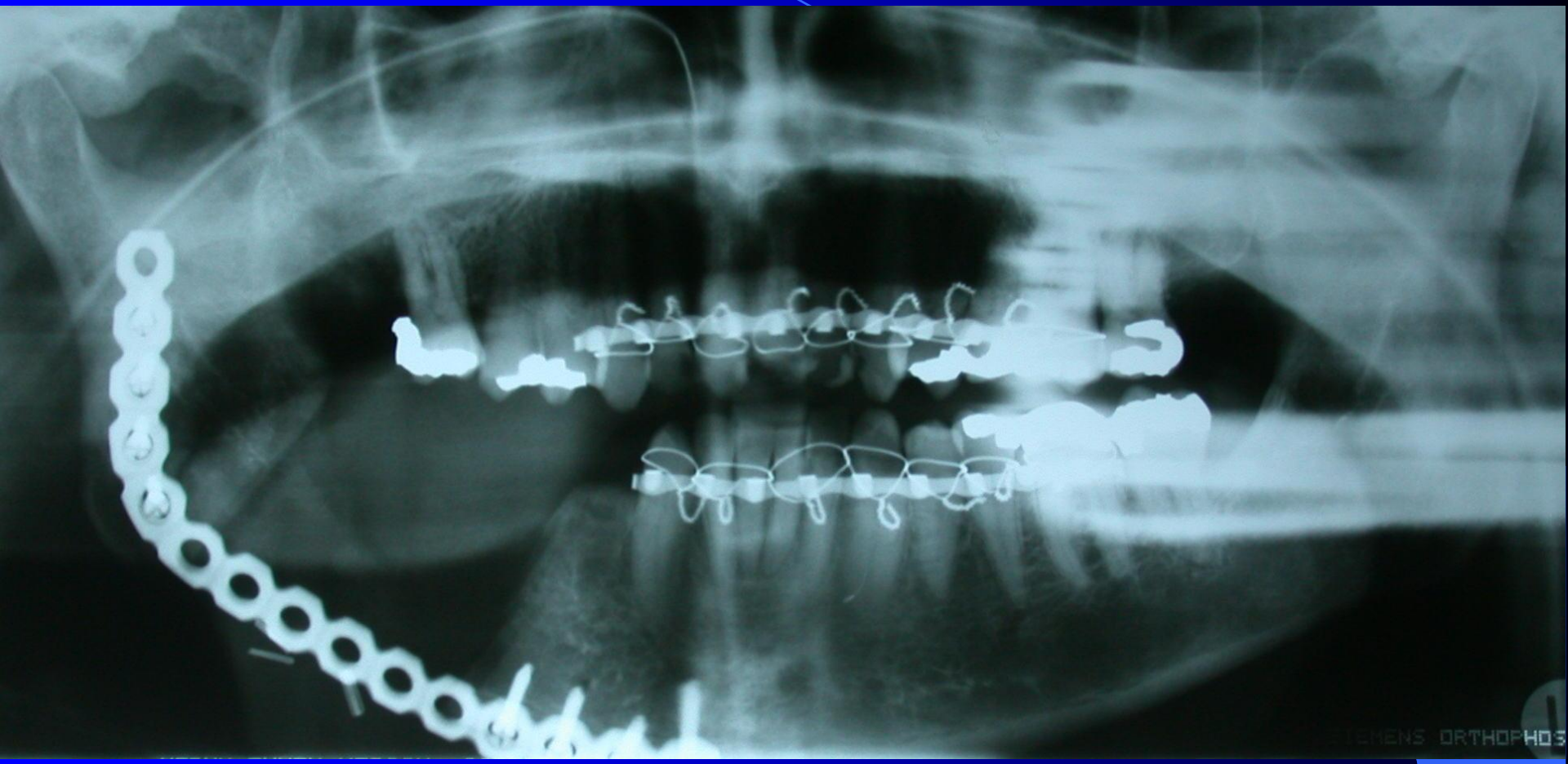
SIEMENS ORTHOPHOS

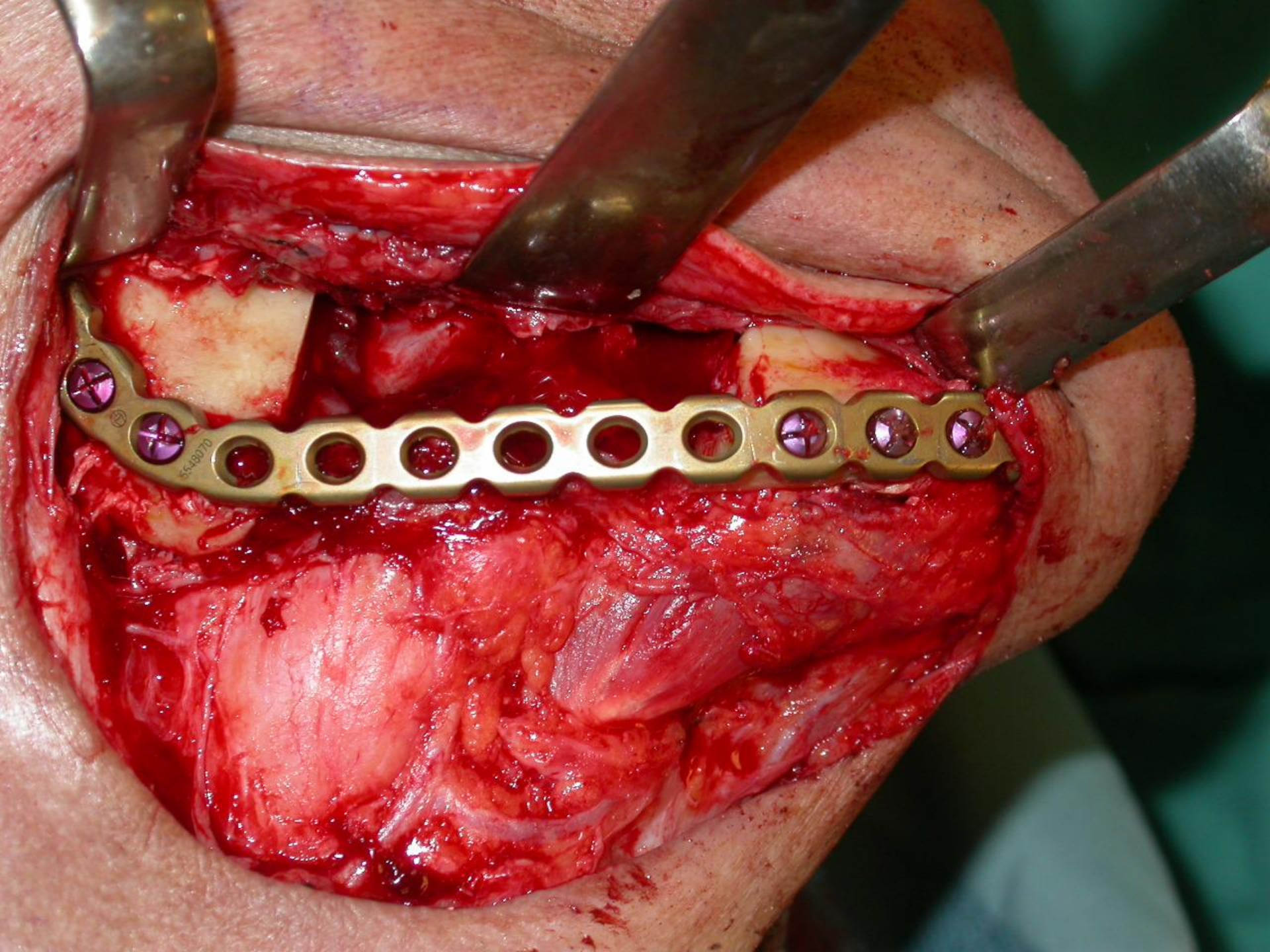

Questions