Left Anterior Oblique Projection at 55/60° combined with a Cranial angulation of 20°

The cranial angulation of 20°combined with the LAO projection at 55/60° is especially useful to study the LMCA

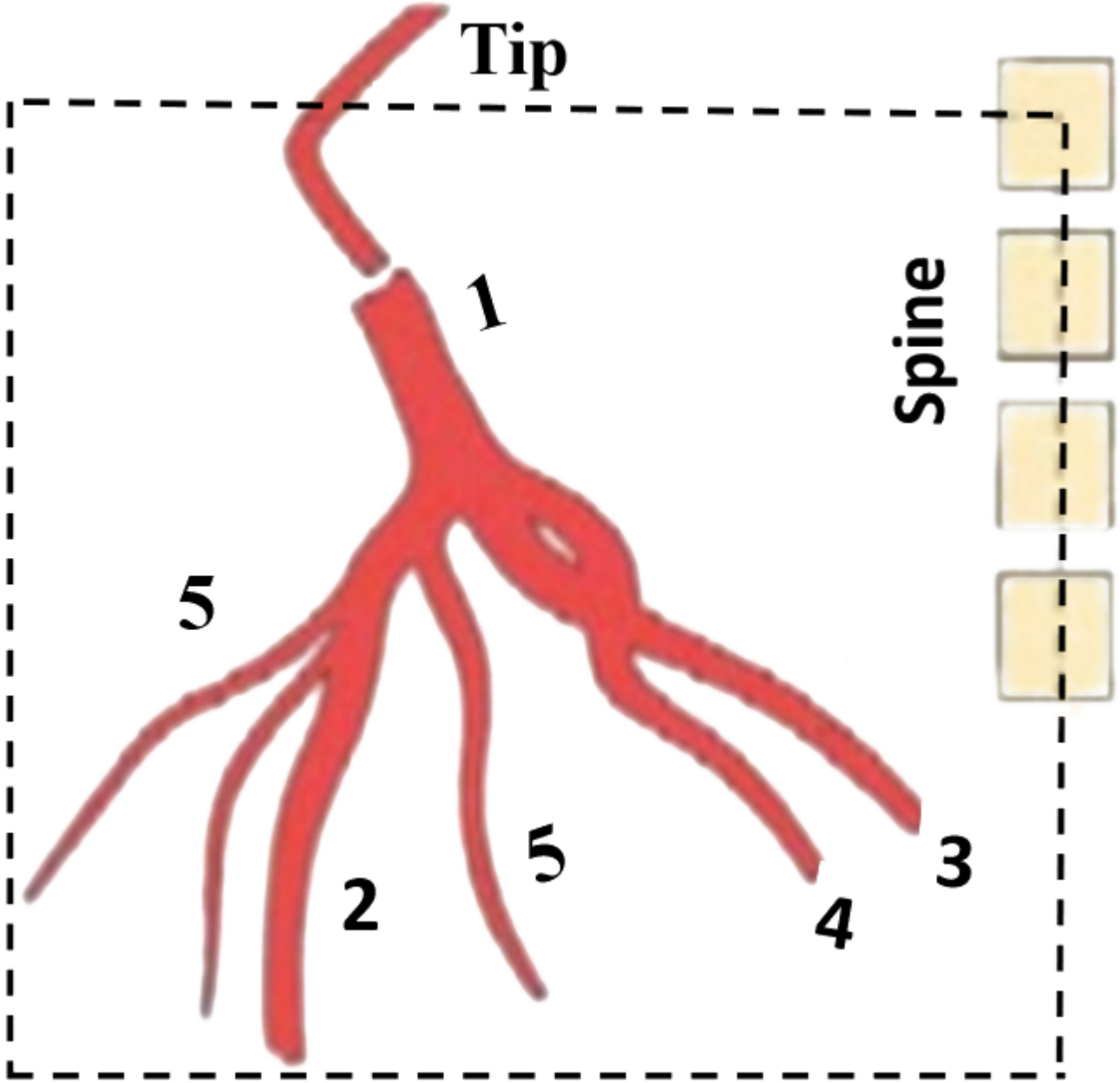

1. **LMCA**
2. **Middle part of the LAD**
3. **Proximal LCX**
4. **Obtuse Marginal Artery**
5. **Septal perforator branches**

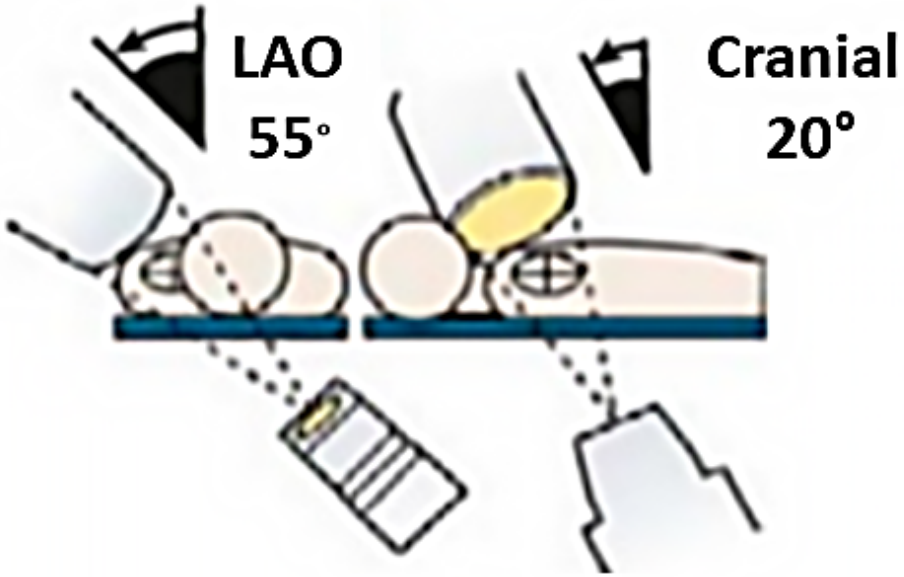

Left Anterior Descending Artery

- **Course**

  Down the anterior interventricular groove-usually reaches apex. In 22% of cases does not reach apex.

- **Branches**

  Septal and diagonals-supply lateral wall of LV, anterolateral papillary muscle; 37% have median ramus(courses like 1st diagonal).

- **LAD**

  Supplies anterolateral, apex and septum:≈45% -55% of the left ventricle.

The left anterior descending artery (LAD) is the largest coronary artery runs anterior to the interventricular septum in the anterior interventricular groove, extending from the base of the heart to the apex. The LAD gives two sets of branches.

Structure

It passes at first behind the pulmonary artery and then comes forward between that vessel and the left atrium to reach the anterior interventricular sulcus, along which it descends to the notch of cardiac apex. Although rare, multiple anomalous courses of the LAD have been described. These include the origin of the artery from the right aortic sinus. In 78% of cases, it reaches the apex of the heart.

Branches

The LAD gives off two types of branches: septals and diagonals. Septals originate from the LAD at 90° to the surface of the heart, perforating and supplying the anterior $^{2}/_{3}$ of the interventricular septum. Diagonals run along the surface of the heart and supply the lateral wall of the left ventricle and the anterolateral papillary muscle.

Function

The artery supplies the anterolateral myocardium, apex, and interventricular septum. The LAD typically supplies 45-55% of the left ventricle (LV) and is therefore considered the most critical vessel in terms of myocardial blood supply.

Left: Critical stenosis (95%) of the proximal LAD in a patient with Wellens' Warning.

Right: The same patient after reperfusion.

Further information: Wellens' sign

Widow maker is an alternative name for the anterior interventricular branch of the LAD. (***Topol, Eric J.; Califf, Robert M. (2007). Textbook of Cardiovascular Medicine. Lippincott Williams & Wilkins. p. 283. ISBN 9780781770125. Retrieved 6 November 2014. The most worrisome type is the proximal left anterior descending artery*** The name widow maker may also apply to the LMCA (**Barbara J. Aehlert; Robert Vroman (2011). "22". Paramedic Practice Today: Above and Beyond (1st ed.). Jones & Bartlett Publishers. p. 819. ISBN 978-0-323-08535-9. Retrieved 2 March 2015**.) or severe occlusions to that artery.(**Richard Beebe; Jeff Myers (11 December 2009). "34". Professional Paramedic, Volume I: Foundations of Paramedic Care. Cengage Learning. p. 764. ISBN 1-4283-2345-7. Retrieved 2 March 2015**)(**Carlos S Restrepo; Dianna M. E. Bardo (1 January 2011). Cardiac Imaging. Thieme. p. 188. ISBN 978-1-60406-186-4. Retrieved 2 March 2015**.) This term is used because the LMCA and/or the LAD supply blood to large areas of the heart. This means that if these arteries are abruptly and completely occluded it will cause a massive MI that will likely lead to sudden death. The blockage that kills is made up of platelets streaming to the site of a ruptured cholesterol plaque. Even a small amount of plaque in this area can (for a variety of poorly understood reasons) rupture and cause death; bypassing chronic blockages or trying to open them up with angioplasty does not prevent heart attack but it can restore blood flow in case of a sudden blockage or heart attack and if performed within a rapid time period can minimize the damage done. An example of the devastating results of a complete occlusion of the LAD artery was the sudden death of former NBC News Washington Bureau Chief Tim Russert,(**Morgan, David (June 13, 2008). "TV newsman Tim Russert dies of heart attack". Reuters. Archived from the original on June 24, 2008. Retrieved June 13, 2008**) as well as the near-death of film director Kevin Smith (https://www.livescience.com/61863-kevin-smith-widow-maker-heart-attack.html).

From the minute a widow maker heart attack hits, survival time ranges from minutes to several hours. Rapidly progressing symptoms should signal the need for immediate attention. Symptoms of initial onset may include nausea, shortness of breath, pain in the head, jaw, arms or chest, numbness in fingers, often of a novel but imprecise sensation which builds with irregular heart beat. Early symptoms may be mistaken for food poisoning, flu or general malaise until they intensify. A widow maker cannot kill instantly but induces cardiac arrest which may do so within 10 to 20 minutes of no circulation. A victim with no pulse or breath is still alive, living off oxygen stored in the blood and may be able to be rescued if treatment is begun promptly within this window.(**Kearl, Mary (June 2009). "Surviving a Widow-Maker Heart Attack". AOL Health. Retrieved June 22, 2009**.)

Left Circunflex (LCX)

It follows the left part of the coronary sulcus, running first to the left and then to the right, reaching nearly as far as the posterior longitudinal sulcus. There have been multiple anomalies described, for example the LCX having an aberrant course from the RCA.(**PAGE, H. L.; ENGEL, H. J.; CAMPBELL, W. B.; THOMAS, C. S. (1 October 1974). "Anomalous Origin of the Left Circumflex Coronary Artery: Recognition, Angiographic Demonstration and Clinical Significance". Circulation. 50 (4): 768–773. doi:10.1161/01.CIR.50.4.768**)

Branches

The LCX curves to the left around the heart within the coronary sulcus, giving rise to one or more left marginal arteries also called obtuse marginal branches (OM1 and OM2) as it curves toward the posterior surface of the heart. It helps form the posterior LV branch or posterolateral artery. The left marginal artery of the heart is a branch of the circumflex artery. It originates as the latter passes around the left border of the heart in the interventricular groove. The left marginal artery passes obliquely down the left border towards the apex of the heart. Its fine branches supply the LV. The LCX ends at the point where it joins to form to the LPD in 15% of all cases, which lies in the posterior interventricular sulcus. In the other 85% of all cases the LPD comes out of the RCA. When the LCX supplies the LPD in those 15% of cases, it is known as a left dominant circulation.

Structures supplied

The LCX supplies the basal-lateral LV and the anterolateral papillary muscle. It also supplies the sinoatrial nodal artery in 38% of people.

It supplies 15-25% of the LV in right-dominant systems. If the coronary anatomy is left-dominant, the LCX supplies 40-50% of the LV.

LCX Summary

- **Origin:**

  from distal LMCA

- **Course**

  Down distal left AV groove

- **Branches**

  Obtuse marginal

  Posterolateral-supply basal lateral LV, anterolateral papillary muscle.

  SA-Node 38%

- **Supplies**

  15%-25% of LV, unless dominant(supplies 40-50% of LV

- **Coronary Angiography**

  Left lateral view best visualizing proximal LCX

  Right Anterior Oblique projection 30° (RAO 30°): The RAP projection at 30° permits the entire circumflex system to be studied, as well as the first centimeters of tle anterior interventricular artery (see next slide)

Right Anterior Oblique projection 30° (RAO 30°)

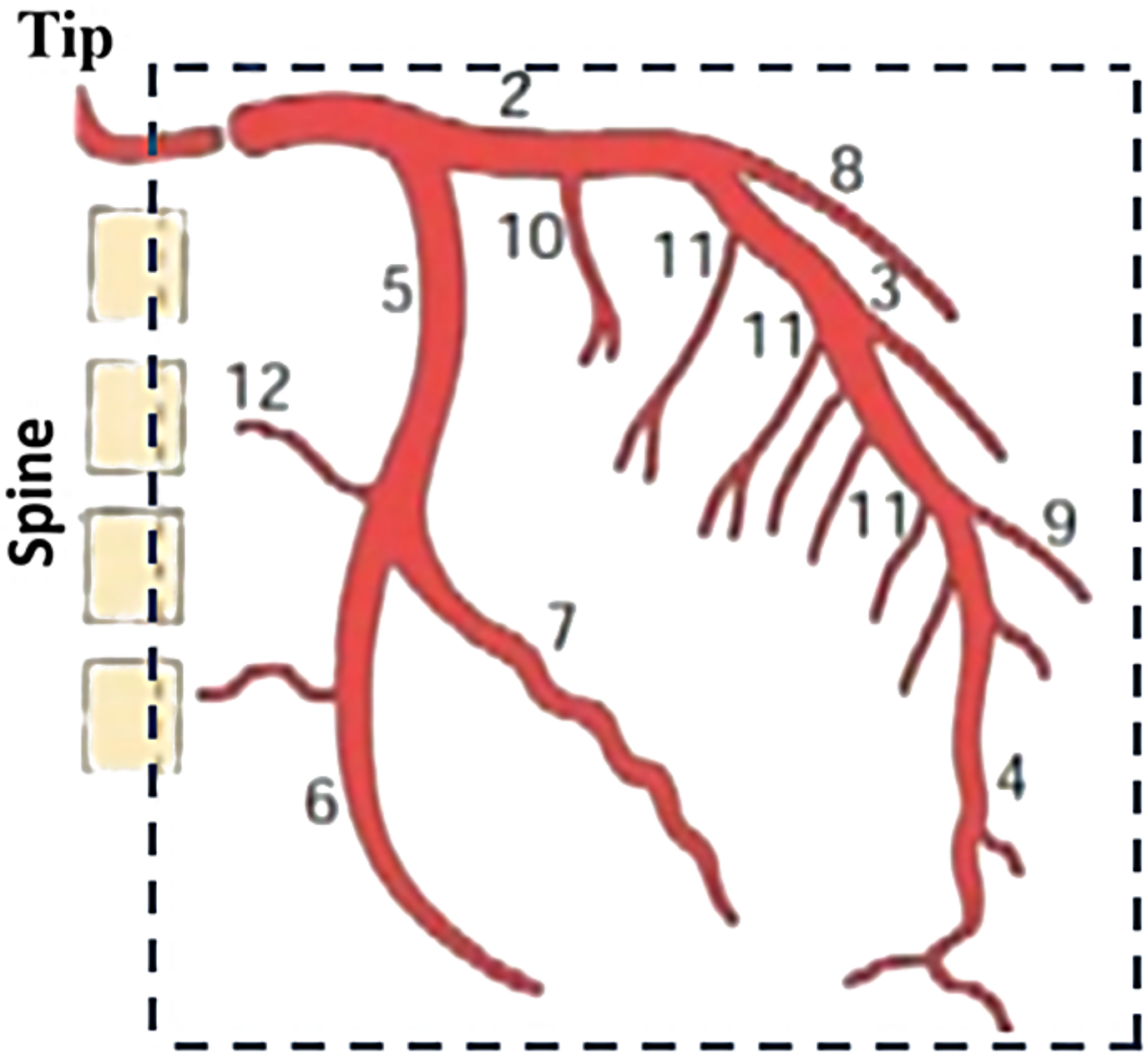

1. LMCA
2. Proximal part of LAD
3. Mid part of LAD
4. Distal parte of LAD
5. Proximal LCX
6. Distal LCX
7. Obtuse Marginal Artery
8. First diagonal artery
9. Second diagonal artery
10. First septal perforator artery
11. Septal arteries
12. Atrial branch of the LCX

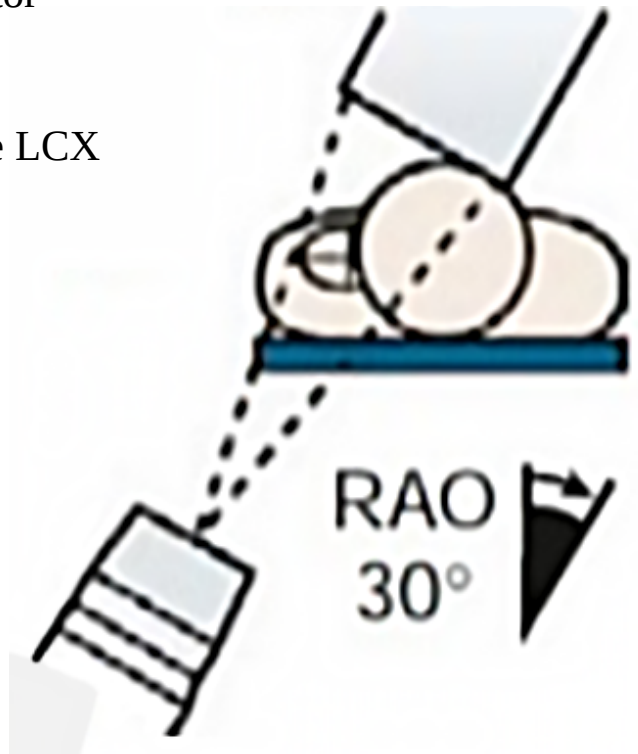

Coronary artery territories

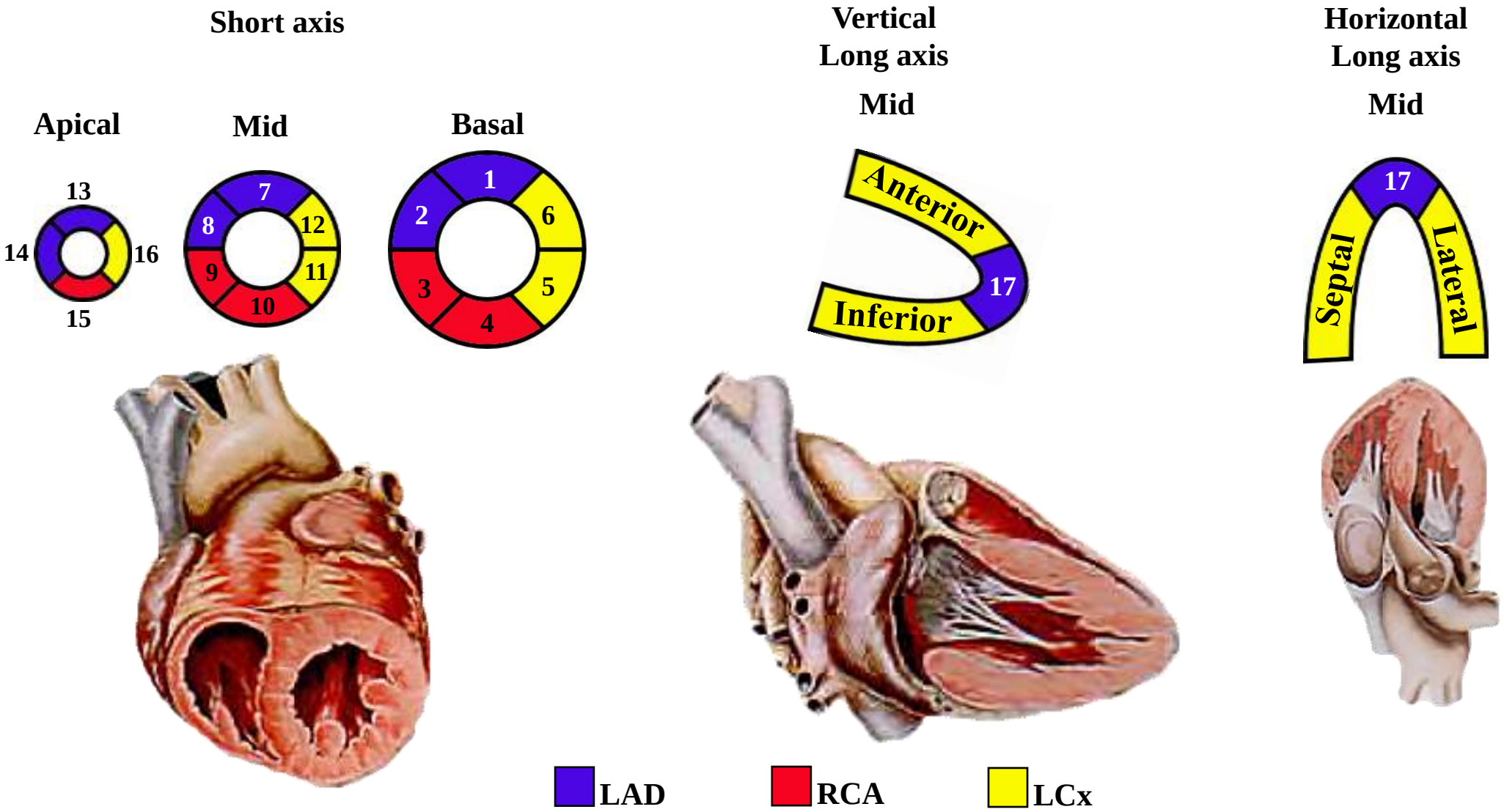

Cerqueira MD, Weissman NJ, Dilsizian V, Jacobs AK, Kaul S, Laskey WK, Pennell DJ, Rumberger JA, Ryan T, Verani MS; American Heart Association Writing Group on Myocardial Segmentation and Registration for Cardiac Imaging. Standardized myocardial segmentation and nomenclature for tomographic imaging of the heart. A statement for healthcare professionals from the Cardiac Imaging Committee of the Council on Clinical Cardiology of the American Heart Association. Circulation. 2002 Jan 29;105(4):539-42.

Left Ventricle myocardial segmentation, standard standard 17-segment model, and vascular territories

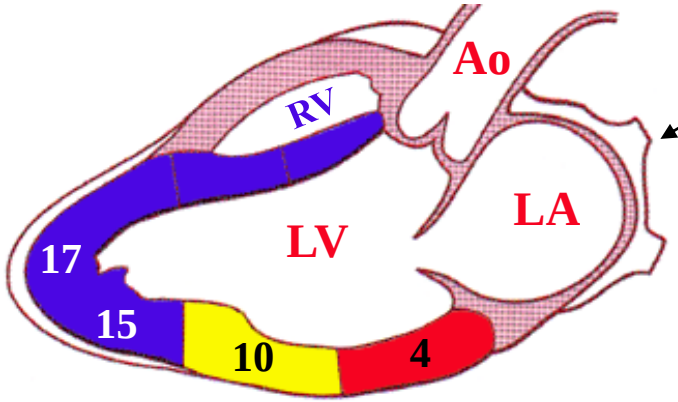

Longitudinal paraesternal

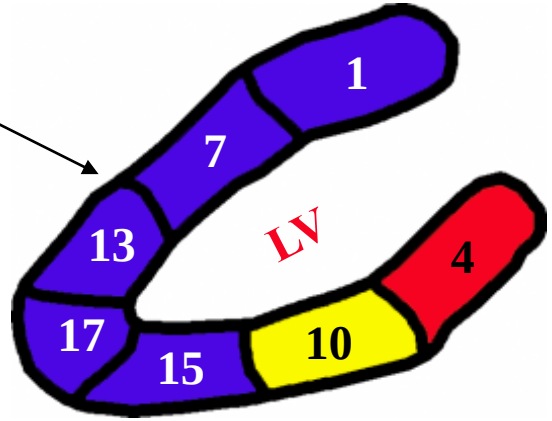

Bulls eye (apical short axis)

Anterior Wall

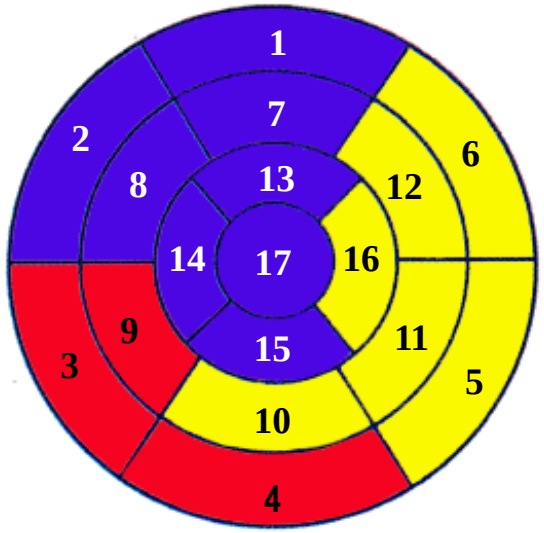

Septal Wall

Lateral Wall

Inferior Wall

Apical four chambers

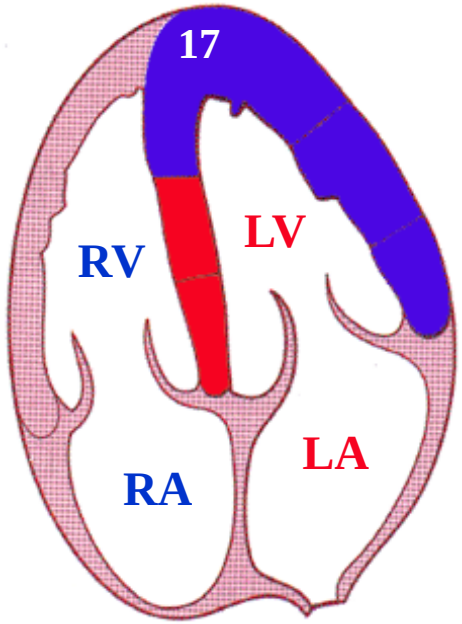

Apical two chambers

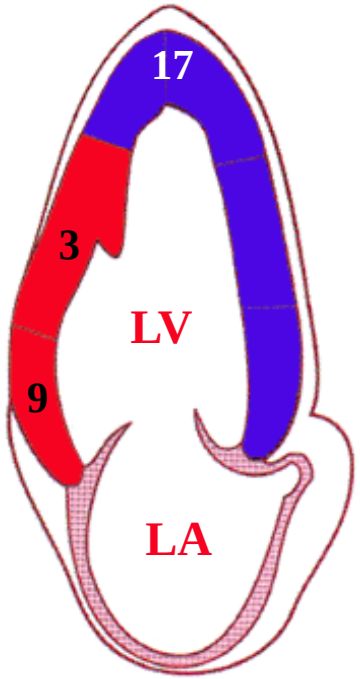

Left Anterior Descending (LAD)

Left Circunflex (LCx)

Posterior Descending (RCA or LCx)

The apex is analyzed separately, usually from a vertical long-axis slice.

Parasternal long axis (PLAX)

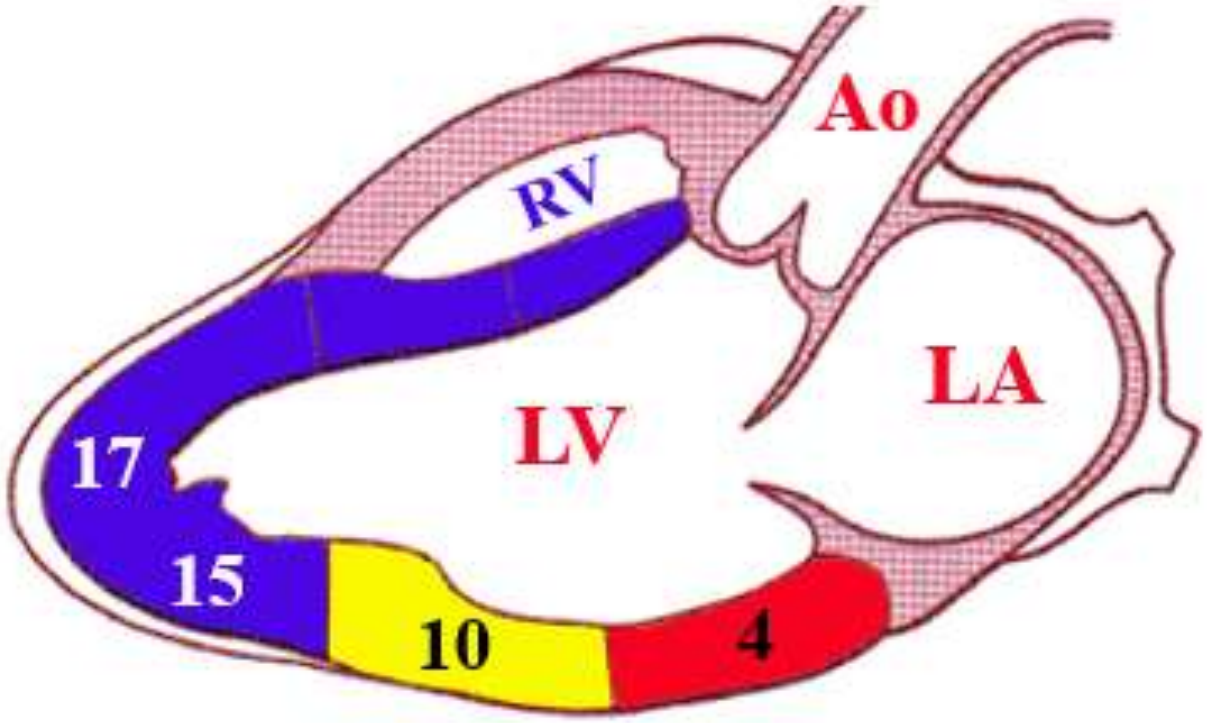

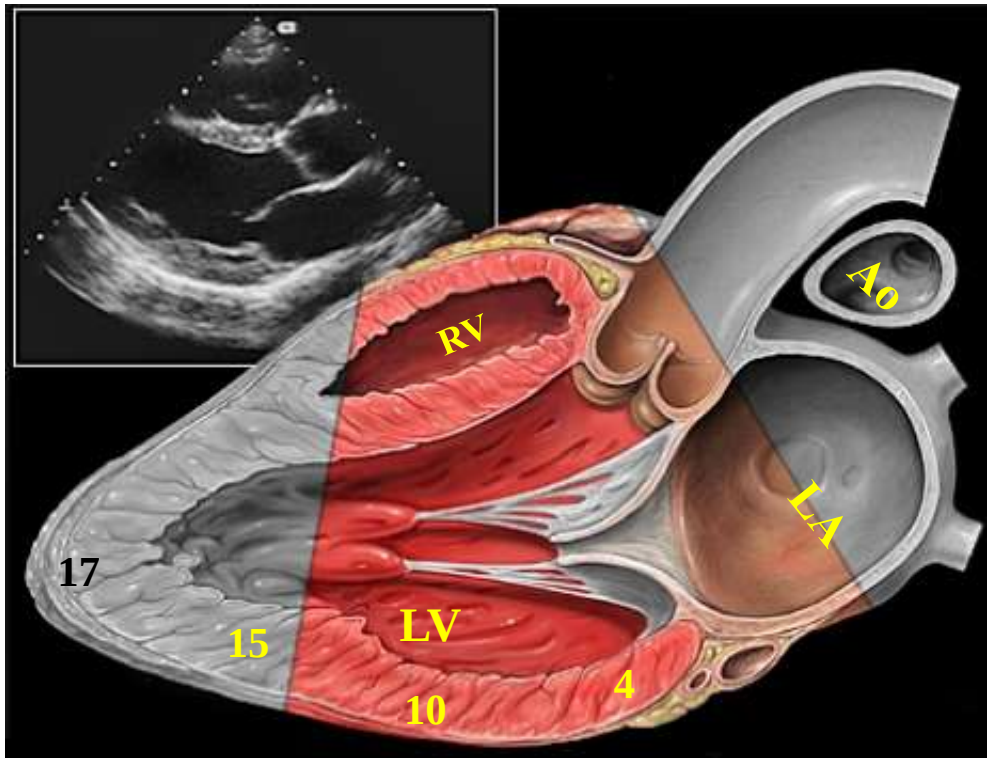

This view is obtained to the left of the sternum and views the heart in its long axis. In this view, the mitral valve, aortic valve, right ventricular outflow tract, base of the LV , and the LA can be visible. Angulation in this view can bring the right ventricular inflow tract and tricuspid valve into view, and angulation the opposite way can bring the pulmonary valve into view. In this view, it is possible to appreciate the long-axis cross section of the mitral and aortic valves. The classic "hockey stick" shape of rheumatic mitral stenosis can be appreciated in this view. However, the angle of the probe with these valves can lead to under-appreciation of valve dysfunction. The parasternal long view of the pulmonary valve is the only view of the posterior leaflet.

Structures visible: Anterior septal and inferior lateral walls of the LV; LA; Mitral valve in long-axis with chordae; Aortic valve in long-axis; Tricuspid valve in long-axis (angulated) and RVIT; Pulmonary valve in long-axis (angulated) and right ventricular; outflow tract; Measurements in this view can be used to quantify the heart:; Left ventricular size and wall thickness; Left atrial linear dimension (as opposed to area); Left ventricular outflow tract diameter (used to calculate aortic valve area by the continuity equation); Aortic annulus, sinus of Valsalva, and aortic root sizes. Color doppler of all four valves; Spectral doppler of tricuspid and pulmonary valves