CARDIOLOGY

CORONARY ARTERY ANATOMY

- **End arteries**
- Two main branches originating at the aortic root behind two of the aortic valve leaflets
  - Left main stem→ Left anterior descending **(LAD)** and Left circumflex **(LCx)**
  - Right coronary artery **(RCA)**
- Receive blood supply in **Diastole**

Artery		Branches	Supplies	Associated MI
Right Coronary Artery (RCA) (Right Artium, RV, posterior septum, inferior of both ventricles & both nodes)		SA nodal art (60% of population)	SA Node	-**Proximal RCA lesion** -RV, Inferior & Post -**Escape rhythm**
		Right Marginal Artery (or Acute Marginal Artery)	Right Ventricle	-RV
		AV Nodal Artery (very small branch on posterior)	AV Node	-**Proximal/ Mid RCA** -Inferior/Posterior -**Complete HB**
		Post Interventricular Artery* (or Posterior Descending Artery) (70% of population)	Posterior 1/3 of septum and inferior of both ventricles	-Inferior/ Posterior
Left Coronary Artery (or Left main stem)	**Left Anterior Descending (LAD)** (Anterior Interventricular Artery)	Diagonal Branches (above this is the Proximal LAD)	Anterio- lateral LV	-Anterior/ Lateral
		Septal Branches	Anterior 2/3 of Septum	-Septal **-Right or Left BBB** **-Complete HB**
	Left Circumflex Artery (LCx)	Left Marginal Arteries (Obtuse Marginal Artery)	Left atrium Posterio- lateral LV	-Posterior/ Lateral
		Post Interventricular Artery* (or Posterior Descending Artery) (10% of population)	Posterior 1/3 of septum and inferior of both ventricles	-Inferior/ Posterior

***Which artery (RCA or LCx) determines cardiac dominance; Right (70%) or Left (10%) in 20% it is a combination of both.**

This is important as which side has dominance determines other structures could be affected by thrombus i.e. if left dominant could have extensive posterior inferior and lateral LV damage, as well as septum but if right dominant could have RV infarct (no GTN!) or either SA or AV Nodes could be affected

Superior vena cava
Aorta
Right atrium
Right coronary artery
Posterior descending artery
Right marginal artery
Right ventricle
Left pulmonary artery
Left pulmonary veins
Left coronary artery
Left circumflex artery
Left marginal artery
Left anterior descending (or interventricular) artery
diagonal branch
Left ventricle
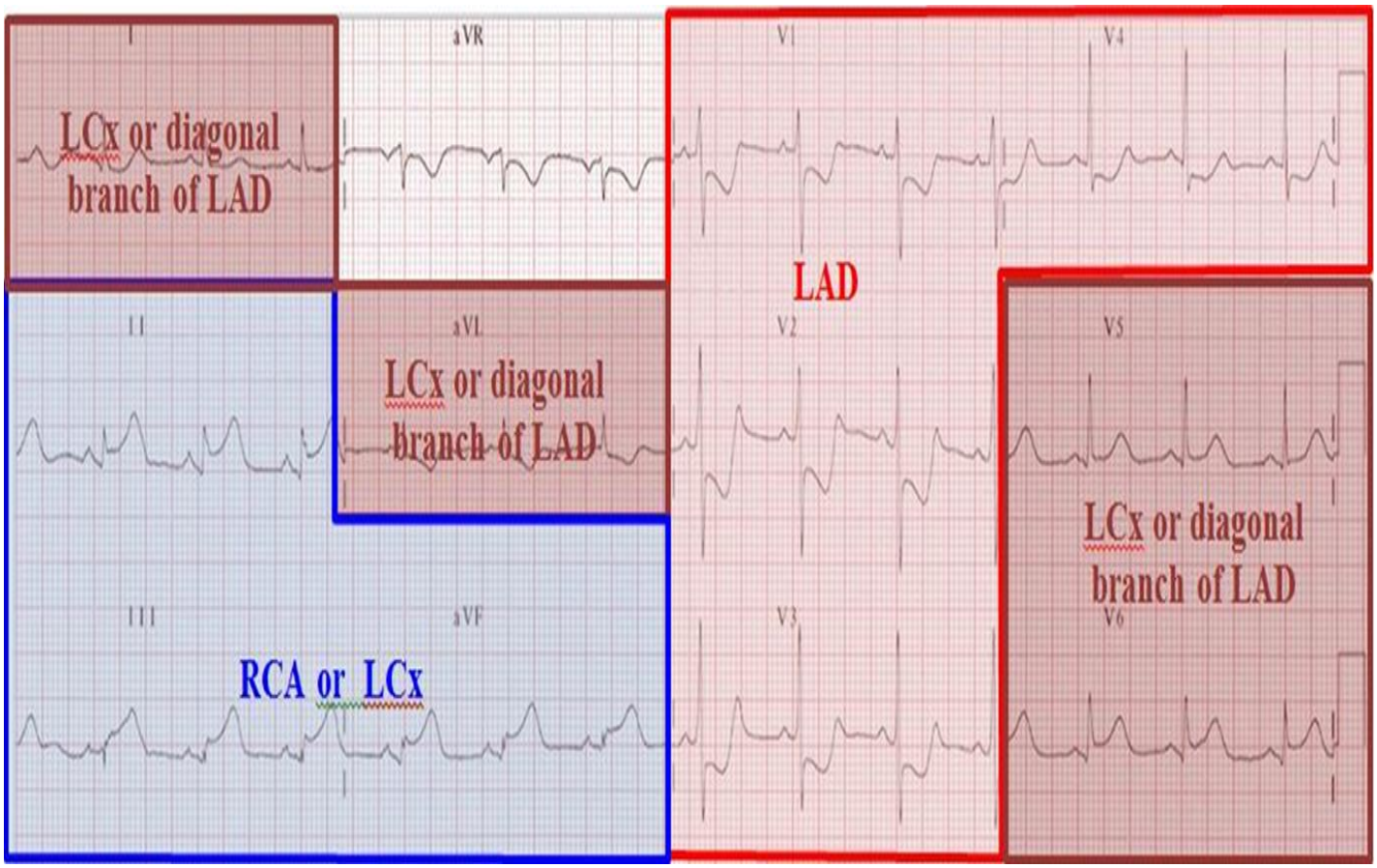
N.B. this is a right coronary artery dominant heart