Coronary Circulation: An Overview
Observations about Kugel's artery anatomy

“The heart has its reasons which reason knows not.”
Blaise Pascal (1623-1662)

French mathematician, physicist, inventor, writer and Catholic theologian.

By Andrés Ricardo **Pérez-Riera,** MD PhD
Laboratório de Metodologia de Pesquisa e Escrita Científica, Centro Universitário Saúde ABC, Santo André, São Paulo, Brazil.

Coronary Circulation: An Overview

Coronary arteries supply oxygenated blood to the heart, and cardiac veins drain away the blood once it has been deoxygenated. Heart circulation is of major importance not only to its own tissues but to the entire body and even the level of consciousness of the brain from moment to moment. Interruptions of coronary circulation quickly cause myocardial infarctions, in which the heart muscle is damaged by oxygen starvation. Such interruptions are usually caused by coronary artery disease and sometimes by embolism from other causes like obstruction in blood flow through vessels. Coronary arteries supply blood to the myocardium and other cardiac components. Two coronary arteries originate from the left side of the heart at the root of the aorta, just after the aorta exits the LV. There are three aortic sinuses (dilations) in the wall of the aorta just superior to the aortic semilunar valve. Two of these, the left posterior aortic sinus and anterior aortic sinus, give rise to the LMCA and RCA, respectively. The third sinus, the right posterior aortic sinus, typically does not give rise to a vessel. Coronary vessel branches that remain on the surface of the artery and follow the sulci of the heart are called epicardial coronary arteries.(**Betts, J. Gordon (2013). Anatomy & physiology. pp. 787–846. ISBN 1938168135. Retrieved 11 August 2014.**)The LMCA distributes blood to the left side of the heart, the LA and LV , and the interventricular septum(IVS). The LCX arises from the LMCA and follows the coronary sulcus to the left. Eventually, it will fuse with the small branches of the RCA. The larger anterior interventricular artery, also known as the LAD, is the second major branch arising from the LMCA. It follows the anterior interventricular sulcus around the pulmonary trunk. Along the way it gives rise to numerous smaller branches that interconnect with the branches of the posterior interventricular artery(LPD), forming anastomoses. An anastomosis is an area where vessels unite to form interconnections that normally allow blood to circulate to a region even if there may be partial blockage in another branch. The anastomoses in the heart are very small. Therefore, this ability is somewhat restricted in the heart so a coronary artery blockage often results in MI death of the cells supplied by the particular vessel. The RCA proceeds along the coronary sulcus and distributes blood to the RA, portions of both ventricles, and the

conduction system. Normally, one or more marginal arteries arise from the RCA inferior to the RA. The marginal arteries supply blood to the superficial portions of the RV. On the posterior surface of the heart, the RCA gives rise to the posterior descending artery PAD,. It runs along the posterior portion of the interventricular sulcus toward the apex of the heart, giving rise to branches that supply the interventricular septum and portions of both ventricles. (**Betts, J. Gordon (2013). Anatomy & physiology. pp. 787–846. ISBN 1938168135. Retrieved 11 August 2014.**).

Anastomoses

There are some anastomoses between branches of the two coronary arteries. However the coronary arteries are functionally end arteries and so these meetings are referred to as potential anastomoses, which lack function, as opposed to true anastomoses like that in the palm of the hand. This is because blockage of one coronary artery generally results in death of the heart tissue due to lack of sufficient blood supply from the other branch. When two arteries or their branches join, the area of the myocardium receives dual blood supply. These junctions are called anastomoses. If one coronary artery is obstructed by an atheroma, the second artery is still able to supply oxygenated blood to the myocardium. However, this can only occur if the atheroma progresses slowly, giving the anastomoses a chance to proliferate. Under the most common configuration of coronary arteries, there are three areas of anastomoses. Small branches of the LAD branch of the left coronary join with branches of the PDA of the RCA in the interventricular sulcus(groove). More superiorly, there is an anastomosis between the LCX (a branch of the LMCA and the RCA in the atrioventricular groove. There is also an anastomosis between the septal branches of the two coronary arteries in the interventricular septum.

Variation

The left and RCA occasionally arise by a common trunk, or their number may be increased to three; the additional branch being the posterior coronary artery (which is smaller in size). In rare cases, a person will have the third coronary artery run around the root of the aorta.

Occasionally, a coronary artery will exist as a double structure (i.e. there are two arteries, parallel to each other, where ordinarily there would be one).

Coronary Artery dominance

Coronary arterial dominance is defined by the vessel which gives rise to the posterior descending artery (PDA), which supplies the myocardium of the inferior 1/3rd of the interventricular septum. Most hearts (80-85%) are right dominant(RD) where the PDA is supplied by the RCA. The artery that supplies the posterior third of the interventricular septum – the PDA determines the coronary dominance.(**Gorlin R. Coronary anatomy. Major Prob Int Med 1976;11:40–58**.)(**Knaapen M, Koch AH, Koch C, et al. Prevalence of left and balanced coronary arterial dominance decreases with increasing age of patients at autopsy. A postmortem coronary angiograms study. Cardiovasc Pathol 2013;22:49–53**.) (**Fuster, V; Alexander RW; O'Rourke RA (2001). Hurst's The Heart (10th ed.). McGraw-Hill. p. 53. ISBN 0-07-135694-0**.). In conclusion coronary artery dominance is classified as LD, RD or CD depending on the origin of the posterior descending artery (PDA)

- ***If the PDA is supplied by the RCA, then the coronary circulation can be classified as "right-dominance"(RD).≈70% of cases;***
- ***If the PDA is supplied by the L(CX, a branch of the left artery, then the coronary circulation can be classified as "left-dominance"(LD). ≈20% of cases;***
- ***If the PDA is supplied by both the RCA and the LCX, then the coronary circulation can be classified as "co-dominant" or*** **"balanced coronary arterial dominance" or CD.** ***≈10% of cases. See figure in the next slide***.

I. Right dominance **II. Left dominance**

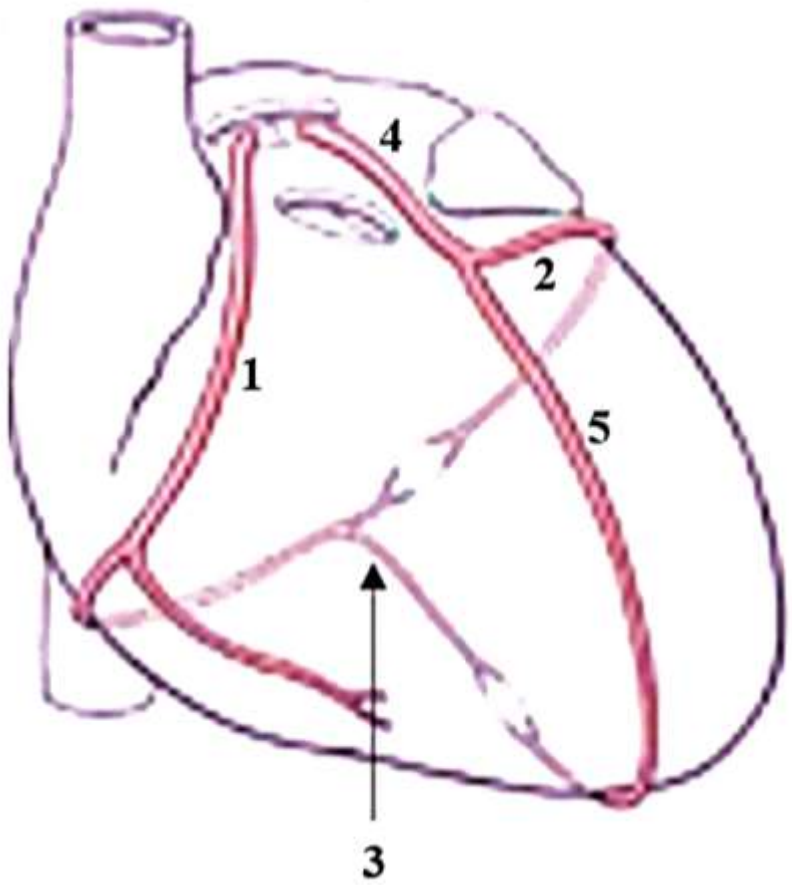

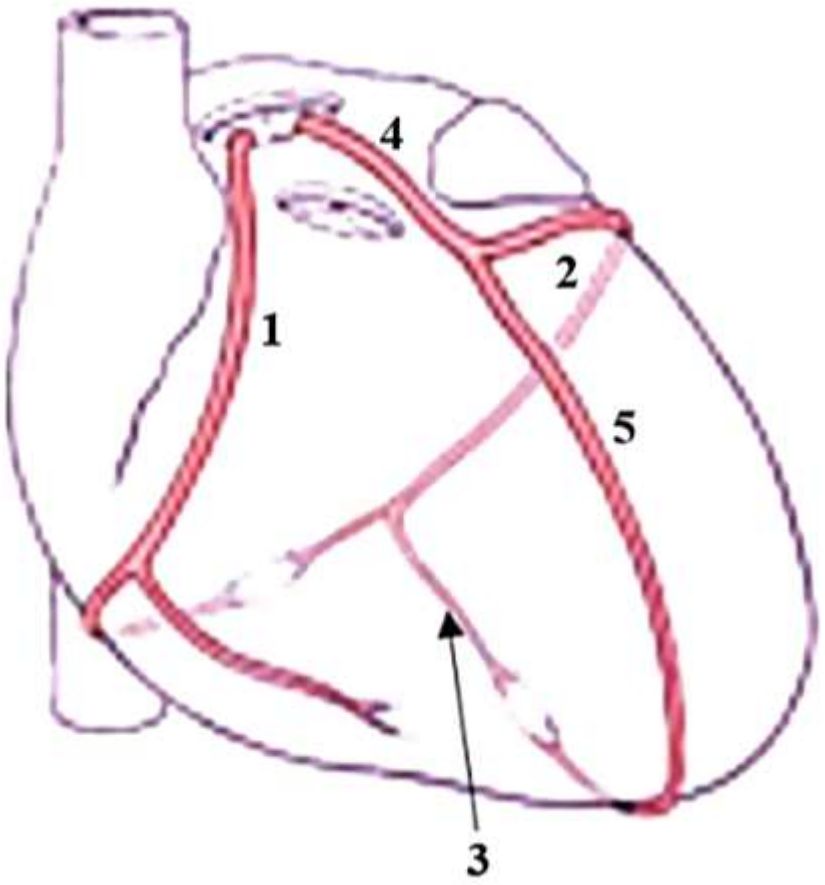

I. If the posterior Descending Artery (PDA) is supplied by The Right Coronary Artery (RCA), then the coronary circulation can be classified as "right-dominance".

II. If the Posterior Descending Artery (PDA) is supplied by the Left Circumflex Artery (LCX) , then the coronary circulation can be classified as "right-dominance".

1. **Right Coronary Artery (RCA); 2. Left Circumflex Artery (LCX); 3. Posterior Descending Artery (PDA); 4. Left Main Coronary Artery; 5. Left Anterior Descending Artery** (**LAD**)

Impact of Right Coronary Dominance on Triple-Vessel Coronary Artery Disease

Recently, Peng L et al (**Liyuan Peng 1, Xincheng Guo 2, Ya Gao 3, Qi Guo 4, Jingjing Zhang 3, Bangjiang Fang 5, Bin Yan 1. Impact of Right Coronary Dominance on Triple-Vessel Coronary Artery Disease: A Cross-Sectional Study. Medicine (Baltimore) , 97 (32), e11685 Aug 2018 PMID: 30095625 PMCID: PMC6133631 DOI: 10.1097/MD.0000000000011685**) investigate the relationship between right coronary dominance and coronary angiographic characteristics in patients with or without significant coronary artery disease (CAD).

A total of 2225 patients undergoing coronary angiography between January 2011 and November 2014 were recruited in the study. Based on the coronary angiography results, patients were divided into the left dominance (LD) group, right dominance (RD) group, and co-dominance (CD) group. Multinomial logistic regression was applied to analyze the relationships between coronary dominance and triple-vessel CAD.

They found that patients with RD had a higher prevalence of triple-vessel CAD (36.6% vs 27.3%, $P=.008$) and significant stenosis in the RCA (40.5% vs 29.2%, $P=.001$). In addition, results of multinomial logistic regression analysis showed that RD was significantly associated with the triple-vessel disease (odds ratio 1.768, 95% confidence interval 1.057–2.956, $P=.030$).

In conclusion, RD positively correlated with triple-vessel CAD rather than LD or CD in patients. This result suggested that RD may serve as a risk factor for triple-vessel CAD and more effective measures should be taken in RD patients to prevent fatal cardiovascular events.

The papillary muscles of the Mammalians heart

The papillary muscles(PMs) are the involuntary muscles located in the ventricles of the mammalian heart. They are components of the The mitral valve apparatus. This apparatus has six components: 1) the left atrial wall, 2) the mitral annulus, 3) the mitral valve leaflets, 4) the chordae tendineae, 5) the papillary muscles, and 6) The left ventricular wall. This is a complex three–dimensional functional unit that is critical to unidirectional heart pump function. The last one are attach to the cusps of the atrioventricular valves (the mitral and the papillary muscles are the involuntary muscles which are present in the ventricles of the mammalian heart. They support the tricuspid valves and mitral valves. The contraction of the papillary muscles opens these values when the papillary muscles relax, the valves get closed. Chordae tendineae connects the papillary muscles to the valves. Chordae tendineae connects the papillary muscles to the tricuspid valves via the chordae tendineae and contract to prevent inversion or prolapse of these valves inside de atriums during the ventricular contraction) (**Moore KL, et al. 2007**). The PMs constitute about 10% of the total heart mass.

Structure

There are five total papillary muscles in the heart; three in the right ventricle and two in the left. The anterior, posterior, and septal papillary muscles of the RV each attach via chordae tendineae to the tricuspid valve. There are typically two papillary muscles arising from the area between the apical and middle thirds of the LV free wall. The anterolateral papillary muscle is often composed of one body or head, whereas the posteromedial papillary muscle may have two or more heads. Each papillary muscle provides chordae to both leaflets, and the axial relationship of the chordae prevents chordal abrasion or dyssynchrony. The attachment of the papillary muscles to the lateral wall of the LV indicates that the ventricle is also an important part of the mitral valve complex. Any change in ventricular geometry that affects papillary muscle position can change the axial relationship of the chordae and leaflets, resulting in valve dysfunction

Supply to papillary muscles

The papillary muscles attach the mitral valve (the valve between the LA and the LV) and the tricuspid valve (the valve between the RA and the RV) to the wall of the heart. The **papillary muscles** are **muscles** located in the ventricles of the heart. They attach to the cusps of the atrioventricular valves via the chordae tendineae and contract to prevent inversion or prolapse of these valves on systole. If the papillary muscles are not functioning properly, the mitral valve may leak during contraction of the LV . This causes some of the blood to travel "in reverse", from the LV to the LA , instead of forward to the aorta and the rest of the body. This leaking of blood to the LA is known as mitral regurgitation. Similarly, the leaking of blood from the RV through the tricuspid valve and into the RA can also occur, and this is described as tricuspid insufficiency or tricuspid regurgitation. The anterolateral papillary muscle more frequently receives two blood supplies: LAD artery and the LCX.(**Voci P, Bilotta F, CarettaQ, Mercanti C, Marino B (1995). "Papillary muscle perfusion pattern. A hypothesis for ischemic papillary muscle dysfunction". Circulation. 91 (6): 1714–8. doi:10.1161/01.cir.91.6.1714. PMID 7882478**.) It is therefore more frequently resistant to coronary ischemia. On the other hand, the posteromedial papillary muscle is usually supplied only by the PDA. This makes the posteromedial papillary muscle significantly more susceptible to ischemia. The clinical significance of this is that a MI involving the PDA is more likely to cause mitral regurgitation.

Components of the Mitral Valve Apparatus

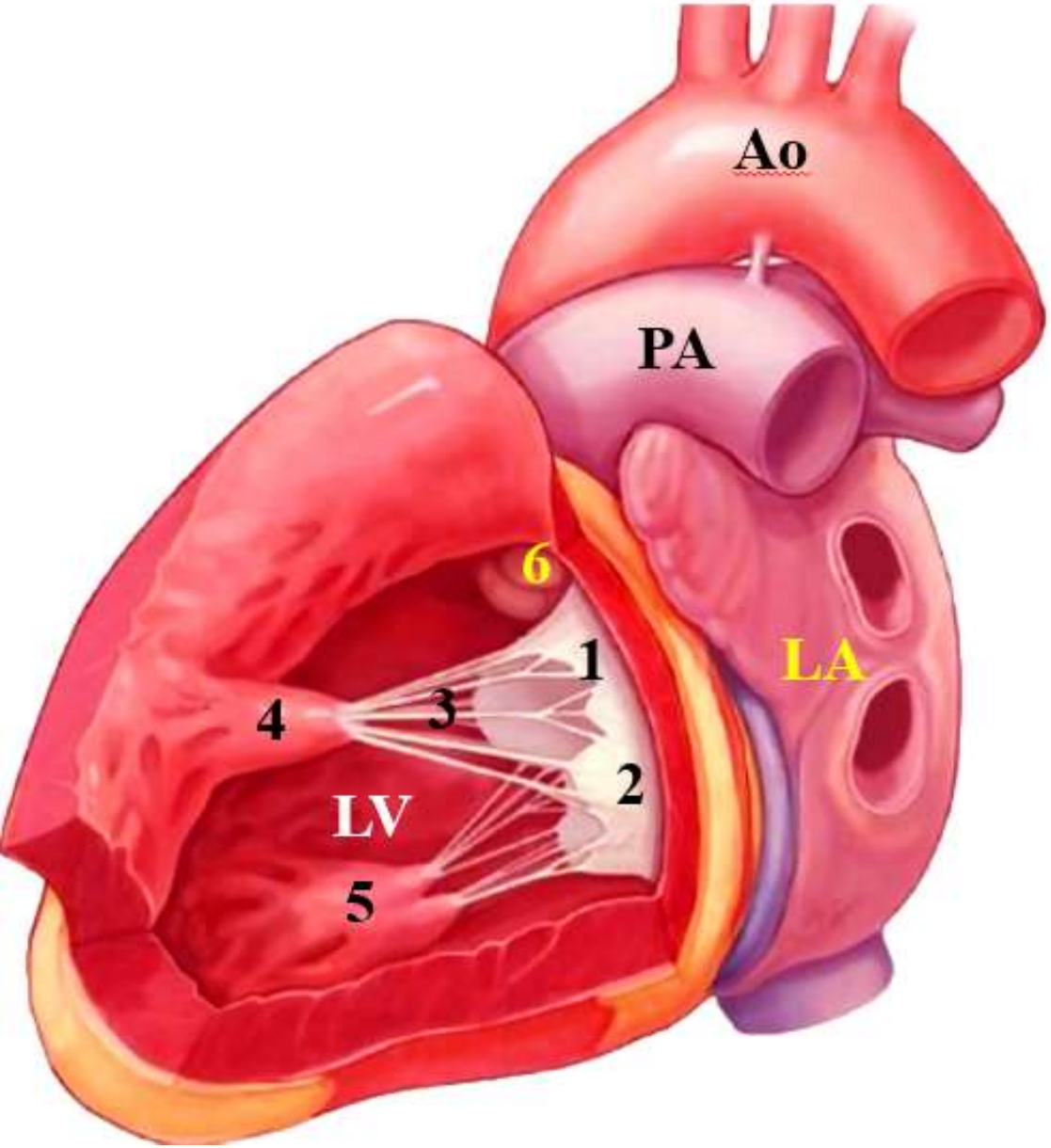

Ao: Aorta; PA: Pulmonary Artery; LA: Left Atrium; 6: Aortic valve.

The mitral valve apparatus is a complex three–dimensional functional unit that is critical to unidirectional heart pump function. The main mitral valve apparatus components are:

1) ***Anterior leaflet of mitral valve***
2) ***Posterior leaflet of mitral valve***
3) ***Chordae tendineae***
4) ***Anterolateral papillary muscle***
5) ***Posterolateral papillary muscle***
6) ***Aortic valve***

Ao) Aorta

LA) Left atrium

LV) Left ventricle

PA) Pulmonary artery

Example of total obstruction in middle part of Right Coronary Artery (RCA): R-2

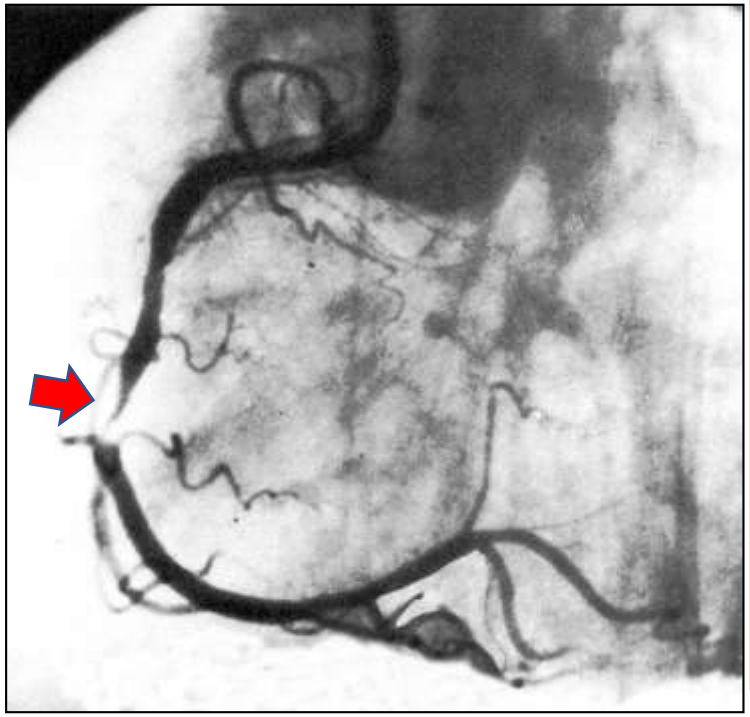

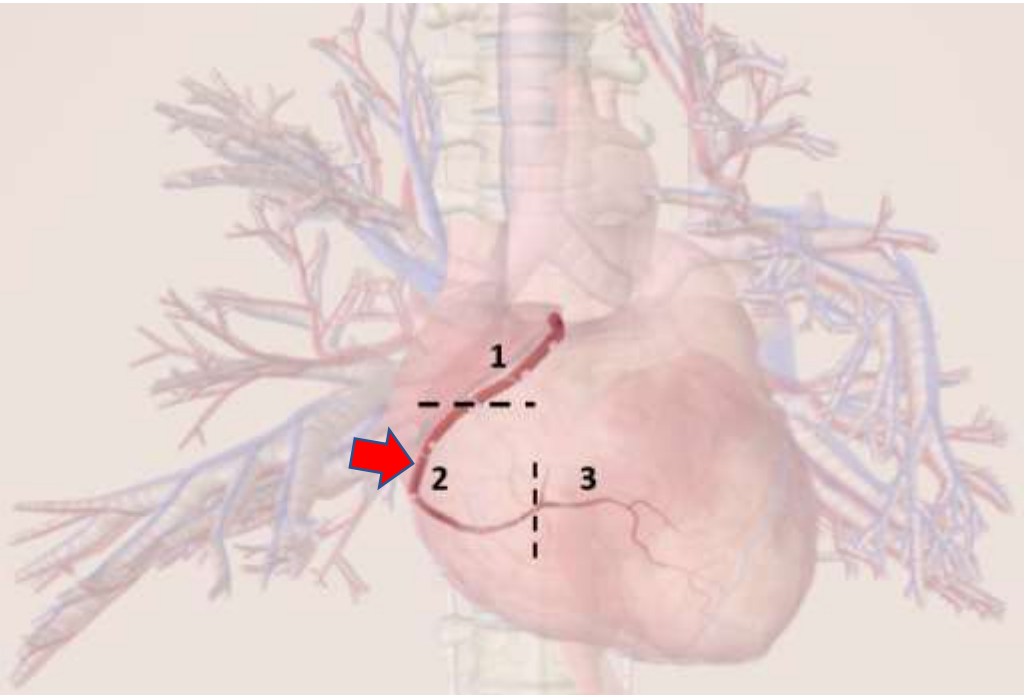

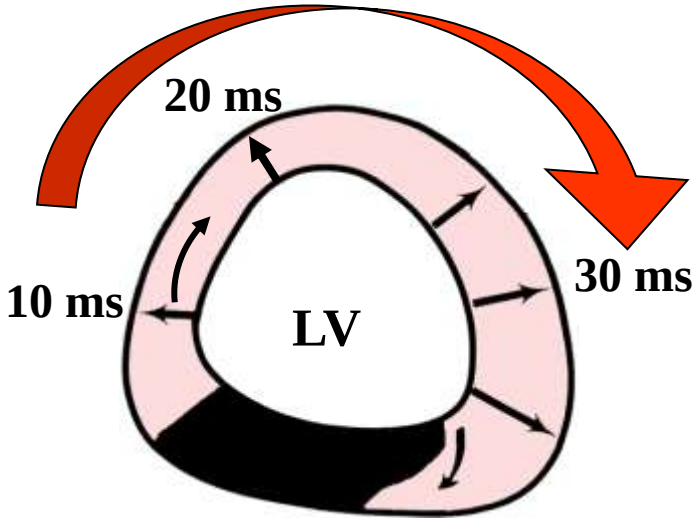

Bulls eye (apical short axis)

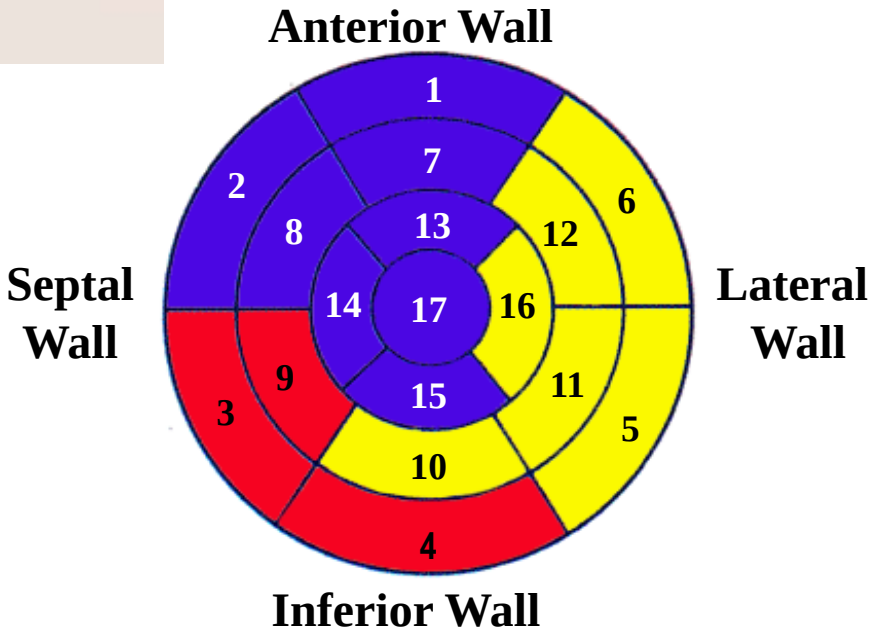

Posterior Descending (RCA or LCx)