Main Coronary Arteries The coronary tree

I. ***Left Main Coronary Artery, Left Main, the left main stem coronary artery (LMCA/LCA), the Left Mai Trunk, the Left Main Stem coronary artery (abbreviated LMS):*** The LMCA runs from its origin in the aorta to its bifurcation into:

- The left anterior descending(LAD)
- Left circumflex artery (LCX).

    I. *Obtuse marginal artery #1 (OM1) Obtuse marginal artery #2 (OM2)*

    II. *Posterior descending artery (PDA. Only in 10% of the cases(Left dominance)*

II. ***Left Anterior Descending Artery (LAD):***

I. *Diagonal arteries:*

1 - Dg1 or first diagonal;

2 - Dg2 Diagonal artery 2 - or second diagonal

II. *Anterior Septal Perforator Branches:*

I. S_1*: First Septal Perforator branch;*

II. S_2***:*** *Second Septal Perforator and*

III. S_3***:*** *Third Septal Perforator branch*

III. Right Coronary Artery (RCA):

1. *The conus (arteriosus) artery which runs to the right ventricular outflow tract*
2. *The atrial branch which gives off the SA nodal artery (in ~ 60 % of hearts), which runs along the anterior RA to the SVC, encircling it before reaching the SA node*
3. *Atrioventricular nodal branch*
4. *Right marginal branch/artery; of is a large marginal branch which follows the acute margin of the heart and supplies blood to both surfaces of the RV.*
5. *Posterior descending artery (PDA); It is typically a branch of the RCA (70%, right dominance).*
6. *Posterolateral artery #1 (PL#1) and*
7. *Posterolateral artery #2 (PL#2)*

The Coronary tree

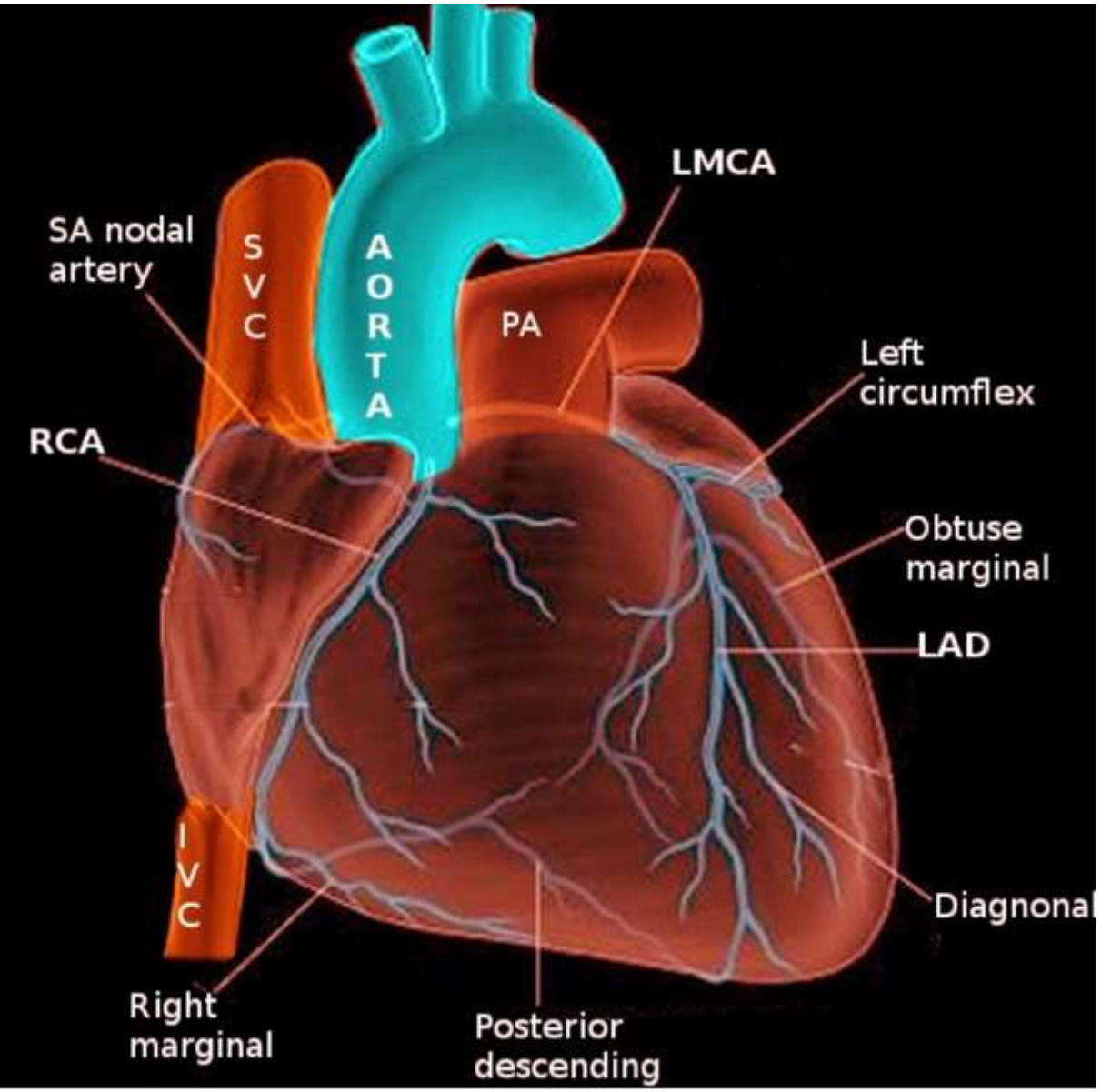

Left Main Coronary Artery(LMCA): the LMCA branches into the circumflex and LAD In about 15% of people, the LMCA gives rise to both of the interventricular arteries. The LMCA supplies blood to the left side of the heart.

Right Coronary Artery (RCA): The RCA supplies blood to the right side of the heart. The RCA gives rise to the sinoatrial nodal branch of the RCA IN 60% of cases, PDA branch of the RCA, and the marginal branch. supplies blood to the RA, RV, SA node, AV node and helps supply blood to the septum. The atrioventricular nodal artery supplies the AV node and comes of the RCA.

Left Anterior Descending (LAD) Supply blood to the LA and LV. The LAD supplies blood to the front and the left side of the heart, ventricular septum and the greater portion of the anterior portion of the LV.

Left Circumflex (LCX): Supply blood to the LA and the basal-lateral aspect of the LV. The LCx supplies blood to the lateral wall of the LV and sometimes to the basal inferior aspect of the heart when there is left heart dominance.

Acute marginal Artery or marginal branch of the RCA: provides blood supply to the lateral portion of the RV.

Posterior Descendam Artery (PDA): supplies blood to the inferior aspect of the septum.

Obtuse Marginal: the obtuse marginal branches supply the inferior wall directly.

Right Marginal of RCA or right marginal artery) is a large marginal branch which follows the acute margin of the heart and supplies blood to both surfaces of the right ventricle.

Coronary circulation

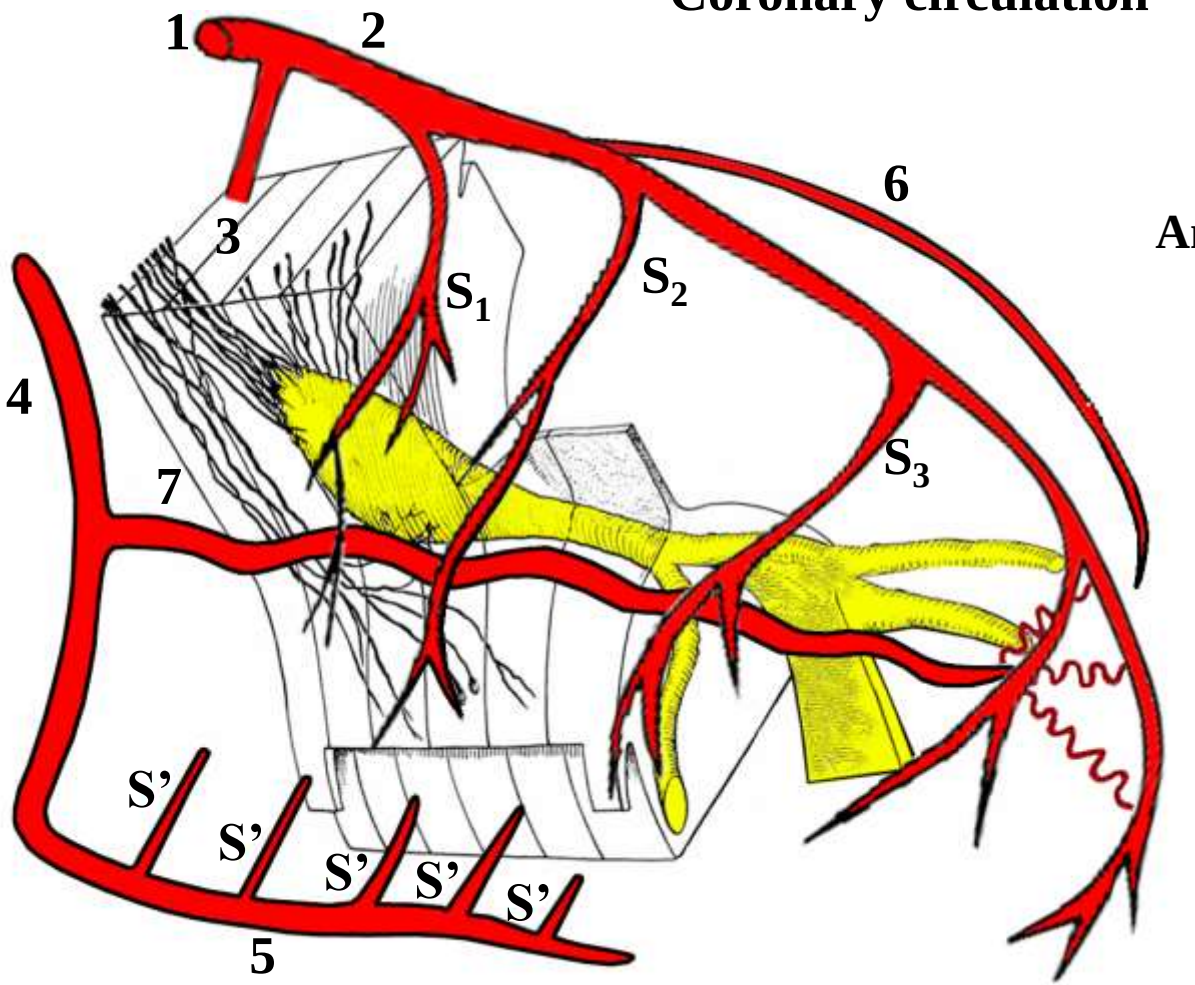

Anterior Septal Perforator Branches

S_1: First Septal Perforator branch
S_2: Second Septal Perforator
S_3: Third Septal Perforator

S': Posterior Septal Perforators

1. Left Main Coronary Artery (**LMCA)**
2. Left Anterior Descending Artery (**LAD)**
3. Left Circumflex Coronary Artery (**LCX)**
4. Right Coronary Artery (**RCA)**
5. Posterior Descending Artery (**PDA**). In this case is supplied by the RCA, then the coronary circulation can be classified as "right-dominance“
6. First Diagonal (**Dg**)
7. Acute Marginal (**A. Mg)**

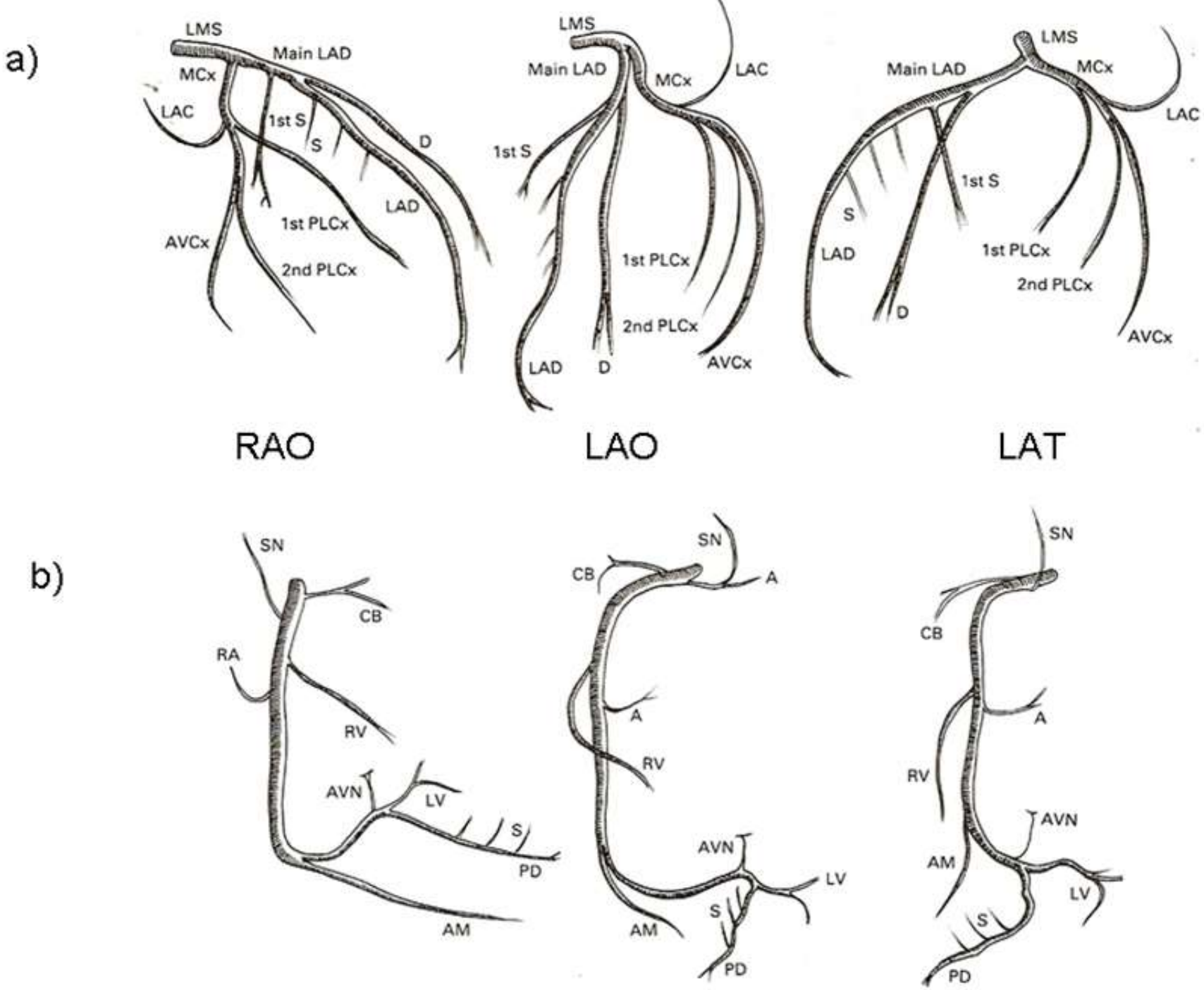

Coronary artery anatomy. a) Left coronary artery and b) Right coronary artery. A, atrial branch; AM, acute marginal artery; AVCx, atrioventricular groove branch of circumflex; AVN, atrioventricular node artery; CB, conus branch; D, diagonal branch of LAD; LAC, left atrial circumflex; LAD, left anterior descending; LAO 30° left anterior oblique projection; LAT, left lateral projection; LMS, left main stem; LV, left ventricular branches; MCx, main circumflex; PD, posterior descending; PLCx, posterior circumflex branch (obtuse marginal); RA, right atrial branch; RAO, 30° right anterior oblique projection; RV, right ventricular branch;

S, septal perforating arteries;

SN, sinus node artery.

The left Coronary Artery tree

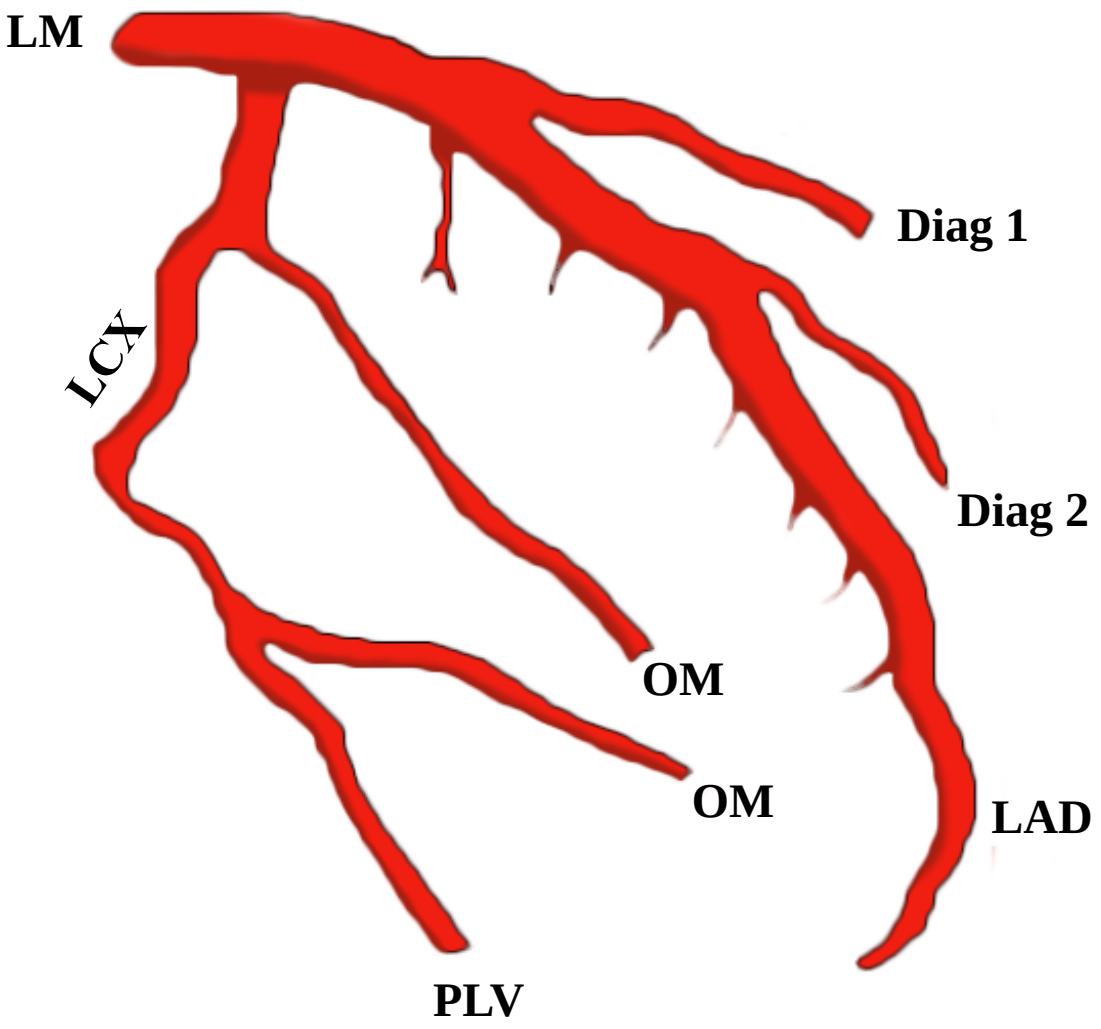

The American Heart Association divides the LMCA: left main coronary artery, LM: left main artery, 8. LAD: left anterior descending artery, 9 Diag 1: 1st diagonal branch, Diag 2: 2nd diagonal branch, LCX: left circumflex artery, OM: obtuse marginal branch

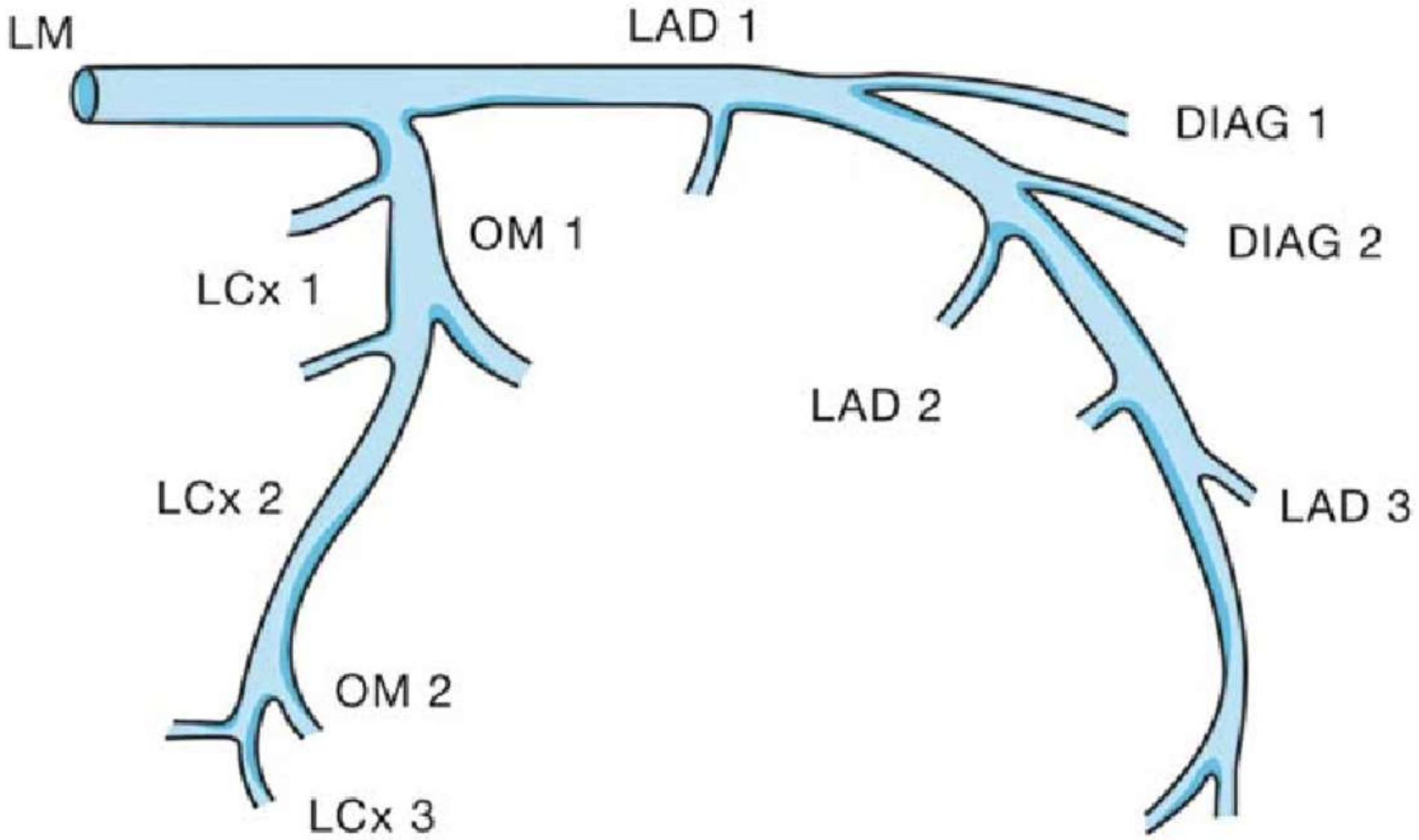

Fig. Left coronary artery in caudal right anterior oblique (RAO) view. LM Left main artery, LAD left anterior descending artery (segments 1–3), DIAG 1 1st diagonal branch, DIAG 2 2nd diagonal branch, LCX left circumflex artery (segments 1–3), OM 1 1st obtuse marginal branch, OM 2 2nd obtuse marginal branch

Right Coronary Artery (RCA)

The RCA is an artery originating above the right cusp of the aortic valve, at the right aortic sinus in the heart. It travels down the right coronary sulcus, towards the crux of the heart. It branches into the PDA and the right marginal artery. Although rare, several anomalous courses of the RCA have been described including origin from the left aortic sinus (**Angelini, P. (15 July 2014). "Novel Imaging of Coronary Artery Anomalies to Assess Their Prevalence, the Causes of Clinical Symptoms, and the Risk of Sudden Cardiac Death". Circulation: Cardiovascular Imaging. 7 (4): 747–754. doi:10.1161/CIRCIMAGING.113.000278**). At the origin of the RCA is the conus artery. In addition, to supplying blood to the RV, the RCA supplies 25% to 35% of the LV. In 85% of patients (Right Dominant), the RCA gives off the PDA. In the other 15% of cases (Left Dominant), the PDA is given off by the LCX. The PDA supplies the inferior wall, ventricular septum, and the posteromedial papillary muscle. The RCA also supplies the SA nodal artery in 60% of people. The other 40% of the time, the SA nodal artery is supplied by the LCX. The RCA emerges from the aorta into the AV groove. It descends through the groove, then curves posteriorly, and makes a bend at the crux of the heart and continues downward in the posterior interventricular sulcus. Within millimeters after emerging from the aorta, the RCA gives off two branches: 1) the conus (arteriosus) artery which runs to the right ventricular outflow tract, and 2) the atrial branch which gives off the SA nodal artery (in ~ 50-73% of hearts), which runs along the anterior RA to the SVC , encircling it before reaching the SA node. The RCA continues in the AV groove and gives off a variable number of branches to the RA and RV. The most prominent of these is the **right marginal branch** which runs down the right margin of the heart supplying this part of the RV. As the right coronary curves posteriorly and descends downward on the posterior surface of the heart, it gives off two to three branches. **The AV nodal artery** which branches from the RCA at the crux of the heart and passes anteriorly along the base of the atrial septum to supply the AV node (in 50-60 % of hearts), proximal parts of the bundles branches of His, and the parts of the posterior interventricular septum that surround the bundle branches.

1. ***The conus (arteriosus) artery*** *which runs to the right ventricular outflow tract*, At the origin of the RCA is the conus artery. It ramus is only present in about 45 % of the human hearts, and which provides collateral blood flow to the heart when the LAD artery is occluded. (**Wynn GJ, Noronha B, Burgess MI (2008). "Functional significance of the conus artery as a collateral to an occluded left anterior descending artery demonstrated by stress echocardiography". International Journal of Cardiology. 140 (1): e14–5. doi:10.1016/j.ijcard.2008.11.039. PMID 19108914**.)(**Schlesinger MJ, Zoll PM, Wessler S (1949). "The conus artery: a third coronary artery". American Heart Journal. 38 (6): 823–38. doi:10.1016/0002-8703(49)90884-4. PMID 15395916**.)
2. ***The atrial branch*** *which gives off the* ***SA node/nodal artery*** *(in ~ 60 % of hearts), which runs along the anterior RA to the SVC, encircling it before reaching the SA node.* This is the second branch of the RCA (the first one is the conus artery) and in 38% of cases from the LCX and from both arteries in 3%.(**Kyriakidis MK, Kourouklis CB, Papaioannou JT, Christakos SG, Spanos GP, Avgoustakis DG. Sinus node coronary arteries studied with angiography. Am J Cardiol. 1983 Mar 1;51:749-750.**)· The sinoatrial nodal artery is an artery of the heart which supplies the SA-Node, the natural pacemaker of the heart, and arises from the RCA in around 60% of cases. In about 40% of cases, the sinoatrial artery is a branch of the LCX.(**Pejković B, Krajnc I, Anderhuber F, Kosutić D (July 2008). "Anatomical aspects of the arterial blood supply to the sinoatrial and atrioventricular nodes of the human heart". Journal of International Medical Research. 36 (4): 691–8. doi:10.1177/147323000803600410. PMID 18652764**.) In less than 1% of cases, the artery has an anomalous origin directly from the coronary sinus, descending aorta, or distal RCA. In > 50% of cases, the artery actually courses close to the superior posterior aspect of the interatrial septum. (**Click RL, Holmes DR Jr, Vliestra RE et al. Anomalous coronary arteries: Location, degree of atherosclerosis and effect on survival-A report from the coronary artery surgery study. J Am Coll Cardiol 1989; 13:531-537**.).The origin of the Sinoatrial node artery is not related to coronary artery dominance, which means the side (right or left) that provides the circulation to the back of the

heart. In contrast, the AV nodal branch, that is the artery that brings blood to the AV-Node, depends on coronary artery dominance. The SA-Node surrounds the sinoatrial artery, which can run centrally (in 70% of individuals) or off center within the node.(**Sanchez-Quintana D, Anderson RH, Cabrera JA, et al. The terminal crest: morphological features relevant to electrophysiology. Heart 2002;88: 406–411**.) A left S-shaped sinoatrial node artery, originating from the proximal LCX artery, has been described as a common variant in ≈10% of cases.(**Saremi F, Channual S, Abolhoda A et al. MDCT of the S-shaped sinoatrial node artery. Am J Roentgenol 2008; 190:1569-1575**.) This artery is larger than normal and supplies a good part of the LA, but also right sided structures like part of the SA-Node and the AV nodal areas. In this variant, the artery courses in the sulcus between the left superior pulmonary vein and the left atrial appendage where it could be susceptible to injury during catheter or surgical ablation.

3. ***Atrioventricular nodal branch:*** The atrioventricular nodal branch is a cardiac artery that is crucial because it feeds the AV-Node. In over 80% of hearts it arises as a distal branch from the RCA near the crux of the heart. In ≈ 18% the AV-Node instead receives blood from the LCX. In ≈ 2% of cases, the vascular supply to the AV-Node arises from both the RCA and the LCX (**Sow ML, Ndoye JM, Lo EA. The artery of the atrioventricular node: an anatomic study based on 38 injection-dissections. Surg Radiol Anat 1996;18:183–187**)
4. ***Right marginal branch/artery****; of is a large marginal branch which follows the acute margin of the heart and supplies blood to both surfaces of the RV.*
4. ***Posterior descending artery (PDA); It is typically a branch of the RCA (70%, right dominance).***
5. ***Posterolateral artery #1 (PL#1) and***
6. ***Posterolateral artery #2 (PL#2)***

Blood supply of SA-Node

In the majority of individuals (≈ 59% of cases), the SA-Node receives blood from a SA node artery. This is the second branch of the RCA (the first one is the conus artery) and in 38% of cases from the LCX and from both arteries in 3% in remain.

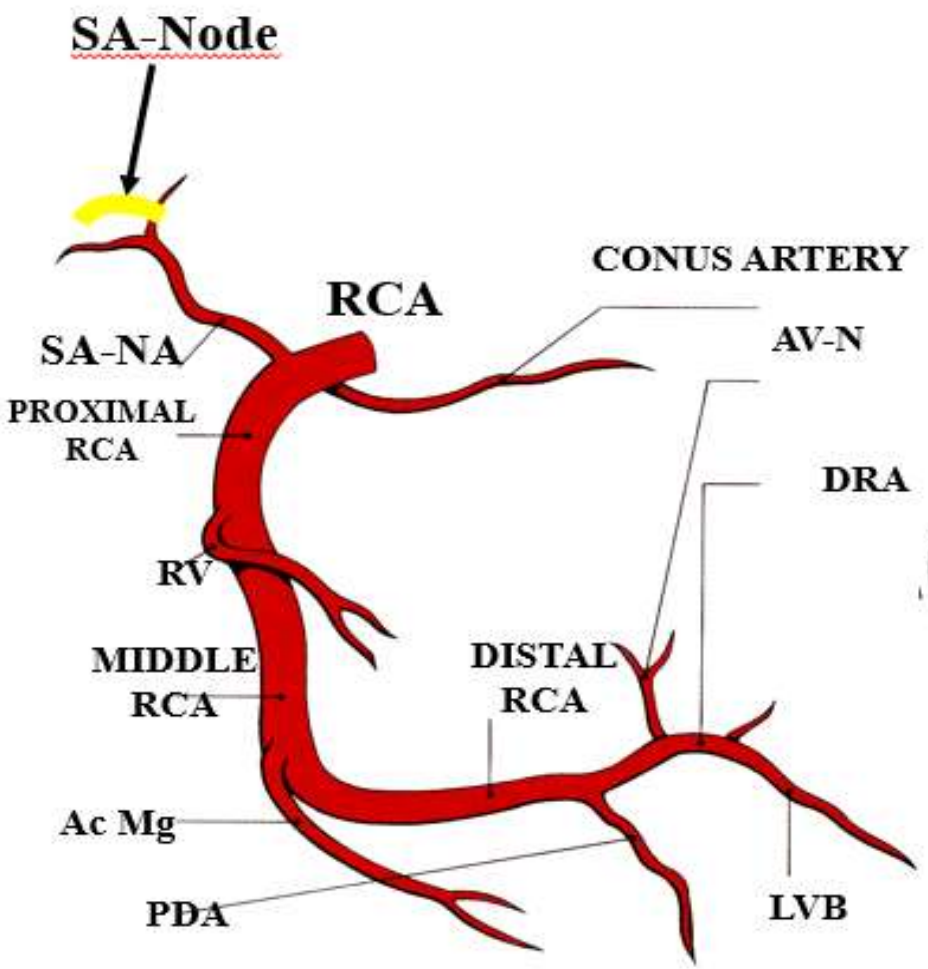

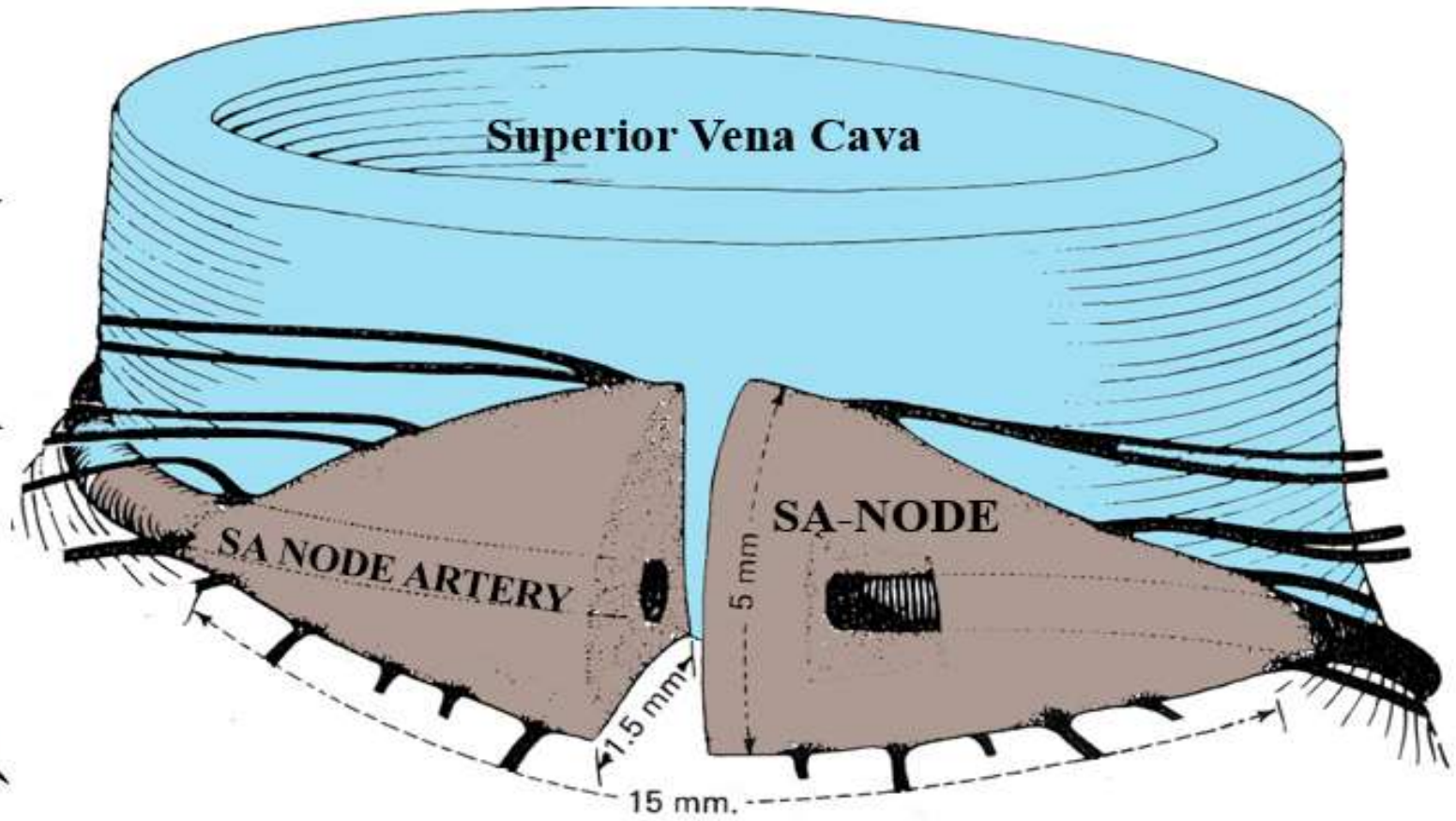

RA – Right Atrium