Summary of the Right Coronary Artery - Basic Anatomy

- **Origin**
  Right aortic sinus (lower origin than Left Coronary Artery
- **Course**
  Down right AV groove toward crux of the heart, gives off PDA (85%) from which septal branches arise, continues in LAV groove giving off posterior LV branches (posterolateral). PDA may originate more proximally, bifurcate early of be small with part of "its territory" supplied by an acute marginal branch.
- **Supplies**
  25% to 35% if the Left ventricle.

Right Coronary Artery - Other Branches

- **Conus Artery**
  Usually very proximal (≈50% have a separate origin) –courses anteriorly and upward over the RVOT toward the LAD. May be an important source of collaterals.
- **SA Node Artery**
  (≈69%) usually 2nd branch of RCA-courses obliquely backward through upper portion of atrial septum and anteromedial wall of the RA-supplies SAN, usually RA and sometimes LA.
- **Right ventricular (Acute Marginal Branches)**
  Arise form mid RCA; supply anterior RV; may be a collateral source
- **AV Nodal Artery**
  Arise at or near crux; supplies AV node.
- **PDA**

  Supplies inferior wall, ventricular septum, and posteromedial papillary muscle

Right Coronary Artery: Optimal View

- **LAO (30°) Cranial 30°) LAO** refers to rotating the camera to the patient's left (catheter and spine will be on the right side of the image),

  Particularly this projection is indicate for distal bifurcation (AP Cranial may be better)

- **RAO:** to the patient's right (catheter and spine on the left side of the image). Angulation describes the position of the image intensifier in the short axis of the patient.

  Main shaft; cranial enhances distal vessels and very proximal; caudal may help with shepherd´s crook

- **Lateral**

  Bifurcations with RV branches-distal bifurcation, particularly with cranial.

Standard Angiographic Views

- **LAO 30 30° LAO**
  - Best for visualizing ostial and proximal RCA
- **RAO**
  - Best for visualizing mid RCA and PDA
- **PA Cranial: PA and 30° cranial**
  - Best for visualizing distal RCA bifurcation and the PDA

Left Anterior Oblique Projection at 45° combined with a caudal angulation of 15°

This projection allows the whole study of the RCA and especially, clearly defines the region of the crux cordis

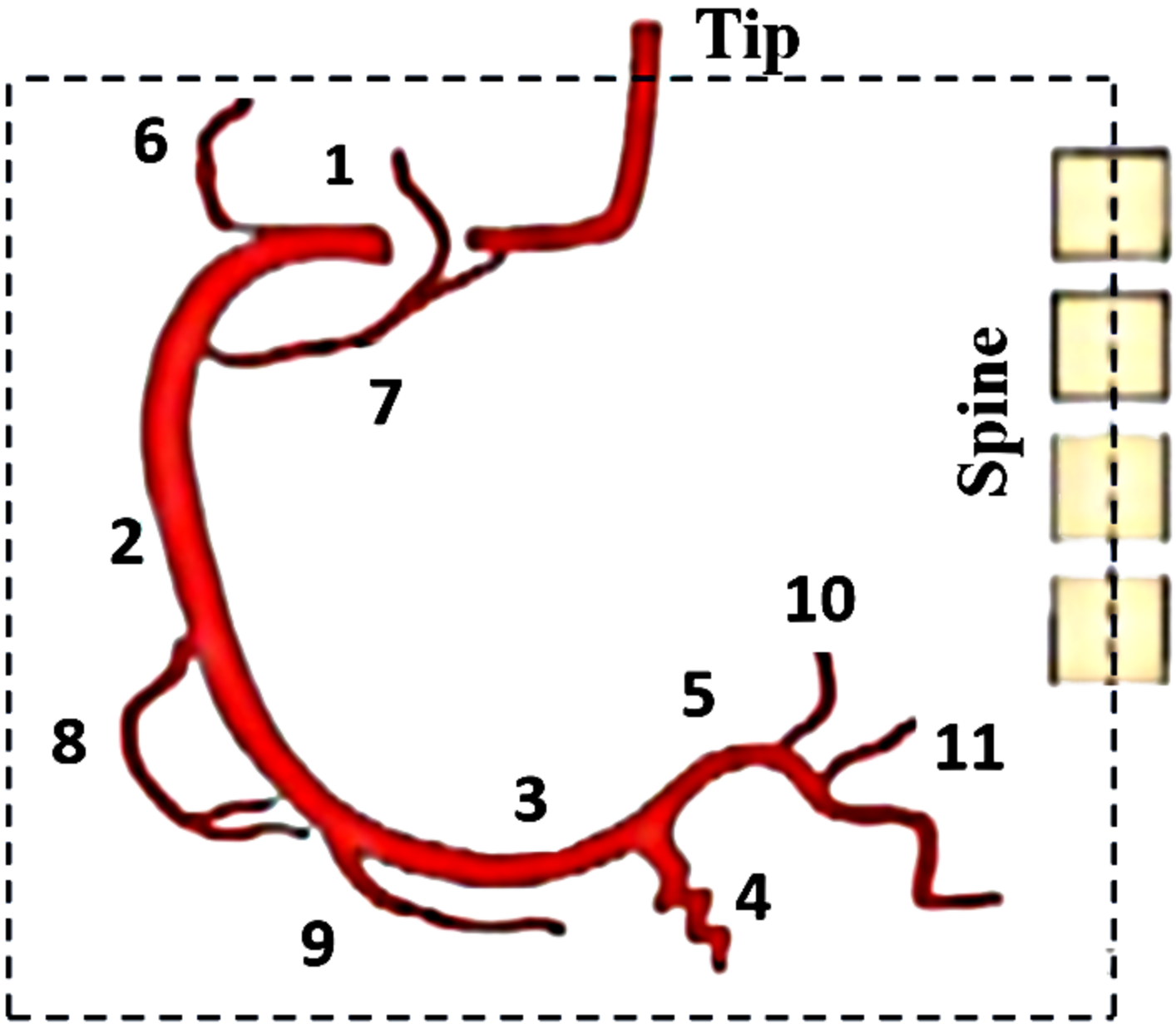

1. First (horizontal) segment of the RCA
2. Second(vertical) segment of the RCA
3. Third(horizontal) segment of the RCA
4. Posterior interventricular
5. Retro ventricular artery
6. Conus branch
7. Artery of the SAN
8. Right ventricular artery
9. Right marginal artery
10. Artery of the AV-Node
11. Diaphragmatic artery

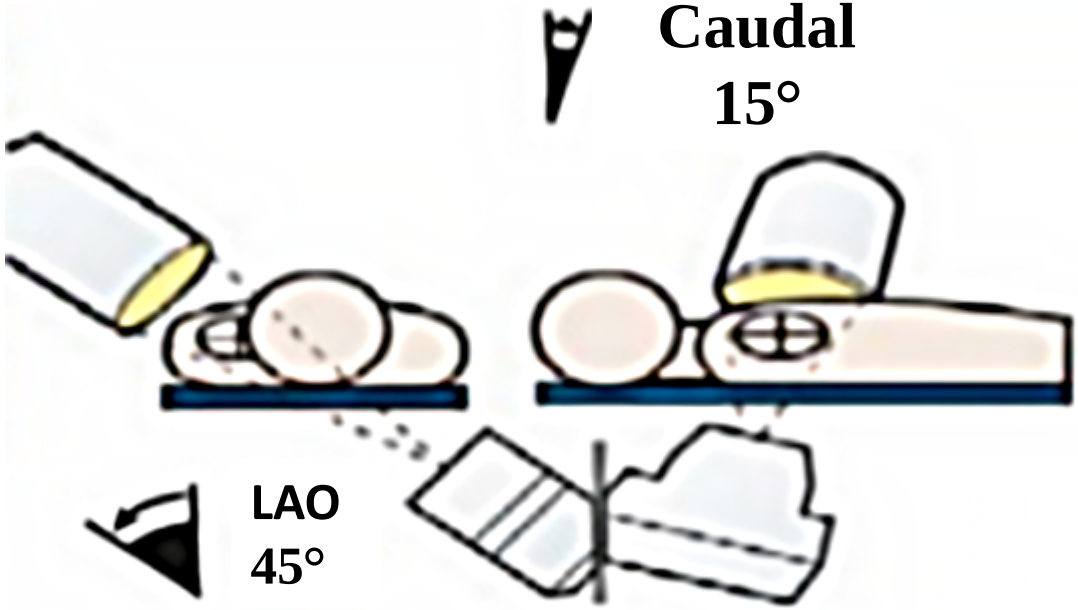

Right Anterior Oblique (RAO) Projection at 45°

The RAO projection at 45° permits the survey of the second(vertical) segment of the RCA, the posterior interventricular artery and the collateral branches(right ventricular and right marginal arteries) On the other hand, the first segment and third segment as well MAs the retro ventricular artery are not clearly defined. This projection also allows the visualization of the retrograde re opacification of the distal part of LAD proximally occluded.

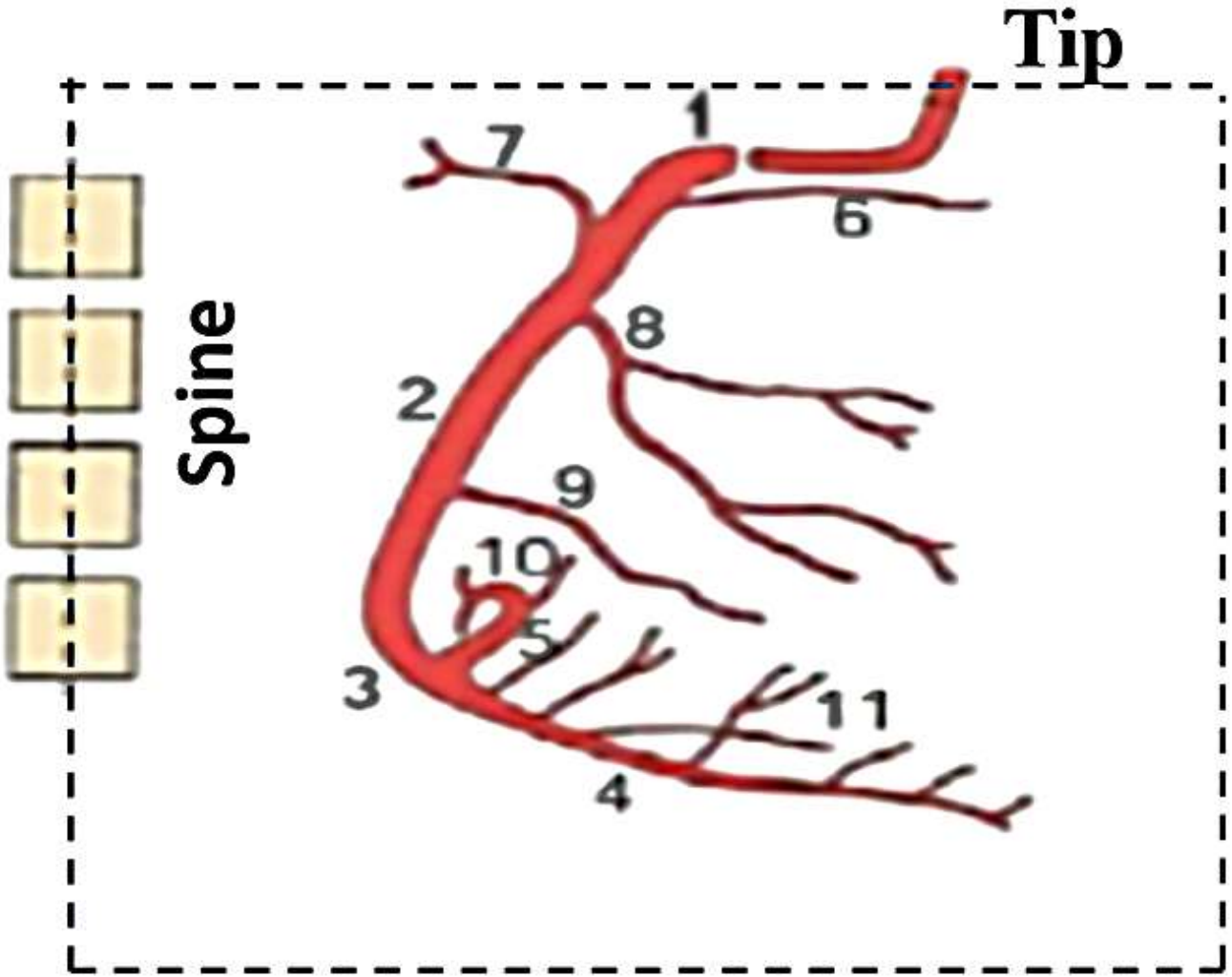

1. First (horizontal) segment
2. Second (vertical) segment of the RCA
3. Third (horizontal segment of the RCA
4. PDA
5. Retro ventricular artery
6. Conus branch
7. Artery of the SAN
8. Right ventricular artery
9. Right Marginal Artery
10. Artery of the AV Node
11. Inferior Septal Arteries

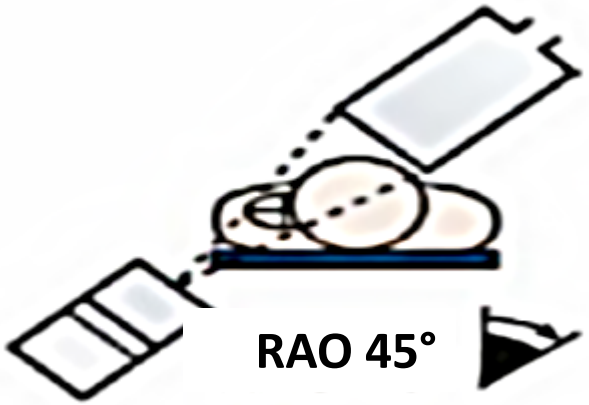

Right anterior oblique projection 120° combined with a cranial angulation of 10°

This projection is very useful for studying the third horizontal segment, the crux cordis, and the retro ventricular artery and its branches.

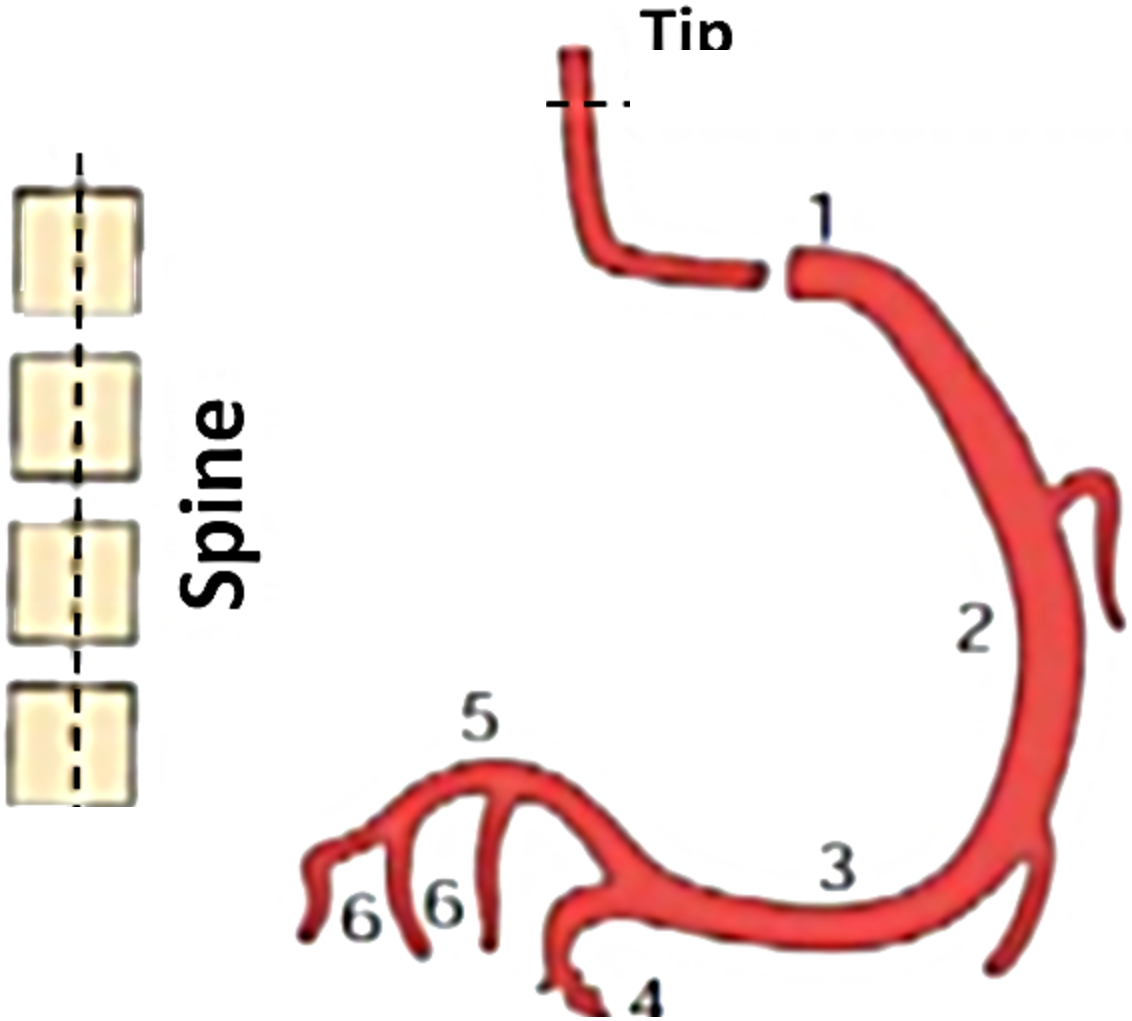

1. First (horizontal segment of the RCA
2. Second (vertical) segment of the RCA
3. Third (horizontal) segment of the RCA
4. Posterior interventricular artery
5. Retro ventricular artery
6. Diaphragmatic artery

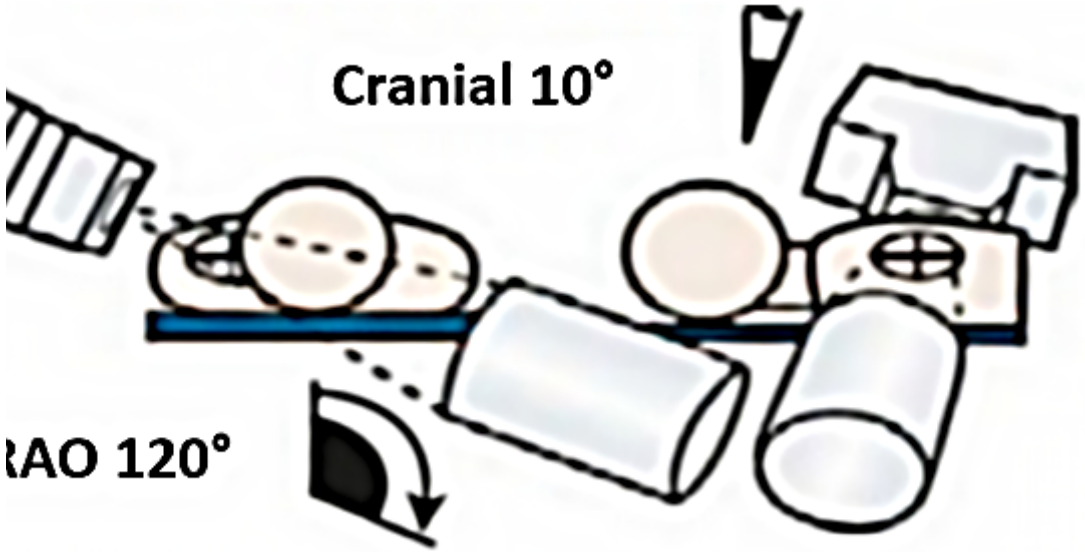

Left Lateral Projection

This projection permits the study of the second (vertical) segment of the RCA and the collateral branches (conus branch RV artery, right marginal artery

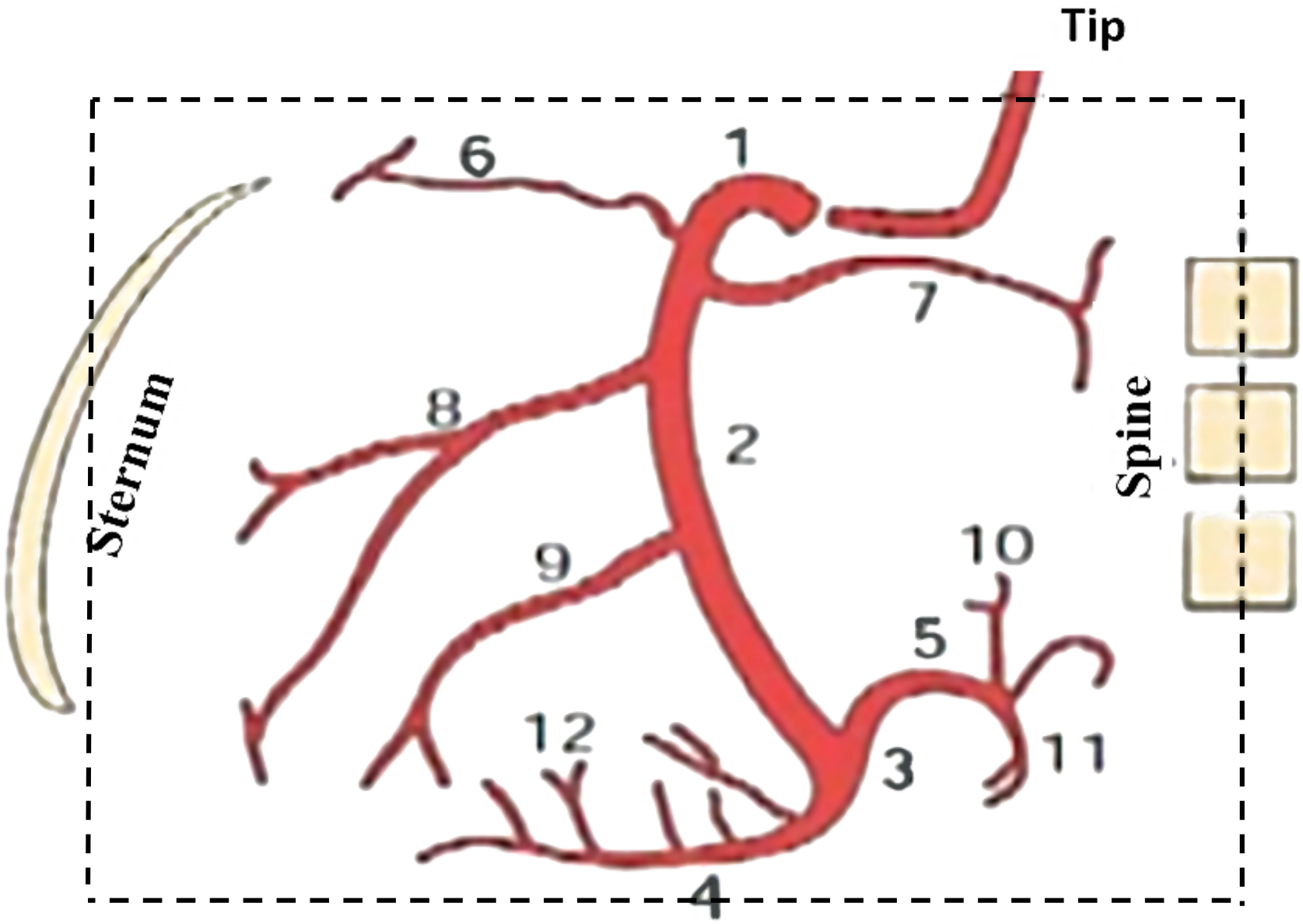

1. First horizontal segment of the RCA
2. Second(vertical) segment of the RCA
3. Third (horizontal) segment of the RCA
4. Posterior interventricular artery
5. Retro-ventricular artery
6. Conus branch]Artery of the sinus node
7. Right ventricular artery
8. Right marginal artery
9. Inferior septal arteries

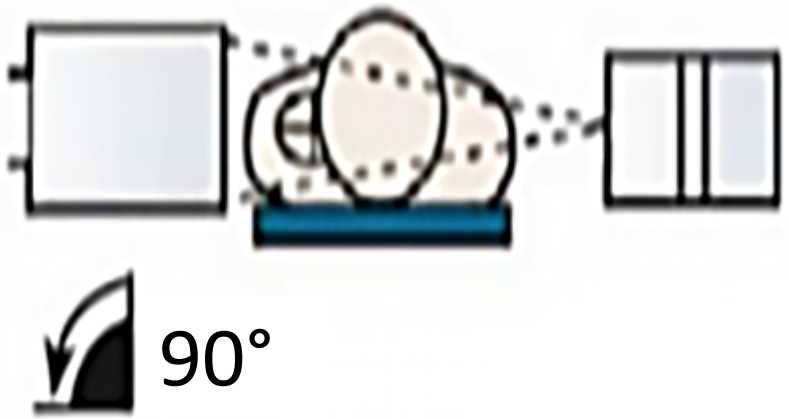

Right Coronary Artery (RCA): Proximal, Middle and Distal parts

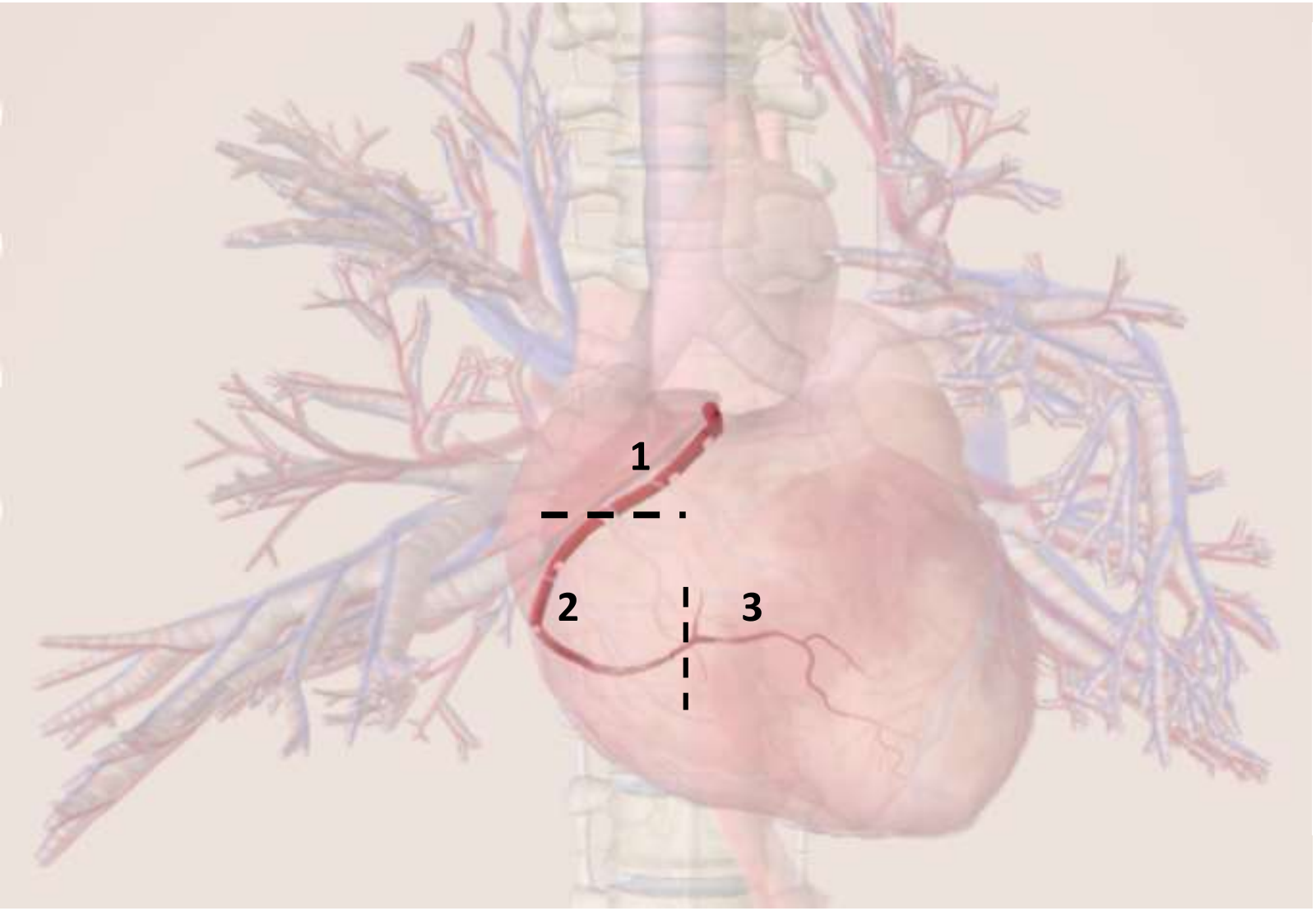

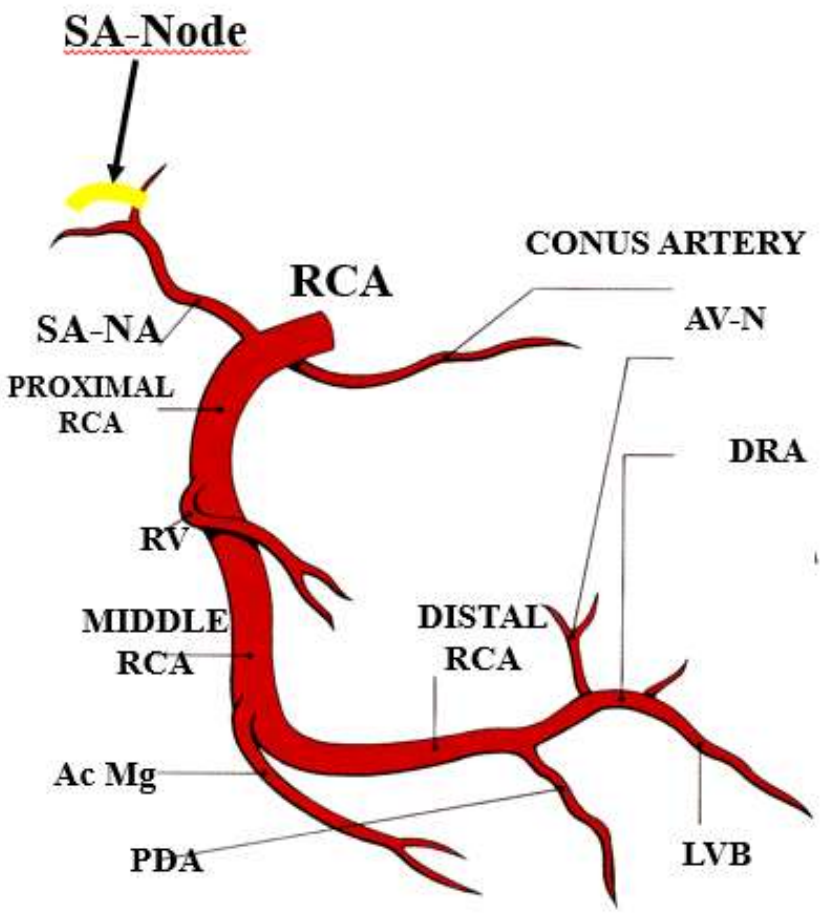

1, Proximal part of RCA: R-1 segment; 2. Middle part of RCA: R-2 segment; 3, Distal part of RCA: R-3 segment .

Coronary Angiography Right Coronary Artery RCA

RAO Right Anterior Oblique

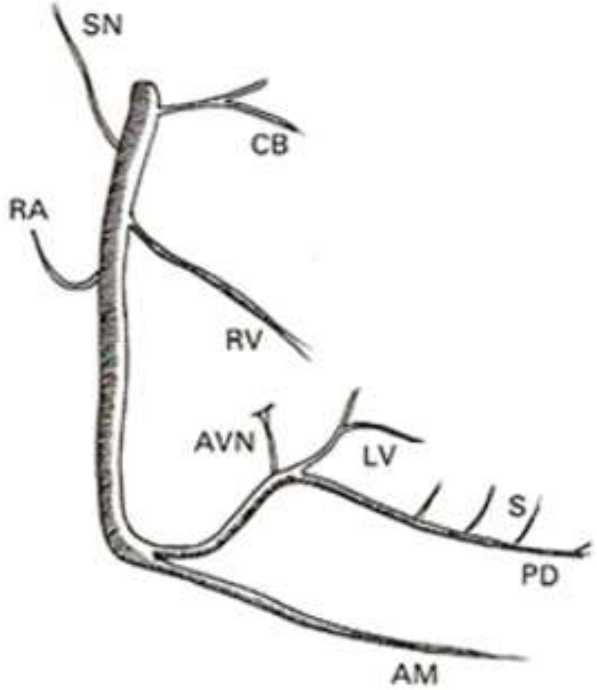

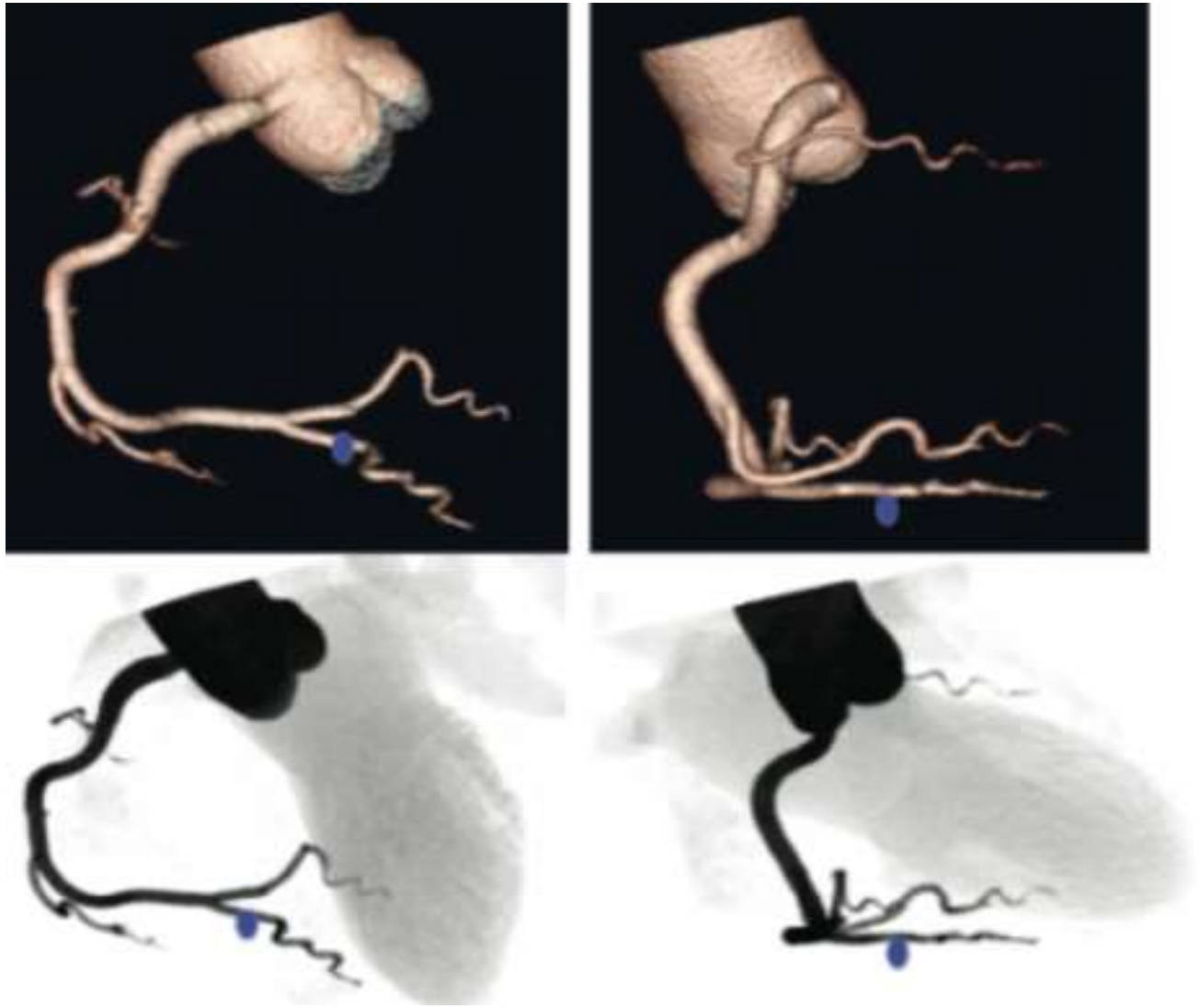

CTA reconstruction of the RCA in the left anterior oblique (LAO) view, cranial(left) and right anterior oblique(RAO) (no cranial or caudal(right) angulations. The lower drawing are salutations of the images that are seen on contrast angiography

LAO

The Proximal RCA (R1 segment) including the ostium is best visualized in the 30° LAO view with no cranial or caudal angulation.

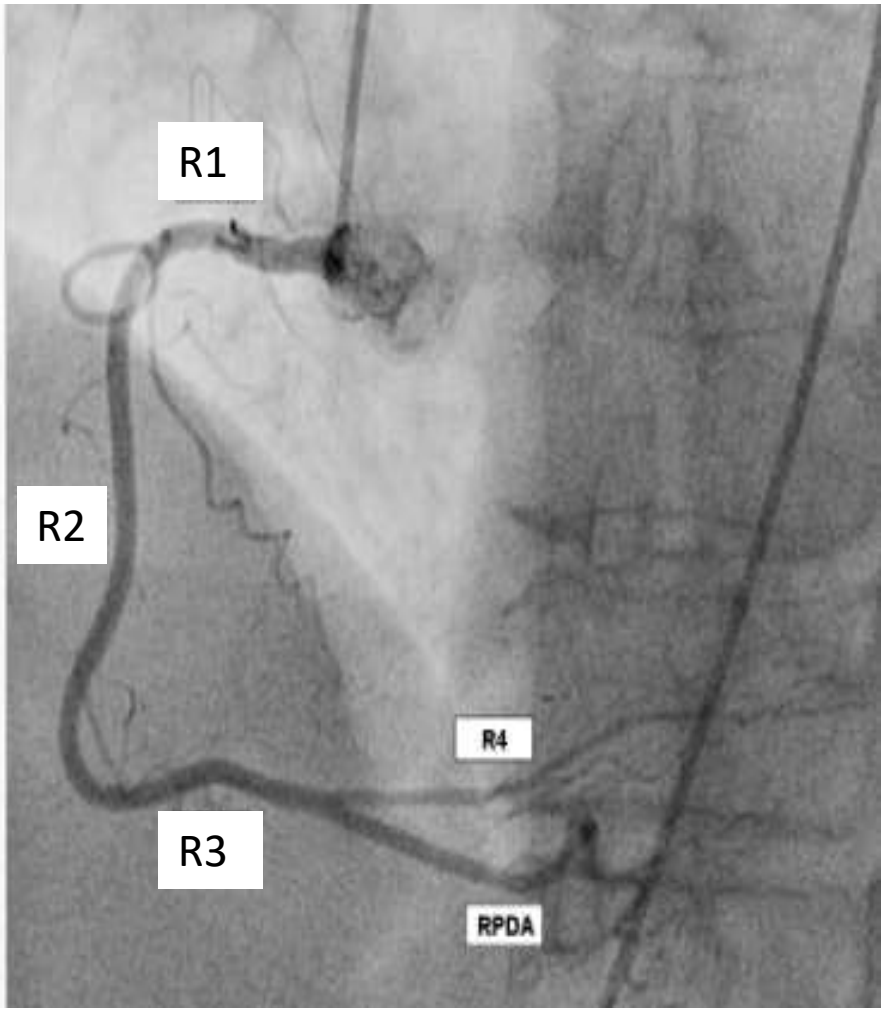

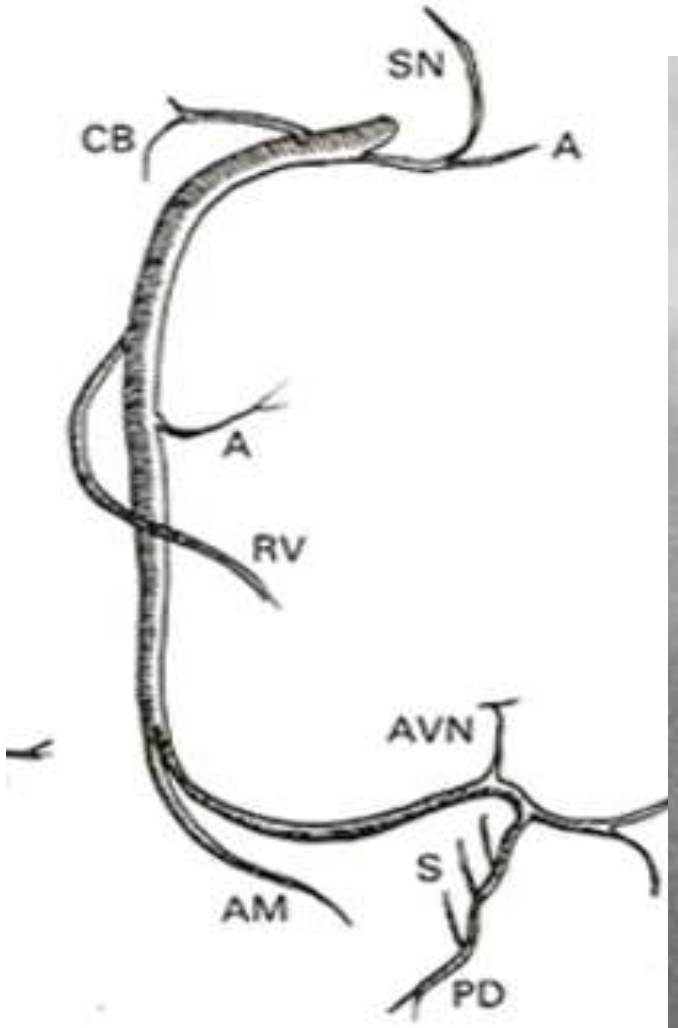

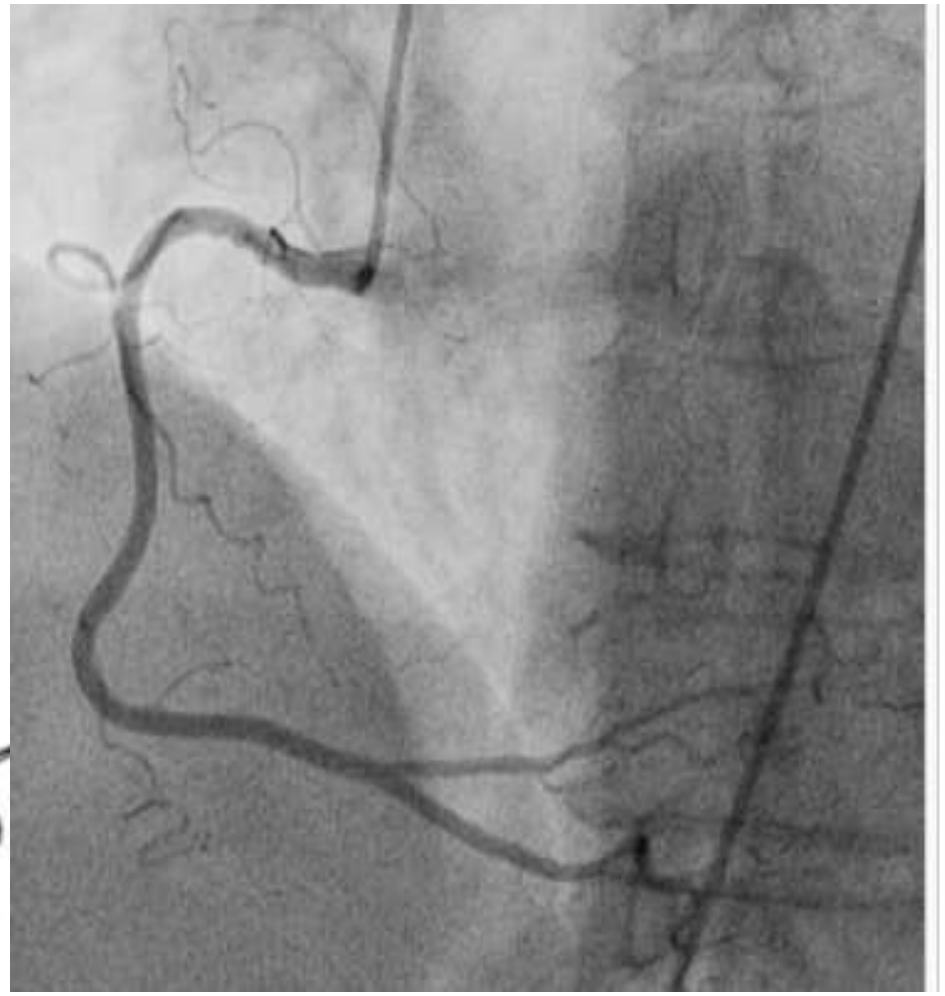

R1: Proximal part of RCA: **R2:** Middle part of RCA; **R3:** Distal part of RCA.

The American Heart Association division of the Coronary tree

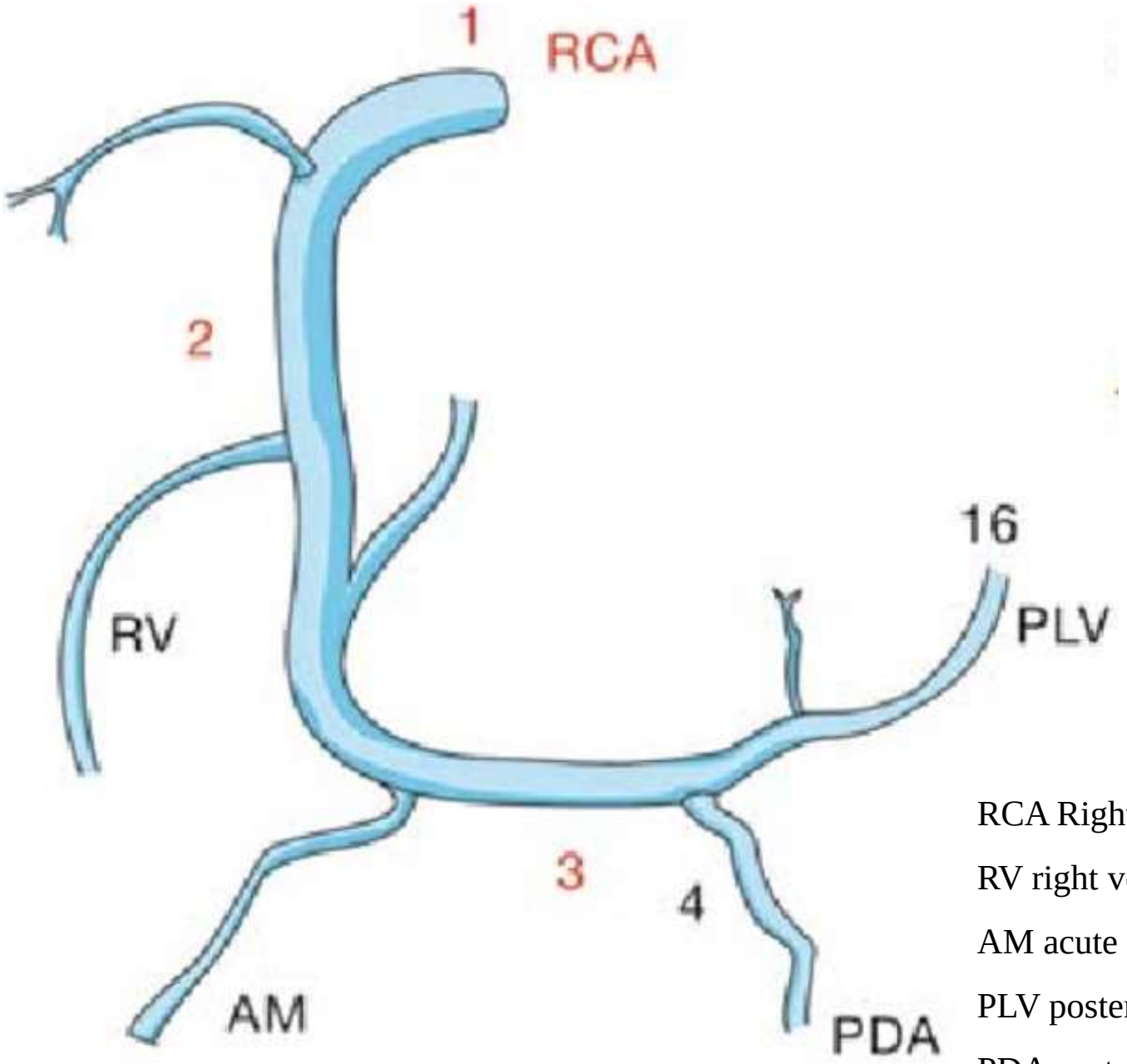

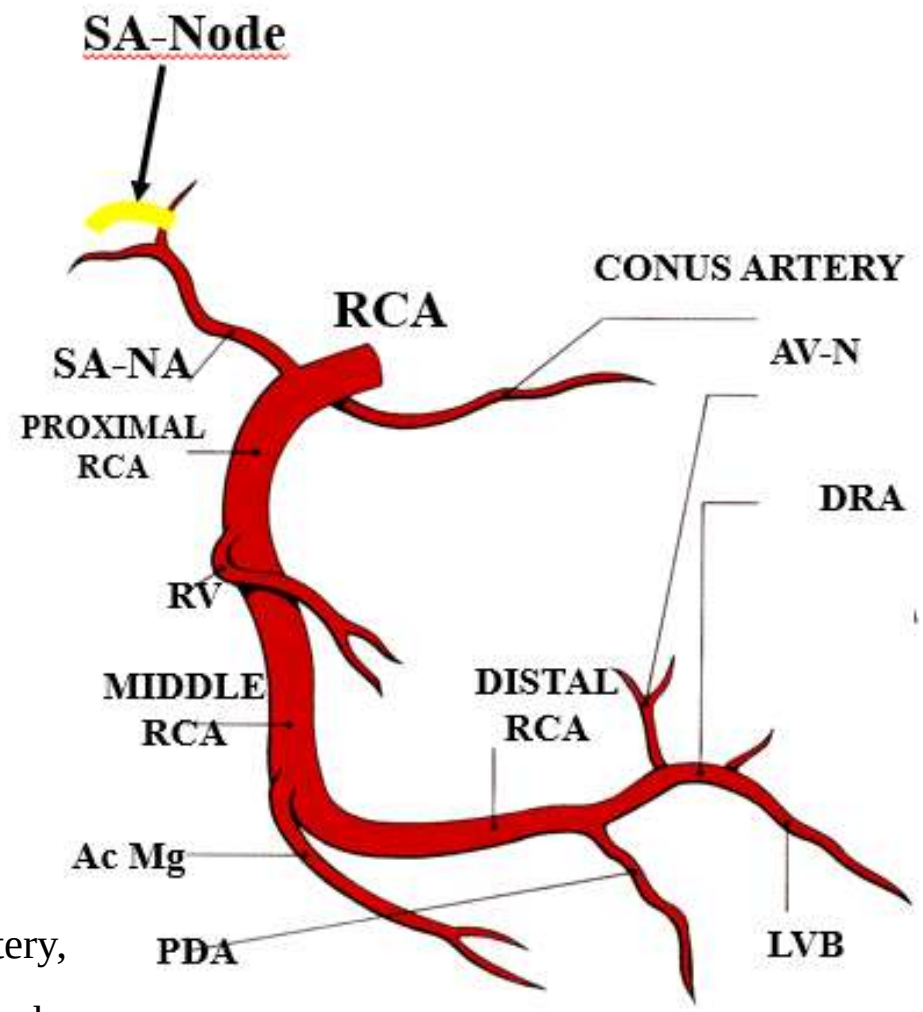

RCA Right coronary artery,

RV right ventricular branch,

AM acute marginal branch,

PLV posterolateral ventricular branch,

PDA posterior descending artery,