Bifurcation of the RCA

The camera is cranial to 15° - 20° and the LAO angulation is minimized to 5° - 10°. This view optimizes the bifurcation of the distal RCA where the right posterolateral artery and the posterior descending artery divide and branch from the distal RCA. The patient should take a deep breath and hold it during the injection to optimize the view.

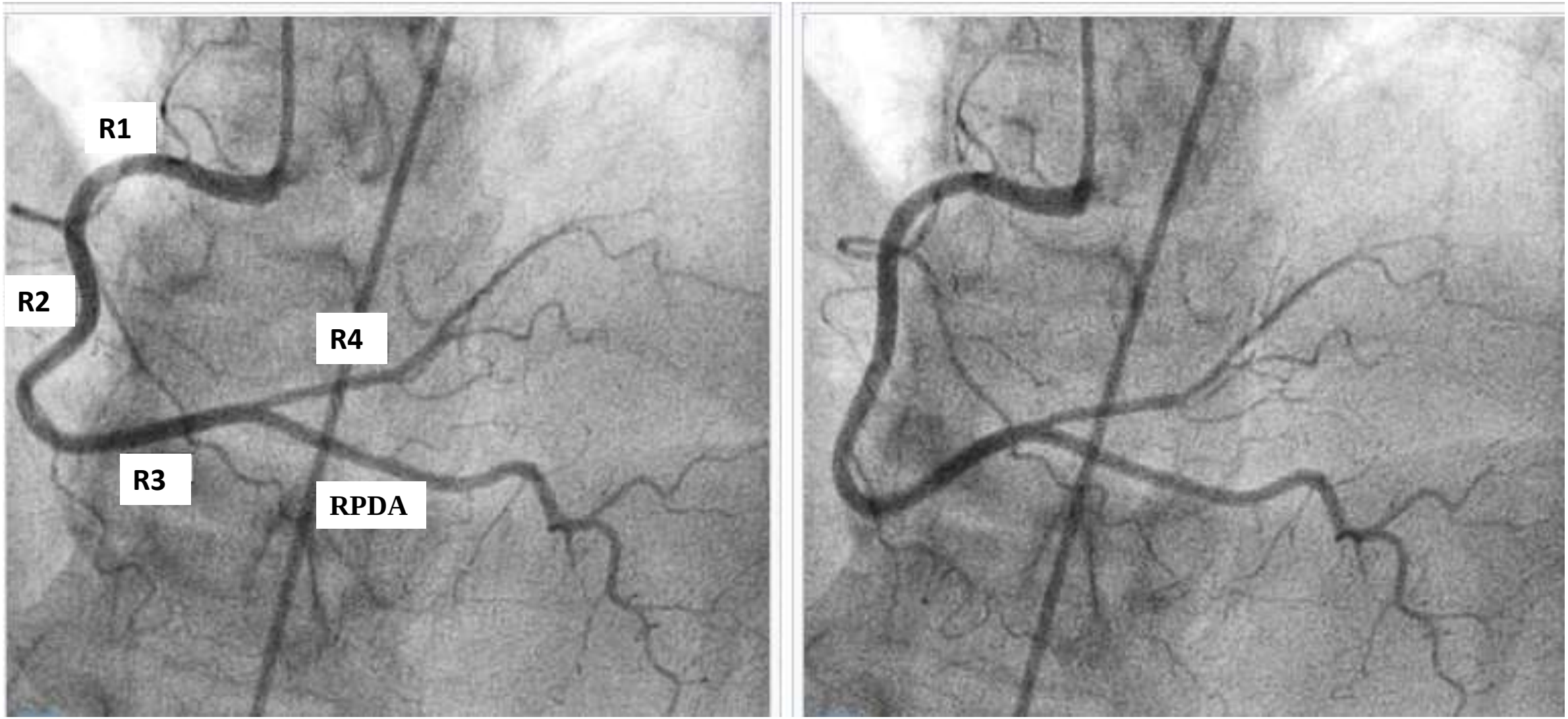

R1 = Proximal RCA; **R2 =** Middle RCA**; R3** = Distal RCA; **RPDA =** Right posterior descending artery.

Mid RCA

The middle RCA (R2 segment) is best visualized in the 30° RAO straight view.

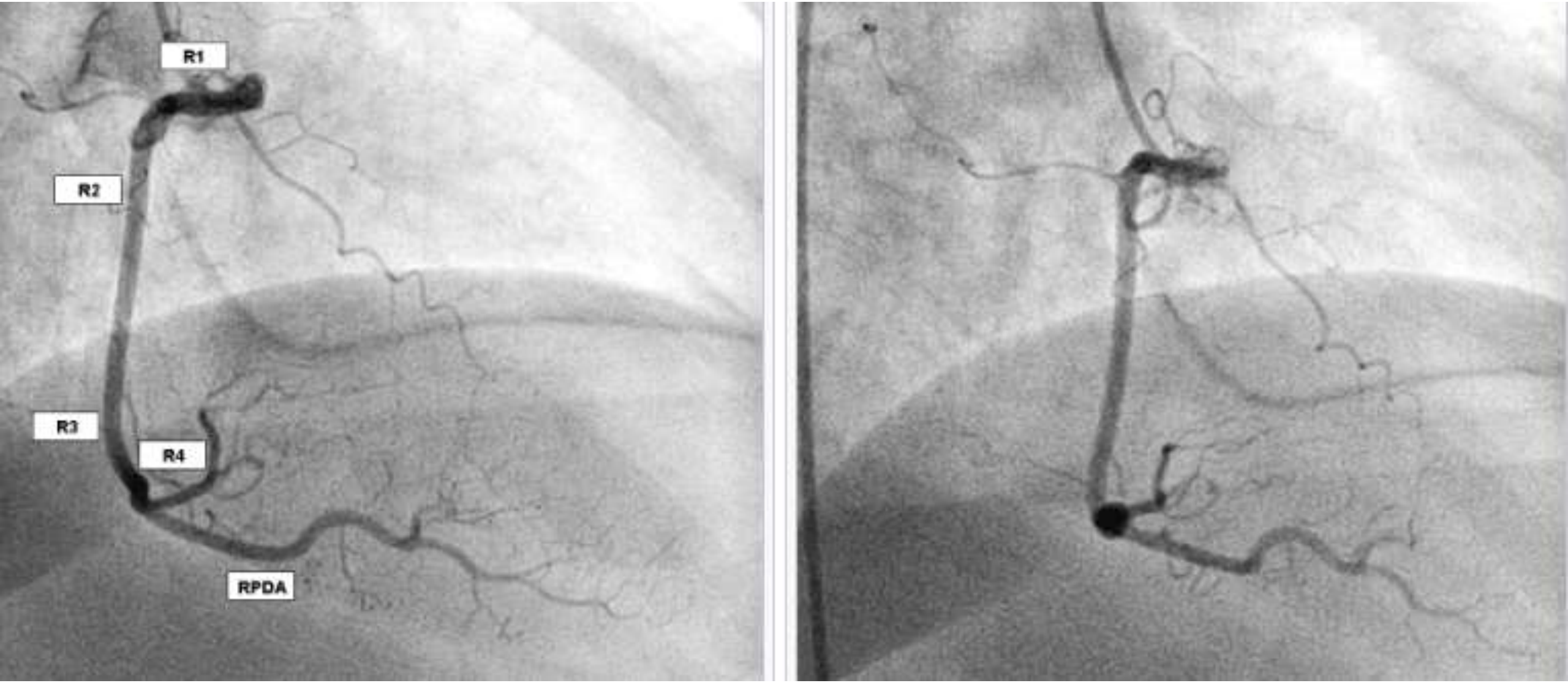

R1 = Proximal RCA; R2 = Middle RCA; R3 = Distal RCA; RPDA = Right posterior descending artery.

The junctional or atrioventricular area

The AV junction can be divided into 3 regions as follows:

1. Transitional cell zone = AN: Atrionodal Region
2. Compact AV node = N: Nodal Region
3. Penetrating portion of the AV bundle = NH
4. Penetrating portion of His bundle = H

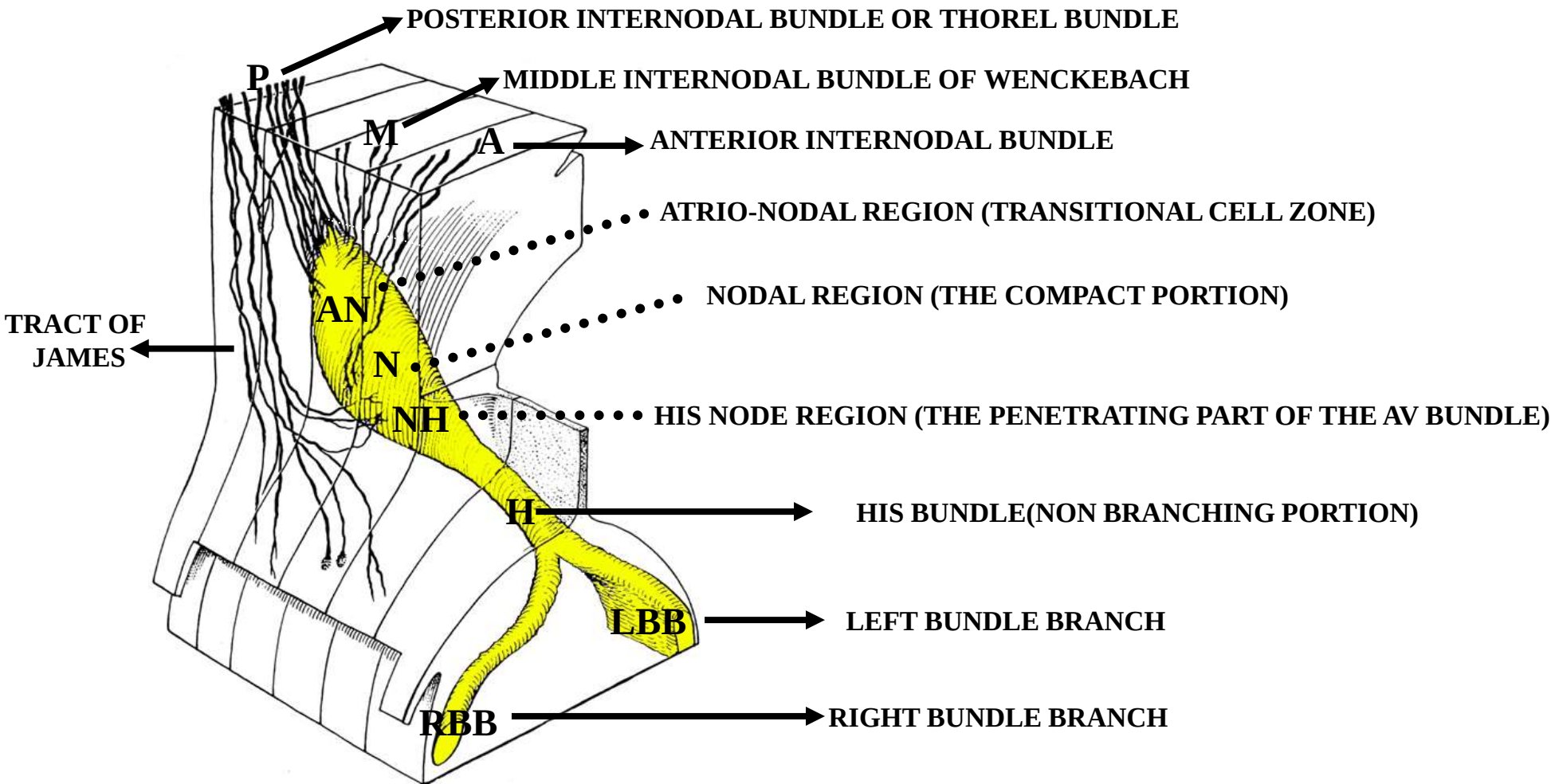

BLOOD SUPPLY OF THE COMPACT AV NODE

In 85% of cases AV node receives its blood supply from the RCA. In the remaining 13% by the **LCX** and in 2% by both arteries[1].

The AV node becomes the AV His bundle at the point where the overall axis for conduction penetrates into the central fibrous body[2].

BLOOD SUPPLY OF THE HIS BUNDLE

This structure has double blood supply: from branches of the LAD and PDA[3].

- **BLOOD SUPPLY OF THE LEFT BUNDLE BRANCH (LBB)** branches of the PDA (90% of the RCA): AV node artery: ramus septi fibrosi, ramus septi ventriculorum superior and ramus cristae.
- Branches of LAD: Ramus limbi sinistri (equivalent to ramus limbi dextri of the LDA). Consequently, the blood supply to the LBB is dual: RCA atrioventricular branch (90% of hearts) and septal perforator branches of the LAD (10% of hearts) https://www.pharmacology2000.com/Cardio/Cardio_risk/adult_cardiac_procedures/anatomy4.htm

)

1. **Hadziselimović H. Vascularization of the conducting system in the human heart. Acta Anat (Basel). 1978;102:105-110.**
2. **Anderson RH, Ho SY, Becker AE. Anatomy of the human atrioventricular junctions revisited. Anat Rec. 2000 Sep 1;260:81-91.**
3. **Lumg G, Singletary HP. Blood Supply to the Atrioventricular Node and Bundle of His: A Comparative Study in Pig, Dog, and Man Am J Pathol. 1962 Jul;41:65-75.**

Right Bundle Branch on right septum surface of right ventricle

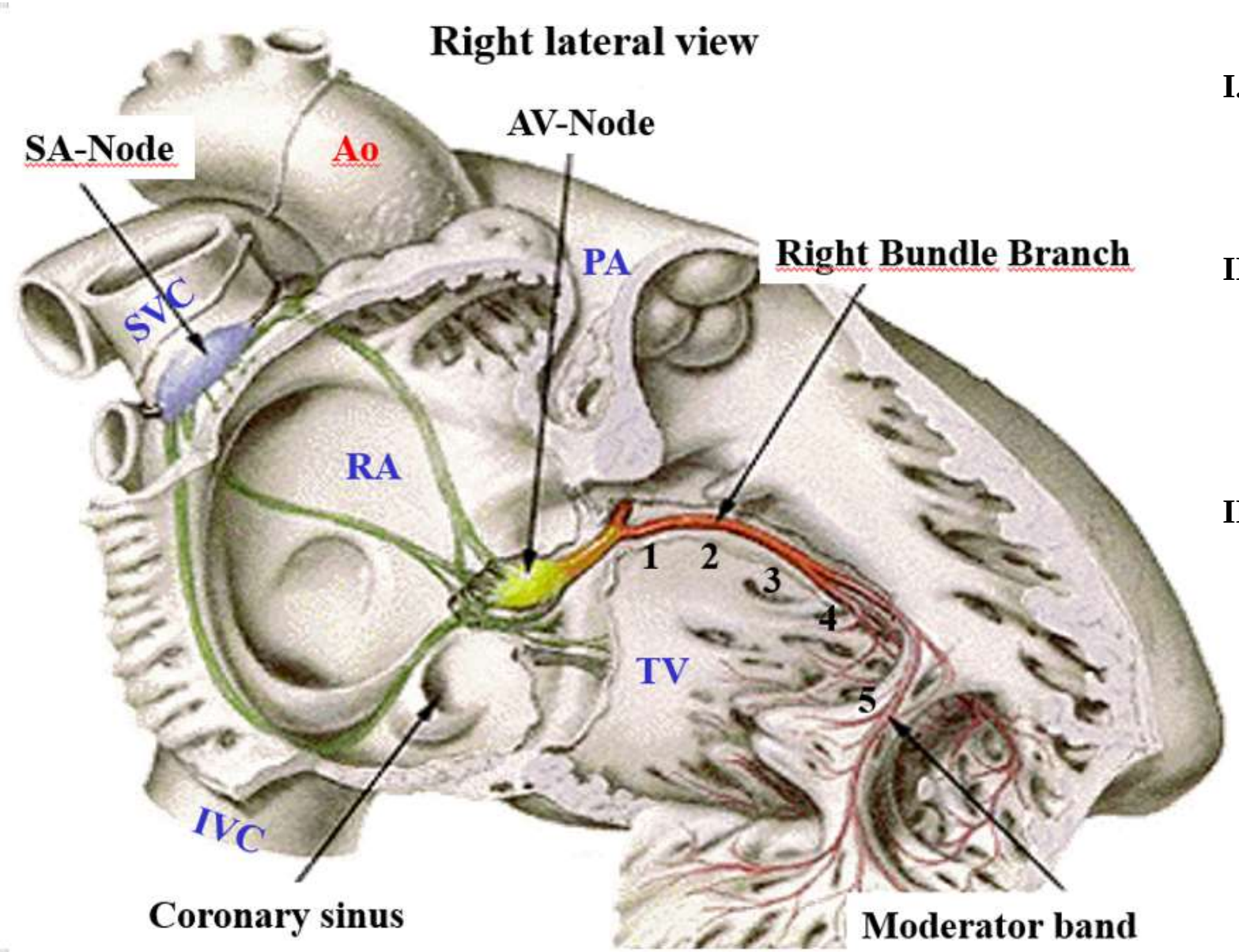

I. **Proximal portion: 1+2** is irrigated by the AV node artery of the RCA and the first septal perforator artery (S_1) of the LAD.

II. **Middle portion: 3** is irrigated by: Posterior Septal perforators of the PDA and the second septal perforator artery(S_2) of the LAD and Kugel's artery, branch of the LCX.

III. **Middle and distal portion: 4** are irrigated by the "Ramus limbi dextri", branch of the S_2 of the LAD.

Blood supply of the Right Bundle Branch (RBB)

Septal RBB

PROXIMAL PORTION is irrigated by the AV node artery of the RCA and the first septal perforator artery (S_1) of the LAD.

MIDDLE PORTION is irrigated by:

- **Posterior Septal perforators of the PDA**
- **Second septal perforator artery(S_2) of the LAD**
- **Kugel's artery, branch of the LCX.**

MIDDLE AND DISTAL PORTION: are irrigated by the "Ramus limbi dextri", branch of the S_2 of the LAD.

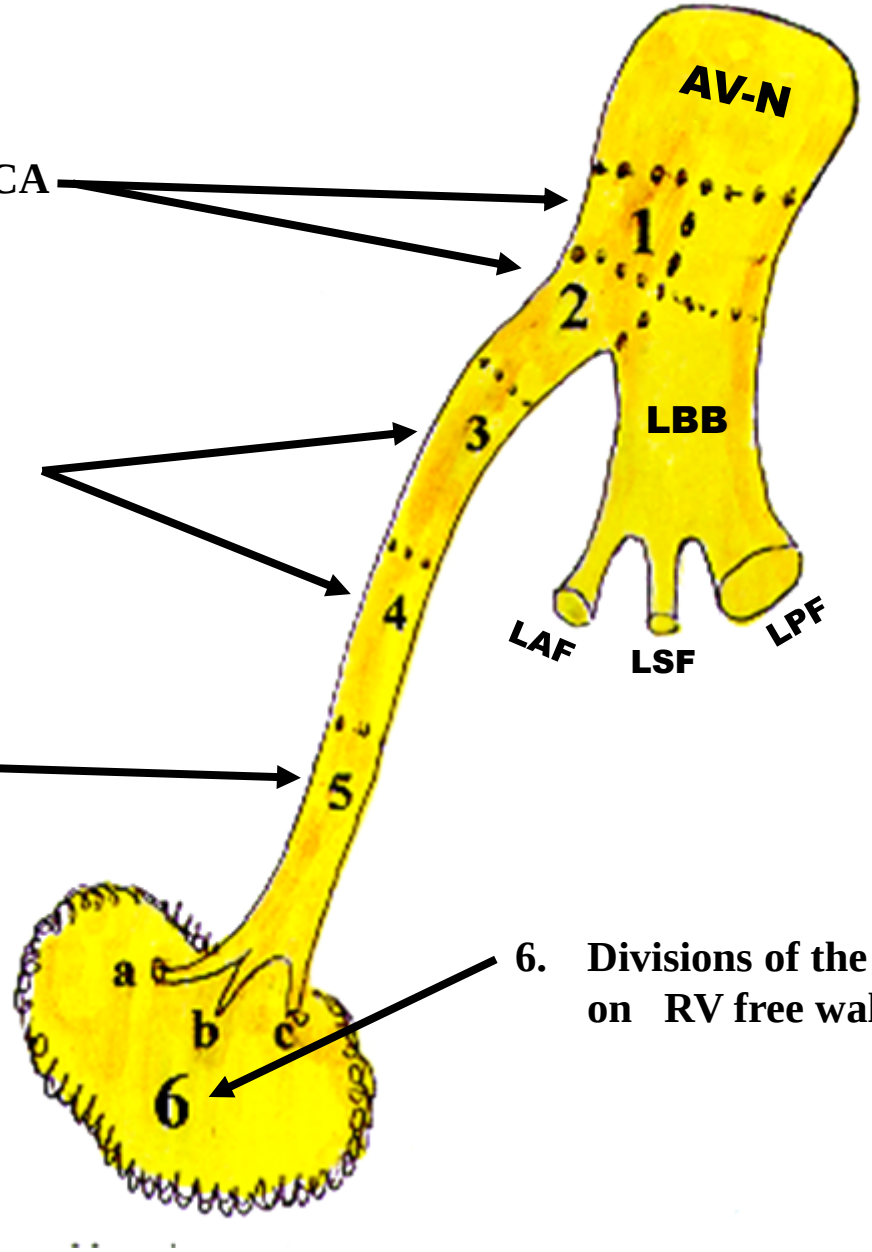

6. Divisions of the RBB on RV free wall

1) His Right Penetrating Portion.
2) His Right Branching Portion
3) Proximal or membranous of RBB
4) Middle, intramyocardial or mimetic
5) Inferior, distal, moderator Band (MB) or septomarginal trabécula (**Latin**: trabecula septomarginalis): It is a muscular band of heart tissue

found in the RV of the base of the anterior papillary muscle of the tricuspid valve to the ventricular septum. The MB is an important structure because it carries part of the RBB of the AV bundle of the conduction system of the heart to the anterior papillary muscle of the tricuspid valve. This shortcut across the chamber of the ventricle seems to facilitate conduction time, allowing coordinated contraction of the anterior papillary muscle. From its attachments it was thought to prevent overdistension of the ventricle, and was named the "moderator band". It was first described by Leonardo da Vinci in his exploration of human anatomy. The moderator band is often used by radiologists and obstetricians to more easily identify the RV in prenatal ultrasound. The MB is a consistent structure in the morphologic RV and can be helpful as a landmark in situations where the ventricles may be ambiguous (i.e. in some forms of congenital heart disease).The term "septomarginal" is descriptive since the muscle extends from the interventricular septum to the margin of the RV, contacting/joining the base of the anterior papillary muscle. The MB does not attach to the tricuspid valve, but acts as part of the electrical conduction pathway of the heart (final portion of the septal RBB).

Irrigation of the Right ventricle

The different segments of the right ventricular chamber are irrigated in this way:

1. **RV free wall:** RCA truncus, except the anterior edge;
2. **RV lateral wall:** acute marginal branch (Ac.Mg), the right marginal branch or ramus marginalis dexter, The right marginal branch of right coronary artery (or right marginal artery) is a large marginal branch which follows the cardiac acute margin and supplies blood to both surfaces of the right ventricle and the apex.
3. **RV anterior surface:** right ventricular branch of the RCA;
4. **RCA cone branch:** part of the septum;
5. **Posterior descending artery(PAD) :** (in 86% of the cases, RCA branch): RV posterior wall. In 14% of the cases, the PD is the branch of the Cx.

Note: in a small percentage of cases, the branches of the anterior descending artery (ADA) irrigate part of the RV. This happens with prolonged ADA, called type IV ADA, which surround the tip.

Blood Supply of the Left Fascicles of Left Bundle Branch

1. **Left Anterior Fascicle (LAF)** Is supplied either by septal branches of the LAD or by the AV nodal artery
2. **Left Posterior Fascicle (LPF):** The proximal part of LPF is supplied by the artery to the AV Node and, at times, by septal branches of the LAD artery. The distal portion has a dual blood supply from both anterior (S) and posterior (S`) Septal Perforator Arteries.
3. **Left Septal Fascicle (LSF):** It is supplied exclusively by septal branches of the LAD. Critical lesions of the LAD before the first septal perforator, constitute the main cause of LSFB in the first world.

RESPONSIBLE SYSTEM	LAF	LPF	LSF
Branches of the LAD	40 %	10 %	100 %
Double irrigation (LAD & RCA)	50 %	40 %	0 %
RCA branches	10 %	50 %	0 %

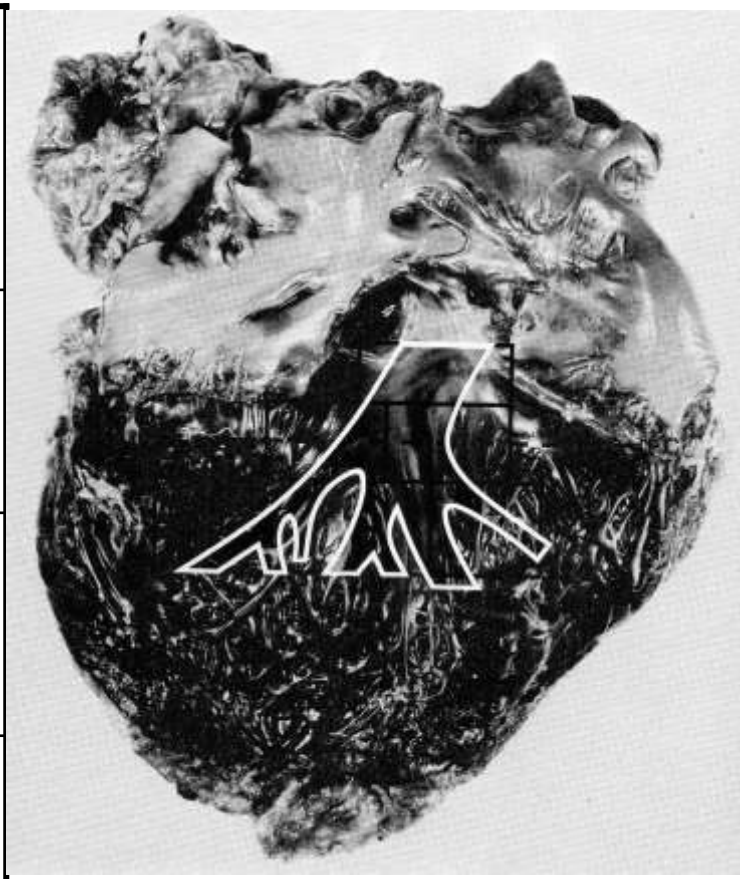

Summary of Left Main Coronary Artery

- **Origin**

  Upper portion pf left aortic sinus just below the sinotubular ridge. Typically 0-10mm in length. Rarely no LMCA(separate origins).

- **Optimal Views**

  LAO caudal and cranial; AP-caudal, cranial or flat.

A-P PROJECTION

The A-P projection allows a good visualization of the LMCA

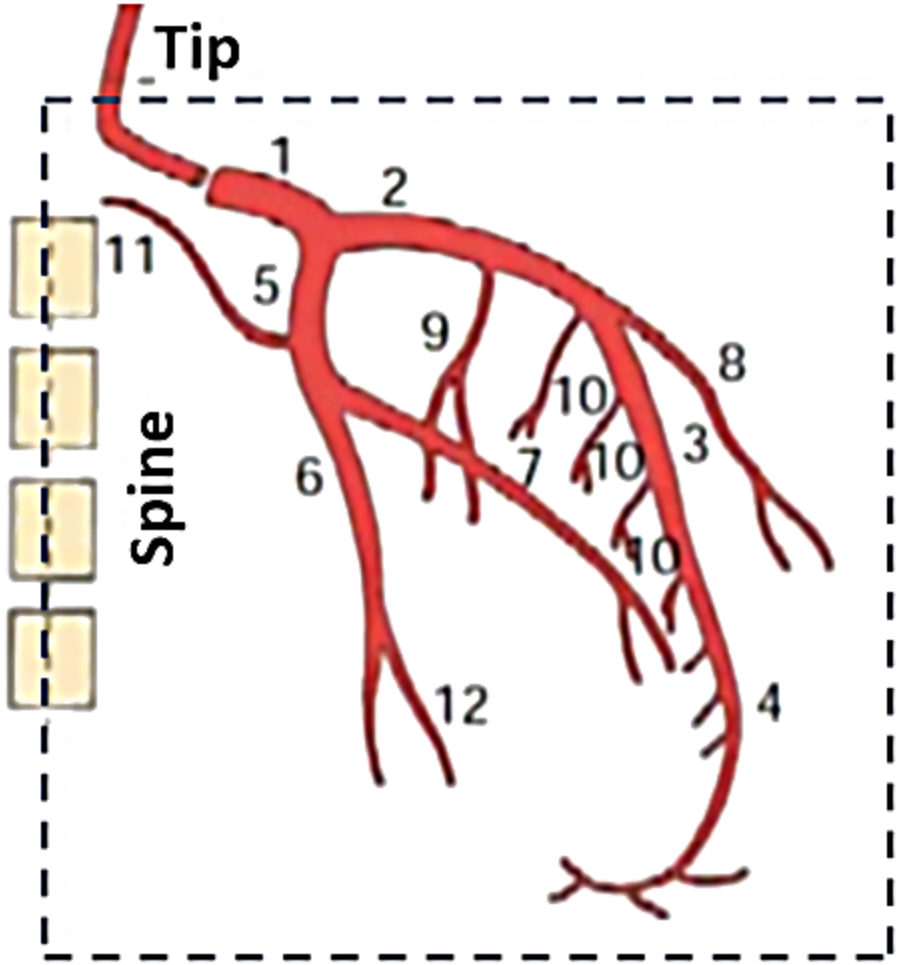
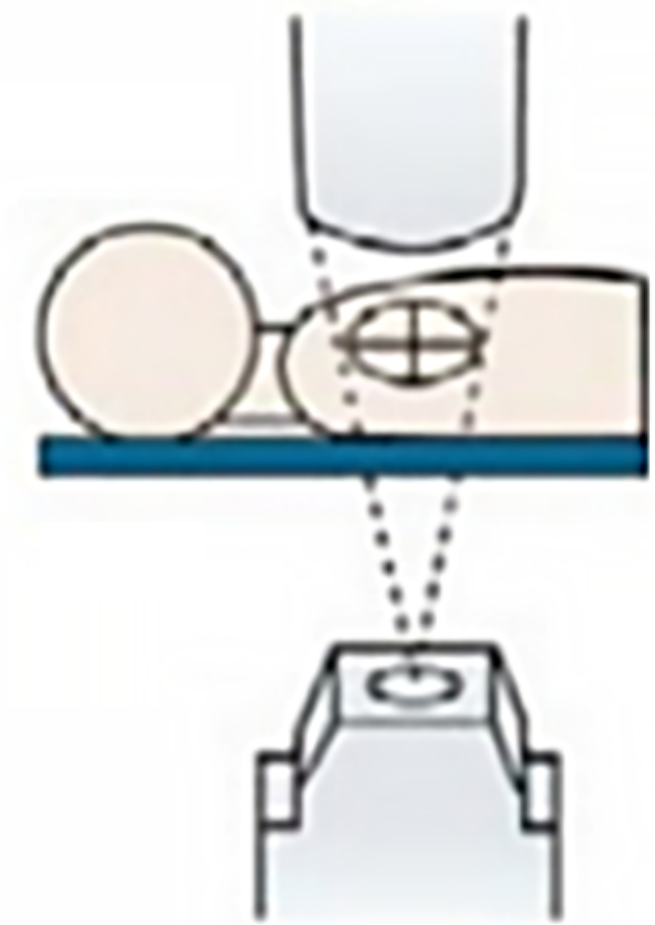
1. LMCA
2. Proximal part of LAD
3. Distal part of LAD
4. Proximal LCX
5. Distal LCX
6. Left Obtuse Marginal Artery
7. First Diagonal Artery
8. First Septal Perforator Branch
9. Septal arteries
10. Auricular branch of LCX
11. Obtuse Marginal Artery n° 2