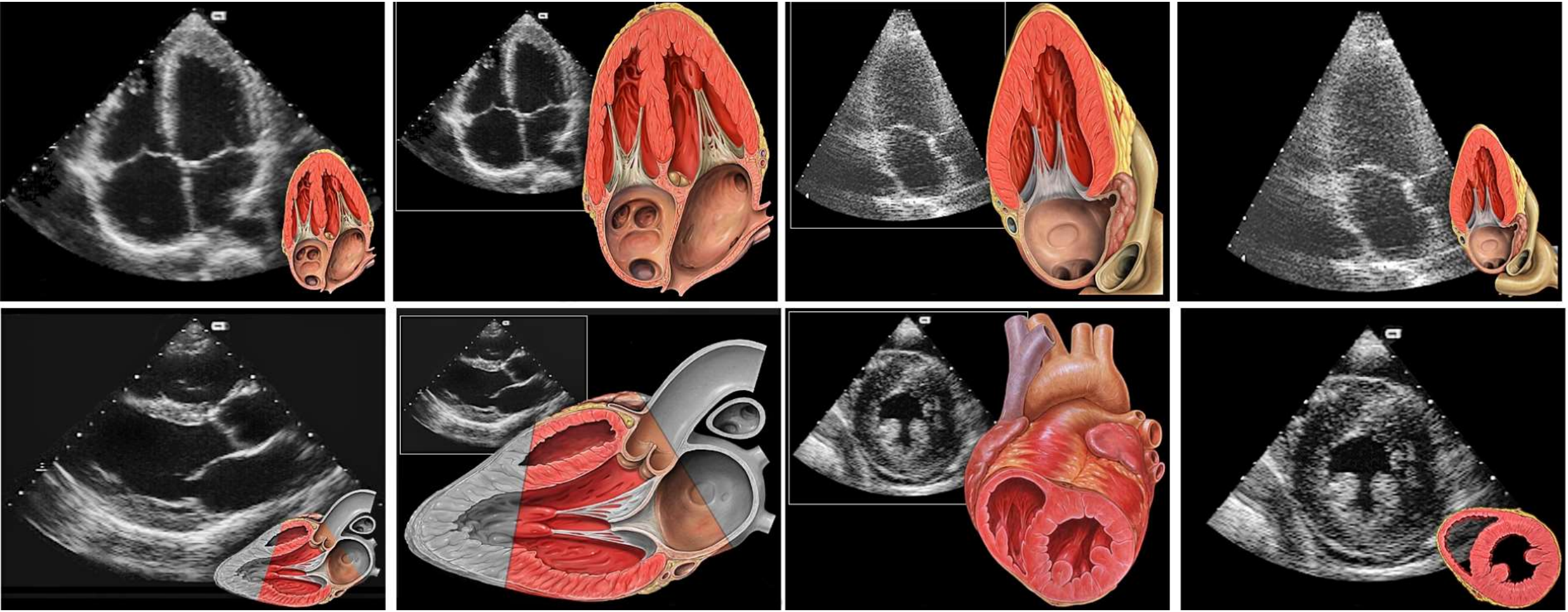

Creative credits: Patrick J. Lynch, medical illustrator; C. Carl Jaffe, MD, cardiologist. https://creativecommons.org/licenses/by/2.5

Kugel's artery anatomy

Kugel (**Kugel MA. Anatomical studies on the coronary arteries and their branches. I. Arteria anastomotica auricularis magna. Am Heart J 1927;3:260–70**.) described an atrial artery that arose from the proximal LCx or from its branches, coursed through the lower part of the interatrial septum, and in most of his cases (66%) anastomosed directly or through its branches with the distal RCA. In the rest of his cases, the same artery formed anastomoses with the proximal RCA (26%) or with branches from the anterior portion of the LCx and RCA and the posterior portion of the LCx (8%). He called this artery “arteria anastomotica auricularis magna” because of its large caliber, the apparent importance of its anastomotic role, and its consistent occurrence at this site. James (**James TN. Anatomy of the coronary arteries. New York: Paul B Hoeber; 1961. p. 132–4**.) and McAlpin (**McAlpin WA. Heart and coronary arteries: an anatomical atlas for clinical diagnosis, radiological investigation, and surgical treatment. New York: Springer-Verlag; 1975. p. 151**.) did not accept the existence of such an artery in their anatomical studies. Instead, they described small atrial branches that arose from either the LCx or the RCA, or even from both arteries, and connected with one another or with other small atrial branches from the surrounding area, then coursed posteriorly to the base of the interatrial septum and anastomosed with the AVN artery. Although these authors described an anastomotic network without accepting the existence of an artery, they applied the term “Kugel's artery” to this network. Moreover, they did not indicate the frequency of the network. On the other hand, angiographic studies have shown the existence in the same area of a large atrial artery that arises from the RCA or the LCx, or through the SN artery, and anastomoses with the AVN artery in various percentages (3.6%, 4.5%, and 6%) of cases. These authors, however, emphasize that this artery was found only in cases of severe atherosclerosis of the large coronary arteries. In the literature mentioned, Kugel's artery was not simple to demonstrate postmortem, and was extremely difficult to see in coronary arteriograms in vivo. Nerantzis et al, using a large series of specimens and a new technique, attempts to resolve the confusion in the literature regarding the existence of Kugel's artery, its origin, its ending,

and its relationship to the AVN artery. It also attempts to give details regarding whether an anastomotic network of small atrial arteries exists in the same area and what its relation to Kugel's artery and the AVN artery might be. These new anatomical findings may become useful to physicians who engage in diagnostic and therapeutic procedures that involve this area of the heart (**Nerantzis CE1, Marianou SK, Koulouris SN, Agapitos EB, Papaioannou JA, Vlahos LJ. Kugel's artery: an anatomical and angiographic study using a new technique. Tex Heart Inst J. 2004;31(3):**267-70). Professor Gustavo Abuin et al, From Buenos Aires described 2 vascular conduits that have never before been objectively shown to supply the conduction system. Twenty human hearts from subjects aged between 15 and 65 years--with and without coronary artery disease--were dissected after anterograde and retrograde injection with latex butaclor E-650 by means of a technique developed by the authors. In 40% of these hearts, Kugel's artery was found to supply the atrioventricular node. The right descending superior artery supplied the AVN in 70% of the hearts dissected. These findings may be of major significance both in clinical cardiology and in cardiovascular surgery (https://www.ncbi.nlm.nih.gov/pmc/articles/PMC325521/pdf/thij00021-0033.pdf). We succeeded in using a new technique to find, and then describe in detail, vascular courses in the lower part of the interatrial septum. In all of our cases, we observed anastomotic networks of various sizes. In addition, in 6 of the 100 hearts, we found a Kugel's artery in the same area. Nerantzis et al. described as a Kugel's artery an atrial artery that connected directly or through the Sinus node artery the proximal part of the LCx or the RCA with the distal part of the vessel where it crossed the crux. This artery is long and wide, and suitably fulfills the 4 initial descriptive terms given by Kugel: “arteria anastomotica auricularis magna.” Also Soto et al. and Smith et al. (**Soto B, Jochem W, Karp RB, Barcia A. Angiographic anatomy of the Kugel's artery. Am J Roengenol Radium Ther Nucl Med 1973;119:503–7**; **Smith C, Amplatz K. Angiographic demonstration of Kugel's artery (arteria anastomotica auricularis magna). Radiology 1973;106:113–8**) have not accepted the term “artery” because they found small atrial branches, but not a vessel so large in diameter as an artery in the lower part of the interatrial septum. It is strange, however, that they used the term Kugel's artery, despite the

fact that they described only an anastomotic network in this area. Nerantzis et al. found only 6 Kugel's arteries out of 100 normal hearts (6%). Similar percentages ranging between 3.6% and 6%, albeit in patients with severe atherosclerotic heart disease, have been reported in the literature, in 3 coronary angiographic studies (**Grollman JH Jr, Heger L. Angiographic anatomy of the left Kugel's artery. Cathet Cardiovasc Diagn 1978;4:127–33; Levin DC. Pathways and functional significance of the coronary collateral circulation. Circulation 1974;50:831–7; Soto B, Jochem W, Karp RB, Barcia A. Angiographic anatomy of the Kugel's artery. Am J Roengenol Radium Ther Nucl Med 1973;119:503–7**). On the other hand, in anatomical studies, the percentage ranged between 40% and 66%. These increased percentages probably included cases with a large anastomotic network. It is hard to explain why other authors did not report any percentages in their studies. Kugel's arteries originated from the LCx in 3 hearts and from the RCA in the other 3 (via the sinus node artery in 1 of these last). Nerantzis results, in accordance with previous publications, clearly demonstrate that this artery does not have a standard point of origin. In their 6 hearts, Kugel's artery was connected directly with the distal artery after it crossed the crux, keeping a course independent from the AVN artery. The same finding has been described BY Thompson (**Thompson AJ, Froelicher VF. Kugel's artery as a major collateral channel in severe coronary disease. Aerosp Med 1974; 45(11):1276–80**). Kugel reported that in some cases his artery connected directly with the distal RCA , while in all other cases it connected via the AVN artery. Most of the authors who have reported finding Kugel's artery in their anatomical and angiographic studies have mentioned its indirect connection with the artery that crosses the crux, always through the AVN by Soto and Smith. Kugel's artery is difficult to demonstrate in postmortem angiography, and it is also difficult to see in vivo, in the usual coronary arteriographic projections. However, with Nerantzis technique, they succeeded in demonstrating clearly for the 1st time this artery in postmortem angiograms. Nerantzis also believe that Kugel's artery will be easy to demonstrate in vivo if the right oblique projection is used for the right arteriogram and the left lateral projection for the left arteriogram. In both projections, a cephalad angle will often help to bring the artery into the middle of the projection, parallel to the AVN

artery, thereby avoiding overlap with the vessels in the atrioventricular groove. The anastomotic network was found in all 100 hearts, connecting indirectly the proximal and distal parts of the large coronary arteries—via the AVN artery in 66 cases and, in the rest, via small branches from the artery that crossed the crux. This type of connection via the AVN artery has been described in most of the studies. The sinus node artery or its branches contributed to the formation of this network, an observation that has been mentioned. Nerantzis et al. observed the participation of the right superior descending artery, but they did not describe this in detail because of the small number of cases in which it was found. They believe that our technique will render satisfactory the postmortem angiographic demonstration of the network in normal hearts, but in vivo arteriographic demonstration of the network, unlike that of Kugel's artery, will remain very difficult due to the small size of the vessels. In other studies, all these inter- and intracoronary anastomoses tended to be larger in hearts with stenotic lesions of the major epicardial coronary arteries. Since both Kugel's artery and the anastomotic network originate from the beginning of the coronary trunks, they have to be taken into consideration in many surgical procedures involving the aortic root. Moreover, interventional cardiologists who perform procedures involving the lower part of the interatrial septum, such as radiofrequency ablation and biventricular pacemaker insertion, should be aware of the potential risk of damaging these important anastomotic branches.

In conclusion, following the observations of Nerantzis et al an anastomotic network of small atrial branches courses through the lower part of the interatrial septum and in all cases indirectly connects the proximal to the distal ends of the larger coronary arteries, while Kugel's artery, in 6% of the cases, provides a direct arterial anastomosis in the same area. The knowledge from these findings is important for anatomists, cardiologists, and cardiac surgeons Figures of slides 56 and 57.

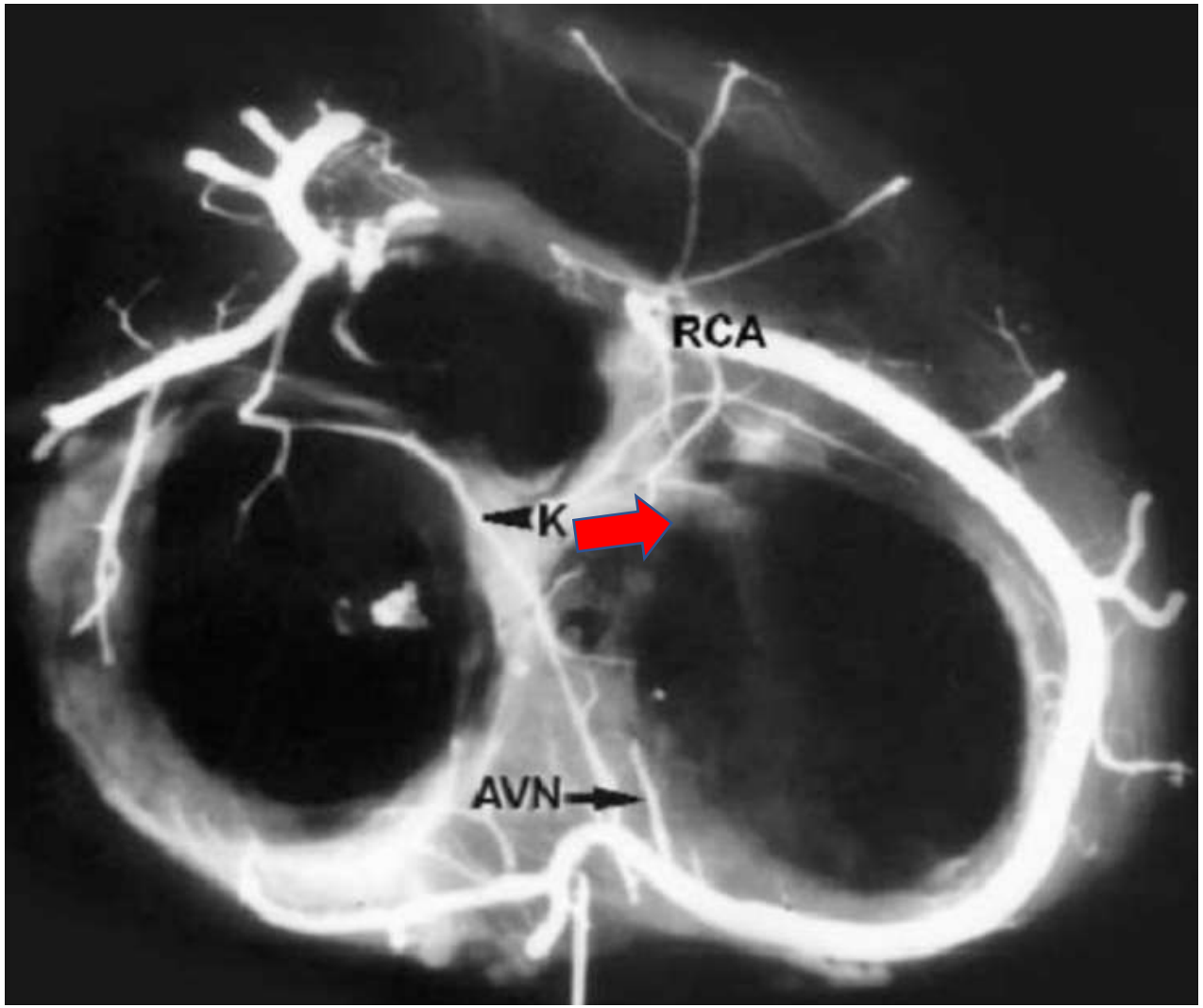

Superior view of the middle part of a normal right dominant heart containing the arteries and their branches that course through the atrioventricular groove and the lower portion of the interatrial septum. The arteriogram shows that Kugel's artery (K red arrow) directly connects the proximal left circumflex artery with the distal right coronary artery (RCA) near the crux (inter coronary connection). Kugel's artery distributes branches throughout its course. The independent atrioventricular node (AVN) artery can also be seen. Furthermore, atrial branches forming an anastomotic network are shown.

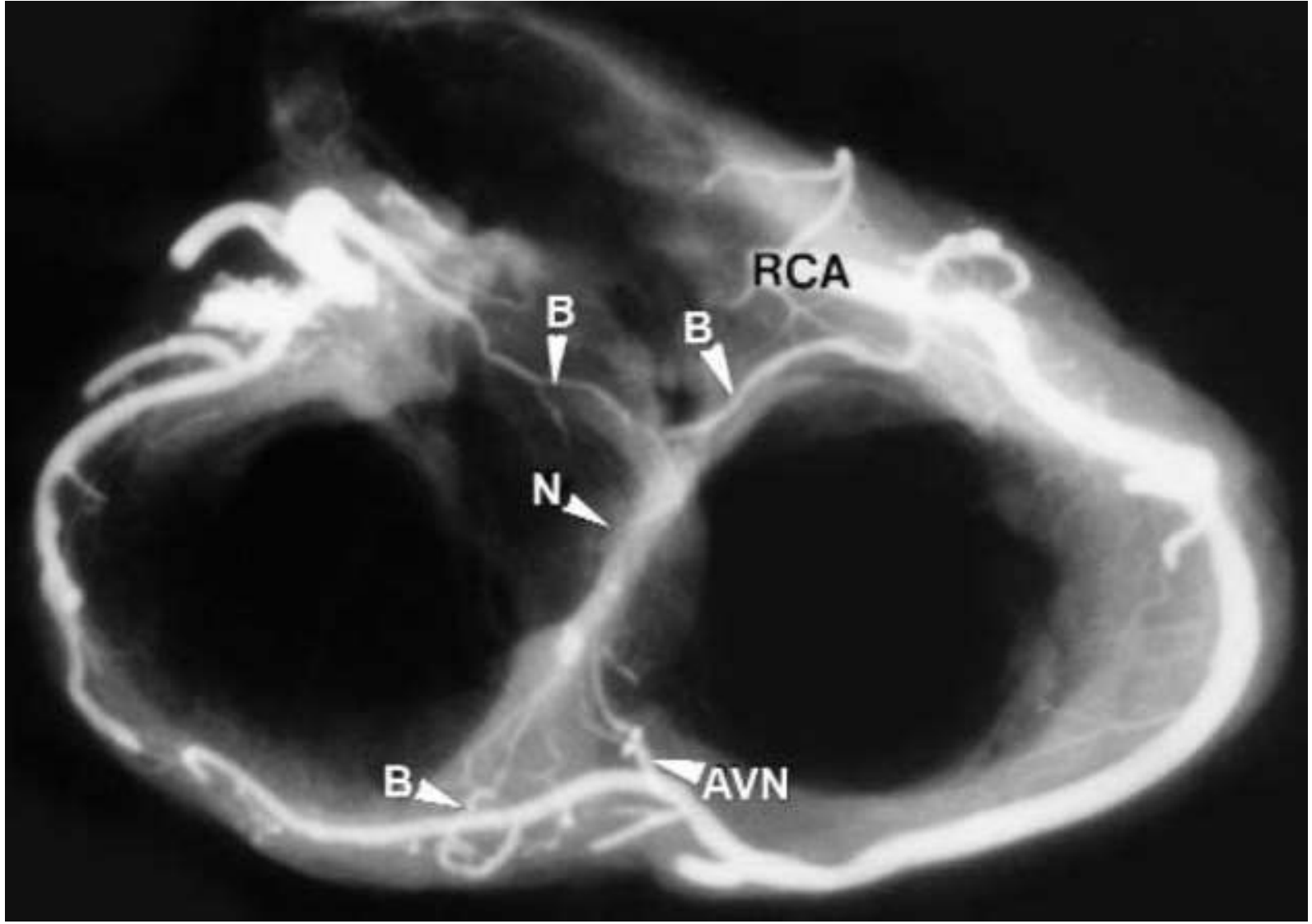

Superior view of the middle part of a normal right dominant heart containing the arteries and their branches that course through the atrioventricular groove and the lower portion of the interatrial septum. The arteriogram shows that atrial branches (B) originating from the proximal left circumflex artery and the RCA connect and form an anastomotic network (N). It also shows the contribution of the atrioventricular node (AVN) artery to the network. Note that the atrial branches shown The authors magnified this figure to better demonstrate the network and also because the absence of Kugel's artery makes them larger.

Professor Gustavo Abuin
Kugel's artery
Universidad de Buenos Aires | UBA · Department of Anatomy
Figures 1, 2 and 3 Gustavo Abuin currently works at the Department of Anatomy, University of Buenos Aires. Gustavo does research in Cardiothoracic Surgery.

Kugel's artery. A) Anastomosis between right and left coronary trunks.

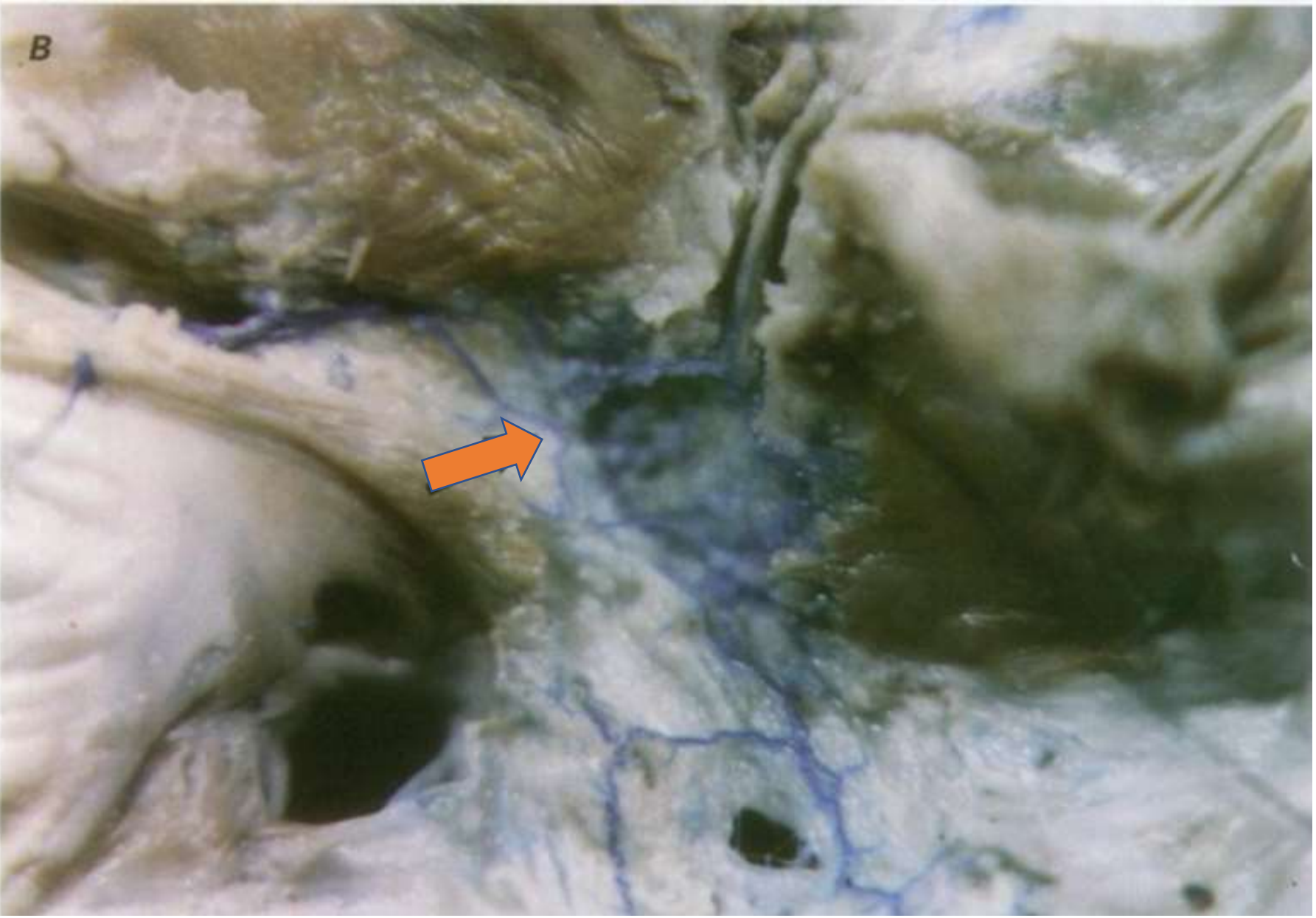

Atrial branch supplying the atrioventricular node (arrow).

The anatomy of the heart's conduction system and of its blood supply have been research topics for many years. However, several proposals have never been demonstrated. Professor Gustavo Abuin et al, described 2 vascular conduits that have never before been objectively shown to supply the conduction system. Twenty human hearts from subjects aged between 15 and 65 years--with and without coronary artery disease--were dissected after anterograde and retrograde injection with latex butaclor E-650 by means of a technique developed by the authors. In 40% of these hearts, Kugel's artery was found to supply the atrioventricular node. The right descending superior artery supplied the atrioventricular node in 70% of the hearts dissected. These findings may be of major significance both in clinical cardiology and in cardiovascular surgery.

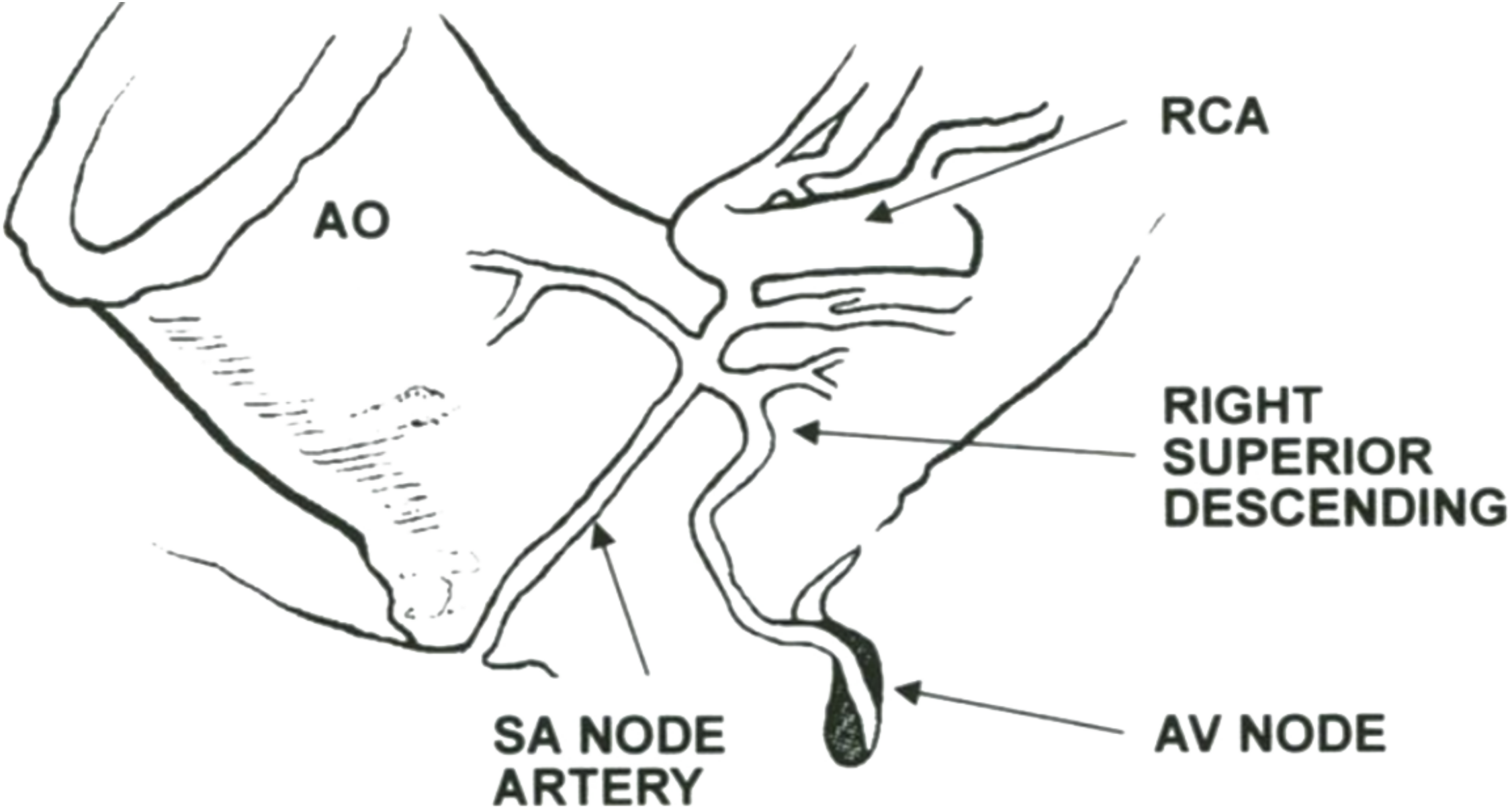

The right superior descending artery has an important role in RCA supplying the atrioventricular node (arrow).