CHAPTER 11

Blood Vessels

PBD9 Chapter 11 and PBD8 Chapter 11: Blood Vessels

BP9 Chapter 9 and BP8 Chapter 10: Blood Vessels

1 A malignant neoplasm is found within the cranial cavity. A biopsy is obtained and microscopic examination shows malignant cells within vascular lumina. Which of the following types of vessels is most likely to be invaded by this malignancy?

- **A** Arterioles
- **B** Capillaries
- **C** Lymphatics
- **D** Muscular arteries
- **E** Veins

2 A 44-year-old woman is found to have a blood pressure of 150/100 mm Hg on a routine physical examination following a transient ischemic attack (TIA). Laboratory studies show normal serum potassium, sodium, and natriuretic peptide levels but increased plasma renin activity. Her urinary fractional excretion of sodium is normal. Which of the following vascular abnormalities is most likely to be seen on renal arterial angiography?

- **A** Arterial dissection
- **B** Arteriovenous fistula
- **C** Berry aneurysm
- **D** Focal stenosis and dilation
- **E** Vascularized mass lesion

3 A dermal venule with endothelial cells in the basal state is stressed by release of biogenic amines from mast cells following anaphylaxis. The extravascular fluid compartment increases in size. Which of the following is the most likely change occurring in these activated endothelial cells?

- **A** Cytoplasmic contraction
- **B** Free radical formation
- **C** mRNA translation
- **D** Thromboxane synthesis
- **E** VEGF elaboration

4 A 73-year-old healthy man has experienced lightheadedness with episodes of fainting for the past 10 days. On examination, his blood pressure changes from 135/90 mm Hg when lying down to 100/60 mm Hg when he assumes a sitting position. Laboratory studies show his serum electrolyte levels are normal. Which of the following regulatory mechanisms for blood pressure is most likely altered in this man?

- **A** Aldosterone release
- **B** Cardiac output
- **C** Intravascular volume
- **D** Renin synthesis
- **E** Sympathetic tone
- **F** Vasoconstriction

5 A 55-year-old woman has had dull, episodic headaches for the past year, but otherwise she feels fine and has had no major medical illnesses or surgical procedures during her lifetime. On physical examination, her temperature is 37° C, pulse is 70/min, respirations are 14/min, and blood pressure is 166/112 mm Hg. Her lungs are clear on auscultation, and her heart rate is regular. An abdominal ultrasound scan shows that the left kidney is smaller than the right kidney. A renal angiogram shows a focal stenosis of the left renal artery. Which of the following laboratory findings is most likely to be present in this patient?

- **A** Anti–double-stranded DNA titer 1:512
- **B** C-ANCA titer 1:256
- **C** increased cryoglobulins in blood
- **D** Plasma glucose level 200 mg/dL
- **E** Marked elevation in HIV RNA
- **F** Plasma renin 15 mg/mL/hr

6 A clinical study is performed that includes a group of subjects whose systemic blood pressure measurements are consistently between 145/95 mm Hg and 165/105 mm Hg. They are found to have increased cardiac output and increased peripheral vascular resistance. Renal angiograms show no abnormal findings, and CT scans of the abdomen show no masses. Laboratory studies show normal levels of serum creatinine and urea nitrogen. The subjects take no medications. Which of the following laboratory findings is most likely to be present in this group of subjects?

- **A** Decreased urinary sodium
- **B** Elevated plasma renin
- **C** Hypokalemia
- **D** Increased urinary catecholamines
- **E** Lack of angiotensin-converting enzyme

7 A 61-year-old woman has smoked two packs of cigarettes per day for the past 40 years. She has experienced increasing dyspnea for the past 6 years. On physical examination, her vital signs are temperature, 37.1° C; pulse, 60/min; respirations, 18/min and labored; and blood pressure, 130/80 mm Hg. On auscultation, expiratory wheezes are heard over the chest bilaterally. Her heart rate is regular. A chest radiograph shows increased lung volume, with flattening of the diaphragms, greater lucency to all lung fields, prominence of pulmonary arteries, and a prominent border on the right side of the heart. Laboratory studies include blood gas measurements of Po_2 of 80 mm Hg, Pco_2 of 50 mm Hg, and pH of 7.35. Which of the following morphologic findings is most likely to be present in her pulmonary arteries?

- **A** Amyloid deposition
- **B** Atheromatous plaques
- **C** Intimal tears
- **D** Medial calcific sclerosis
- **E** Necrotizing vasculitis
- **F** Phlebothrombosis

8 A population health study shows that the prevalence of essential hypertension has been increasing for the past 10 years and now is found in one fourth of all adults. A strategy is adopted to decrease the prevalence of hypertension through lifestyle changes. A policy to reduce dietary intake of which of the following is most likely to support this goal?

- **A** Alcohol
- **B** Animal protein
- **C** Coffee
- **D** Eggs
- **E** Milk products
- **F** Salt
- **G** Sugar

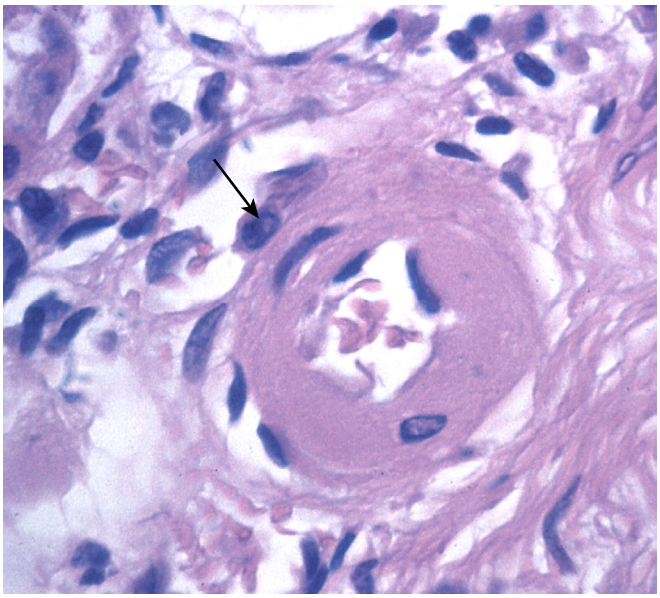

9 A 61-year-old man has reported increasing fatigue over the past year. Laboratory studies show a serum creatinine level of 4.7 mg/dL and urea nitrogen level of 44 mg/dL. An abdominal ultrasound scan shows that his kidneys are symmetrically smaller than normal. The representative high-magnification microscopic appearance of the kidneys is shown in the figure. These findings are most likely to indicate which of the following underlying conditions?

- **A** Adenocarcinoma of the colon
- **B** *Escherichia coli* septicemia
- **C** Polyarteritis nodosa
- **D** Syphilitic endarteritis
- **E** Systemic hypertension

10 A 45-year-old man has had poorly controlled hypertension ranging from 150/90 mm Hg to 160/95 mm Hg for the past 11 years. Over the past 3 months, his blood pressure has increased to 250/125 mm Hg. On physical examination, his temperature is 36.9° C. His lungs are clear on auscultation, and his heart rate is regular. There is no abdominal pain on palpation. A chest radiograph shows a prominent border on the left side of the heart. Laboratory studies show that his serum creatinine level has increased during this time from 1.7 mg/dL to 3.8 mg/dL. Which of the following vascular lesions is most likely to be found in this patient's kidneys?

- **A** Fibromuscular dysplasia
- **B** Granulomatous arteritis
- **C** Renal arterial stenosis
- **D** Necrotizing arteriolitis
- **E** Polyarteritis nodosa

11 A 57-year-old woman experiences mild intermittent right hip pain after falling down a flight of stairs. Physical examination shows a 3-cm contusion over the right hip. The area is tender to palpation, but she has full range of motion of the right leg. A radiograph of the pelvis and right upper leg shows no fractures, but does show calcified, medium-sized arterial branches in the pelvis. This radiographic finding is most likely to represent which of the following?

- **A** An incidental observation
- **B** Benign essential hypertension
- **C** Increased risk for gangrenous necrosis
- **D** Long-standing diabetes mellitus
- **E** Unsuspected hyperparathyroidism

12 A study of risk factors for atherogenesis in adults is performed. Chemical factors are found that are associated with reduction in serum cholesterol. Which of the following substances is most likely to reduce serum cholesterol?

- **A** C-reactive protein
- **B** Homocysteine
- **C** Lipoprotein(a)
- **D** Omega-3 fatty acids
- **E** *trans*–unsaturated fats

13 A cohort study is performed involving healthy adult men and women born 20 years ago. They are followed to assess development of atherosclerotic cardiovascular diseases. Multiple laboratory tests are performed yearly during this study. An increase in which of the following is most likely to indicate the greatest relative risk for development of one of these diseases?

- **A** Anti–proteinase 3 (PR3)
- **B** C-reactive protein (CRP)
- **C** Cryoglobulin
- **D** Erythrocyte sedimentation rate (ESR)
- **E** Platelet count

14 A 58-year-old man had a myocardial infarction 1 year ago, which was the first major illness in his life. He now wants to prevent another acute coronary event and is advised to begin a program of exercise and to change his diet. A reduction in the level of which of the following serum laboratory findings 1 year later would best indicate the success of his diet and exercise regimen?

- **A** Calcium
- **B** Cholesterol
- **C** Glucose
- **D** Potassium
- **E** Renin

15 A 35-year-old woman has a reputation as a perfectionist. She has angina pectoris of 6 months' duration. On physical examination, her blood pressure is 135/85 mm Hg. She is 168 cm (5 ft 5 in) tall and weighs 82 kg (BMI 29). Her Hgb A_{1C} is 9% and fasting serum glucose is 143 mg/dL. Coronary angiography shows 75% narrowing of the anterior descending branch of the left coronary artery and 70% narrowing of the right coronary artery. Angioplasty with stent placement is performed. Which of the following is her greatest risk factor for the causation of her disease?

- **A** Age
- **B** Diabetes mellitus
- **C** Obesity
- **D** Sedentary lifestyle
- **E** Type A personality

16 An experiment studies early atheroma development. Lipid streaks on arterial walls are examined microscopically and biochemically to determine their cellular and chemical constituents and the factors promoting their formation. Early lesions show increased attachment of monocytes to endothelium. The monocytes migrate subendothelially and become macrophages; these macrophages transform themselves into foam cells. Which of the following substances is most likely to be responsible for the transformation of macrophages?

- **A** C-reactive protein
- **B** Homocysteine
- **C** Lp(a)
- **D** Oxidized LDL
- **E** Platelet-derived growth factor
- **F** VLDL

17 A 29-year-old man has had angina for the past year. There is a family history of cardiovascular disease. On examination, his blood pressure is 120/80 mm Hg. Laboratory studies show total serum cholesterol 185 mg/dL and glucose 85 mg/dL. A mutation involving a gene encoding for which of the following is most likely present in this man's family?

- **A** Angiotensin
- **B** Apolipoprotein
- **C** Endothelin
- **D** Factor VIII
- **E** Von Willebrand factor

18 A study is conducted involving persons with LDL cholesterol levels above 160 mg/dL. They are found to have increased oxidized LDL deposited in their arteries. As a consequence the arterial lumen, particularly at branch points, is decreased in size. Which of the following is the most likely pathologic change that develops initially in these areas of arterial narrowing?

- **A** Endothelial cell disruption
- **B** Intimal thickening
- **C** Lymphocytic infiltrates
- **D** Platelet aggregation
- **E** Smooth muscle hypertrophy

19 A 50-year-old man has a 2-year history of angina pectoris that occurs during exercise. On physical examination, his blood pressure is 135/75 mm Hg, and his heart rate is 79/min and slightly irregular. Coronary angiography shows a fixed 75% narrowing of the anterior descending branch of the left coronary artery. He has several risk factors for atherosclerosis: smoking, hypertension, and hypercholesterolemia. Which of the following is the earliest event resulting from the effects of these factors?

- **A** Alteration in vasomotor tone regulation
- **B** Conversion of smooth muscle cells to foam cells
- **C** Dysfunction from endothelial injury
- **D** Inhibition of LDL oxidation
- **E** Modification of hepatic lipoprotein receptors

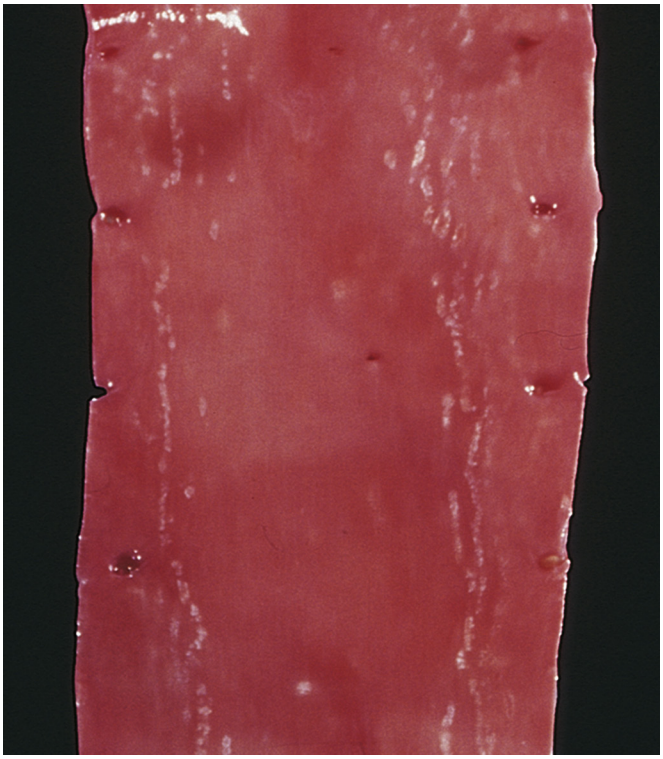

20 A 12-year-old boy died of complications of acute lymphocytic leukemia. There is no family history of cardiovascular disease. The gross appearance of the aorta at autopsy is shown in the figure. Histologic examination of the linear pale markings is most likely to show which of the following features?

- **A** Cap of smooth muscle cells overlying a core of lipid debris
- **B** Collection of foam cells with necrosis and calcification
- **C** Granulation tissue with a lipid core and areas of hemorrhage
- **D** Lipid-filled foam cells and small numbers of T lymphocytes
- **E** Cholesterol clefts surrounded by proliferating smooth muscle cells and foam cells

21 A study of atheromatous plaques shows that release of growth factors, including PDGF, FGF, and TNF-α leads to increased extracellular matrix production. As a result, the size of the plaques increases. Which of the following cells is most likely to release these growth factors in the plaques?

- **A** Endothelium
- **B** Fibroblast
- **C** Platelet
- **D** Smooth muscle
- **E** T lymphocyte

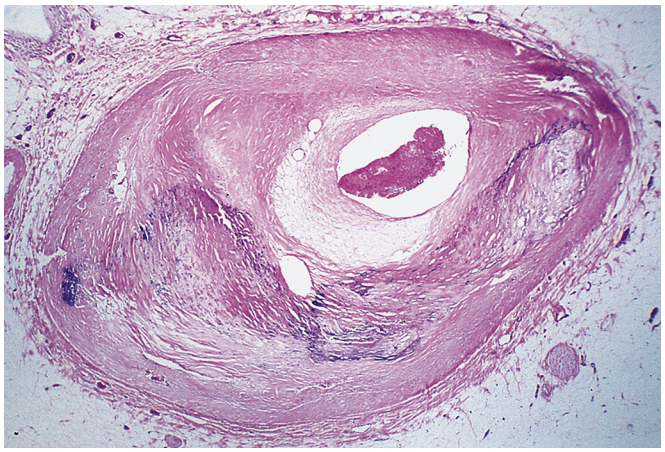

22 A 58-year-old woman has experienced chest pain at rest for the past year. On physical examination, her pulse is 80/min and irregular. The figure shows the microscopic appearance representative of her left anterior descending artery. Which of the following laboratory findings is most likely to be involved in the pathogenesis of the process illustrated?

- **A** Elevated platelet count
- **B** Low HDL cholesterol
- **C** Low Lp(a)
- **D** Low plasma homocysteine
- **E** Positive VDRL

23 In an experimental model of atherosclerosis, plaques are shown to change slowly but constantly in ways that can promote clinical events, including acute coronary syndromes. In some cases, changes were not significantly associated with acute coronary syndromes. Which of the following plaque alterations is most likely to have such an association?

- **A** Calcium deposition
- **B** Hemorrhage into the plaque substance
- **C** Intermittent platelet aggregation
- **D** Thinning of the media
- **E** Ulceration of the plaque surface

24 A 59-year-old woman with type II diabetes mellitus experiences an episode of chest pain with exercise. On examination, her BMI is 30. Angiography reveals proximal coronary arterial narrowing with up to 70% stenosis. Which of the following pharmacologic agents ingested in low doses daily is most appropriate for reducing her risk for myocardial infarction?

- **A** Acetaminophen
- **B** Aspirin
- **C** Ibuprofen
- **D** Paclitaxel
- **E** Propranolol

25 An 84-year-old man with a lengthy history of smoking survived a small myocardial infarction 2 years ago. He now reports chest and leg pain during exercise. On physical examination, his vital signs are temperature, 37.1° C; pulse, 81/min; respirations, 15/min; and blood pressure, 165/100 mm Hg. Peripheral pulses are poor in the lower extremities. There is a 7-cm pulsating mass in the midline of the lower abdomen. Laboratory studies include two fasting serum glucose measurements of 170 mg/dL and 200 mg/dL. Which of the following vascular lesions is most likely to be present in this patient?

- **A** Aortic dissection
- **B** Arteriovenous fistula
- **C** Atherosclerotic aneurysm
- **D** Polyarteritis nodosa
- **E** Takayasu arteritis
- **F** Thromboangiitis obliterans

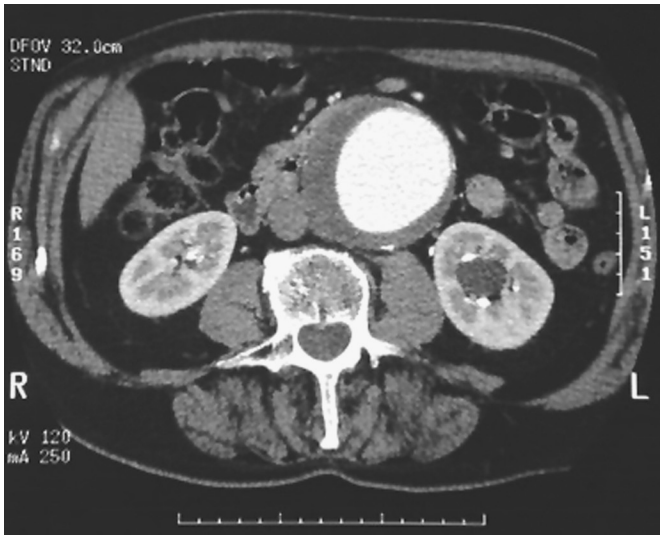

26 A 41-year-old man has had worsening abdominal pain for the past week. On physical examination, his vital signs are temperature, 36.9° C; pulse, 77/min; respirations, 16/min; and blood pressure, 140/90 mm Hg. An abdominal CT scan shows the findings in the figure. Which of the following is the most likely underlying disease process in this patient?

- **A** Diabetes mellitus
- **B** Marfan syndrome
- **C** Polyarteritis nodosa
- **D** Systemic lupus erythematosus
- **E** Syphilis

27 A 77-year-old man has had progressive dementia and gait ataxia for the past 9 years. He succumbs to bronchopneumonia. Autopsy shows that the thoracic aorta has a dilated root and arch, giving the intimal surface a "tree-bark" appearance. Microscopic examination of the aorta shows an obliterative endarteritis of the vasa vasorum. Which of the following laboratory findings is most likely to be recorded in this patient's medical history?

- **A** Antibodies against *Treponema pallidum*
- **B** Double-stranded DNA titer positive at 1:512
- **C** Ketonuria of 4+
- **D** P-ANCA positive at 1:1024
- **E** Sedimentation rate of 105 mm/hr

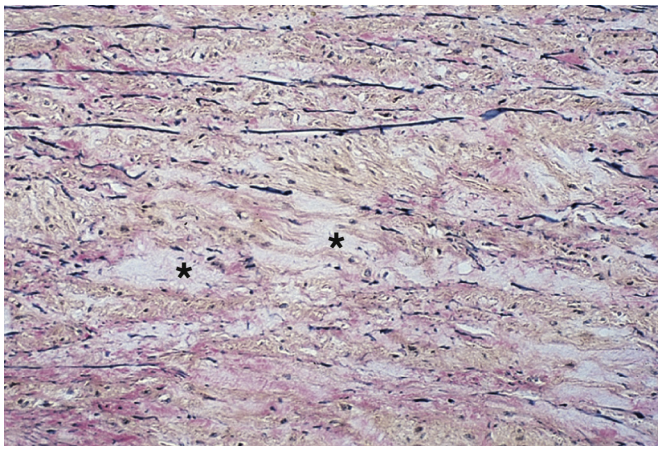

28 A 23-year-old man experiences sudden onset of severe, sharp chest pain. On physical examination, his temperature is 36.9° C, and his lungs are clear on auscultation. A chest radiograph shows a widened mediastinum. Transesophageal echocardiography shows a dilated aortic root and arch, with a tear in the aortic intima 2 cm distal to the great vessels. The representative microscopic appearance of the aorta with elastic stain is shown in the figure. Which of the following diseases is the most likely cause of these findings?

- **A** ANCA-associated vasculitis
- **B** Diabetes mellitus, maturity onset type
- **C** Marfan syndrome
- **D** Scleroderma, diffuse
- **E** Systemic hypertension
- **F** Takayasu arteritis

29 A 59-year-old man experiences sudden severe chest pain that radiates to his back. On physical examination his blood pressure is 170/110 mm Hg. Heart sounds are distant. Pulsus paradoxus is observed. A pericardiocentesis is performed and yields blood. Which of the following pathologic findings has most likely occurred in his aorta?

- **A** Aneurysm
- **B** Arteriolosclerosis
- **C** Dissection
- **D** Thrombosis
- **E** Vasculitis

30 A 75-year-old man has experienced headaches for the past 2 months. On physical examination, his vital signs are temperature, 37° C; pulse, 68/min; respirations, 15/min; and blood pressure, 130/85 mm Hg. His right temporal artery is prominent, palpable, and painful to the touch. His heart rate is regular, and there are no murmurs. His erythrocyte sedimentation rate is 100 mm/hr. A temporal artery biopsy is performed, and the segment of temporal artery excised is grossly thickened and shows focal microscopic granulomatous inflammation. He responds well to corticosteroid therapy. Which of the following complications of this disease is most likely to occur in untreated patients?

- **A** Blindness
- **B** Gangrene of the toes
- **C** Hemoptysis
- **D** Malignant hypertension
- **E** Renal failure

31 A 32-year-old woman has had coldness and numbness in her arms and decreased vision in the right eye for the past 5 months. On physical examination, she is afebrile. Her blood pressure is 100/70 mm Hg. Radial pulses are not palpable, but femoral pulses are strong. She has decreased sensation and cyanosis in her arms, but no warmth or swelling. A chest radiograph shows a prominent border on the right side of the heart and prominence of the pulmonary arteries. Laboratory studies show serum glucose, 74 mg/dL; creatinine, 1 mg/dL; total serum cholesterol, 165 mg/dL; and negative ANA test result. Her condition remains stable for the next year. Which of the following is the most likely diagnosis?

- **A** Aortic dissection
- **B** Kawasaki disease
- **C** Microscopic polyangiitis
- **D** Syphilis
- **E** Takayasu arteritis
- **F** Thromboangiitis obliterans

32 A 43-year-old man has experienced malaise, fever, and a 4-kg weight loss over the past month. On physical examination, his blood pressure is 145/90 mm Hg, and he has mild diffuse abdominal pain, but no masses or hepatosplenomegaly. Laboratory studies include a serum urea nitrogen concentration of 58 mg/dL and a serum creatinine level of 6.7 mg/dL. Renal angiography shows right renal arterial thrombosis, and the left renal artery and branches show segmental luminal narrowing with focal aneurysmal dilation. During hemodialysis 1 week later, he experiences abdominal pain and diarrhea and is found to have melena. Which of the following serologic laboratory test findings is most likely to be positive in this patient?

- **A** ANA
- **B** C-ANCA
- **C** HIV
- **D** HBsAg
- **E** Scl-70
- **F** RPR

33 A 3-year-old child from Osaka, Japan, has developed a fever and a rash and swelling of her hands and feet over the past 2 days. On physical examination, her temperature is 37.8° C. There is a desquamative skin rash, oral erythema, erythema of the palms and soles, edema of the hands and feet, and cervical lymphadenopathy. The child improves after a course of intravenous immunoglobulin therapy. Which of the following is most likely to be a complication of this child's disease if it is untreated?

- **A** Asthma
- **B** Glomerulonephritis
- **C** Intracranial hemorrhage
- **D** Myocardial infarction
- **E** Pulmonary hypertension

34 A 50-year-old man has had a chronic cough for the past 18 months. Physical examination shows nasopharyngeal ulcers, and the lungs have diffuse crackles bilaterally on auscultation. Laboratory studies include a serum urea nitrogen level of 75 mg/dL and a creatinine concentration of 6.7 mg/dL. Urinalysis shows 50 RBCs per high-power field and RBC casts. His serologic titer for C-ANCA (proteinase 3) is elevated. A chest radiograph shows multiple, small, bilateral pulmonary nodules. A transbronchial lung biopsy specimen shows a necrotizing inflammatory process involving the small peripheral pulmonary arteries and arterioles. Which of the following is the most likely diagnosis?

- **A** Granulomatosis with polyangiitis
- **B** Fibromuscular dysplasia
- **C** Granuloma pyogenicum
- **D** Kaposi sarcoma
- **E** Polyarteritis nodosa
- **F** Takayasu arteritis

35 A 50-year-old man with muscle pain and fever for a month now notes darker colored urine for the past 2 weeks. On physical examination he has palpable purpuric lesions of his skin. Urinalysis shows hematuria and proteinuria. Serum laboratory findings include a mixed cryoglobulinemia with a polyclonal increase in IgG, as well as a high titer of anti–neutrophil cytoplasmic autoantibodies, mainly antimyeloperoxidase (MPO-ANCA, or P-ANCA). A skin biopsy is performed. What pathologic finding is most likely to be observed in this biopsy?

- **A** Giant cells and macrophages
- **B** Medial fibrinoid necrosis
- **C** Microabscesses
- **D** Mycotic aneurysms
- **E** Perivascular eosinophilic infiltrates

36 A 33-year-old man has smoked two packs of cigarettes per day since he was a teenager. He has had painful thromboses of the superficial veins of the lower legs for 1 month and episodes during which his fingers become blue and cold. Over the next year, he develops chronic, poorly healing ulcerations of his feet. One toe becomes gangrenous and is amputated. Histologically, at the resection margin, there is an acute and chronic vasculitis involving medium-sized arteries, with segmental involvement. Which of the following is the most appropriate next step in treating this patient?

- **A** Antibiotic therapy
- **B** Corticosteroid therapy
- **C** Hemodialysis
- **D** Insulin therapy
- **E** Smoking cessation

37 An 8-year-old child has had abdominal pain and dark urine for 10 days. Physical examination shows blotchy purple skin lesions on the trunk and extremities. Urinalysis shows hematuria and proteinuria. Serologic test results are negative for MPO-ANCA (P-ANCA) and PR3-ANCA (C-ANCA). A skin biopsy specimen shows necrotizing vasculitis of small dermal vessels. A renal biopsy specimen shows immune complex deposition in glomeruli, with some IgA-rich immune complexes. Which of the following is the most likely diagnosis?

- **A** Giant cell arteritis
- **B** Henoch-Schönlein purpura
- **C** Polyarteritis nodosa
- **D** Takayasu arteritis
- **E** Telangiectasias

38 A 35-year-old woman with a history of injection drug use has developed a high fever over the past day. On examination her temperature is 37.6° C. A heart murmur is auscultated. Blood culture is obtained and grows *Staphylococcus aureus.* She develops a severe headache. A head CT scan shows an intracranial hemorrhage. Which of the following vascular complications has most likely occurred in her brain?

- **A** Bacillary angiomatosis
- **B** Hyperplastic arteriolosclerosis
- **C** Lymphangitis
- **D** Mycotic aneurysm
- **E** Phlebothrombosis

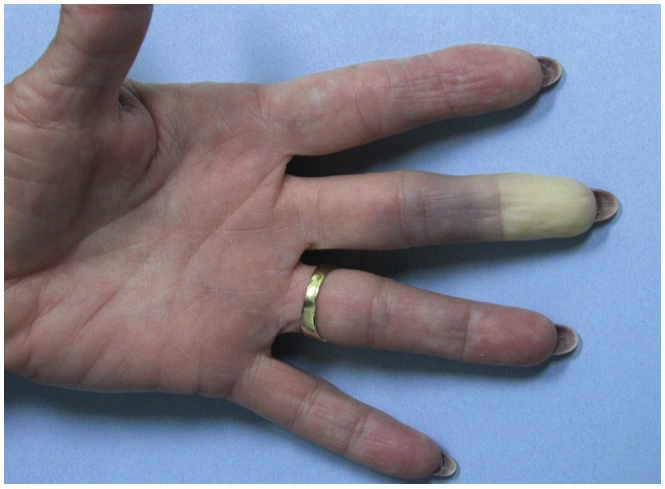

39 A 60-year-old woman noted the change seen in the figure while she was driving to work one morning. There was associated pain and numbness. Within 20 minutes after entering the warm office building, these problems disappeared. What pathologic process has most likely led to these findings?

- **A** Calcification
- **B** Hypertension
- **C** Thrombosis
- **D** Vasculitis
- **E** Vasoconstriction

40 A 21-year-old healthy woman, who is in week 34 of a normal pregnancy, complains of itching with burning pain in the perianal region for the past 4 months. She noted a small amount of bright red blood on toilet paper last week. Which of the following underlying conditions is most likely to be present in this patient?

- **A** Filariasis
- **B** Polyarteritis nodosa
- **C** External hemorrhoids
- **D** Micronodular cirrhosis
- **E** Rectal adenocarcinoma

41 A 69-year-old woman has been bedridden while recuperating from a bout of viral pneumonia complicated by bacterial pneumonia for the past 2 weeks. Physical examination now shows some swelling and tenderness of the right leg, which worsens when she raises or moves the leg. Which of the following terms best describes the condition involving her right leg?

- **A** Disseminated intravascular coagulation
- **B** Lymphedema
- **C** Thromboangiitis obliterans
- **D** Thrombosis of deep veins
- **E** Varicose veins

42 A healthy 54-year-old woman has noted the increasing prominence of unsightly dilated superficial veins over both lower legs for the past 5 years. Physical examination shows temperature of 37° C, pulse of 70/min, respirations of 14/min, and blood pressure of 125/85 mm Hg. There is no pain, swelling, or tenderness in either lower leg. Which of the following complications is most likely to occur as a consequence of her condition?

- **A** Atrophy of the lower leg muscles
- **B** Disseminated intravascular coagulation
- **C** Gangrenous necrosis of the lower legs
- **D** Pulmonary thromboembolism
- **E** Stasis dermatitis with ulceration

43 A 48-year-old woman has developed persistent swelling and puffiness in the left arm after a mastectomy with axillary node dissection for breast cancer 1 year ago. She developed cellulitis in the left arm 3 months ago. Physical examination shows firm skin over the left arm and "doughy" underlying soft tissue. The arm is not painful or discolored. Which of the following terms best describes these findings?

- **A** Lymphedema
- **B** Subclavian arterial thrombosis
- **C** Thrombophlebitis
- **D** Tumor embolization
- **E** Vasculitis

44 A 50-year-old man cuts his right index finger on a sharp metal shard while cleaning debris out of the gate in an irrigation canal. The cut stops bleeding within 3 minutes, but 6 hours later he notes increasing pain in the right arm and goes to his physician. On physical examination, his temperature is 38° C. Red streaks extend from the right hand to the upper arm, and the arm is swollen and tender when palpated. Multiple tender lumps are noted in the right axilla. A blood culture grows group A β-hemolytic streptococcus. Which of the following terms best describes the process that is occurring in this patient's right arm?

- **A** Capillaritis
- **B** Lymphangitis
- **C** Lymphedema
- **D** Phlebothrombosis
- **E** Polyarteritis nodosa
- **F** Thrombophlebitis
- **G** Varices

45 A 46-year-old man has noted increasing abdominal enlargement over the past 15 months. Physical examination shows multiple skin lesions on the upper chest that have central pulsatile cores and measure, from core to periphery, 0.5 to 1.5 cm. Pressing on a core causes a radially arranged array of subcutaneous arterioles to blanch. Laboratory studies show serum glucose of 112 mg/dL, creatinine of 1.1 mg/dL, total protein of 5.8 g/dL, and albumin of 3.4 g/dL. Which of the following underlying diseases is most likely to be present in this patient?

- **A** AIDS
- **B** Diabetes mellitus
- **C** Granulomatosis with polyangiitis
- **D** Marfan syndrome
- **E** Micronodular cirrhosis

46 A 21-year-old woman is in the third trimester of an uncomplicated pregnancy. She has noted an enlarging nodule in her mouth for the past 2 weeks. On physical examination there is a 1-cm red nodule on the left lateral gingiva below the first molar. The nodule regresses following delivery. What is this nodule most likely to be?

- **A** Bacillary angiomatosis
- **B** Capillary hemangioma
- **C** Cavernous lymphangioma
- **D** Glomus tumor
- **E** Kaposi sarcoma

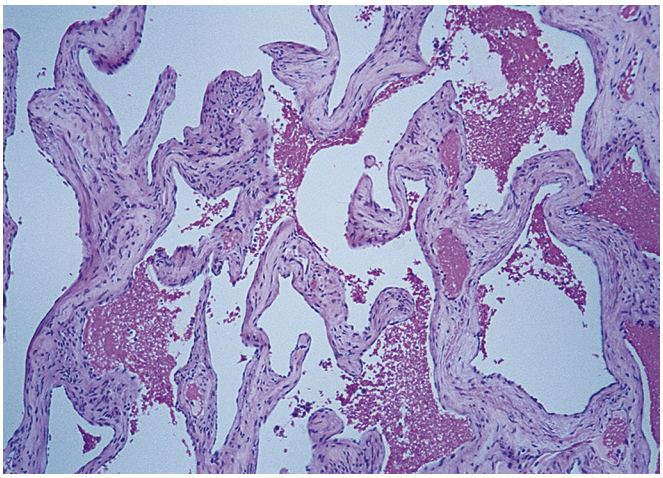

47 A 10-year-old boy has a 2-cm spongy, dull red, circumscribed lesion on the upper outer left arm. The parents state that this lesion has been present since infancy, and the appearance has not appreciably changed. The lesion is excised, and its microscopic appearance is shown in the figure. Which of the following is the most likely diagnosis?

- **A** Angiosarcoma
- **B** Hemangioma
- **C** Kaposi sarcoma
- **D** Lymphangioma
- **E** Telangiectasia

48 A 6-year-old previously healthy child has had increasing size of his neck for the past year. Physical examination reveals an ill-defined, soft mass deforming the left side of his neck, but no other abnormalities. Surgical resection of the 10 cm mass is attempted, but the borders of the lesion are not discrete. Pathologic examination of the resected tissue shows dilated spaces filled with milky fluid and bounded by thin connective tissue walls. Microscopically, the spaces are lined by flattened endothelium and surrounded by collagenous tissue and smooth muscle with collections of small lymphocytes. Which of the following is the most likely outcome associated with this child's lesion?

- **A** Distant metastases
- **B** Local recurrence
- **C** More neoplasms elsewhere
- **D** Opportunistic infection
- **E** Sarcomatous transformation

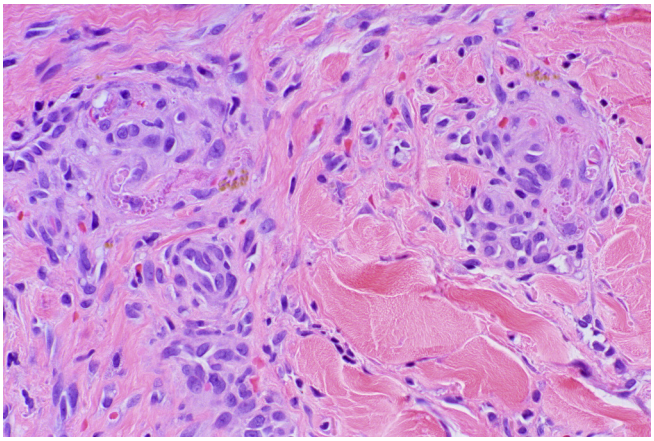

49 A 35-year-old man is known to have been HIV-positive for the past 10 years. Physical examination now shows multiple reddish purple, nodular skin lesions with the microscopic appearance shown in the figure. These lesions have been slowly increasing for the past year. Which of the following risk factors is most likely to play a role in the development of these skin lesions?

- **A** Antiretroviral therapy
- **B** Epstein-Barr virus infection
- **C** Hyperlipidemia
- **D** *Mycobacterium avium* complex infection
- **E** Sexual intercourse

50 A 67-year-old woman with glucose intolerance, hypertension, central obesity, and hyperlipidemia has increasing dyspnea from worsening congestive heart failure. Echocardiography shows a left ventricular ejection fraction of 25%. Percutaneous transluminal coronary angioplasty is performed with placement of a left anterior descending arterial stent containing paclitaxel. Which of the following long-term complications in her coronary artery is most likely to be prevented by paclitaxel?

- **A** Angiosarcoma
- **B** Bacillary angiomatosis
- **C** Cystic medial degeneration
- **D** Giant cell arteritis
- **E** Proliferative restenosis
- **F** Thromboangiitis obliterans

51 A 73-year-old woman with hyperhomocystinemia has noted poor circulation in her left leg for the past 2 years. On examination her dorsalis pedis and posterior tibial pulses are barely palpable. CT angiography shows 90% stenosis of the left iliac artery. Which of the following procedures would be most effective in treating this woman?

- **A** Arterial bypass graft
- **B** Clopidogrel therapy
- **C** Endovascular stent
- **D** Synthetic graft
- **E** Venous bypass graft

ANSWERS

1 E Veins have thin walls compared to their diameter, with less distinct layers, and slow blood flow. These characteristics make them more prone to compression and invasion by malignancies. This is a route for metastases via hematogenous spread. Of the remaining options, lymphatic invasion is an excellent choice, but the intracranial location chosen for this question excludes lymphatics, which are extracranial in the head. Neoplasms can elaborate growth factors to promote endothelial proliferation and capillary formation to form a stromal vascular supply for continued growth. Invasion of a muscular artery by a neoplasm is a rare event.

PBD9 483–485 BP9 328–329 PBD8 488–489 BP8 340–341

2 D Fibromuscular dysplasia (FMD) typically involves renal and carotid arteries. Renal arterial stenosis activates the renin-angiotensin system, leading to hypertension. On angiography, FMD appears as a "string of beads" caused by focal medial hyperplasia with thickened fibromuscular ridges adjacent to less involved areas of the arterial wall. This is a surgically correctible cause for hypertension. Arterial dissection is most likely to occur in the proximal aorta with risk factors of hypertension and cystic medial degeneration. Arteriovenous fistulas and berry aneurysms are likely to be intracranial and may rupture and bleed. Renal cell carcinomas may be highly vascular, but a focal mass effect is unlikely to obstruct the main renal artery, and does not account for the TIA. Hypertension could eventually drive atherosclerosis with arterial stenotic lesions lacking focal dilation.

PBD9 485 BP9 329–330 PBD8 490 BP8 341

3 A Activated endothelium can undergo many changes. In the acute situation of anaphylaxis, endothelial contraction within minutes leads to exudation of intravascular fluid into the extravascular compartment to produce edema, but this is also quickly reversible, because no permanent vascular injury has occurred. Free radical formation is more typical for endothelial dysfunction when stressors have acted for months to years, as is the case with atherogenesis. Endothelial injury from inflammation over days may lead to up-regulation of protein synthesis and release of regulators of thrombogenesis. Vascular injury may promote vascular endothelial growth factor (VEGF) formation, but in the basal state, procoagulants, anticoagulants, cytokines, and growth factors are elaborated at low levels and balance each other.

PBD9 486–487 BP9 329–330 PBD8 490–491 BP8 341–342

4 C Orthostatic hypotension is described. Diminished intravascular volume from fluid loss (sweating, urination, vomiting, diarrhea) or from decreased intake of fluids leads to dehydration. The other options listed cannot act quickly or forcefully enough to compensate for lack of intravascular fluid volume. Subtle changes in total body water and salt that play a role in essential hypertension are not reflected in altered electrolytes. Vomiting and diarrhea could alter acid-base status and electrolytes, but that is not the case here. Autoregulation by sympathetic tone and arteriolar vasoconstriction can adjust blood pressure and flow quickly, though the speed and magnitude of this response is diminished with aging. Adjustments in the synthesis and release of hormones such as renin and aldosterone take days.

PBD9 488–489 BP9 330–332 PBD8 493–494 BP8 355–356

5 F This is a classic example of a secondary form of hypertension for which a cause can be determined. In this case, the renal artery stenosis reduces glomerular blood flow and pressure in the afferent arteriole, resulting in renin release by juxtaglomerular cells. The renin initiates angiotensin II–induced vasoconstriction, increased peripheral vascular resistance, and increased aldosterone, which promotes sodium reabsorption in the kidney, resulting in increased blood volume. Anti–double-stranded DNA is a specific marker for systemic lupus erythematosus. Anti–neutrophil cytoplasmic autoantibodies (ANCAs) are markers for some forms of vasculitis, such as microscopic polyangiitis or ANCA-associated vasculitis. Some patients with hepatitis B or C infection can develop a mixed cryoglobulinemia with a polyclonal increase in IgG. Renal involvement in such patients is common, and cryoglobulinemic vasculitis then leads to skin hemorrhages and ulceration. Hyperglycemia is a marker for diabetes mellitus, which accelerates the atherogenic process and can involve the kidneys, usually bilaterally, promoting the development of hypertension. HIV infection is not related to hypertension.

PBD9 490–491 BP9 331–333 PBD8 495 BP8 355–356

6 A The term *essential hypertension* (now applied when there is no obvious cause for moderate hypertension) was coined before hormonal control of blood pressure was understood, because it was thought that the high pressure was essential to force blood through narrowed arteries. Essential hypertension has several postulated theories for its cause. One theory is that there are defects in renal sodium homeostasis that reduce renal sodium excretion. The kidney retains sodium with water, increasing intravascular fluid volume, which drives increased cardiac output. The increased cardiac output is compensated by increasing peripheral vascular resistance, causing an increase in blood pressure. If angiotensin-converting enzyme (ACE) was absent, blood pressure would decrease because angiotensin I would not be converted to angiotensin II (drugs that act as ACE inhibitors are antihypertensives). An elevated plasma renin level is typical of renovascular hypertension, which can occur with narrowing of a renal artery. Hypertensive patients with hypokalemia also can have hyperaldosteronemia, which can be caused by an aldosterone-secreting adrenal adenoma. Increased urinary catecholamines can indicate increased catecholamine output from a pheochromocytoma.

PBD9 487–490 BP9 331–333 PBD8 493–495 BP8 355–356

7 B The pulmonary vasculature is under much lower pressure than the systemic arterial circulation and is much less likely to have endothelial damage, which promotes

atherogenesis. Atherosclerosis in systemic arteries is most likely to occur where blood flow is more turbulent, a situation that occurs at arterial branch points, such as in the first few centimeters of the coronary arteries or in the abdominal aortic branches. Factors driving systemic arterial atherosclerosis (e.g., hyperlipidemias, smoking, diabetes mellitus, and systemic hypertension) do not operate in the pulmonary arterial vasculature. Pulmonary hypertension is the driving force behind pulmonary atherosclerosis, and it occurs as pulmonary vascular resistance increases, when the pulmonary vascular bed is decreased by either obstructive (e.g., emphysema, as in this patient) or restrictive (e.g., as in scleroderma with pulmonary interstitial fibrosis) diseases. Amyloid deposition usually occurs in small vessels and is driven by underlying conditions such as multiple myeloma or chronic inflammatory diseases. Intimal tears lead to arterial dissection. Mönckeberg arteriosclerosis is typically an incidental finding in systemic arterioles. Necrotizing vasculitis occurs in pulmonary vasculature in association with anti–neutrophil cytoplasmic autoantibody (ANCA)–associated granulomatous vasculitis. Phlebothrombosis occurs in peripheral veins and is a risk factor for pulmonary thromboembolism.

PBD9 491 BP9 332, 484–485 PBD8 512–513 BP8 346–347

8 F It is very difficult to keep dietary intake of sodium under 2 g per day because processed and packaged foods have considerable salt for both preservation and flavoring. Just 30 g of potato chips can have more than 150 mg of sodium. Even a single "healthy" can of soup may have half a gram of sodium! Reduced renal sodium excretion may initiate essential hypertension. Decreased sodium excretion may lead sequentially to an increase in fluid volume, increased cardiac output, and peripheral vasoconstriction, thereby elevating blood pressure. Increased salt intake potentiates hypertension. Although alcohol intake may reduce atherogenesis, there is increased risk for cardiomyopathy as well as liver disease. Reducing protein intake may help patients with chronic renal failure. The caffeine in coffee has neuroendocrine effects, but it is the milk and sugar added that may be most deleterious. Eggs have cholesterol. Milk is a good source of calcium, but comes with saturated fats and cholesterol, thus increasing the risk for atherogenesis. Sugar (sucrose and fructose), with high glycemic index, is most likely to drive weight gain.

PBD9 490 BP9 333 PBD8 493–495 BP8 354–356

9 E The figure shows an arteriole with marked hyaline thickening of the wall, indicative of hyaline arteriolosclerosis. Diabetes mellitus also can lead to this finding, which is most often seen in kidneys. Sepsis can produce disseminated intravascular coagulation with arteriolar hyaline thrombi. The debilitation that accompanies cancer tends to diminish the vascular disease caused by atherosclerosis. Syphilis can cause a vasculitis involving the vasa vasorum of the aorta. Polyarteritis can involve large to medium-sized arteries in many organs, including the kidneys; the affected vessels show fibrinoid necrosis and inflammation of the wall (vasculitis).

PBD9 490–491 BP9 333–334 PBD8 495 BP8 356–357

10 D Malignant hypertension can suddenly complicate and be superimposed on less severe, benign essential hypertension. The arterioles undergo concentric thickening and luminal narrowing with malignant hypertension, called hyperplastic arteriolosclerosis, and fibrinoid necrosis is a prominent feature. Fibromuscular dysplasia can involve the main renal arteries, with medial hyperplasia producing focal arterial obstruction. This process can lead to hypertension, but not typically malignant hypertension. A granulomatous arteritis is most characteristic of anti–neutrophil cytoplasmic autoantibody (ANCA)–associated granulomatous vasculitis, which often involves the kidney but typically involves lung and other organs. Hyaline arteriolosclerosis is seen with long-standing essential hypertension of moderate severity. These lesions give rise to benign nephrosclerosis. The affected kidneys become symmetrically shrunken and granular because of progressive loss of renal parenchyma and consequent fine scarring. Polyarteritis nodosa produces a vasculitis that can involve the kidney.

PBD9 487, 490 BP9 333–334 PBD8 496 BP8 355–356

11 A Older adults with radiographic evidence of calcified arteries often have Mönckeberg arteriosclerosis, beginning in the internal elastic lamina. This is a benign process that is a form of arteriosclerosis, often with no serious sequelae. The distal extremities, pelvis, thyroid, and breast regions are the most common locations. Such focal peripheral arterial calcification is far less likely to be a consequence of atherosclerosis, with diabetes mellitus or with hypercalcemia. Hypertension is most likely to affect small renal arteries, with hyaline or hyperplastic arteriolosclerosis, and calcification is not a major feature, although hypertension also is a risk factor for atherosclerosis.

PBD9 491 BP9 335 PBD8 496 BP8 343 AP3 Fig 1-18

12 D Think about a diet containing teleost fish, which contain oils that may be associated with lower cholesterol and therefore may be are protective against atherogenesis. The other listed options are associated with risk for atherosclerosis. C-reactive protein (CRP) is an acute phase reactant that increases in response to inflammatory cytokines, including those released from cells within atheromatous plaques. Hyperhomocysteinemia is a risk factor independent of lipids for atheroma formation. Lipoprotein(a) is a small LDL-like lipid particle that forms an insudate in arterial walls to drive atherogenesis. Trans fats chemically altered via hydrogenation make lipids last longer on the shelf and taste better, but are bad for you by increasing the ratio of LDL to HDL cholesterol.

PBD9 493 BP9 336–338 PBD8 497 BP8 345

13 B CRP is an acute phase reactant that increases in response to inflammation. It causes endothelial cell activation, promotes thrombosis, and increases leukocyte adhesiveness in developing atheromas. Because atherogenesis is partly an inflammatory process, CRP is an independent predictor of

cardiovascular risk. PR3 is one type of anti–neutrophil cytoplasmic autoantibody (ANCA) associated with some vasculitides such as microscopic polyangiitis. Cryoglobulins may be found with some forms of immune complex–mediated vasculitis. The ESR ("sed rate") is a nonspecific indicator of inflammation and therefore the internist's least favorite test; the ESR is best known to be markedly elevated with giant cell arteritis. Though platelets play a role in atheroma formation, the actual number of platelets is not a predictor of atherogenesis.

PBD9 493–494 BP9 337 PBD8 498 BP8 345

14 B Reduced cholesterol, particularly LDL cholesterol, with the same or increased HDL cholesterol level, indicates a reduced risk of atherosclerotic complications. Atherosclerosis is multifactorial, but modification of diet (i.e., reduction in total dietary fat and cholesterol) with increased exercise is the best method of reducing risk for most individuals. Atheromatous plaques that have formed can be reduced, albeit over months to years, but plaque regression yield an outcome better than drug or surgical therapy. Glucose is a measure of control of diabetes mellitus. Potassium, calcium, and renin values can be altered with some forms of hypertension, one of several risk factors for atherosclerosis.

PBD9 492–493 BP9 336–338 PBD8 500 BP8 345–346

15 B Diabetes mellitus, suggested here by hyperglycemia, is a significant risk factor for early, accelerated, and advanced atherosclerosis. If a premenopausal woman or a young man has severe coronary atherosclerosis, diabetes mellitus or other metabolic disease such as hyperlipidemia must be suspected as a predisposing factor. "Soft" risk factors that can play a lesser role in the development of atherosclerosis include obesity, stress, and lack of exercise.

PBD9 493–494 BP9 336–338 PBD8 497–498 BP8 343, 345

16 D Oxidized LDL can be taken up by a special "scavenger" pathway in macrophages; it also promotes monocyte chemotaxis and adherence. Macrophages taking up the lipid become foam cells that begin to form the fatty streak. Smoking, diabetes mellitus, and hypertension all promote free radical formation, and free radicals increase degradation of LDL to its oxidized form. About one third of LDL is degraded to the oxidized form; a higher LDL level increases the amount of oxidized LDL available for uptake into macrophages. C-reactive protein is a marker for inflammation, which can increase with more active atheroma and thrombus formation and predicts a greater likelihood of acute coronary syndromes. Increased homocysteine levels promote atherogenesis through endothelial dysfunction. Lp(a), an altered form of LDL that contains the apo B-100 portion of LDL linked to apo A, promotes lipid accumulation and smooth muscle cell proliferation. Platelet-derived growth factor promotes smooth muscle cell proliferation. VLDL is formed in the liver and transformed in adipose tissue and muscle to LDL.

PBD9 496–497 BP9 338–340 PBD8 499–500 BP8 348–349

17 B Lipoprotein(a) is an altered form of LDL cholesterol that has the apolipoprotein B-100 portion of LDL linked to apolipoprotein A, and an increase in Lp(a) is independently associated with a risk for endothelial dysfunction and atherogenesis. Apolipoprotein E promotes metabolism and clearance of LDL. Drugs such as statins that affect LDL receptor activity do not affect Lp(a) concentration. Early in the course of atheroma formation, angiotensin and its receptor may play a role in development of hypertension, which then becomes a risk factor for atherosclerosis. Endothelin is a vasoconstrictor with no known role in atherogenesis. Decreased factor VIII leads to abnormal bleeding. Von Willebrand factor is required for normal platelet adhesion to collagen, and its absence leads to abnormal bleeding.

BPD9 494–496 BP9 338–339 PBD8 497–498 BP8 345–347

18 B The initial response of an arterial wall to injury is intimal thickening with neointimal smooth muscle cell proliferation and production of increased intimal extracellular matrix. Note that "injury" can be caused by inflammation, immune reactions, and toxins as well as the local physical trauma from hypertension and abnormal flow. The trauma does not produce immediate injury with endothelial cellular disruption, but a response of endothelial dysfunction that signals smooth muscle cell migration. This process takes years to show changes of vascular narrowing. As atheromatous plaques progress, there is participation by lymphocytes producing cytokines, as well as monocytes that are transformed to macrophages that accumulate lipid to evolve into foam cells. Eventually plaque disruption may incite platelet aggregation.

PBD9 494–496 BP9 334–335 BPD8 499 BP8 342

19 C Atherosclerosis is thought to result from an initial endothelial injury and the subsequent chronic inflammation and repair of the arterial intima. All risk factors, including smoking, hyperlipidemia, and hypertension, cause biochemical or mechanical injury to the endothelium with resulting dysfunction that initiates smooth muscle migration with proliferation, as well as lymphocyte and monocyte-macrophage infiltration. Formation of foam cells occurs after the initial endothelial injury. Vasomotor tone does not play a major role in atherogenesis. Inhibition of LDL oxidation should diminish atheroma formation. Although lipoprotein receptor alterations can occur in some inherited conditions, these account for only a fraction of cases of atherosclerosis, and other lifestyle conditions do not affect their action.

PBD9 494–496 BP9 335–340 PBD8 499 BP8 342, 346–348

20 D The slightly raised, pale lesions shown in the figure are called *fatty streaks* and are seen in the aorta of almost all children older than 10 years. They are thought to be precursors of atheromatous plaques. T cells are present early in the pathogenesis of atherosclerotic lesions and are believed to activate monocytes, endothelial cells, and smooth muscle cells by secreting cytokines. T cells adhere to VCAM-1 on activated endothelial cells and migrate into the vessel wall. These T cells, activated by some unknown mechanism, secrete

various proinflammatory molecules that recruit and activate monocytes and smooth muscle cells and perpetuate chronic inflammation of the vessel wall. Fatty streaks cause no disturbances in blood flow and are discovered incidentally at autopsy. All of the other lesions described are seen in fully developed atheromatous plaques. The histologic features of such plaques include a central core of lipid debris that can have cholesterol clefts and can be calcified. There is usually an overlying cap of smooth muscle cells. Hemorrhage is a complication seen in advanced atherosclerosis. Foam cells, derived from smooth muscle cells or macrophages that have ingested lipid, can be present in all phases of atherogenesis.

PBD9 496–497 BP9 340–341 PBD8 502 BP8 346–350

21 D Growth factor release from activated platelets, macrophages, and vascular wall cells induces smooth muscle cell recruitment, medial smooth muscle migrate into the intima, proliferate, and synthesize extracellular matrix (ECM) in much the same way that fibroblasts fill in a wound. Endothelial cell injury initiates atherogenesis, but endothelial cells do not form a significant part of an atheroma. Platelets do not synthesize ECM. T cells secrete inflammatory cytokines that activate macrophages, endothelial cells, and smooth muscle cells.

PBD9 496–498 BP9 338–340 PBD8 499–501 BP8 348–349

22 B The figure shows an arterial lumen that is markedly narrowed by atheromatous plaque complicated by calcification. Hypercholesterolemia with elevated LDL and decreased HDL levels is a key risk factor for atherogenesis. Although platelets participate in forming atheromatous plaques, their number is not of major importance. Thrombocytosis can result in thrombosis or hemorrhage. Levels of Lp(a) and homocysteine, if elevated, increase the risk of atherosclerosis. Syphilis (positive VDRL test result) produces endarteritis obliterans of the aortic vasa vasorum, which weakens the wall and predisposes to aortic aneurysm formation.

PBD9 499–501 BP9 341–343 PBD8 503–504 BP8 350–352

23 D Atheromatous plaques can be complicated by various pathologic alterations, including hemorrhage, ulceration, thrombosis, and calcification. These processes can increase the size of the plaque and narrow the residual arterial lumen. Although atherosclerosis is a disease of the intima, in advanced disease, the expanding plaque compresses the media. This causes thinning of the media, which weakens the wall and predisposes it to aneurysm formation.

PBD9 498–501 BP9 342–343 PBD8 503–504 BP8 348–351

24 B Aspirin (acetylsalicylic acid) inhibits the cyclooxygenase pathway of arachidonic acid metabolism and inhibits platelets that participate in thrombogenesis. When atheromatous plaques have progressed to the point of symptomatic occlusion and subsequent angina, they are likely to be unstable plaques that may rupture, ulcerate, or erode to promote thrombosis. A "baby" aspirin containing 80 mg (325 mg in the "adult" tablet) taken once a day may reduce this thrombotic risk, and also prevent the significantly increased risk for hemorrhage that is associated with higher doses. Acetaminophen is primarily analgesic in action. Ibuprofen is a nonsteroidal anti-inflammatory drug (NSAID) that has no significant effect upon atheroma progression. Paclitaxel is one type of drug (initially used as an anticancer agent) used in drug-eluting stents placed in coronary arteries following angioplasty to deter restenosis. Propranolol is a beta-blocker that is employed as an antihypertensive agent.

PBD9 BP9 342–343 PBD8 498–499 BP8 347–348

25 C Abdominal aneurysms are most often related to underlying aortic atherosclerosis. This patient has multiple risk factors for atherosclerosis, including diabetes mellitus, hypertension, and smoking. When the aneurysm reaches this size, there is a significant risk of rupture. An aortic dissection is typically a sudden, life-threatening event with dissection of blood out of the ascending aortic lumen, typically into the chest, without a pulsatile abdominal mass. The risk factors for atherosclerosis and hypertension also underlie aortic dissection. An arteriovenous fistula can produce an audible bruit on auscultation. Classic polyarteritis nodosa (PAN) can produce small microaneurysms in small arteries, most often renal and mesenteric. Takayasu arteritis typically involves the aortic arch and branches in children. Thromboangiitis obliterans (Buerger disease) is a rare condition in which muscular arteries become occluded in the lower extremities in smokers.

PBD9 501–503 BP9 344–346 PBD8 707 BP8 357–359

26 A His abdominal CT scan shows a 6-cm diameter enlargement of the abdominal aorta, which is an atherosclerotic abdominal aortic aneurysm. Diabetes mellitus, an important risk factor for atherosclerosis, must be suspected if a younger man or premenopausal woman has severe atherosclerosis. Marfan syndrome is a risk for aortic dissection starting in a dilated ascending aorta. Polyarteritis nodosa does not typically involve the aorta. Obesity, a "soft" risk factor for atherosclerosis, also contributes to type 2 diabetes mellitus; however, the extent of atherosclerotic disease in this patient suggests early-onset diabetes mellitus, which is more likely to be type 1. Systemic lupus erythematosus produces small arteriolar vasculitis. Syphilitic aortitis, a feature of tertiary syphilis, most often involves the thoracic aorta, but it is rare, and most thoracic aortic aneurysms nowadays are likely to be caused by atherosclerosis.

PBD9 498, 502–503 BP9 344–346 PBD8 507–508 BP8 358–359

27 A This description is most suggestive of syphilitic aortitis, a complication of tertiary syphilis, with characteristic involvement of the thoracic aorta. The history also suggests tabes dorsalis and neurosyphilis. Obliterative endarteritis is not a feature of other forms of vasculitis. High-titer double-stranded DNA antibodies are diagnostic of systemic lupus erythematosus, and the test result for P-ANCA (antibodies mainly directed at myeloperoxidase) is positive in various vasculitides, including microscopic polyangiitis. Ketonuria can occur in individuals with diabetic ketoacidosis. A high sedimentation rate is a nonspecific marker of inflammatory diseases.

PBD9 502, 504 BP9 345–346 PBD8 507–508 BP8 359–360

28 C The figure shows disruption of the medial elastic fibers, typical for cystic medial degeneration, which weakens the aortic media and predisposes to aortic dissection. In a young patient a heritable disorder of connective tissues, such as Marfan syndrome, must be strongly suspected. Scleroderma and anti–neutrophil cytoplasmic autoantibody (ANCA)–associated vasculitis (granulomatosis with polyangiitis) do not typically involve the aorta. Atherosclerosis associated with diabetes mellitus and hypertension are risk factors for aortic dissection, although these are more often seen at an older age. Takayasu arteritis is seen mainly in children and involves the aorta (particularly the arch) and branches such as the coronary and renal arteries, causing granulomatous inflammation, aneurysm formation, and dissection.

PBD9 502, 504 BP9 346–348 PBD8 507 BP8 357, 361

29 C A sudden tear in the proximal aortic intima allows blood to enter the space between layers within the wall of the aorta. This blood may pass through the aortic wall, around great vessels, and into the pericardial cavity, as in this case with cardiac tamponade. Blood may enter the chest cavity, causing hemothorax. Hypertension is the most common risk factor for aortic dissection. In contrast, a false aneurysm is characterized by formation of a hematoma by extravasated blood, but it communicates with the vascular lumen; a true aneurysm includes all three layers of the arterial wall. Arteriolosclerosis can be associated with hypertension, but it involves arterioles, typically in kidneys, not the aorta. Thrombosis of extravasated blood from a dissection can occur, but this is not the primary lesion. Vasculitis does not often involve the aorta, but giant cell arteritis and Takayasu arteritis may do so, although they are unlikely to weaken the wall to the point of rupture.

PBD9 504–505 BP9 346–348 PBD8 506, 509 BP8 358, 360

30 A Giant cell (temporal) arteritis typically involves large to medium-sized external carotid artery branches in the head (especially temporal arteries), but also vertebral and ophthalmic arteries. Involvement of the latter can affect vision. Because involvement of the kidney, lung, and peripheral arteries of the extremities is much less common, renal failure, hemoptysis, and gangrene of toes are unusual complications of giant cell arteritis. There is no association between hypertension and giant cell arteritis, but some patients may have polymyalgia rheumatica.

PBD9 507–508 BP9 350–351 PBD8 512–513 BP8 363–364

31 E Takayasu arteritis leads to "pulseless disease," because of involvement of the aorta (particularly the arch) and branches such as coronary, carotid, and renal arteries, which results in granulomatous inflammation, aneurysm formation, and dissection. Fibrosis is a late finding, and the pulmonary arteries also can be involved. Aortic dissection is an acute problem that, in older adults, is driven by atherosclerosis and hypertension, although this patient is within the age range for complications of Marfan syndrome, which causes cystic medial degeneration of the aorta. Kawasaki disease affects children and is characterized by an acute febrile illness, coronary arteritis with aneurysm formation and thrombosis, skin rash, and lymphadenopathy. Microscopic polyangiitis affects arterioles, capillaries, and venules with a leukocytoclastic vasculitis that appears at a similar stage in multiple organ sites (in contrast to classic polyarteritis nodosa, which causes varying stages of acute, chronic, and fibrosing lesions in small to medium-sized arteries). Tertiary syphilis produces an endaortitis with proximal aortic dilation. Thromboangiitis obliterans (Buerger disease) affects small to medium-sized arteries of the extremities and is strongly associated with smoking.

PBD9 508–509 BP9 351 PBD8 513–514 BP8 364–365

32 D Classic polyarteritis nodosa (PAN) has segmental involvement of medium-sized arteries with aneurysmal dilation in the renal and mesenteric vascular beds (e.g., abdominal pain, melena). PAN can affect many organs at different times. Although the cause of PAN is unknown, about 30% of patients have hepatitis B surface antigen that presumably forms immune complexes that damage vascular walls. In contrast to microscopic polyangiitis, PAN has less of an association with anti–neutrophil cytoplasmic autoantibody (ANCA). A collagen vascular disease with a positive ANA test result, such as systemic lupus erythematosus, may produce a vasculitis, but not in the pattern seen here; the affected vessels are smaller. Vasculitis with HIV infection is uncommon. The Scl-70 autoantibody is indicative of scleroderma, which can produce renal failure. The rapid plasma reagin (RPR) is a serologic test for syphilis; an endaortitis of the vasa vasorum can occur in syphilis.

PBD9 509–510 BP9 352 PBD8 514–515 BP8 363, 365–366

33 D Mucocutaneous lymph node syndrome, or Kawasaki disease, involves large, medium-sized, and small arteries. Cardiovascular complications occur in 20% of cases and include thrombosis, ectasia, and aneurysm formation of coronary arteries. Asthma can be seen in association with Churg-Strauss vasculitis. Glomerulonephritis is a feature of anti–neutrophil cytoplasmic autoantibody (ANCA)–associated granulomatous vasculitis and of some autoimmune diseases such as systemic lupus erythematosus. Intracranial hemorrhage can occur with septic emboli to peripheral cerebral arteries, producing mycotic aneurysms that can rupture. Pulmonary hypertension can also complicate Takayasu arteritis, but is not as life-threatening as the coronary artery disease.

PBD9 510 BP9 352 PBD8 515 BP8 363, 366

34 A Anti–neutrophil cytoplasmic autoantibody (ANCA)–associated vasculitis (granulomatosis with polyangiitis) is a form of hypersensitivity reaction to an unknown antigen characterized by necrotizing granulomatous inflammation that typically involves small to medium-sized vessels, although many organ sites may be affected. Pulmonary and renal involvement can be life-threatening. C-ANCAs (antibodies mainly directed against neutrophil proteinase 3) are found in more than 90% of cases. Fibromuscular dysplasia is a hyperplastic medial disorder, usually involving renal and carotid arteries; on angiography, it appears as a "string of beads" caused by thickened

fibromuscular ridges adjacent to less involved areas of the arterial wall. Granuloma pyogenicum is an inflammatory response that can produce a nodular mass, often on the gingiva or the skin. Kaposi sarcoma can produce plaquelike to nodular masses that are composed of irregular vascular spaces lined by atypical-appearing endothelial cells; skin involvement is most common, but visceral organ involvement can occur. Polyarteritis nodosa most often involves small muscular arteries, and sometimes veins. It causes necrosis and microaneurysm formation followed by scarring and vascular occlusion, mainly in the kidney, gastrointestinal tract, and skin of young to middle-aged adults. Takayasu arteritis is seen mainly in children and involves the aorta (particularly the arch) and branches such as the coronary and renal arteries, with granulomatous inflammation, aneurysm formation, and dissection.

PBD9 511–512 BP9 353–354 PBD8 516–517 BP8 363, 367–368

35 B Microscopic polyangiitis involves small vessels, typically capillaries. Kidneys and lungs are commonly involved, but many organs can be affected. There may be an underlying immune disease, chronic infection, or drug reaction. Giant cell arteritis typically involves arterial branches of the external carotid, most often the temporal artery. Microabscesses may be present with an infectious process, or with thromboangiitis obliterans (Buerger disease), which typically involves lower extremities. Mycotic aneurysms occur when a focus of infection, often from a septic embolus, weakens an arterial wall so that it bulges out. Perivascular eosinophilic infiltrates may be seen with Churg-Strauss syndrome, which typically involves the lungs.

PBD9 510–511 BP9 353 PBD8 515-516 BP8 366-367

36 E Thromboangiitis obliterans (Buerger disease), which affects small to medium-sized arteries of the extremities, is strongly associated with smoking. This disease may eventually involve adjacent peripheral veins and nerves. Syphilis can be treated with antibiotics, but it mainly produces an aortitis. Immunosuppressive therapy is not highly effective. Renal involvement does not occur. Although peripheral vascular disease with atherosclerosis is a typical finding in diabetes mellitus, vasculitis is not.

PBD9 512 BP9 354 PBD8 517 BP8 368

37 B In children, Henoch-Schönlein purpura is the multisystemic counterpart of the IgA nephropathy seen in adults. The immune complexes formed with IgA produce the vasculitis that affects mainly arterioles, capillaries, and venules in skin, gastrointestinal tract, and kidney. In older adults, giant cell arteritis is seen in external carotid branches, principally the temporal artery unilaterally. Polyarteritis nodosa is seen most often in small muscular arteries and sometimes veins, with necrosis and microaneurysm formation followed by scarring and vascular occlusion. This occurs mainly in the kidney, gastrointestinal tract, and skin of young to middle-aged adults. Takayasu arteritis is seen mainly in children and involves the aorta (particularly the arch) and branches such as coronary and renal arteries, with granulomatous inflammation, aneurysm formation, and dissection. Telangiectasias are small vascular arborizations seen on skin or mucosal surfaces.

PBD9 512–513 BP9 349 PBD8 512, 517 BP8 366

38 D Infectious endocarditis is likely present in this woman, and portions of the vegetations often dislodge and embolize. These are septic emboli carrying organisms that can start growing and produce local arterial destruction wherever they are carried. The destruction of a vascular wall by an infectious process is uncommon, but can result from spread of local infection or via embolization. A so-called mycotic aneurysm can be due to any infectious agent that weakens an arterial wall so that it bulges out—an aneurysmal dilation. Bacillary angiomatosis produces a focal vascular proliferation, typically on the skin, of an immunocompromised person infected with *Bartonella* spp. Hyperplastic arteriolosclerosis is most often found in the kidneys of persons with malignant hypertension, some of whom may have underlying systemic sclerosis. Lymphatic channels are not found within the brain. Phlebothrombosis is typically found in large veins of the legs and pelvis, most often following prolonged immobilization.

PBD9 502, 513 BP9 345, 355 PBD8 517 BP8 357, 369

39 E The "red, white, and blue" changes shown represent Raynaud phenomenon, which can be a primary exaggerated vasoconstriction without an underlying disease. In older persons, an underlying disease, such as an autoimmune disease, should be sought. Hyperviscosity may underlie this phenomenon. In younger persons it is "primary" and likely vasomotor hyperreactivity. Calcification with medial calcific sclerosis tends to involve arteries that are small and muscular, but larger than those of hands or feet; it is often an incidental finding on a radiograph. Hypertension may drive atherosclerosis, but not marked vasoconstriction. Thrombosis is unlikely to develop and subside so quickly. Vasculitis likewise is not an evanescent phenomenon.

PBD9 513 BP9 355 PBD8 518 BP8 369–370

40 C The hemorrhoidal veins can become dilated from venous congestion. They are derived from ectoderm, covered by squamous epithelium, and innervated by somatic sensory nerves. External hemorrhoids are most common in patients with chronic constipation, but a pregnant uterus presses on pelvic veins to produce similar congestion, which promotes hemorrhoidal vein dilation. Filarial infections can affect lymphatics, including those in the inguinal region, and produce lymphedema. Polyarteritis does not affect veins. Portal hypertension with cirrhosis is most likely to dilate submucosal esophageal veins, but internal hemorrhoidal veins occasionally can be affected. Cirrhosis would be rare at this patient's age. Carcinomas are also uncommon at this age, and they are not likely to obstruct venous flow.

PBD9 514 BP9 356 PBD8 518–519 BP8 370

41 D Phlebothrombosis (but most often called thrombophlebitis) is a common problem that results from venous

stasis with prolonged immobilization. Phlebothrombosis may be a better (but less often used) term because there is little or no inflammation, but the former term is well established. Disseminated intravascular coagulation more often results in hemorrhage, and edema is not the most prominent manifestation. Lymphedema takes longer than 2 weeks to develop and is not caused by bed rest alone. Thromboangiitis obliterans is a rare form of arteritis that results in pain and ulceration of extremities. Varicose veins are dilated, tortuous superficial veins and can thrombose, but they are not related to bed rest, and they do not predispose to pulmonary thromboembolism, as does thrombosis of deeper, larger veins.

PBD9 514–515 BP9 356 PBD8 519 BP8 370–371

42 E Chronic peripheral venous stasis results in hemosiderin deposition and dermal fibrosis with brownish discoloration and skin roughening. Focal ulceration can occur over the varicosities, but extensive gangrene similar to that seen in arterial atherosclerosis does not occur. Hippocrates described varicosities circa 370 BCE and recommended compression for ulceration. In 1896 Australian surgeon Jerry Moore described ligation of the great saphenous vein, a procedure still in use. The varicosities involve only the superficial set of veins, which can thrombose, but they are not the source of thromboemboli, as are the larger, deep leg veins. The varicosities do not affect muscle; however, diminished muscular support for veins to "squeeze" blood out for venous return can predispose to formation of varicose veins. The thromboses in superficial leg veins do not lead to disseminated intravascular coagulation, because there is no acute vascular injury to promote ongoing coagulopathy. Venous infarction is uncommon, because of collateral deep and superficial veins for venous return.

PBD9 514 BP9 356 PBD8 518–519 BP8 370

43 A A mastectomy with axillary lymph node dissection leads to disruption and obstruction of lymphatics in the axilla. Such obstruction to lymph flow gives rise to lymphedema, a condition that can be complicated by cellulitis. Arterial thrombosis produces ischemia distal to the obstruction. Thrombophlebitis from venous stasis is a complication seen more commonly in the lower extremities. An arterial thrombosis can lead to a cold, blue, painful extremity. Tumor emboli are generally small but uncommon. Vasculitis is not a surgical complication.

PBD9 515 BP9 357 PBD8 519–520 BP8 371

44 B The red streaks represent lymphatic channels through which the acute infection is draining to axillary lymph nodes, and these nodes drain to the right lymphatic duct and into the right subclavian vein (lymphatics from the lower body and left upper body drain to the thoracic duct). Capillaritis is most likely to be described with inflammation involving the lungs. Lymphedema occurs with blockage of lymphatic drainage and develops over a longer period without significant acute inflammation. Phlebothrombosis and thrombophlebitis describe thrombosis in veins with stasis and minimal inflammation, typically in the pelvis and lower extremities. Classic polyarteritis nodosa (PAN) involves small to medium-sized muscular arteries, typically the renal and mesenteric branches. Varices are veins dilated from obstruction to venous drainage.

PBD9 515 BP9 357 PBD8 519 BP8 371

45 E Spider telangiectasias are a feature of micronodular cirrhosis, typically as a consequence of chronic alcohol abuse. They are thought to be caused by hyperestrogenism (estrogen excess) that results from hepatic damage with reduced clearance of circulating steroids. The most common vascular skin lesion in patients with AIDS is Kaposi sarcoma, which is a neoplasm that manifests as one or more irregular, red-to-purple patches, plaques, or nodules. Diabetes mellitus, with its accelerated atherosclerosis, is most likely to result in ischemia or gangrene. Vasculitis does not tend to produce skin telangiectasias. The vascular involvement in Marfan syndrome is primarily in the aortic arch with cystic medial degeneration.

PBD9 515–516 BP9 357–358 PBD8 522 BP8 374

46 B A so-called pyogenic granuloma is described. Half of them are related to trauma and represent an exuberant repair reaction with granulation tissue. They can ulcerate and bleed. Bacillary angiomatosis represents a vascular proliferation that occurs in immunocompromised patients infected with *Bartonella* organisms. Cavernous lymphangiomas can be deforming mass lesions in the neck region of children, and though technically benign they do not have well-defined borders and can be difficult to excise. A glomus tumor typically presents as a painful nodule beneath the fingernail. There are various forms of Kaposi sarcoma (classic, endemic, AIDS-related) but they all appear as reddish purple patches, plaques, or nodules on the skin and are associated with Kaposi sarcoma herpes virus (KSHV), also called *human herpesvirus 8 (HHV8).*

PBD9 516 BP9 358–359 PBD8 521 BP8 373

47 B The figure shows dilated, endothelium-lined spaces filled with RBCs. The circumscribed nature of this lesion and its long, unchanged course suggest its benign nature. The vascular spaces of a hemangioma may be small, resembling capillaries, or large and cavernous. Angiosarcomas are large, rapidly growing malignancies in adults. Kaposi sarcoma is uncommon in its endemic form in childhood, and it is best known as a neoplastic complication associated with HIV infection. Lymphangiomas, seen most often in children, tend to be more diffuse and are not blood-filled. A telangiectasia is a radial array of subcutaneous dilated arteries or arterioles surrounding a central core that can pulsate.

PBD9 516–517 BP9 358–359 PBD8 523–524 521–522
BP8 372–373

48 B The lesion is a cavernous lymphangioma. Although histologically benign, such lesions have a tendency to become large and extend around adjacent structures, complicating removal. Lymphangiomas are unlikely to be associated with syndromes involving multiple neoplasms, and

there is no association with infections. The cystic hygroma of Turner syndrome has a similar appearance, but is bilateral, nonprogressive, and may account for the "web neck" appearance.

PBD9 517 BP9 358–359 PBD8 522 BP8 373

49 E Infection by HHV8, also called *Kaposi sarcoma herpes virus (KSHV)*, is associated with Kaposi sarcoma (KS) and can be acquired as a sexually transmitted disease. KS is a complication of AIDS. Individuals with HIV infection can be infected with various viruses, including cytomegalovirus (CMV) and Epstein-Barr virus (EBV), but these viruses have no etiologic association with KS. EBV is a factor in the development of non-Hodgkin lymphoma, and CMV can cause pneumonitis or retinitis, or it can be disseminated. Hyperlipidemia may complicate antiretroviral therapy, but does not produce skin nodules. MAC infection can be seen in HIV-infected patients as well, but it produces small granulomas, mainly in tissues of the mononuclear phagocyte system.

PBD9 518–519 BP9 360–361 PBD8 523–524 BP8 375–376

50 E She has metabolic syndrome, a risk for coronary atherosclerosis. Following angioplasty, there is often intimal thickening that causes restenosis. The wire stent holds the lumen open and the paclitaxel limits smooth muscle hyperplasia. Atherosclerosis is not a risk factor for neoplasia. Bacillary angiomatosis is caused by *Bartonella* organisms (cat-scratch disease) and most often produces a red skin nodule. Cystic medial degeneration is a feature of Marfan syndrome with aortic dissection. Giant cell arteritis most often involves external carotid branches such as temporal arteries; it is not related to atherosclerosis. Thromboangiitis obliterans is a rare form of vasculitis involving lower extremities in smokers.

PBD9 520–521 BP9 338, 362 PBD8 528 BP8 378

51 C Endovascular stent placement can be done without major surgery, because the graft can be deployed percutaneously. Arterial bypass grafting is most often used from left internal mammary (thoracic) artery to left anterior descending coronary artery, or by harvesting a portion of radial artery to bypass a stenotic coronary artery. Clopidogrel is an antiplatelet agent to help prevent thrombosis, and patients with such a risk, including severe atherosclerosis or those with stent or graft placement, may receive such a drug. Endovascular stents have largely replaced synthetic grafts, which need major surgery for placement. Saphenous vein bypass grafts are often used for coronary artery bypass grafting. All of these grafts may be complicated by thrombosis, restenosis, or both.

PBD9 520–521 BP9 362–363 PBD8 526 BP8 377–378