Pulse DIAGNOSTICS™

Neuberg Pulse DIAGNOSTICS

LABORATORY REPORT

Name : **Mr SARANIK DEY**	Sex/Age : **Male / 36 Years**	Case ID : **60135208461**	
Reg Date : 24-Jan-2026 12:44		Pt. ID : 7660732	
Bill. Loc. : Neuberg Pulse Lansdowne		Mob.No : 9038432001	
Ref. By : Dr. Debabrata De MBBS (Cal)			
Sample Date and Time : 24-Jan-2026 12:47	Sample Type : Whole Blood EDTA	Ref Id1 :	
Report Date and Time : 24-Jan-2026 15:02		Ref Id2 :	

TEST		RESULTS	UNIT	BIOLOGICAL REF RANGE	REMARKS
Haemoglobin		14.7	gm/dL	13 - 17	
Remark					
*Biological Reference Values Updated as per Dacie & Lewis 12th Edition.					
RBC		5.30	millions/cumm	4.5 - 5.5	
PCV		46.7	Vol%	40.0 - 50.0	
Remark					
*Biological Reference Values Updated as per Dacie & Lewis 12th Edition					
MCV		88.1	fL	83 - 101	
MCH		27.7	pg	27 - 32	
MCHC		31.5	gm/dL	31.5 - 34.5	
RDW		13.0	%	11.6 - 14.6	
TOTAL AND DIFFERENTIAL WBC COUNT					
Total WBC Count	H	**10800**	/µL	4000 to 10000	
Neutrophil		60	%	40 - 80	
Lymphocyte		35	%	20 - 40	
Monocytes		03	%	2 - 10	
Eosinophil		02	%	1 - 6	
Basophil		00	%	0 - 1	
Neutrophil Absolute		6480	/µL	2000 - 7000	
Lymphocyte Absolute	H	**3780**	/µL	1000 - 3000	
Eosinophil Absolute		216	/µL	20 - 500	
Monocyte Absolute		324	/µL	200 - 1000	
Basophil Absolute		0	/µL	00 - 100	
Neut/Lympho Ratio (NLR)		1.71		0.78 - 3.53	

Note:(LL-VeryLow,L-Low,H-High,HH-VeryHigh,A-Abnormal)

AUTO

Verified by

Supratik Biswas

Dr. Supratik Biswas
MBBS, MD
Consultant Biochemist
WBMC 64600

Dr. Nabanita Banerjee
MBBS (Cal), DNB (I), MIAPM, MIAC, Pathologist

MC - 2167

LABORATORY REPORT

Name	: **Mr SARANIK DEY**	Sex/Age	: **Male / 36 Years**	Case ID	: **60135208461**
Reg Date	: 24-Jan-2026 12:44			Pt. ID	: 7660732
Bill. Loc.	: Neuberg Pulse Lansdowne			Mob.No	: 9038432001
Ref. By	: Dr. Debabrata De MBBS (Cal)				

Sample Date and Time	: 24-Jan-2026 12:47	Sample Type	: Whole Blood EDTA	Ref Id1	:
Report Date and Time	: 24-Jan-2026 15:02			Ref Id2	:

PLATELETS

Platelet Count	407000	/µL	1,50,000 - 4,10,000
MPV	9.5	fL	7.50 - 12.0
PDW	10.0		10.0 - 17.9
ESR	6	mm	0 - 10

Method : Modified Westergren Method
Instrument - Automated Vescube - 30 touch

Note : *XN 1000, Sysmex : **Method :** FLOWCYTOMETRY*

Note:(LL-VeryLow,L-Low,H-High,HH-VeryHigh,A-Abnormal)

AUTO

Verified by

Supratik Biswas

Dr. Supratik Biswas
MBBS, MD
Consultant Biochemist
WBMC 64600

Banerjee

Dr. Nabanita Banerjee
MBBS (Cal), DNB (I),
MIAPM, MIAC,
Pathologist

MC - 2167

Pulse DIAGNOSTICS™

Neuberg Pulse DIAGNOSTICS

LABORATORY REPORT

Name : **Mr SARANIK DEY**	Sex/Age : **Male / 36 Years**	Case ID : **60135208461**	
Reg Date : 24-Jan-2026 12:44		Pt. ID : 7660732	
Bill. Loc. : Neuberg Pulse Lansdowne		Mob.No : 9038432001	
Ref. By : Dr. Debabrata De MBBS (Cal)			
Sample Date and Time : 24-Jan-2026 12:47	Sample Type : Plasma Fluoride F,Serum	Ref Id1 :	
Report Date and Time : 24-Jan-2026 16:08		Ref Id2 :	

TEST	RESULTS	UNIT	BIOLOGICAL REF RANGE	REMARKS
Plasma Glucose - F *Hexokinase*	86	mg/dL	70 - 99 : Non diabetic 100 - 125 : Pre diabetic >= 126 : Diabetic	
Creatinine *Jaffe - Kinetic*	0.87	mg/dL	<1.2	

Note:(LL-VeryLow,L-Low,H-High,HH-VeryHigh,A-Abnormal)

Pintu Manna

Verified by

Dr. Krishti Chatterjee

MBBS, MD (Pathology),
Consultant Pathologist
WBMC 69911

MC - 2167

LABORATORY REPORT

Name	: **Mr SARANIK DEY**	Sex/Age	: **Male / 36 Years**	Case ID	: **60135208461**
Reg Date	: 24-Jan-2026 12:44			Pt. ID	: 7660732
Bill. Loc.	: Neuberg Pulse Lansdowne			Mob.No	: 9038432001
Ref. By	: Dr. Debabrata De MBBS (Cal)				
Sample Date and Time	: 24-Jan-2026 12:47	Sample Type	: Whole Blood EDTA	Ref Id1	:
Report Date and Time	: 24-Jan-2026 16:08			Ref Id2	:

TEST	RESULTS	UNIT	BIOLOGICAL REF RANGE	REMARKS
HbA1c *HPLC*	5.70	%	Normal : <5.7 Pre diabetes : 5.7-6.4 Diabetes : >6.5	
Average Plasma Glucose *Calculated*	117	mg/dL		

Interpretation :

HbA1C level reflects the mean glucose concentration over previous 8-12 weeks and provides better indication of long term glycemic control.

Levels of HbA1C may be low as result of shortened RBC life span in case of hemolytic anemia.

Increased HbA1C values may be found in patients with polycythemia or post splenectomy patients.

Patients with Homozygous forms of rare variant Hb(CC,SS,EE,SC) HbA1c can not be quantitated as there is no HbA.

In such circumstances glycemic control can be monitored using plasma glucose levels or serum Fructosamine.

The A1c target should be individualized based on numerous factors, such as age, life expectancy,comorbid conditions, duration of diabetes, risk of hypoglycemia or adverse consequences from hypoglycemia, patient motivation and adherence.

Note:(LL-VeryLow,L-Low,H-High,HH-VeryHigh,A-Abnormal)

Debolina Bhadra

Verified by

Dr. Krishti Chatterjee

MBBS, MD (Pathology),
Consultant Pathologist
WBMC 69911

MC - 2167

Chromatogram Report

TOSOH G8 VAR V05.29 490206 2026-01-24 15:32:13

ID 260135208461
Sample No. 01240118 SL 0005 - 01
Patient ID
Name
Comment

CALIB Y =1.1675X + 0.6388

Name	%	Time	Area
A1A	0.5	0.24	6.36
A1B	1.0	0.31	11.60
F	0.3	0.40	3.94
LA1C+	1.9	0.47	23.45
SA1C	5.7	0.59	51.92
A0	92.2	0.90	1109.96
H-V0			
H-V1			
H-V2			

Total Area 1207.23

HbA1c 5.7 % **IFCC 39 mmol/mol**

HbA1 7.2 % HbF 0.3 %

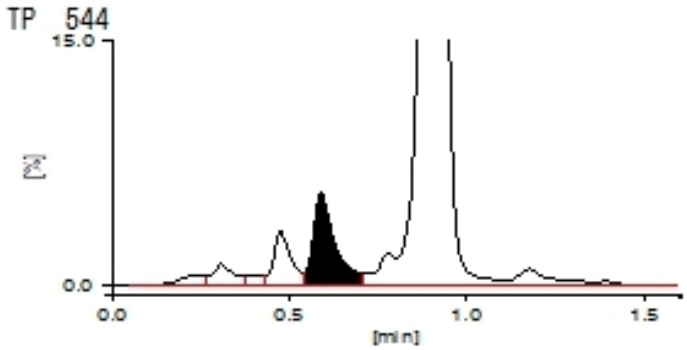

NEUBERG PULSE DIAGNOSTIC CENTRE
75,SARAT BOSE RD, KOL - 26

Pulse DIAGNOSTICS™

Neuberg Pulse DIAGNOSTICS

LABORATORY REPORT

Name : **Mr SARANIK DEY**	Sex/Age : **Male / 36 Years**	Case ID : **60135208461**	
Reg Date : 24-Jan-2026 12:44		Pt. ID : 7660732	
Bill. Loc. : Neuberg Pulse Lansdowne		Mob.No : 9038432001	
Ref. By : Dr. Debabrata De MBBS (Cal)			
Sample Date and Time : 24-Jan-2026 12:47	Sample Type : Serum	Ref Id1 :	
Report Date and Time : 24-Jan-2026 16:08		Ref Id2 :	

LIPID PROFILE

TEST		RESULTS	UNIT	BIOLOGICAL REF RANGE	REMARKS
Cholesterol *Enzymatic*		196	mg/dL	<200 - Desirable 200 - 239 - Borderline High > 240 - High	
Triglyceride *Glycerol Phosphate Oxidase*		102	mg/dL	< 150 - Normal 150 - 199 - Borderline 200 - 499 - High > 500 - Very High	
HDL Cholesterol *CHOD-POD*		46	mg/dL	Desirable : >60 Borderline : 40-60 Low(High risk) : <40	
LDL Cholesterol (Direct) *CHOD-POD*		124	mg/dL	Optimal : <100 Above Optimal: 100 - 129 Borderline high : 130 - 159 High : 160 - 189 Very High : >190	
VLDL		26	mg/dL	10-40	
Non-HDL Cholesterol *Calculated*	H	**150**	mg/dL	<130	
Cholesterol/HDL-C *Calculated*		4.26		1 - 5.2	
LDL/HDL Ratio		2.70			

***National Cholesterol Education Programme Adult Treatment Panel III Guidelines(US).**

Note:(LL-VeryLow,L-Low,H-High,HH-VeryHigh,A-Abnormal)

Pintu Manna

Verified by

Dr. Krishti Chatterjee

MBBS, MD (Pathology),
Consultant Pathologist
WBMC 69911

MC - 2167

LABORATORY REPORT

Name	: **Mr SARANIK DEY**	Sex/Age	: **Male / 36 Years**	Case ID	: **60135208461**
Reg Date	: 24-Jan-2026 12:44			Pt. ID	: 7660732
Bill. Loc.	: Neuberg Pulse Lansdowne			Mob.No	: 9038432001
Ref. By	: Dr. Debabrata De MBBS (Cal)				

Sample Date and Time	: 24-Jan-2026 12:47	Sample Type	: Serum	Ref Id1	:
Report Date and Time	: 24-Jan-2026 16:08			Ref Id2	:

Liver Function Test

TEST		RESULTS	UNIT	BIOLOGICAL REF RANGE	TEST REMARK
Bilirubin Total *DIAZO REACTION*		0.80	mg/dL	<1.2	
Bilirubin Conjugated *DPD*	**H**	**0.24**	mg/dL	< 0.2	
Bilirubin Unconjugated *Calculated*		0.56	mg/dL	0 - 0.8	
ALT (SGPT) *NADH (Without P-5-P)*		24	U/L	< 50	
AST (SGOT) *NADH (Without P-5-P)*		25	U/L	< 50	
Gamma Glutamyl Transferase *IFCC*		25	U/L	0-55	
Alkaline Phospatase *IFCC*		103	U/L	30-120	
Proteins (Total) *Biuret*		7.38	g/dL	6.4 - 8.3	
Albumin *(BCG)*		5.00	g/dL	3.5 - 5.2	
Globulin *Calculated*		2.38	g/dL	1.80 - 3.60	
A/G Ratio *Calculated*	**H**	**2.10**		1.2 - 2.0	

Note:(LL-VeryLow,L-Low,H-High,HH-VeryHigh,A-Abnormal)

Pintu Manna

Verified by

Dr. Krishti Chatterjee
MBBS, MD (Pathology),
Consultant Pathologist
WBMC 69911

MC - 2167

RADIOLOGY REPORT			
Name:	Mr SARANIK DEY	**Patient ID:**	60135208461
Gender/ Age :	Male / 36 Years	**Registration Date & Time :**	24-Jan-2026 12:44
Ref Id:		**Receiving Date & Time:**	
Bill Location:	Neuberg Pulse Lansdowne	**Report Date & Time:**	24-Jan-2026 16:18
Ref By:	Dr. Debabrata De MBBS (Cal)		

X-RAY CHEST PA VIEW

Lung fields are clear.

Hilar shadows are normal.

Bilateral CP angles are normal.

Cardio thoracic ratio is within normal limits.

Domes of the diaphragm are normal in contour & position.

Bony thorax does not reveal any obvious abnormality.

IMPRESSION
Normal Study.

Partha Mondal
Verified BY

Dr. Arunava Chaudhuri
Consultant Radiologist
WBMC 63780

CARDIOLOGY REPORT			
Name:	Mr SARANIK DEY	**Patient ID:**	60135208461
Gender/ Age :	Male / 36 Years	**Registration Date & Time :**	24-Jan-2026 12:44
Ref Id:		**Receiving Date & Time:**	24-Jan-2026 14:40
Bill Location:	Neuberg Pulse Lansdowne	**Report Date & Time:**	24-Jan-2026 18:51
Ref By:	Dr. Debabrata De MBBS (Cal)		

ECHOCARDIOGRAPHY 2D

M Mode Data : Parameter	Test Value	Normal Range (Adults)	Unit
Aortic Root Diameter	2.5	2.0 – 4.0	cm
Aortic cusp opening	2.1	1.5 – 2.0	cm
Left atrial diameter	3.5	2.0 – 4.0	cm
RV internal diameter	2.0	0.6 – 2.3	cm
IV septal thickness (diastole)	1.1	0.60 – 1.10	cm
LV Internal diameter (diastole)	4.8	3.50 – 5.6	cm
Post. Wall thickness (diastole)	1.1	0.60 – 1.10	cm
Internal diameter (systole)	3.1	2.4 – 4.20	cm
LV Ejection fraction	65%	55 – 75	%
EPSS	0.9	0.1 – 1.0	cm
EF slope	13	5 – 15	cm/ sec
DE amplitude	1.5	1.5 – 2.5	cm
FS	36%		%

Observation:

Left Ventricle :

Cavity size / wall thickness : Within normal limits
LV wall motion study : No regional wall motion abnormality
Systolic function : Good
Diastolic compliance : Adequate

Left Atrium :

Normal sized, no mass in the appendage / body.

Right ventricle and right atrium :

Normal sized. Good RV systolic function. TAPSE - 20 mm

Mitral valve :

Normal leaflets, good excursion, normal subvalvular apparatus.

Aortic valve :

Three cusps – no thickening, good systolic excursion.

Tricuspid valve :

Normal leaflets, normal sizes annulus.

Pulmonary valve :

Normal cusps, good systolic excursion.

Ventricular septum :

Intact.

Inter atrial septum :

Intact

Pericardium :

No thickening, no effusion

CARDIOLOGY REPORT			
Name:	Mr SARANIK DEY	**Patient ID:**	60135208461
Gender/ Age :	Male / 36 Years	**Registration Date & Time :**	24-Jan-2026 12:44
Ref Id:		**Receiving Date & Time:**	24-Jan-2026 14:40
Bill Location:	Neuberg Pulse Lansdowne	**Report Date & Time:**	24-Jan-2026 18:51
Ref By:	Dr. Debabrata De MBBS (Cal)		

Impression:
Normal biventricular systolic and diastolic function

Sharmila Samadder
Verified BY

Dr. Subir Sen
MD (Med),DM(Cardio),
Consultant Cardiologist,
20883 (AMC)

RADIOLOGY REPORT			
Name:	Mr SARANIK DEY	**Patient ID:**	60135208461
Gender/ Age :	Male / 36 Years	**Registration Date & Time :**	24-Jan-2026 12:44
Ref Id:		**Receiving Date & Time:**	
Bill Location:	Neuberg Pulse Lansdowne	**Report Date & Time:**	24-Jan-2026 14:48
Ref By:	Dr. Debabrata De MBBS (Cal)		

USG STUDY OF WHOLE ABDOMEN

LIVER
Is normal in size (145 mm), outline with diffusely increased parenchymal echotexture. No focal lesion is seen. Intrahepatic billary radicles are not seen dilated. Hepatic & Portal venous systems appear normal. Portal vein 8 mm.in calibre.

GALL BLADDER
Is seen normal in size, shape, outline, position & wall thickness. No intraluminal calculus or any mass lesion is seen. No pericholecystic fluid collection is seen.

CBD
Is not seen dilated and measures 3 mm.

PANCREAS
Is normal in size, shape, outline and echotexture. No definite focal lesion is evident. Pancreatic duct is not seen dilated. No tenderness is seen over the region.

SPLEEN
Is normal in shape, size, position and echotexture. No focal lesion is seen. No abnormal vessels are seen at the splenic hilum. Spleen measures 98 mm. in length.

KIDNEYS
Are normal in size, position, outline and echogenicity with maintained cortico-medullary differentiation. No focal lesion is seen involving either kidney. Central echocomplexes of both kidneys appear normal. There is no evidence of hydronephrosis or calculus.
Right kidney measures 100 mm.
Left kidney measures 102 mm

URETERS
Ureters are not seen dilated.

URINARY BLADDER
Urinary bladder appears optimally distended. It appears smooth in outline. No mass lesion or any calculus is seen within the urinary bladder.

PROSTATE
Prostate is seen normal in size, outline and echotexture. No definite focal parenchymal lesion is seen. Prostatic capsule is intact. Prostate measures 25 x 38 x 31 mm and weighs 15 gms.

No evidence of ascitis, pleural effusion or abdominal lymphadenopathy.

IMPRESSION
Grade I fatty changes in liver

RADIOLOGY REPORT			
Name:	Mr SARANIK DEY	**Patient ID:**	60135208461
Gender/ Age :	Male / 36 Years	**Registration Date & Time :**	24-Jan-2026 12:44
Ref Id:		**Receiving Date & Time:**	
Bill Location:	Neuberg Pulse Lansdowne	**Report Date & Time:**	24-Jan-2026 14:48
Ref By:	Dr. Debabrata De MBBS (Cal)		

---------- End Of Report ----------

Bithika Mistry
Verified BY

Dr. Arunava Chaudhuri
Consultant Radiologist
WBMC 63780