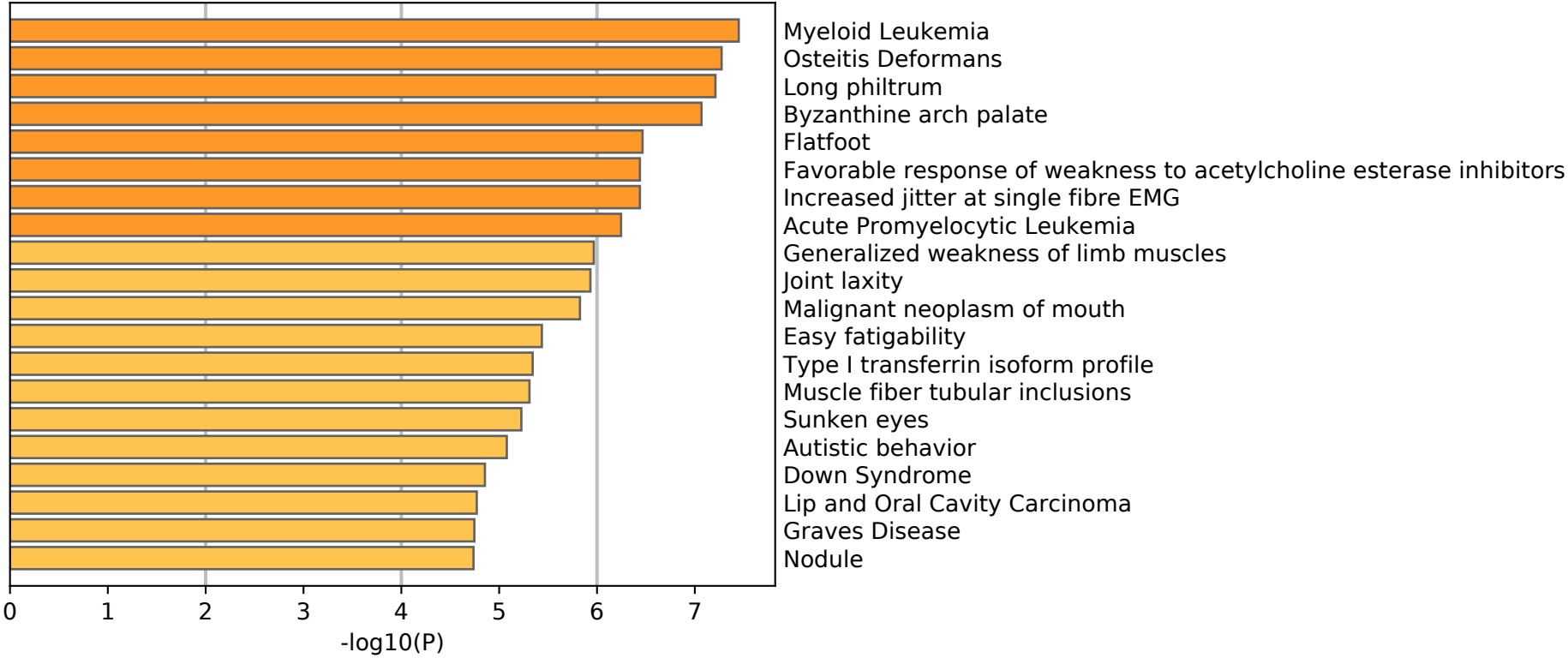
Myeloid Leukemia
Osteitis Deformans
Long philtrum
Byzanthine arch palate
Flatfoot
Favorable response of weakness to acetylcholine esterase inhibitors
Increased jitter at single fibre EMG
Acute Promyelocytic Leukemia
Generalized weakness of limb muscles
Joint laxity
Malignant neoplasm of mouth
Easy fatigability
Type I transferrin isoform profile
Muscle fiber tubular inclusions
Sunken eyes
Autistic behavior
Down Syndrome
Lip and Oral Cavity Carcinoma
Graves Disease
Nodule
0
1
2
3
4
5
6
7
-log10(P)