Clinical Scenarios: One male patient aged 72 years complained of one-week chest pain and three-day exertional dyspnoea. There was no past history of cardiovascular, respiratory, or gastrointestinal disease …

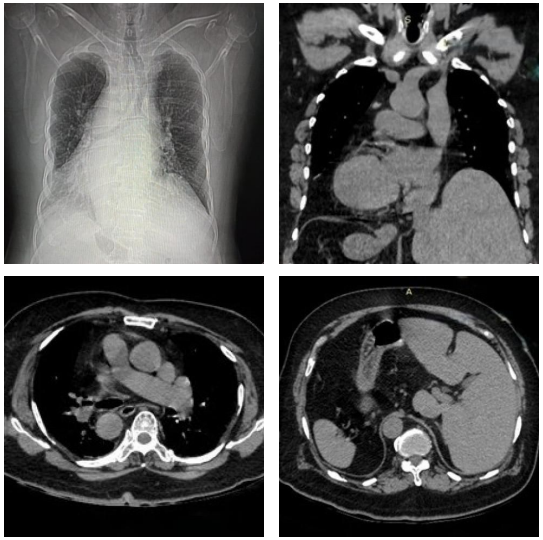

Based on ALL provided images together with the textual context, select the single best diagnosis from the options.

A. Situs inversus totalis with dextrocardia
B. Dextrocardia without situs inversus
C. Kartagener syndrome
D. Technical rotation artefact on imaging
E. Congenital cardiac malformation with positional abnormality

Medical thinking with images (TwI)

Medical Agent

Step1: per-image radiological annotations

Figure 1: Chest X-ray (PA view) demonstrating situs inversus totalis,…
Figure 2/3/4

Step2: case-level integrated imaging findings

Chest X-ray demonstrated dextrocardia with gastric bubble on the right and thereby suggested situs inversus totalis. ECG demonstrated …

Step3: differential diagnosis reasoning

The images show a clean mirror-image layout: the heart apex points right, the aortic arch tracks on the right, and on abdominal CT, the stomach/spleen are right-sided while the liver is left-sided: classic situs inversus totalis with dextrocardia.

Isolated dextrocardia (B) would keep normal abdominal situs, which we do not see.

Kartagener syndrome (C) needs ……

Rotation artifact (D) cannot ……

A congenital malformation with positional abnormality (E) usually gives mixed/ambiguous organ positions, not this symmetric mirror pattern. Hence only (A) Situs inversus totalis with dextrocardia fits all findings.

Diagnosing-Style Evaluation

MedTwI Eval

Step1 and Step2:
- ROUGE/RadCliQ

Step3: step by step
- Clinical Correct ?
- Clinical Critical ?
- Error Analysis →

MedTwI Error Analysis

- Clinical Scenario Understanding
- Image Perceptual Error
- Lack of Medical Knowledge
- Reasoning Process Error

Case Discussion Eval

B+C+I+C+O+T

1. Section by section eval
2. Each section annotate sent.-level correctness

Education Value Analysis

1. Disease Definition 2. Clinical Manifestation 3. Imaging Findings 4. Diagnostic Reasoning 5. Transferable Learning → Each scored 0–2

Medical Education Case Discussion

Background:
Situs describes the position of the thoracic and abdominal organs. Situs solitus [1] ……

Clinical Perspective:
Patients with situs inversus totalis are frequently asymptomatic. However …

Imaging Perspective:
Initial chest radiography suggested dextrocardia with situs inversus. ECG findings further supported this. CT thorax and abdomen [5] …

Clinical Significance:
Recognition of situs inversus totalis is vital in clinical and emergency settings to prevent misdiagnosis [10], especially in …

Outcome:
No acute cardiac or respiratory pathology was identified in our case. The patient

Take Home Message / Teaching Points:

1. Situs inversus totalis is often discovered incidentally.
2. Awareness of such anatomical variants is essential for accurate diagnosis and treatment planning.
3. Imaging plays a pivotal role in confirming the diagnosis and excluding associated anomalies.
4. Patients should be informed about their condition, especially in preparation for emergencies or interventions.