LEXINGTON PODIATRY
THE FOOT + ANKLE SPECIALISTS

Fax - Important Notice

September 17, 2025
Fax: (859) 399-6697

Jamie N Settles Carter, DPM
(859) 264-1141 Work
(859) 264-1963 Fax

Lexington Podiatry
2700 Old Rosebud Rd Ste 250
Lexington, KY 40509-8624

LEXINGTON PODIATRY
THE FOOT + ANKLE SPECIALISTS

Carter, Brian

PMS ID:	Sex:	DOB:	Phone:	MRN:
IMS10875	Male	06/30/1950	(859) 576-3189	835378

September 17, 2025

We would like to refer Brian Carter to your office for continued care.

If you required additional information aside from the below or have questions related to this patient, you may reach out Referral Department at (859) 264-1141 or happyfeet@lexpodiatry.com.

Thank you for your care and expertise.

Regards,

Sammie Olivera

Jamie N Settles Carter, DPM
(859) 264-1141 Work
(859) 264-1963 Fax

Lexington Podiatry
2700 Old Rosebud Rd Ste 250
Lexington, KY 40509-8624

Lexington Podiatry

Lexington Podiatry

Appointment: 10/07/2025 1:15 PM

Provider: Smallwood, Stacey APRN

Patient Information

Name:	Brian Carter	**Home Phone:**	
D.O.B:	06/30/1950	**Work Phone:**	(859) 357-8004
Sex:	Male	**Mobile Phone:**	(859) 576-3189
SSN:		**Email:**	brian.carter34@windstream.net
MRN:	835378	**Preferred Contact Method:**	Unspecified
PMS ID:	IMS10875	**Language:**	English
Marital Status:	Unknown	**Emergency Contact:**	
Race:	Unspecified	**Emergency Contact Phone:**	
Ethnicity:	Unspecified	**Employer:**	
Address:	PO Box 54974 Lexington, KY 40555	**Primary Care Provider:**	
		Referring Providers:	

Primary Insurance Information

Carrier:	Blue Cross Blue Shield of Kentucky	**Address:**	PO BOX 105187 Atlanta, GA 30348
Policy #:	WNXM6151615300		
Group ID/Name:		**Phone Number:**	(800) 676-2583

Pharmacy Information

Name:	Sam's Club Pharmacy 8188	**Address:**	1063 NEW CIRCLE RD. NE LEXINGTON, KY 40505
Phone Number:	8592816615		
Fax Number:	8592816376		

LEXINGTON PODIATRY
THE FOOT + ANKLE SPECIALISTS

Visit Note - September 9, 2025

Carter, Brian

PMS ID:	Sex:	DOB:	Phone:	MRN:
IMS10875	Male	06/30/1950	(859) 576-3189	835378

Allergies
Obtained and Reviewed September 9, 2025.
No known drug allergies

Medications
Obtained and Reviewed September 9, 2025.
lisinopril-hydrochlorothiazide 20-12.5 mg Oral - tablet

Medical History
Obtained and Reviewed September 9, 2025.
Other: Hypertension

Podiatric Foot/Ankle Disease History
None

Podiatric Foot/Ankle Surgical History
Other: L foot

Podiatric Foot/Ankle Family History
None

Surgical History
Obtained and Reviewed September 9, 2025.
Other: Multiple hernia repairs, appendix, R knee scope, L foot

Social History
Obtained and Reviewed September 9, 2025.
Smoking status - Unspecified

Chief Complaints:
1. L2 plantar "ulcer"

HPI: This is a 75 year old male who:
1. is being seen for a chief complaint of L2 plantar "ulcer". Patient states this has been going on since January 2025. Patient describes pain as a 7/10 sharp pain at its worst. At home treatment includes soaking in peroxide twice a week.

Historical Summary:
Shoe size: 13

Vitals:

Date	Taken By	B.P.	Pulse	Resp.	O2 Sat.	Temp.	Ht.	Wt.	BMI	BSA
09/09/25 13:24	Lowe, Devon	123/66 SIT					78.0 cm	377.0 lbs	281.1	1.5
	FiO2									

* Patient Reported

Exam:

Foot/Ankle

Peripheral Pulses:
Left Dorsalis Pedis: Normal +2 dorsalis pedis pulse
Left Posterior Tibial: Normal +2 posterior tibial pulse
Left Capillary Refill: Normal
Left Vascular Skin Trophic Changes: No Skin trophic changes of vascular nature
Left Edema: No Edema
Left Venous Exam: Normal

Skin:
Left Foot and Ankle: **L2 ulcer - 0.3CMx0.5CMx0.5CM - 100% granular, moist hyperkeratotic margins, no signs of infection, no tunneling**

Gait: normal gait

Appearance: well developed and nourished

Additional Exam Findings:

- Units: cm
- Pre-debridement Wound Length: 0.2
- Pre-debridement Wound Width: 0.4
- Pre-debridement Wound Depth: 0.5

Tests

X-Ray Interpretation Ankle/Foot

Diagnosis: Foot Pain, Left - M79.672
X-Ray Data:
Date: 09/09/2025
The following film(s) were done in our facility: left ankle AP, ankle oblique, and ankle lateral standing , foot oblique and foot AP weight bearing ankle, 3 views minimum; CPT 73610 and foot, 2 views; CPT 73620
Medical Necessity: Pain

X-rays of the left ankle/foot were ordered and obtained, demonstrating the following findings: Hardwear in fibula intact, DJD in MF, 2nd proximal phalanx fracture healing, hammertoe 345

Impression/Plan:

1. **Non-pressure chronic ulcer of other part of left foot with fat layer exposed**
   Non-pressure chronic ulcer of other part of left foot with fat layer exposed (L97.522)
   located on the right lateral plantar 2nd toe.
   Associated diagnosis: Foot Pain

   Plan: Counseling - Ulcer.
   I counseled the patient regarding the following:
   Skin Care: Ulcers can be treated with topical antiseptic washes, topical antibiotics, non-adhesive dressings and compression stockings. Elevation and offloading should also be performed, especially at night. Vascular studies may be indicated to assess the extent of disease. Surgical intervention is indicated in some patients, and a variety of grafts and products may be used.
   Expectations: Ulcers can result from vascular insufficiency and edema to the skin. Ulcers are prone to infections, and meticulous wound care is a must. Vascular interventions may be indicated depending on findings. Stasis ulcers often take weeks to months to heal. Some ulcers fail to heal despite multiple treatment modalities.
   Contact office if: Ulcer fails to improve after several weeks of treatment or if redness, swelling, fever, purulence or tenderness develop.

   Plan: Excisional Debridement - No Pathology.
   The initial decision to perform this procedure was made after evaluation during this visit.

   Specific Location of Wound Debrided: RIGHT LATERAL PLANTAR 2ND TOE

   Medical Necessity for Excisional Debridement: Excisional debridement is medically necessary due to the presence and extent of devitalized and necrotic tissue noted in this wound examination. This type of tissue requires sharp instrumentation excision because it prevents and interferes with optimal wound healing.

   Clinical Photo in Chart
   Consent was obtained from the patient. The risks, benefits and alternatives to therapy were discussed in detail. Specifically, the risks of infection, scarring, bleeding, prolonged wound healing, nerve injury, and allergy to anesthesia were addressed. Alternatives to debridement, such as aggressive wound care, were also discussed. Prior to the procedure, the treatment site was clearly identified and confirmed by the patient. All components of Universal Protocol/PAUSE Rule completed.

   Wound Characteristics:
   Pre-debridement Wound Measurements:
   - Length: 0.2 cm
   - Width: 0.4 cm
   - Depth: 0.5 cm
   - Area: 0.08 cm^2
   - Volume: 0.04 cm^3
   Wound Base: granular
   Wound Edges Additional: moist hyperkeratotic
   -Presence or absence of obvious signs of infection: ABSENCE OF OBVIOUS SIGNS OF INFECTION
   -Presence or absence of necrosis, devitalized, or nonviable tissue: ABSENCE OF OBVIOUS SIGNS OF NECROSIS, DEVITALIZED, OR NONVIABLE TISSUE
   - Tunneling: Not Present
   - Undermining: Not Present
   Odor: None
   Exudate: None

   Post-debridement Wound Measurements:
   - Length: 0.3 cm
   - Width: 0.5 cm
   - Depth: 0.5 cm
   - Area: 0.15 cm^2
   - Volume: 0.07 cm^3
   Upon completion of debridement, the wound bed was notable for healthy granulation visible at the base.

   Level/depth of tissue debrided: Debridement of the the wound on the right lateral plantar 2nd toe was carried into SKIN AND SUBCUTANEOUS

TISSUE layer.
Nature of tissues removed and selective surgical debridement of hypergranulation.

Method: Excisional surgical debridement was accomplished using scalpel to remove the tissues. Hemostasis was accomplished with the use of compression. Satisfactory hemostasis was noted. Complications: None. Immediate post-op care performed and the wound was dressed with Bacitracin.
Bandaging included dry sterile dressing.

Goals: There is an expectation that the treatment will substantially affect tissue healing and viability, reduce or control tissue infection, or prepare the tissue for surgical management. After the documented goal is reached, the wound should look fully covered with epidermal layer of skin. Possible scarring, hyperpigmentation, change of skin texture reviewed.

Follow up care and Post-op Instructions:
-HELIX DRESSING CHANGES: Keep bandage clean, dry and intact. Clean wound daily with soap and water and allow to dry before re-applying bandage. Apply a generous layer of Helix collagen powder to cover the entire base of the wound. Cover with appropriate secondary dressing. Patient to monitor for signs of infection and to call the office for questions or concerns. and POLYMEM DRESSING CHANGES: Keep bandage clean, dry and intact. Clean wound daily with soap and water and allow to dry before re-applying bandage. Apply one Polymem bandage to the wound, being careful not to allow the adhesive edges to touch the open wound. This bandage can be used for up to 3 days as long as the foam is not saturated with drainage. Patient is to monitor for signs of infection and to call the office for questions or concerns.
-Appropriate Care Note: Care has been performed inaccordance with accepted standards for medical and surgical treatment of wounds of this type. The appropriate interval and frequency of debridement is adequate on this individual clinical characteristics and the extent of the wound. and The extent and number of services provided is medically necessary and reasonable based on the documented medical evaluation of the patient's condition, diagnosis, and plan.

Plan: Home Health Referral.
Brian Carter was examined and treated today.

Home Health Instructions:
- Admit to home health: Please admit the patient to home health care.
- Wound care: antibiotic ointment and a dry dressing

Orders
- Change dressing daily.:
Provider: Jamie N Settles Carter, DPM
Priority: normal

Plan: Recommendations.
The following were recommended to patient at this visit:
OTC PRODUCTS: The following OTC products were recommended but declined at todays visit:
Post-op shoe

Plan: Separate and Identifiable Documentation.

2. **Foot Pain, Left**
Pain in left foot (M79.672)

MIPS

1. **MIPS**
Plan: MIPS Quality.

Quality 226 (Tobacco Use Screening and Cessation Intervention): Patient screened for tobacco use and is an ex/non-smoker
Quality 130 (Documentation of Current Medications in the Medical Record): Current Medications Documented
Quality 47 (Advance Care Plan): Advance Care Planning discussed and documented in the medical record; patient did not wish or was not able to name a surrogate decision maker or provide an advance care plan.
Quality 317 (Preventative Care and Screening: Screening for High Blood Pressure and Follow-up Documented): Elevated or hypertensive blood pressure reading documented, and the indicated follow-up is documented
Additional Notes: Recommended follow up with pcp due to elevated BP.

Follow up in 4 weeks

Staff:

Jamie N Settles Carter, DPM (Primary Provider) (Bill Under)

Emily McGuire

Other Photos		
 Tue 09/09/2025 13:36:38.913	 Tue 09/09/2025 14:07:38.094	

Electronically Signed By: Jamie N Settles Carter, DPM, 09/12/2025 12:37 PM EDT

Dr. Nicole Freels, FACFAOM
Dr. Jamie Settles Carter
Stacey Smallwood, APRN
happyfeet@lexpodiatry.com

LEXINGTON PODIATRY
THE FOOT • ANKLE SPECIALISTS

2700 Old Rosebud Rd, Suite 110
Lexington, KY 40509
Ph 859-264-1141 • Fx 859-264-1963
www.lexingtonkypodiatry.com

Outgoing Referral Form

Patient Information **Date:** 9/17/25

Name: Brian Carter **Date of Birth:** 6/30/50

Address: PO Box 534974 Lexington Ky 40555

Phone: 859-576-3189

Insurance: Anthem #WNXM615161 53506 **Referred By:** Dr. Jamie Carter

Referral Information

Referred To: Mcgrath Medical Wound **Phone:** 859-285-9562

Address: 1648 Alexandria Dr. Ste

Specialty: Wound Care

Referred For: Non pressure chronic ulcer | L foot w | fat layer exposed

Diagnosis Code: L97.522

Included with this referral form is demographic information, office visit notes, imaging/lab results. If you require any further documentation please contact our office and ask for Katrina in the Referrals Department. We can be reached via phone (859)264-1141 or email: katrina.hall@lexpodiatry.com OR happyfeet@lexpodiatry.com

Once the patient has been scheduled for an appointment with your office please fax this form back to (859)264-1963.

Appointment Date & Time: _____

BlueCross BlueShield

WINDSTREAM

BRIAN F CARTER

Member ID

WNXM6151615300

Group No. 0105090001

Windstream

Ded: In $6550 Out $13100

Max OOP: In $6550 Out $13100

6550 Plan

SELF-FUNDED

PPO

BlueAdvantage Administrators of Arkansas

Hospitals or physicians: File claims with local BlueCross and BlueShield Plan. Call BlueAdvantage Administrators of Arkansas provider services to preauthorize inpatient medical/behavioral health admissions (including emergency admissions), and to prenotify outpatient behavioral health or diagnostic imaging services.

Members: Contact your personal healthcare assistant Included Health* for help, understanding your medical bills and coverage, finding doctors, and more.

* Included Health contracts directly with Windstream to provide member services and care management at no cost to you and your dependents.

www.blueadvantagearkansas.com

*Personal Healthcare Assistant
includedhealth.com/windstream
or call 855-524-8426
Provider Service 844-662-2279
Precertification 844-662-2279
Behavioral Health 855-524-8426
High Tech 866-688-1449

*Contracts directly with group

BlueAdvantage Administrators of Arkansas
P.O. Box 1460
Little Rock, AR 72203-1460

BlueAdvantage Administrators of Arkansas, an independent licensee of the Blue Cross Blue Shield Association, provides administrative claim payment services only and does not assume any financial risk or obligation with respect to claims.

Payor ID: 00520

1C

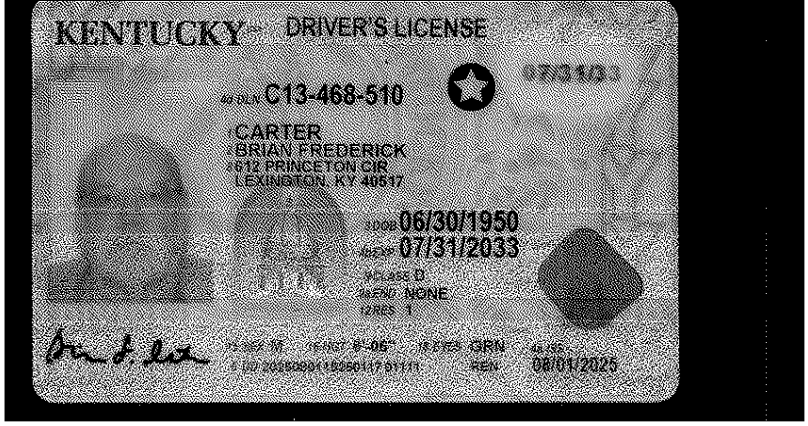
KENTUCKY DRIVER'S LICENSE
4d DLN C13-468-510
07/31/33
1 CARTER
2 BRIAN FREDERICK
8 612 PRINCETON CIR
LEXINGTON, KY 40517
10 DOB 06/30/1950
4b EXP 07/31/2033
9a CLASS D
9b END NONE
12 RES 1
15 SEX M
16 HGT 5'-06"
18 EYES GRN
DD 20250001180501170111
REN
08/01/2025