Chronic Undiagnosed Hydrocephalus Secondary to Tectal Glioma: An Autoethnography of Neurological Decline and Systemic Diagnostic Failure

Benjamin Kane BSc.

April 1, 2026

1 Abstract

This autoethnographic study explores the prolonged misdiagnosis of complex neurological conditions, including traumatic brain injury (TBI), exacerbated by age-based stigma and reductive biomedical assumptions. Through a first-person narrative, it traces the author's trajectory from a "normal" life to rapid cognitive, physical, and psychological deterioration resulting from delayed neurosurgical intervention and overlooked multimorbidity.

Challenging dominant biomedical narratives, this account illuminates the profound cognitive, emotional, and social impacts of chronic neurological illness, including disruptions to identity, self-regulation, and social inclusion. It offers critical insights for clinicians, researchers, and neurodivergent individuals, advocating for earlier and more comprehensive diagnostic assessments that extend beyond initial presenting symptoms to encompass associated neurological signs.

This study emphasises the essential role of third-party observations from family members, friends, or caregivers in diagnostic processes, particularly when cognitive impairments limit patients' ability to self-report symptoms. It calls for the elimination of age-based assumptions that contribute to delays in vital medical and surgical interventions.

Keywords

autoethnography, obstructive hydrocephalus, tectal glioma, traumatic brain injury, misdiagnosis, diagnostic delay, age-based stigma, Hakim's triad, third-party advocacy, ventriculoperitoneal shunt, multiple sclerosis, schizoaffective disorder, diagnostic overshadowing

Introduction

Obstructive hydrocephalus, secondary to tectal glioma, is rare in adolescents and young adults, where a low-grade tumour obstructs cerebrospinal fluid flow, causing progressive ventriculomegaly and elevated intracranial pressure. Symptoms including cognitive impairment, gait disturbances, and urinary incontinence, develop insidiously over many years, complicating timely diagnosis. In younger patients, these are often misattributed to behavioural, psychiatric, or substance-related issues due to age-based stigma favouring more common explanations in this demographic.

Hakim's triad (gait disturbances, incontinence, and cognitive decline) is classically associated with normal pressure hydrocephalus in older adults and can also manifest in obstructive cases. However, its recognition is uncommon in youth, exacerbating diagnostic overshadowing.

Autoethnography enables insider exploration of such overlooked experiences, blending personal narratives with critical analysis to challenge biomedical discourses and reveal systemic gaps. As both patient and researcher[1;2], I examine my trajectory from perceived "normal" adolescence to near-fatal crisis due to undiagnosed obstructive hydrocephalus and associated traumatic brain injury.

This account traces the onset of symptoms in childhood, escalation through adolescence, and the pivotal role of third-party advocacy in securing diagnosis and lifesaving intervention. It advocates for holistic symptom assessment and reduction of age-based bias when cognitive impairments limit self-reporting.

This study contributes to the literature by demonstrating how age-based diagnostic bias and fragmented symptom assessment can critically delay life-saving intervention in younger patients with obstructive hydrocephalus.

Methods

This study employs an analytical autoethnographic approach, in which the author serves as both the patient and researcher. This method provides a robust framework for exploring the lived experience of misdiagnosed complex neurological conditions, including long-term undiagnosed obstructive hydrocephalus secondary to tectal glioma with resulting traumatic brain injury. It is particularly suited to examining how memory, identity, and cognitive function are reshaped by delayed neurosurgical intervention and neurological multimorbidity [1;2].

Data sources comprise reconstructed autobiographical memories elicited through in-depth conversations with close family members and friends, supplemented by clinical documentation and neurosurgical reports. Verbal informed consent was obtained from all contributors prior to these conversations. These external accounts were used to corroborate, contextualize, and address gaps in the author's fragmented or inaccessible autobiographical memory, a common sequela of the conditions described.

This methodology aims to interpret the long-term consequences of undiagnosed traumatic brain injury arising from obstructive hydrocephalus, while highlighting gaps in medical intervention exacerbated by age-based stigma and reductive biomedical assumptions. The analysis involved iterative cycles of reflective writing, thematic coding of personal and corroborated accounts, and ongoing reflexivity to mitigate biases inherent in insider research. Limitations include retrospective bias, mitigated through corroboration and reflexivity.

Patient and Public Contribution

As both patient and author, I led this autoethnographic study, drawing on my lived experience as the primary data source and foundation for the core narrative. My first-person reflections centre on the prolonged misdiagnosis of complex neurological symptoms, the impacts of hydrocephalus, and associated traumatic brain injury, with particular emphasis on social disruption and memory loss.

Family members and close friends provided external perspectives through informal discussions that aided solely in reconstructing fragmented memories from traumatic brain injury and undiagnosed hydrocephalus. These contributions focused primarily on building an accurate timeline of events leading to initial diagnosis and treatment. Verbal informed consent was obtained from all contributors.

The external accounts served to enhance the authenticity and validity of the narrative by corroborating and highlighting key events during my journey to diagnosis and treatment. They did not influence the study design, analytical framework, interpretation, or writing, ensuring the work remained firmly rooted in an insider's perspective. All third-party contributions were anonymized.

Early Life

I was raised by a single father, alongside my brother and sister. Throughout my childhood, life appeared normal until changes emerged around the age of twelve or thirteen, when I would return home from school and sleep for several hours, unable to stay awake. In retrospect, this was the beginning of my neurological symptoms. This subsided for approximately two years. During this time, academic performance was impacted, regularly failing mock GCSE tests, in particular mathematics, highlighting the impact of neurological symptoms on cognitive abilities, particularly those reliant on procedural learning. When symptoms eased, my grades recovered, culminating in a B in GCSE Mathematics.

Due to my routine of falling asleep when returning from school, my ability to sleep later that night was affected, where I would be awake until the early hours of the morning. My father attributed this to me falling asleep when returning from school, masking the impact of the initial signs of subsequent neurological symptoms, initiating the age-based stigma that prolonged my diagnosis. This created an early narrative that framed my symptoms as age-based behaviour rather than a pathological condition, masking the underlying condition.

My behaviour during this time aligned with what might be expected from a troubled child, getting involved in mischievous behaviours that later contributed to the perceptions of drug abuse. I regularly started fires in the local woods, stayed out all night without permission, drank a lot, and was a general public nuisance. I listened to music commonly associated with this form of antisocial behaviour, including bands such as Slipknot and System Of A Down. This, combined with having a heavy-drinking father on a low income, reinforced perceptions of deliberate misbehaviour or drug abuse[3]. In hindsight, while partly typical teenage rebellion, these were later misinterpreted through intersecting class and age-based stigmas, diverting attention from progressive neurological decline.

Working Life Social Impact

At age 16, I began working at the bakery at ASDA, Dunstable, a role centred on repetitive tasks that later proved profoundly challenging amid progressive neurological decline. The steady income brought new freedoms. I started attending music events, mainly in central London, often staying overnight at my grandmother's house to manage logistics and recovery.

During this time, symptoms resurfaced at a far more severe intensity. Excessive fatigue, memory lapses, and unpredictable dips in consciousness disrupted daily life and social interactions, making even routine tasks exhausting.

Late nights and highly stimulating environments amplified visible signs of impairment; extreme tiredness, disorientation, and erratic behaviour. Given my age and adolescent history, these were frequently attributed to substance abuse rather than medical pathology[4–7].

In retrospect, these misinterpretations, rooted in age-based stigma, were clear indicators of undiagnosed obstructive hydrocephalus and associated traumatic brain injury, prolonging the delay in medical diagnosis and treatment.

Initial Physical Changes

Towards late 16, early 17, new physical symptoms emerged, further reinforcing external perceptions of substance abuse[4–9]. Incontinence became frequent and deeply distressing. I lost voluntary control, with episodes occurring unpredictably, often without warning, and dictated by my body rather than intent, and coincided with worsened sleep patterns.

Alertness deteriorated sharply, even while awake. I experienced frequent dips in consciousness and periods of absent cognitive and physical presence. Those around me often asked if I was okay, their concern typically shaped by the ideology of substance abuse.

In retrospect, these were the unequivocal signs of advancing ventriculomegaly and consequential traumatic brain injury. I attended multiple GP appointments, but my incontinence and altered state of consciousness were simply labelled without further investigation or referral — marking the beginning of significant medical oversight and insufficient clinical assessment[10–12].

Academic Failure and Rehousing

As my executive function continued to decline, I failed my A levels and was asked to leave my family home. This abruptly removed a key constant - my father's daily presence. The timing coincided with the onset of profound memory loss. From this point onwards, my own recollection of events became minimal to non-existent. I therefore rely, to this day, on third-party accounts to reconstruct this fragmented past. Without

my father's consistent observations, critical signs of deterioration - altered gait, reduced alertness, progressive incontinence, and behavioural shifts - went largely unmonitored in a stable home environment.

I moved into rented accommodation, sharing a house with a former school teacher. This transition marked the peak of my symptoms: incontinence and episodes of reduced consciousness reached their most frequent and severe levels, occurring in an unfamiliar environment without parental oversight. In retrospect, this isolation intensified the diagnostic delay as symptoms of advancing obstructive hydrocephalus and traumatic brain injury progressed unchecked.

External Intervention

Amid these compounding difficulties, I entered a period of sobriety. I recall one evening out with my mother when I was refused entry to a local establishment because the staff believed I was "too drunk". My mother contested this assessment, but I was still denied entry, reinforcing external perceptions of drug and alcohol misuse among those unfamiliar with the prolonged effects of my undiagnosed traumatic brain injury.

Not long into this phase, I stayed at my grandmother's house. She later recounted an incident on August 28, 2008 — 125 days before my eventual diagnosis — while I was preparing to attend the Reading Music Festival. My frequent trips to London for similar events had previously masked my deteriorating health, sustaining an illusion of normalcy. That day, however, my profound lethargy and disengagement prompted her frustration. She described sitting at the top of the stairs, head in hands, initially attributing my behaviour to substance abuse - a misinterpretation that echoes the social stigma often faced by young adults with undiagnosed neurological conditions[13;14].

On sharing this story, it rekindled a memory once lost to cognitive decline. To this day, others' recollections help reconstruct periods in which my sense of self had been erased. Her account triggered the vivid image of her sitting at the top of the stairs, head in hands, intensified by my physical and cognitive deterioration, reinforcing the prevailing interpretation of my symptoms as substance abuse[4–9].

She also recalled observing me walking "like an old man", a clear manifestation of motor decline, consistent with earlier adaptations I had made in response to severe headaches and hemiparesis. This observation marked a shift in her understanding of my symptoms as pathological rather than self-inflicted.

As physical adaptations progressed to reduce physical trauma, one key moment stands out. A friend, who played a vital role in facilitating my diagnosis, asked: "Why do you turn your whole body instead of your head?" I had unknowingly adopted this movement to avoid triggering uncontrollable pain, which was caused by even the slightest head movement. Like many others, they had initially attributed my appearances to substance abuse. However, they invited me to stay at their house for several days, to better understand what was happening. After caring and observing me closely, it became apparent that my symptoms were pathological, not self-inflicted.

Due to these symptoms, they first made a call to NHS 111. Because I was over 18 and not their son, operators insisted on only speaking to me - a practical impossibility given my reduced consciousness and alertness. Instead, a GP appointment was arranged. At the surgery, despite their efforts to support thorough assessment, we were told they were unable to accompany me to the consultation. Inadequate evaluations continued.

During this period I was diagnosed as depressed alongside my incontinence. Due to my excessive sleeping, clinicians planned to increase my antidepressant dosage, overlooking other key presentations of gait change, incontinence, reduced alertness and cognitive decline[10;11;15;16]. I have no personal recollection of these events, only third-party accounts. The family later told me that they tried to convince my father that it was pathological, not caused by drug abuse. He dismissed, insisting I was simply "stoned". Their struggle, like my own, prolonged the misdiagnosis. My mother recounted that they were taking each of these core symptoms in isolation, not as an interconnected whole.

Work

Due to my worsening executive decline, I was moved from the bakery to checkouts at ASDA in July/August 2008. This was intended to provide more support and care in a stricter, more supervised environment. My

employers were aware of my personal circumstances, including being forced to leave my family home, and tried to support me as much as possible during this period of physical, emotional, and social instability.

This also coincided with incontinence reaching its worst. I would have little to no control and frequently wet myself in front of colleagues and the general public whilst working. This resulted in profound psychological distress, shame, and social humiliation. Being 18-19 years old and unable to control such simple functions represents one of the most psychologically distressing periods of my life, further exacerbating my frustrations with local healthcare.

Father Witnessing Gait Disturbances

I am told there was a period when I had not seen my father for some time - a separation that made my decline more noticeable to him. Walking home from the working men's club, of which we were both members, he became frustrated with my slow speed and abnormal movements, shouting at me for it. This incident occurred when he also became angry with me because my cognitive decline led to me being unable to attend college.

In retrospect, his frustration, initially directed at perceived laziness and defiance, further masked with the suspected ideology of my drug abuse, marked the point at which he realised something was wrong. This visible gait disturbance, a classic manifestation of advancing obstructive hydrocephalus and ventriculomegaly, finally began to challenge the long-held suspicions of substance abuse[5;6;11;16].

Christmas

December marked a turning point. Multiple GP appointments revealed normal reflexes but persistent numbness to the right-hand side of my body. On the 15th December, a tentative diagnosis of schizoaffective disorder or multiple sclerosis was made, prompting a referral to Neurology. The doctor, finally acknowledging that my condition was not as simple as previously thought, suggested, "Let me have my Christmas," with an appointment scheduled for the new year. In retrospect, I would not have survived that long. I am told that my father began to intervene. He called my sister, asking "What's wrong with Ben?". She explained my symptoms, and the delayed plan.
My last clear memory is of his phone call:

> "Ben, something's wrong. Pack a bag, I'm taking you to hospital."

That was it.

Following initial assessment, I was deemed medically stable and ready for discharge, prescribed paracetamol. Only when my father insisted on a more thorough examination was a scan performed, revealing severe ventriculomegaly. I was subsequently transferred to the Royal Free Hospital, diagnosed with obstructive hydrocephalus secondary to tectal glioma. My first ventriculoperitoneal (VP) shunt was fitted urgently. Clinical accounts indicate that without urgent intervention, paralysis was imminent and mortality highly likely within days.

Diagnostic imaging

Figure 1 - 5 demonstrate the overview of MRI findings in chronic obstructive hydrocephalus secondary to tectal glioma, including pre- and post-shunting images and the tectal lesion (2008-2018).

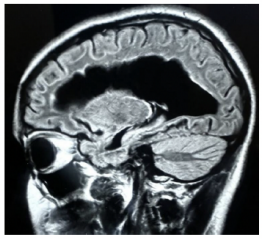

Figure 1.Sagittal T1-weighted MRI (2008, pre-shunting) showing severe ventriculomegaly, thinned corpus callosum, and tonsillar herniation.

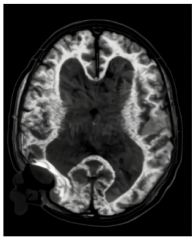

Figure 2. Coronal T2-weighted MRI (2008, pre shunting) showing persistent severe ventriculomegaly

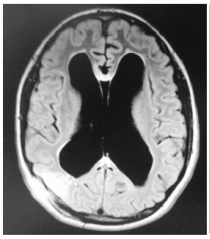

Figure 3. T1-weighted axial MRI (2009, post shunting) demonstrating ventriculomegaly post shunting

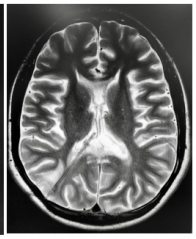

Figure 4. T2-weighted axial MRI (2017) showing VP shunt in situ.

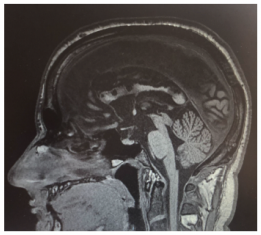

Figure 5. T1 sagittal MRI (2018) revealing tectal glioma.

Hakim's Triad in Retrospective Context

Hakim's triad, comprising gait disturbances, urinary incontinence, and cognitive decline, is widely recognised as classic presentations of normal-pressure hydrocephalus [17;18]. Given my obstructive hydrocephalus secondary to tectal glioma, with elevated rather than normal pressure, the triad's components are dramatically evident throughout my prolonged neurological decline, yet consistently overlooked as symptoms were not considered collectively [19;20].

Gait disturbances, progressing from subtle adaptation, such as turning my whole body instead of my head to avoid triggering unbearable pain, to overt physical and cognitive abnormality observed by vital individuals in my eventual diagnosis. Urinary incontinence emerged as frequent and uncontrollable episodes, causing profound shame and isolation. Cognitive impairment manifested in memory loss, executive and academic decline, reduced alertness, and unpredictable dips in consciousness, deteriorating daily functioning and self-identity.

This triad is typically associated with older adults, where gait issues closely resemble Parkinson's disease, often linked to nerve damage in the substantia nigra. In younger patients, the combination of these symptoms is less likely to prompt neurological investigation, exacerbating the misattribution to substance abuse, psychiatric conditions, or behavioural issues, due to age-based stigma [20].

Multiple sclerosis was considered during later GP appointments due to focal sensory symptoms and gait disturbances. However, unlike multiple sclerosis, obstructive hydrocephalus is characterised by progressive ventriculomegaly, with fluctuating consciousness, early urinary incontinence, and gait change. These features were retrospectively evident but not synthesised. This distinction underscores the critical role of neuroimaging in differentiating between the two conditions, highlighting how its absence contributed to delayed intervention [21–23].

By removing the age-based stigma from consideration of Hakim's triad, clinicians could achieve more accurate, holistic assessments, capturing interconnecting presenting impacts, for faster diagnosis and treatment. With this in consideration, such a shift would reduce the long-term consequences of undiagnosed obstructive hydrocephalus and resulting traumatic brain injury, improve quality of life, and prevent fatalities associated with delayed intervention. It highlights the importance of extending medical assessment to a broader age range and recognising similarities to other symptomatic illnesses. This retrospective alignment with Hakim's triad components is further evidenced by clinical records summarised in Table 1, illustrating the progressive escalation of symptoms and repeated misattributions prior to diagnosis.

Table 1: Clinical Timeline of Key Events and Interventions (2008), Reconstructed from Medical Records

Date	**Location**	**Comments**
8th Feb	GP Surgery	Tired all the time – denies symptoms of depression, comes over quite anxious, discussed options, check FBC and glucose.
19th Feb	GP Surgery	Laboratory investigations otherwise normal, aside from mild isolated unconjugated hyperbilirubinaemia (total bilirubin 37 μmol/L) and borderline hypokalaemia (3.5 mmol/L). Thyroid function test unknown.
16th Jul	GP Surgery	Two weeks off work for depression. Rebound mood swings, low mood, personal problems at home, living with father, PHQ-9 = 19. Plan: start sertraline, review in 4 weeks.
31st Jul	GP Surgery	Depressed – much better, fit to return to work, aim to treat for 4 months.
21st Nov	GP Surgery	Depressed mood again. Sleep poor. Studying and working. Will try different antidepressant. Plans to move back home with father (feels moving out had bad effect). Rx: citalopram 10 mg daily. See in 1 week.
15th Dec	GP Surgery	History: numbness of right side of body, had a "collapse" a few days ago at work and was sent home. Not taking SSRIs (only took a few days' worth). Feeling tired all the time. Examination: normal plantar, knee, thigh adductor and biceps reflexes (all brisk), normal soft touch sensation on both feet (symmetrical). Diagnosis: ?schizoaffective personality ?MS. Plan: check bloods including fasting glucose, refer neurology.
18th Dec	GP Surgery	Full blood count, renal function, electrolytes, serum calcium (corrected for albumin), bone profile, liver function tests, and thyroid function within normal limits, except for mild isolated unconjugated hyperbilirubinaemia (total bilirubin 37 μmol/L) and borderline low potassium (3.5 mmol/L).
21st Dec	Ambulance Service	Patient fell in street, struck head, was conscious throughout, vital signs normal. Lives alone but will stay with parents temporarily. Advised to call emergency services if any further collapse or loss of consciousness occurs. Refused conveyance.
23rd Dec	GP Surgery	History: collapse (seems to have occurred more than once ?seizure – no witness), bedwetting and frequency of urination, odd gait, sleeping a lot, dark urine. Examination: odd gait noted, slightly odd affect, fundi normal. Plan: reassess, ?early MS – consider referral. Odd social history – used to live with father but now rents; has been staying with mother recently who accompanied him today.
27th–30th Dec	A&E → Royal Free Hospital	A&E admission for falls. CT head initially planned as outpatient, but performed as inpatient following father's intervention. Hydrocephalus diagnosed. Ventriculoperitoneal shunt inserted 30th Dec 2008.

These documented encounters reveal a pattern of psychiatric framing and incomplete assessment, delaying neuroimaging that ultimately revealed severe ventriculomegaly and underlying tectal glioma.

Conclusion

Through autoethnography, this study exposes that limited medical observations focusing on single symptoms rather than considering them collectively may lead to fatal consequences. It also advocates for introducing third-party accounts when cognitive symptoms limit self-presentation. It exposes the consequential effects of age-based stigma and prolonged diagnostics in overshadowing neurological symptoms in younger patients.

Hakim's triad, gait disturbances, urinary incontinence, and cognitive decline—a framework for diagnosis in elderly patients with normal pressure hydrocephalus, can be effectively extended to younger populations. This shift would reduce age-based misattributions such as substance abuse, leading to fewer fatalities and long-term consequences of traumatic brain injury.

Earlier use of neuroimaging, alongside more holistic clinical assessment, would improve diagnostic accuracy. This would help prevent the severe physical and psychological impacts of prolonged undiagnosed hydrocephalus in younger patients with this rare but highly treatable condition.

Through this grounded lived experience, this narrative challenges reductive biomedical assumptions, advocating for empathetic, inclusive care, ensuring no young person endures such prolonged diagnostic failure.

References

[1] Leon Anderson. Analytic autoethnography. *Journal of Contemporary Ethnography*, 35(4):373–395, 2006.

[2] Carolyn Ellis, Tony E. Adams, and Arthur P. Bochner. Autoethnography: An overview. *Forum: Qualitative Social Research*, 12(1):Art. 10, 2011.

[3] Children's Commissioner for England. Childhood vulnerability and substance misuse: the extent and impact of substance misuse on children and families in england. Technical report, Children's Commissioner, London, 2017.

[4] Lawrence H. Yang, Lye Y. Wong, Margaux M. Grivel, and Deborah S. Hasin. Stigma and substance use disorders: an international phenomenon. *Current Opinion in Psychiatry*, 30(5):378–388, September 2017. doi: 10.1097/YCO.0000000000000351.

[5] R. Hammarlund, K. A. Crapanzano, L. Luce, L. Mulligan, and K. M. Ward. Review of the effects of self-stigma and perceived social stigma on the treatment-seeking decisions of individuals with drug- and alcohol-use disorders. *Substance Abuse and Rehabilitation*, 9:115–136, November 2018. doi: 10.2147/SAR.S183256.

[6] Jenna Zwick, Hannah Appleseth, and Stephan Arndt. Stigma: how it affects the substance use disorder patient. *Substance Abuse Treatment, Prevention, and Policy*, 15(1):50, July 2020. doi: 10.1186/s13011-020-00288-0.

[7] Stephen E. Lankenau, Michelle Teti, Kaitlin Silva, Julia Jackson Bloom, Alex Harocopos, and Megan Treese. Initiation into prescription opioid misuse amongst young injection drug users. *International Journal of Drug Policy*, 23(1):37–44, January 2012. doi: 10.1016/j.drugpo.2011.05.014. Epub 2011 Jun 20.

[8] Emma E. McGinty and Colleen L. Barry. Stigma reduction to combat the addiction crisis – developing an evidence base. *New England Journal of Medicine*, 382(14):1291–1292, April 2020. doi: 10.1056/NEJMp2000227.

[9] Joy Bielenberg, Gabrielle Swisher, Anna Lembke, and Nancy A. Haug. A systematic review of stigma interventions for providers who treat patients with substance use disorders. *Journal of Substance Abuse Treatment*, 131:108486, December 2021. doi: 10.1016/j.jsat.2021.108486. Epub 2021 May 25.

[10] S. Jones, L. Howard, and G. Thornicroft. Diagnostic overshadowing: worse physical health care for people with mental illness. *Acta Psychiatrica Scandinavica*, 118(3):169–171, September 2008. doi: 10.1111/j.1600-0447.2008.01211.x.

[11] Guy Shefer, Claire Henderson, Louise M. Howard, Joanna Murray, and Graham Thornicroft. Diagnostic overshadowing and other challenges involved in the diagnostic process of patients with mental illness who present in emergency departments with physical symptoms – a qualitative study. *PLoS ONE*, 9 (11):e111682, November 2014. doi: 10.1371/journal.pone.0111682.

[12] P. A. Ali, R. Watson, and K. Dhingra. Diagnostic overshadowing in people with mental illness and physical symptoms: a qualitative study. *British Journal of General Practice*, 71(704):e179–e186, 2021.

[13] James D. Livingston, Terre Milne, Mei Lin Fang, and Erica Amari. The effectiveness of interventions for reducing stigma related to substance use disorders: a systematic review. *Addiction*, 107(1):39–50, January 2012. doi: 10.1111/j.1360-0443.2011.03601.x. Epub 2011 Oct 12.

[14] Patrick W. Corrigan, Georg Schomerus, Valery Shuman, Dana Kraus, Debbie Perlick, Annie Harnish, Magdalena Kulesza, Kathleen Kane-Willis, Sang Qin, and David Smelson. Developing a research agenda for reducing the stigma of addictions, part ii: Lessons from the mental health stigma literature. *The American Journal on Addictions*, 26(1):67–74, January 2017. doi: 10.1111/ajad.12436. Epub 2016 Nov 22.

[15] Ben Houghton, Adam Bailey, Christos Kouimtsidis, Theodora Duka, and Caitlin Notley. Perspectives of drug treatment and mental health professionals towards treatment provision for substance use disorders with coexisting mental health problems in england. *Drugs and Alcohol Today*, 21(4):297–308, 2021.

[16] Claire Henderson, Jo Noblett, Hannah Parke, Sarah Clement, Athanasia Caffrey, Oliver Gale-Grant, Beate Schulze, Benjamin Druss, and Graham Thornicroft. Mental health-related stigma in health care and mental health-care settings. *The Lancet Psychiatry*, 1(6):467–482, November 2014. doi: 10.1016/S2215-0366(14)00023-6. Epub 2014 Nov 5.

[17] S. Hakim and R. D. Adams. The special clinical problem of symptomatic hydrocephalus with normal cerebrospinal fluid pressure. observations on cerebrospinal fluid hydrodynamics. *Journal of the Neurological Sciences*, 2(4):307–327, July–August 1965. doi: 10.1016/0022-510x(65)90016-x.

[18] R. D. Adams, C. M. Fisher, S. Hakim, R. G. Ojemann, and W. H. Sweet. Symptomatic occult hydrocephalus with "normal" cerebrospinal-fluid pressure. a treatable syndrome. *New England Journal of Medicine*, 273:117–126, July 15 1965. doi: 10.1056/NEJM196507152730301.

[19] Harold L. Rekate. A contemporary definition and classification of hydrocephalus. *Seminars in Pediatric Neurology*, 16(1):9–15, March 2009. doi: 10.1016/j.spen.2009.01.002.

[20] Michael Kiefer and Andreas Unterberg. The differential diagnosis and treatment of normal-pressure hydrocephalus. *Deutsches Ärzteblatt International*, 109(1-2):15–25; quiz 26, January 2012. doi: 10.3238/arztebl.2012.0015. Epub 2012 Jan 9.

[21] MSD Manuals. Multiple sclerosis (ms). `https://www.msdmanuals.com/en-gb/professional/neurologic-disorders/demyelinating-disorders/multiple-sclerosis-ms`, 2026. [cited 2026 Jan 27].

[22] Norman Relkin, Anthony Marmarou, Petra Klinge, Marvin Bergsneider, and Peter McL. Black. Diagnosis and management of normal-pressure hydrocephalus. *Journal of Neurosurgery*, 102(5):830–841, 2005. doi: 10.3171/jns.2005.102.5.0830.

[23] María A. Poca, María Mataró, and Juan Sahuquillo. Neuroimaging in hydrocephalus and differential diagnosis. *Neurología (English Edition)*, 31(7):437–445, 2016. doi: 10.1016/j.nrleng.2015.11.002.