British Journal of Dermatology (1994) **131**, 598–607.

REVIEW

Human cowpox 1969–93: a review based on 54 cases

D.BAXBY,*† M.BENNETT*‡ AND B.GETTY*

*Departments of *Medical Microbiology and ‡Veterinary Clinical Science, Liverpool University, PO Box 147, Liverpool L69 3BX, U.K.*
†Alder Hey Childrens Hospital NHS Trust, Liverpool, U.K.

Accepted for publication 24 June 1994

Summary This survey of the clinical and epidemiological features of human cowpox, a rare but relatively severe zoonotic infection, is based on 54 cases, many unpublished, which we have studied since 1969. Patients present with painful, haemorrhagic pustules or black eschars, usually on the hand or face, accompanied by oedema, erythema, lymphadenopathy, and systemic involvement. Severe, occasionally fatal, cases occur in eczematous and immunosuppressed individuals, although cowpox has not yet been reported in anyone infected with the human immunodeficiency virus. Variations in the clinical features are described, and the differential clinical diagnosis of cowpox, parapox, herpes virus, and anthrax infections is discussed. The role of the laboratory in diagnosis is described, and the value of electron microscopy in providing rapid confirmation is emphasized. Care in taking a detailed history will assist in the initial clinical diagnosis, and a history of contact with domestic cats, particularly during July–October, is important. The possible influence of smallpox vaccination on the incidence and severity is discussed and discounted.

Cowpox is of interest because of increasing knowledge of its epidemiology, and its association with Edward Jenner and smallpox vaccination. Human cowpox is a zoonosis but, despite its name, cows are involved only rarely. The most commonly detected source of human infection is the domestic cat, and the virus is probably maintained in wild rodent populations.[1–4] Human cowpox is relatively rare and, although most, if not all, British cases are reported to the public health authorities, cases are usually published only if they are of epidemiological interest or they are severe. This last feature may obscure the spectrum of clinical features represented by the majority of unpublished cases.

Reviews of cowpox have provided relatively little clinical information,[1–7] and perhaps because of lack of familiarity with the clinical features, human cowpox is often diagnosed late.

This review is based on 54 cases investigated since 1969, when one of us (D.B.) became interested in human cowpox. They represent most, if not all, of the British cases, data on three cases from Germany,[8–11] and two each from Belgium,[12–13] Sweden,[14] and France.[15] Of these cases, 13 have been published as illustrated case reports,[8–11,14–23] and six as short summaries,[12,13,24–26] Very brief details of nine others were included in an epidemiological survey,[1] but the remaining 26 are unpublished. Where necessary, additional information on cases with which we were not involved was obtained from the investigators concerned.

Clinical features

Site and number of lesions

Cowpox is acquired by implantation of virus into broken skin. Fingers and hands are most commonly affected; lesions were found only on the hands in 25 cases (48%). The face is also commonly affected, and lesions occurred only on this site in 18 cases (33%). Lesions rarely occurred elsewhere (Table 1). The preponderance of males aged 12–18 years with facial lesions is of interest (Table 1), but is unexplained.

Primary infection at sites other than the hands usually depends on transfer of virus from unbroken skin on contaminated hands to sites where the skin is already broken at the time of transfer. However, it is possible that some facial infections may be acquired directly from cats with active lesions.

Of the cases surveyed, 39 (72%) had only one lesion. Perhaps surprisingly, only one patient, a young girl,

Table 1. Human cowpox; location of lesions in relation to age and sex of patient (54 cases, 1969–93)

	Total		Age (years)					
			< 12		12–18		> 18	
Location of lesion	M	F	M	F	M	F	M	F
Hand only*	10	15	2	5	0	2	8	8
Face only	10	8	1	3	4	2	5	3
Hand and face	0	1	0	1	0	0	0	0
Face and misc.†	1	1	0	0	0	1	1	0
Misc. only‡	2	3	0	2	0	0	2	1
Generalized	3	0	0	0	2	0	1	0
	26	28	3	11	6	5	17	12
Total	54		14		11		29	

* Includes wrist.
† Misc. = chest (1 × M > 18), shoulder and foot (1 × F12).
‡ Misc. = knee and elbow (1 × F6, shoulder (1 × F < 12, 1 × M > 18), arm (1 × M > 18), anogenital (1 × F > 18).

had lesions on the hand and face (Table 1). Additional lesions may be co-primaries due to multiple initial inoculation, not necessarily at adjacent sites (e.g. different hands), or occasional secondary lesions due to accidental transfer from a developing primary lesion (e.g. hand to face), or via lymphatic spread. This last category includes a rare sporotrichoid distribution of facial lesions,[19] and three generalized infections.[9–11,21]

The normal course of infection

There is some variation in what might be regarded as the 'normal' course of infection, and mild cases misdiagnosed as bacterial infection and treated 'successfully' with antibiotics may go unrecognized.

The typical lesion starts as an inflamed macule and, over a period of 7–12 days, passes through papular and vesicular stages. It is unlikely that a patient will present whilst the primary lesion is at such an early stage. However, development of vesicles may be seen in secondary lesions, which occasionally occur (Fig. 1). The vesicle becomes pale blue–purple, and increasingly haemorrhagic (Fig. 2). It evolves via a pustule, which is usually bacteriologically sterile, and begins to ulcerate and crust over by the end of the second week. Usually, 2–3 weeks have elapsed before patients are seen at referral clinics. By this time, the lesion will have progressed to a deep-seated, hard, black eschar 1–3 cm in diameter (Figs 1, 3 and 4), and secondary lesions will be present if they are going to develop (Fig. 1). There is usually oedema (Figs 2 and 3), and

Figure 1. Primary and secondary lesions of cowpox; the former at the early eschar stage, the latter at the early vesicular stage. (From a colour transparency kindly supplied by Dr M.White.)

sometimes induration, occasionally described as 'woody'.[20]

The degree of inflammation varies. In some cases there is little or none around the lesion (Fig. 3). In others, inflammation is more obvious (Figs 1 and 4), and sometimes takes the form of a sharply delineated area of erythema (Fig. 2), up to four times the diameter of the

Figure 2. Cowpox at the late vesicular stage, showing a haemorrhagic lesion, with marked oedema and erythema. (From a colour transparency kindly supplied by the late Mr J.McNae. Baxby D, *Brist Med Chirurg J* 1982; **97**: 12. Reproduced with permission.)[2]

Figure 3. Cowpox lesions at the early eschar stage, showing oedema but little obvious inflammation. (From a colour transparency kindly supplied by Dr M.S.Lewis-Jones.)

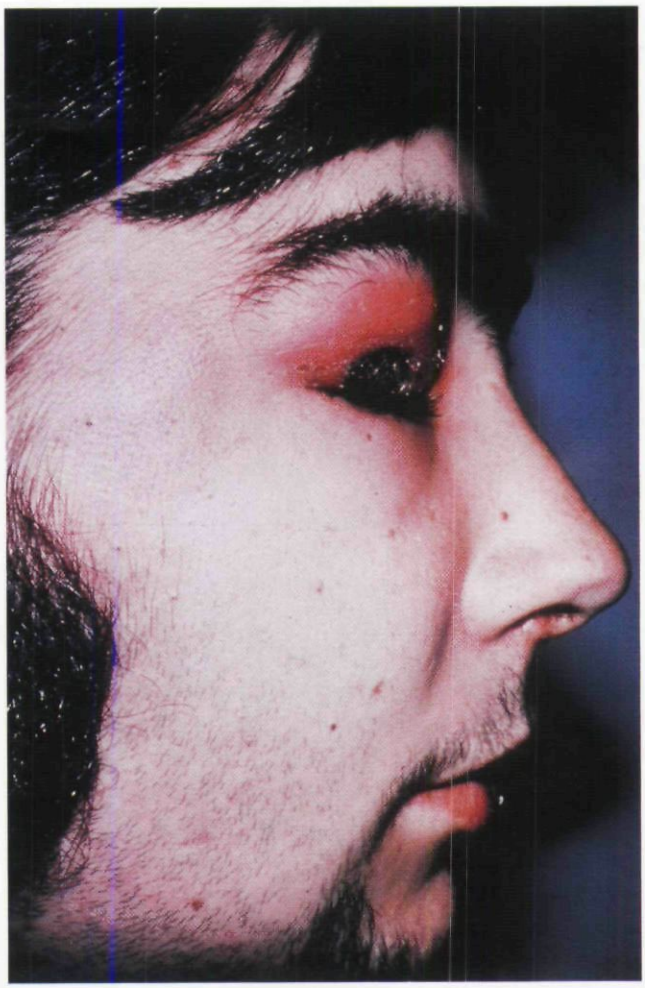

Figure 4. Cowpox lesion at the late eschar stage, showing the hard black eschar and conspicuous inflammation. (From a colour transparency kindly supplied by Dr P.Higgins, Bristol Public Health Laboratory.)

lesion. The inflammation is not necessarily associated with secondary bacterial infection. Such infections rarely occur, possibly because antibiotics are often prescribed at an early stage. The lesion is invariably painful, sometimes extremely so, and there is local lymphadenopathy. The latter is often marked, and sometimes prolonged.

Most patients report some systemic symptoms even though the infection itself usually remains localized. The systemic involvement includes pyrexia, malaise, lethargy, and occasionally vomiting and sore throat. Some reports refer specifically to an 'influenza-like illness'.[16,17,19] The systemic illness may last 3–10 days, but usually resolves as the eschar stage is reached.

The time taken for complete recovery varies. Although some cases heal in 3–4 weeks[8,13,15,19,25] the majority take 6–8 weeks, and in others, complete healing with separation of scabs may take 10–12 weeks or longer.[18,22,23] Induration and residual inflammation may persist after the scab has separated. Scarring is common, and may be permanent.

Ocular infection

Excluding the three generalized infections discussed below, 21 patients (39%) had facial lesions, and nine of these involved the eyelid (Fig. 4). Attention has been focused specifically on ocular infections in some reports,[17,22,23,26] and others have described ocular lesions in patients who also had lesions elsewhere.[11,14,19] Inflammation, periorbital oedema, and lymphadenopathy occurred in all cases, conjunctivitis in four[11,14,22,23,26] (Fig. 5), and corneal involvement in one.[22,23] In two cases there was no systemic involvement

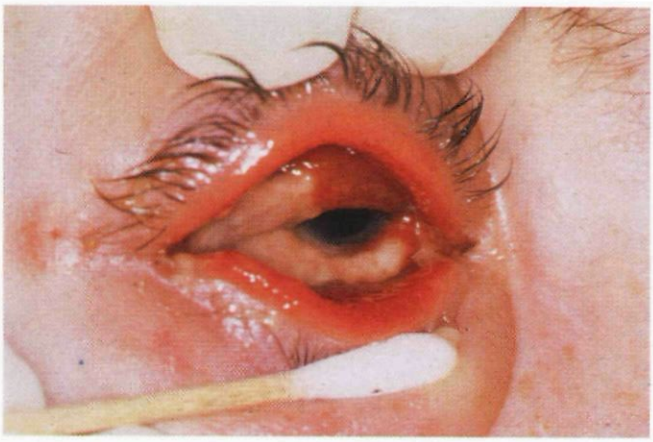

Figure 5. Ocular cowpox showing conjunctivitis. (From a colour transparency kindly supplied by Dr J.Cronqvist. (Cronqvist J *et al. Lakartidningen* 1991; **88:** 2605. Reproduced with permission.)[14]

even though lymphadenopathy persisted for 10–12 weeks.[22,23,26] All recovered uneventfully, although superficial corneal haze persisted for 9 months in one case.[23]

Severe infections

The definition of 'severe' is subjective. Some of the cases discussed above could be considered as severe, but we regard them as illustrating the spectrum of normal infection in otherwise healthy individuals. However, three severe cases have been reported; all were generalized infections,[11,20] and one of them was fatal.[9,10] In two cases, risk factors which would have contraindicated smallpox vaccination probably exacerbated cowpox. These were atopic dermatitis and allergic asthma requiring steroid therapy in one case,[9,10] and atopic eczema treated occasionally with topical steroids in the other.[11] The third patient had a history of hayfever.[20] Despite the risk factors and generalized lesions, two patients recovered quickly and uneventfully.[11,20] In the fatal case, the illness was more severe, but death was due to heart failure. No viral involvement of internal organs was detected, and it is not known to what extent the infection contributed to the outcome.[9,10]

Three other serious cowpox infections have been reported from Europe, outside the time-scale of this survey. These were two generalized cases, one of them fatal, in eczematous patients, and a fatal case of encephalitis.[27]

Diagnosis

The key to early accurate diagnosis is to consider cowpox sooner rather than later, and to be aware of epidemiological indicators and the value of electron microscopy in diagnosis. Cowpox should be considered in anyone presenting with a painful haemorrhagic vesicle or black eschar, with or without erythema, accompanied by lymphadenopathy and a systemic illness. This applies particularly to patients seen in July–October, and/or who have had contact with cats (see below). Attempts to relate cases to contact with cows may be counter-productive. If appropriate laboratory facilities are available where the patient is seen, advice about diagnostic methods should be sought. If not, vesicle fluid allowed to dry on microscope slides, or dried scabs, should be sent to the laboratory by first-class post. Serum samples for antibody detection become more useful in the later acute stage, and are essential if a diagnosis is to be made after the scabs have separated.

Differential clinical diagnosis

In the patients in our survey, cowpox was rarely diagnosed clinically, and laboratory studies were required to establish the diagnosis rather than to confirm a clinical diagnosis. Some cases were diagnosed clinically as parapox (13 cases), herpes virus infection (five cases) or anthrax (nine cases).

Human parapox infections are usually acquired from cows (paravaccinia, pseudocowpox) and sheep (orf, contagious ecthyma). They are clinically similar, and generally reported as orf/paravaccinia if the animal source is unknown. Lesions may present as a characteristic 'target' form (Fig. 6) during the second week,[28,29] but later may progress to a lesion which in some cases is

Figure 6. Parapox infection at the 'target' stage. (From a colour transparency kindly supplied by Dr J.Nagington. Baxby D, *Brist Med Chirurg J* 1982; **97:** 12. Reproduced with permission.)[2]

Figure 7. Parapox infection, showing a crusting lesion similar to that of cowpox illustrated in Figure 2. (From a colour transparency kindly supplied by Dr M.S.Lewis-Jones.)

similar to cowpox (Fig. 7). They are usually more granulomatous than those of cowpox, and true vesicles are not produced. Characteristically, the lesions are usually not painful, and inflammation, lymphadenopathy and systemic reactions are uncommon.[28,29]

The history should suggest a diagnosis of herpes virus reactivation. Primary and reactivated herpes virus lesions are not usually as haemorrhagic or erythematous as those of cowpox (Fig. 8), and the scab is a lighter colour and not so deep-seated. Generalized cowpox has been diagnosed as eczema herpeticum,[9,10,21] and localized cowpox with multiple lesions as Kaposi's varicelliform eruption.[15]

Figure 8. Herpetic whitlow; reactivation at the vesicular stage. (From a colour transparency kindly supplied by Dr E.Rees.)

Figure 9. Anthrax, showing the hard black eschar and inflammation. (From a colour transparency kindly supplied by Dr R.T.D.Emond. Emond RTD *Infectious Diseases*. Recom Verlag, 1981. Reproduced with permission.)[30]

We have no experience of anthrax, which is now very rare in Britain. The typical black eschar,[30,31] (Fig. 9) is similar to that of cowpox. Apparently, the main clinical features which would assist in differentiating between these conditions are that the anthrax lesion is relatively painless, and progresses more rapidly to the eschar stage (5–6 days).

Other clinical diagnoses included mumps in a patient with a stye,[17] mycobacterial inoculation,[19] accidental vaccinia, and 'granuloma'. In a surprising number of cases no clinical diagnosis was made. Despite variation in the clinical picture of cowpox there are probably sufficient features which, together with an adequate history, should suggest the diagnosis more often and earlier than usually occurs.

Laboratory diagnosis

Cowpox virus is an orthopoxvirus, i.e. antigenically related to smallpox, vaccinia, monkeypox and camelpox viruses.[4] It has a wide natural host range, including the domestic cat, and this contributes to its complex epidemiology.[3,4] Not all isolates of cowpox virus are identical, and minor differences in their laboratory characteristics may permit precise identification for epidemiological purposes.[3,4,32] Such differences do not affect recognition of the virus or correlate with the severity of infection, and so do not

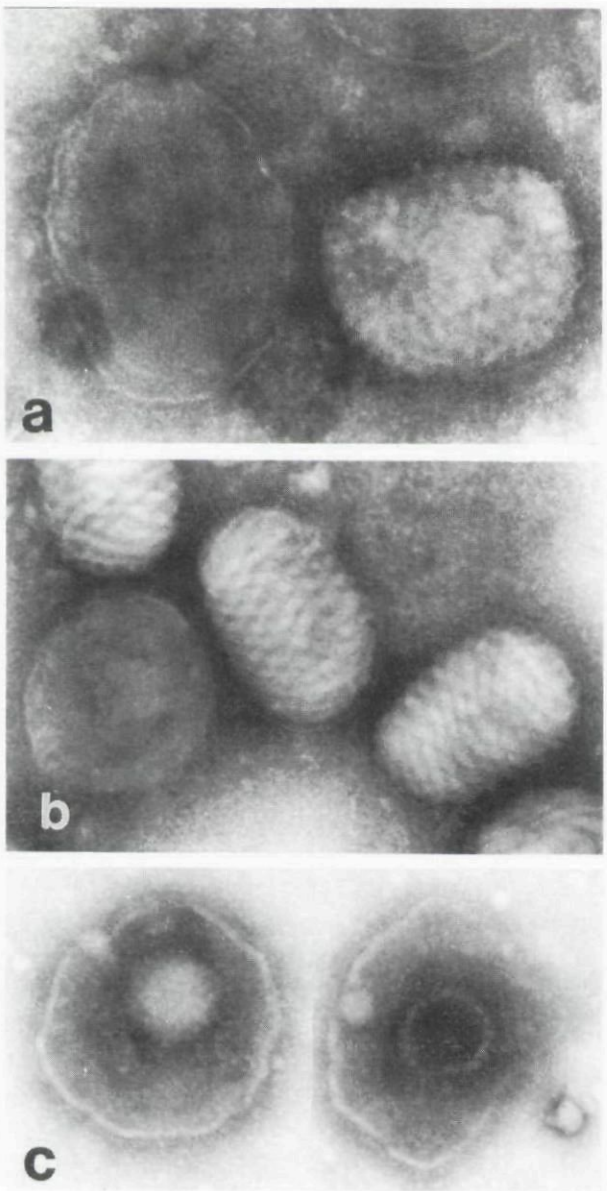

Figure 10. Electron micrographs of (a) cowpox virus, showing the mulberry form [M] with conspicuous but short, randomly arranged surface tubules, and capsule form [C] with deeper stain penetration. (b) M and C forms of parapox virus, showing the characteristic long spiralling of the surface tubules of the former. (c) Enveloped herpes viruses, showing one particle with intact nucleocapsid, and one broken, allowing stain penetration (phosphotungstic acid ×120,000).

influence the management of cases. An important point is that cowpox virus is morphologically and antigenically distinct from parapoxviruses, which cause the infections considered above in the differential clinical diagnosis.

Electron microscopy of vesicle fluid or scab extracts is a most useful method for investigating viral skin infections. Expert operators can report on positive specimens within an hour and can differentiate cowpox, parapox and herpes viruses (Fig. 10). On more than one occasion we have made a positive diagnosis of cowpox, subsequently confirmed by virus isolation, by the recognition of one characteristic virus particle. Unfortunately, this technique was used in only 24 cases. Of these 22 (92%) were reported as positive initially, one was reassessed as positive by a more experienced operator,[20] and the other was confirmed as cowpox by serological studies.[18] Strictly speaking, cowpox cannot be diagnosed by electron microscopy alone, because all orthopox and molluscum viruses are morphologically indistinguishable. However, when considered together with clinical and epidemiological data a definitive diagnosis of cowpox is virtually certain.

Cowpox virus can usually be isolated by routine virology laboratories, but isolation is less successful from older lesions. Identification of cowpox virus isolated in cell culture may present problems for non-specialist laboratories, and will require results from a combination of techniques. If suitable equipment is available, the simplest and most rapid technique is the recognition of virus of appropriate morphology by electron microscopy of cell extracts. Cytoplasmic inclusions may be detected by histology using light or electron microscopy (see below). Cowpox virus produces characteristically haemorrhagic pocks on the chick chorioallantoic membrane. However, this technique is now less widely available, and may still require confirmation by other means. Serological tests to detect virus or virus antigens require suitable antisera. These are not produced commercially, but may be available from virus reference or research laboratories, which may also agree to carry out the tests.

Detection of antibody will confirm the diagnosis in cases where virus detection fails, or in cases seen after the scab has separated. However, such tests are increasingly unlikely to be available in routine laboratories. Of the cases surveyed, five (only one published[18]) were diagnosed in this way. Because of close antigenic relationships, routine serology will not distinguish between cowpox and other orthopoxviruses, but here again clinical and epidemiological evidence will aid appropriate diagnoses. Residual antibody in individuals previously vaccinated or infected should not cause confusion, because haemagglutination-inhibition[33] and specific IgM tests[9–11,18] will confirm recent infection.

Histopathology, using light or electron microscopy, has occasionally been attempted on biopsy material. Cowpox virus produces characteristic cytoplasmic inclusions, which have been detected in infected feline tissues (Fig. 11),[34,35] but they were not seen in the few

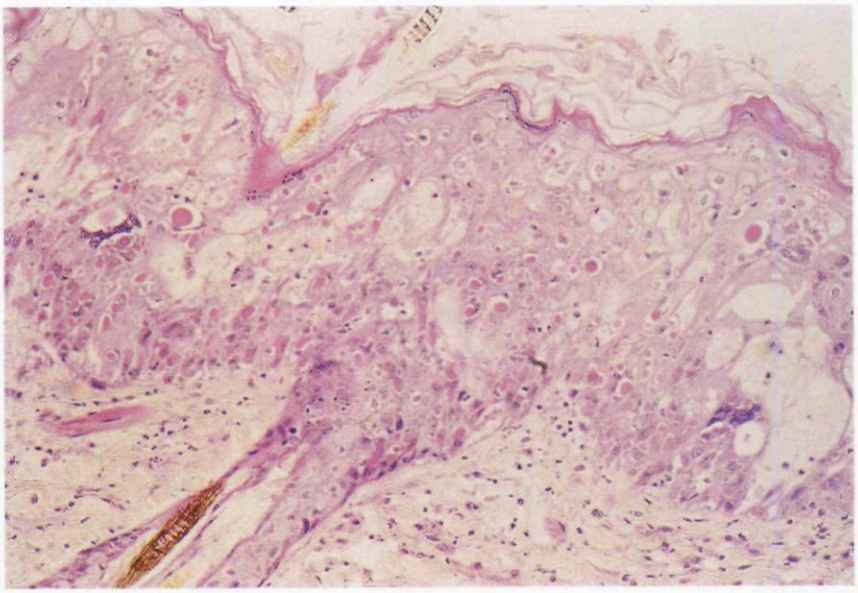

Figure 11. Section of cowpox-infected cat skin, showing conspicuous intracytoplasmic inclusions (haematoxylin and eosin ×250).

human specimens examined.[15,19,23] However, recognition of such inclusions in human infection would be pathognomonic for cowpox. Detection of cowpox antigens in biopsy material by immunohistopathology has not been reported for human cases, but has proved of value in feline cases.[35]

Management

Following confirmation of a diagnosis of cowpox, management in most cases is supportive. However, as explained above, in many cases no clinical diagnosis was made, and in the remainder treatment was usually started before the diagnosis was confirmed. This explains the widespread use of antibiotics and occasional use of acyclovir.[21,26] The latter, however, is not effective against poxviruses. Steroids are contraindicated, and may exacerbate the illness.[16] Antivaccinia gammaglobulin has been used with some success in two cases, only one of which has been published,[9,10] and if available may be used for severe cases. Idoxuridine has been used to treat parapoxvirus infections,[36] but not cowpox; one might expect it to have some effect if used early.

It is common for affected individuals to be absent from school or work, and to require bed rest, and 16 patients, nine of whom were under 18 years, were admitted to hospital for periods ranging from 3 to 24 days. A possibly subjective view is that infection in children is perceived to be more severe than in adults. Minor surgical intervention has been used to drain pus (usually bacteriologically sterile),[11,24] remove eschars and dress underlying tissue,[18,20] or aspirate lymph nodes.[16] If performed too early such procedures may prolong the infection.[11]

Patients should be counselled on the risks of autoinoculation and spread of infection to contacts. It is difficult to assess the value of such advice, but secondary lesions are uncommon (Table 1) and person-to-person transmission has not been reported. This suggests that the virus may be of low infectivity for humans. Second attacks are theoretically possible, and have been noted anecdotally in the early literature.[37] However, we know of no confirmed case, and laboratory confirmation of both episodes would be required to validate such an occurrence.

Epidemiology

Studies on the epidemiology of cowpox during the survey period have provided interesting information, in particular on possible reservoir hosts and the role of the domestic cat as an important source of human infection.

Sources

Cowpox has only been detected in Britain and mainland Europe, including Russia and some adjacent States.[3,4] Cases in Britain have been detected from Scotland to south-west England, mostly in rural areas, but there have not been any reports of cowpox from Ireland. Bovine cowpox has always been rare, and studies in the 1970s showed that cowpox virus did not circulate amongst cattle.[1,2] The alternative suggestion that the

Table 2. Source of human cowpox (54 cases 1969–93)

	Total		1969–77		1978–84*		1985–93†	
Source	M	F	M	F	M	F	M	F
Unknown	12	14	2‡	5‡	4‡	5‡	6	4
Bovine	3	0	3	0	0	0	0	0
Occupational§	3	2	1	1	0	0	2	1
Feline	6	8	0	0	0	0	6	8
Feline?¶	1	3	0	0	0	0	1	3
Rodent?¶	1	1	0	0	0	0	1	1
	26	28	6	6	4	5	16	17
Total	54		12		9		33	

* The first case in domestic cats was detected in 1978.
† The first human case which involved domestic cats as the source was detected in 1985.
‡ Retrospective enquiries failed to implicate domestic cats in these infections with certainty.
§ Three veterinary workers (one male, two female; source not traced). Two laboratory workers (both male).
¶ ? = epidemiological evidence only; laboratory studies not performed on suspect animals.

virus is maintained in small wild mammals[1,2] has been generally accepted, and almost proven. Cowpox virus and antibody to the virus have been detected in Russian rodents,[3] and the antibody has been demonstrated in British bank voles and wood-mice[38] (A.Crouch, M.Bennett and D.Baxby, unpublished observations).

Cowpox was first observed in the domestic cat in 1978,[39] and the cat is now the most commonly detected victim.[4,35] The first cases of human infection acquired from domestic cats were seen in 1985,[12,25] and increasing attention has been paid to cats as a source of human infection.[8–11,14,16,17,19,21,40,41] More recently, there has been circumstantial evidence of rodents as a source of two human cases.[13,20,41]

Table 2 analyses the sources of human cases, subdivided into periods relating to developments in epidemiology. It must be emphasized that we believe there has not been any change in the epidemiology, but increased understanding of and attention to the sources of infection. Thus, some early cases, in which the source was unknown, were probably acquired from cats, and some of the corresponding later cases could have been of bovine origin. No source was established in 35 cases (65%). These included three veterinary workers, six patients possibly infected from cats or rodents (Table 2), and also recent cases subjected to detailed enquiries. Some infections may be acquired indirectly via brambles, barbed-wire, etc.

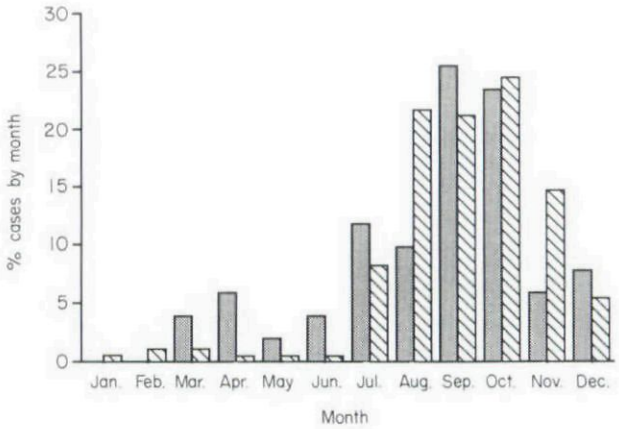

Figure 12. Seasonal distribution of human (51 cases 1969–93) and feline cowpox (184 cases diagnosed in Liverpool 1978–93). Omitted from the cases summarized in Tables 1 and 2 are one case (data not available) and two laboratory infections. ▢, human cowpox; ▨, feline cowpox.

In addition to three cases in farm workers in contact with infected cattle, occupational exposure resulted in five infections, three of them in veterinary workers (Table 2). Not reflected in our survey, and outside our experience, are cases in individuals caring for exotic captive species, particularly elephants, in European zoos.[42] We have investigated three outbreaks (only one published) in captive cheetahs in Britain, but no human cases were involved.[34]

Age and sex

Because the numbers at risk and the degree of exposure are unknown, and the number of cases is small, proper analysis cannot be made. However, there are some general points of interest (Tables 1 and 2). The age range was 1–64 years, with 14 (26%) under the age of 12. The overall sex distribution was equal. The preponderance of males aged 12–18 years with facial lesions has already been mentioned. Also of interest is the higher proportion of females (11 vs. 3 males) in those aged 12 years and under, and of these patients seven females but only one male were associated with feline cases. This may be due to the greater tendency of females, particularly young girls, to cuddle or nurse pet cats.

Season

There is a striking seasonal distribution of both human and feline cases (Fig. 12). Most cases are diagnosed during the late summer and autumn, the

period when the number and activity of wild rodents is maximal.

Feline cowpox

Some knowledge of feline cowpox, which is reviewed thoroughly elsewhere,[35,43] should help those investigating possible human cases. Infection starts as a pruritic, bite-like lesion on the forelimbs or head. Secondary lesions appear after an interval of 10 days, and veterinary help is usually sought during this stage. The secondary lesions progress through erythematous macules to ulcerated papules about 1 cm in diameter, and these crust over. Scratching often causes lesions to appear as raw, glistening areas. Some animals appear generally unwell, and about 20% have respiratory signs and conjunctivitis. Most recover uneventfully, but occasional deaths due to viral pneumonia occur. Around 30–50 cases are investigated in Britain each year, but others probably go undiagnosed.

Persons nursing infected animals should be warned of the risk of infection. However, in spite of the number of feline infections and the degree of human exposure, relatively few human cases occur. This again suggests that cowpox virus is of low infectivity for humans. Infected animals without skin lesions do not present a risk, and no human case has occurred in anyone caring for a sick cat after the feline infection was diagnosed.

Discussion

This is the first review to describe the full clinical spectrum, differential clinical diagnosis, laboratory diagnosis, and epidemiology of human cowpox. Cowpox is a potentially serious infection, particularly in children, the elderly, and the immunosuppressed. The clinical features vary, but the information provided herein should help those dealing with possible cases.

It has been suggested that the cessation of smallpox vaccination has led, or may lead, to an increased incidence and/or severity of human cowpox.[8–12,18,19] Table 2 may be misleading in this context, because the cases for 1985–93 include nine from continental Europe, which are included for their clinical and epidemiological interest, and we have no knowledge of unreported cases during the earlier period. Although more British cases occurred during the period 1982–93 (25 cases in 12 years) than in 1969–81 (20 cases in 13 years), the temporal distribution is uneven, and we believe that any apparent increase in incidence is due to increased awareness. Thus, relative peaks occurred during 1978–81 (eight cases) and 1987–90 (11 cases), which followed attention drawn to what were then recent advances,[1,12,25,39] and only five cases occurred in the intervening 5 years.

Although previous vaccination might have some attenuating effect, which is difficult to assess in a rare and variable infection, the important criterion is the interval between vaccination and infection. Thus, we would expect an adult vaccinated in infancy to be no less susceptible than an unvaccinated child. Even recent vaccination does not necessarily confer protection, and we have seen relatively severe cowpox with erythema, lymphadenopathy, and systemic reaction in an adult successfully vaccinated 12 months previously. The virus is deposited directly into receptive tissue, and largely evades any existing immunity. This is why re-vaccination often produces an unattenuated response,[44] and why U.K. authorities do not recommend vaccination for those working with cowpox virus.[45]

Smallpox vaccination was discontinued in 1971, and would, in any case, have been contraindicated in the immunosuppressed, and patients with eczema. Cowpox in such individuals, although severe, has always been rare, and there are no reports of its occurrence in HIV-positive individuals. Vaccinia is severe in HIV-positive patients,[46] and fatal cowpox has occurred in FIV-positive cats.[47] Although it is likely that the number of immunosuppressed people will increase, we do not think the risk to the individual will rise. However, it would be prudent to advise immunosuppressed individuals of the risks of nursing cats with cowpox.

One final point concerns the future of investigations into human cowpox. Due to reorganization of the U.K. health services, and the commercial pressures and financial constraints involved, routine laboratory investigations may be restricted to those infections diagnosable by inexpensive, commercially available tests. These would not be available for rare infections such as cowpox, and diagnosis of these cases would rely increasingly on clinical acumen helped, where possible, by the few research laboratories interested in the subject. If this pessimistic view proves to be realistic, fewer presumptive cases will be confirmed, and future trends in incidence and severity may go unexplored.

Acknowledgments

We would like to thank those colleagues who generously provided illustrations, and those too numerous to mention who kindly provided information about their cases.

References

1 Baxby D. Is cowpox misnamed? A review of ten human cases. *Br Med J* 1977; **i:** 1379–81.

2 Baxby D. The natural history of cowpox. *Brist Med Chirurg J* 1982; **97:** 12–16.

3 Marennikova SS, Shelukhina EM, Efremova EV. New outlook on the biology of cowpox virus. *Acta Virol* 1984; **28:** 437–44.

4 Baxby D, Bennett M. Cowpox virus. In: *Encyclopedia of Virology* (Webster RG, Granoff A, eds). Orlando: Academic Press, 1994; 261–7.

5 Robinson TWE, Heath RB. *Virus Diseases of the Skin*. Edinburgh: Churchill Livingstone, 1983; 138–9.

6 Baxby D. Poxviruses. In: *Principles and Practice of Clinical Virology* (Zuckerman AJ, Banatvala JE, Pattison JR, eds), 2nd edn. Chichester: John Wiley & Sons, 1990; 411–34.

7 Highet AS, Kurtz J. Viral infections. In: *Textbook of Dermatology* (Champion RH, Burton JL, Ebling FJG, eds), 5th edn. Oxford: Blackwell Scientific Publications, 1992; 873.

8 Nasemann T, Mayr A, Schaeg G *et al.* Infektion eines Mädchens mit Kuhpockenvirus. *Hautarzt* 1987; **38:** 414–18 (Ger.) (Eng. Abstr.).

9 Eis-Hübinger AM, Gerritzen A, Schneweis KE *et al.* Fatal cowpox-like infection transmitted by cat. *Lancet* 1990; **336:** 880.

10 Pfeiff B, Pullmann H, Eis-Hübinger AM *et al.* Letale Tierpockeninfektion bei einem Atopiker unter dem Bild einer Variola vera. *Hautarzt* 1991; **42:** 293–7 (Ger.) (Eng. Abstr.).

11 Klingebiel T, Vallbracht A, Döller G *et al.* A severe human cowpox infection in south Germany. *Pediatr Infect Dis J* 1988; **7:** 883–5.

12 Willemse A, Egberink HF. Transmission of cowpox infection from domestic cat to man. *Lancet* 1985; **i:** 1515.

13 Postma BH, Diepersloot RJA, Niessen GJCM, Droog RP. Cowpox-like virus infection associated with rat bite. *Lancet* 1991; **337:** 733–4.

14 Cronqvist J, Ekdahl K, Kjartansdottir A *et al.* Cowpox — en kattsjuka hos människa. *Lakartidningen* 1991; **88:** 2605–6 (Swe.).

15 Claudy AL, Gaudin OG, Granouillet R. Pox virus infection in Darier's disease. *Clin Exp Dermatol* 1982; **7:** 261–6.

16 Casemore DP, Emslie ES, Whyler DK *et al.* Cowpox in a child, acquired from a cat. *Clin Exp Dermatol* 1987; **12:** 286–7.

17 O'Connor GM, Thiru AAA, Caul OE. Ocular cowpox: transmission from the domestic cat to man. *Br J Ophthalmol* 1990; **74:** 245–6.

18 Vestey JP, Yirrell DL, Aldridge RD. Cowpox/catpox infection. *Br J Dermatol* 1991; **124:** 74–8.

19 Motley RJ, Holt PJA. Cowpox presenting with sporotrichoid spread: a case report. *Br J Dermatol* 1990; **122:** 705–8.

20 Lewis-Jones MS, Baxby D, Cefai C, Hart CA. Cowpox can mimic anthrax. *Br J Dermatol* 1993; **129:** 625–7.

21 Blackford S, Roberts DL, Thomas PD. Cowpox infection causing a generalized eruption in a patient with atopic dermatitis. *Br J Dermatol* 1993; **129:** 628–9.

22 Dugmore WN, Dabir ZM. Cowpox virus. *Br J Ophthalmol* 1992; **76:** 510.

23 Simcock PR, Noble JL, Tullo AB *et al.* Cowpox virus. *Br J Ophthalmol* 1993; **77:** 394.

24 Anon. Cowpox. *Br Med J* 1975; **i:** 46.

25 Pether JVS, Trevains PH, Harrison SRB *et al.* Cowpox from cat to man. *Lancet* 1986; **i:** 38–9.

26 Hall CJ, Stevens JD. Ocular cowpox. *Lancet* 1987; **i:** 111.

27 Dixon CW. *Smallpox*. London: Churchill, 1962; 165.

28 Leavell UW, McNamara MJ, Muelling R *et al.* Orf; report of 19 human cases with clinical and pathological observations. *JAMA* 1968; **204:** 657–64.

29 Johannesson JV, Krogh H-K, Solberg I *et al.* Human orf. *J Cutan Pathol* 1975; **2:** 265–83.

30 Emond RTD. *Infectious Diseases*. Basel: Recom Verlag, 1981; 46.

31 Christie AB. *Infectious Diseases: Epidemiology and Clinical Practice*, 3rd edn. Edinburgh: Churchill Livingstone, 1980; 703–21.

32 Naidoo J, Baxby D, Bennett M *et al.* Characterization of orthopoxviruses isolated from feline infections in Britain. *Arch Virol* 1992; **125:** 261–72.

33 McCarthy K, Downie AW, Bradley WH. The antibody response in man following infection with viruses of the pox group. II. Antibody response following vaccination. *J Hyg* 1958; **56:** 466–78.

34 Baxby D, Ashton DG, Jones D, Thomsett LR *et al.* An outbreak of cowpox in captive cheetahs. *J Hyg* 1982; **89:** 365–72.

35 Bennett M, Gaskell CJ, Baxby D *et al.* Feline cowpox virus infection; a review. *J Small Anim Pract* 1990; **31:** 167–73.

36 Morgan-Capner P. Orf. *Lancs Westmor Med J* 1992; **i:** 191–3.

37 Davies JHT, Janes LR, Downie AW. Cowpox infection in farmworkers. *Lancet* 1938; **ii:** 1534–7.

38 Kaplan C, Healing TD, Evans N *et al.* Evidence for infection by viruses in small British field rodents. *J Hyg* 1980; **84:** 285–94.

39 Thomsett LR, Baxby D, Denham EM. Cowpox in the domestic cat. *Vet Rec* 1978; **103:** 567.

40 Anon. What's new pussy cat? Cowpox. *Lancet* 1986; **ii:** 668.

41 Burton JL. Of mice and milkmaids, cats and cowpox. *Lancet* 1994; **343:** 67.

42 Pilaski J, Rosen-Wolff A. Poxvirus infection in zoo-kept mammals. In: *Virus Diseases in Laboratory and Captive Animals* (Darai G, ed.). Boston; Martinus Nijhoff Publishing, 1988; 83–100.

43 Bennett M, Gaskell RM, Gaskell CJ *et al.* Studies on poxvirus infection in cats. *Arch Virol* 1989; **104:** 19–33.

44 Baxby D. Indications for smallpox vaccination: policies still differ. *Vaccine* 1993; **11:** 395–6.

45 Advisory Committee on Dangerous Pathogens and Advisory Committee on Genetic Manipulation. *Vaccination of Laboratory Workers Handling Vaccinia and Related Poxviruses Infectious for Humans*. London: HMSO, 1990.

46 Redfield RR, Wright DC, James WD *et al.* Disseminated vaccinia in a military recruit with human immunodeficiency (HIV) disease. *N Engl J Med* 1987; **316:** 673–6.

47 Brown A, Bennett M, Gaskell CJ. Fatal poxvirus infection in association with FIV infection. *Vet Rec* 1989; **124:** 19–20.

This document is a scanned copy of a printed document. No warranty is given about the accuracy of the copy. Users should refer to the original published version of the material.