Prognostic Factors of Recurrence in Encapsulated Hurthle Cell Carcinoma of the Thyroid Gland

A Clinicopathologic Study of 50 Cases

Ronald A. Ghossein, M.D.[1]
David H. Hiltzik, M.D.[2]
Diane L. Carlson, M.D.[1]
Snehal Patel, M.D.[3]
Ashok Shaha, M.D.[3]
Jatin P. Shah, M.D.[3]
Robert M. Tuttle, M.D.[4]
Bhuvanesh Singh, M.D., Ph.D.[3]

[1] Department of Pathology Memorial Sloan-Kettering Cancer Center, New York, New York.

[2] Department of Otolaryngology-Head and Neck Surgery, Columbia University, New York, New York.

[3] Head and Neck Surgery Service, Memorial Sloan-Kettering Cancer Center, New York, New York.

[4] Endocrinology Service, Memorial Sloan-Kettering Cancer Center, New York New York.

Address for reprints: Ronald Ghossein, M.D., Department of Pathology, Memorial Sloan-Kettering Cancer Center, 1275 York Ave., New York, NY 10021; Fax: (212) 717-3203; E-mail: ghosseir@mskcc.org

Received September 27, 2005; accepted November 21, 2005.

BACKGROUND. Follicular carcinomas of the thyroid gland, including its oncocytic variant (so-called Hurthle cell carcinoma), are subdivided into the indolent encapsulated ("minimally invasive") and the clinically aggressive widely invasive tumors. There are, however, cases of encapsulated follicular carcinoma that recur and metastasize. Identifying these cases at the time of diagnosis is crucial for prognostic and therapeutic considerations. Because to the authors' knowledge most studies do not focus exclusively on the encapsulated Hurthle cell carcinoma (EHC), the current study attempted to identify predictors of recurrence in EHC.

METHODS. A tumor was defined as EHC if it was encapsulated, macroscopically well defined with microscopic but no macroscopic evidence of vascular or capsular invasion, and composed of >75% follicular oncocytic cells. Retrospective chart review and microscopic examination identified 50 primary tumors meeting the above criteria at the Memorial Sloan-Kettering Cancer Center between 1967 and 2005. The cases were analyzed for various histologic and clinical parameters. Each parameter was correlated with recurrence-free survival (RFS).

RESULTS. Seven of 50 (14%) patients developed disease recurrence. All patients who developed recurrence were found to have a high number of foci of vascular invasion ($\geq$ 4). In univariate analysis, $\geq$ 4 foci of vascular invasion ($P <.0001$), tumor size > 4 cm ($P = .049$), the presence of mitosis ($P = .018$), and a solid/trabecular growth pattern ($P = .009$) were found to be correlated with a decreased RFS. Extensive capsular invasion, gender, and age did not confer a statistically higher recurrence rate. The finding of a solid/trabecular growth and mitosis correlated with the presence of numerous foci ($\geq$ 4) of vascular invasion ($P = .01$ and $P = .005$, respectively).

CONCLUSIONS. A diligent search for vascular invasion is recommended in EHC that display mitosis or a solid/trabecular growth pattern. The presence of $\geq$ 4 foci of vascular invasion should alert the pathologist and the clinician to a significantly higher risk of recurrence in EHC. ***Cancer* 2006;106:1669–76.**
© 2006 American Cancer Society.

KEYWORDS: Hurthle cell carcinomas, encapsulated, thyroid, recurrence, vascular invasion, capsular invasion, mitosis, solid growth pattern.

Follicular carcinomas of the thyroid gland, including its oncocytic variant (so-called Hurthle cell carcinoma), are subdivided into minimally invasive and widely invasive tumors.[1] The minimally invasive carcinoma, also termed encapsulated, is totally surrounded by a fibrous capsule and displays capsular invasion and/or foci of vascular invasion.[1] It is unusual for these foci of invasion to be detected grossly.[1] In contrast, widely invasive follicular and Hurthle cell carcinoma are defined by extensive areas of invasion at both the macro-

© 2006 American Cancer Society
DOI 10.1002/cncr.21825
Published online 13 March 2006 in Wiley InterScience (www.interscience.wiley.com).

scopic and microscopic level.[1] This classification correlates very well with outcome, such that minimally invasive tumors have an overall excellent prognosis, whereas widely invasive tumors have a much poorer outcome.[1] However, there are cases of encapsulated minimally invasive follicular carcinoma that recur and metastasize.[2,3] Identifying these cases at the time of diagnosis is crucial because a minimally invasive tumor will be treated by lobectomy alone followed by observation in some centers even if the follicular tumor is of the oncocytic (Hurthle cell) category. This approach will risk undertreating those few minimally invasive tumors with poor outcome. At variance with the minimalist surgical approach, many surgeons will perform a total thyroidectomy on any minimally invasive follicular carcinoma, especially those of the oncocytic category, most likely overtreating a large number of cases. In 1986, Lang et al.[4] studied a large number of follicular carcinomas and demonstrated that the number of foci of vascular invasion is an adverse prognostic sign even in encapsulated tumor. Recently, Collini et al.[5] found identical results in encapsulated nononcocytic follicular carcinoma. However, in most publications, including the above-mentioned studies, encapsulated Hurthle cell carcinomas (EHCs) are either not included or diluted with their non-Hurthle cell counterparts and not analyzed separately. Because the oncocytic variant of follicular carcinoma is regarded by some to behave in a different fashion from nononcocytic follicular carcinoma,[6] we undertook a clinicopathologic study of 50 consecutive cases of EHCs in a search for predictors of disease recurrence.

MATERIALS AND METHODS

Patient Search and Inclusion Criteria

A tumor was defined as EHC if it was macroscopically well defined, encapsulated with microscopic but no macroscopic evidence of vascular or capsular invasion, and composed of >75% of follicular oncocytic cells. The identification of a cell as an oncocyte was based on the presence of acidophilic, granular cytoplasm, and hyperchromatic or vesicular nucleus with large nucleolus. Tumors with an oncocytic cytoplasm but displaying the nuclear features of papillary thyroid carcinoma such as the oncocytic and tall cell variants of papillary carcinoma were not included in the study. Tumors with a high mitotic rate (≥ 5 mitosis per 10 high-power fields), tumor necrosis, or an undifferentiated component were excluded. Only cases from which primary tumor slides were available were included. Because we were interested in predictors of outcome in the primary tumor, cases with distant metastases at the time of presentation were not included, given that their outcome would be adverse by virtue of the presence of distant disease. The Departments of Surgery, Head and Neck, and Pathology databases and the hospital tumor registry were searched for Hurthle cell tumors. Fifty cases of EHC fulfilling the above criteria were identified between 1967 and 2005 and were consecutively followed and treated at Memorial Sloan-Kettering Cancer Center. Twenty-three of these cases were published in previous reports on Hurthle cell tumors that did not focus on the EHC.[7–9] The study was approved by the Institutional Review Board of Memorial Sloan-Kettering Cancer Center.

Clinical Review

The patient's charts were reviewed for age at diagnosis, gender, type of surgery, and adjuvant therapy (radioactive iodine). Tumor recurrence, both local and metastatic, was established on the basis of clinical examination, radiologic findings on either computed tomography (CT) or magnetic resonance imaging (MRI), findings on follow-up nuclear scanning including radioactive iodine or positron emission tomography (PET) scanning, significant increase in serum thyroglobulin, or histologic examination of the recurrent tumor. Dates of initial thyroid surgery, recurrence, and death were recorded.

Pathologic Review

Two pathologists subspecializing in head and neck tumors (R.A.G. and D.L.C.) reviewed a mean of 14 slides per patient. Histopathologic review was conducted without the pathologist's knowledge of the patients' clinical characteristics or outcome. Tumor size was measured as the maximum dimension of the resected tumor specimen. Tumors were classified into 2 size categories: ≤ 4 cm and > 4 cm. Mitotic rate was determined by counting 10 high-power fields (×400) with an Olympus microscope (U-DO model; Olympus America, Melville, NY) in the areas of greatest concentrations of mitotic figures. Vascular and capsular invasion were identified according to the criteria outlined in the last Armed Forces Institute of Pathology fascicle on thyroid tumors.[1] Foci of vascular and capsular invasion were counted and subdivided into 2 categories: focal (< 4 invasive foci) and extensive (≥ 4 foci). The number of foci of vascular invasion in tumor capsule (intracapsular vascular invasion) and outside the tumor capsule in adjacent thyroid parenchyma (extracapsular vascular invasion) were recorded. The predominant cell size was categorized as small (cells with scant cytoplasm and a nucleus approximating the size of a normal follicular cell) or large (larger nuclear and cell size with more abundant cytoplasm). The predominant growth pattern was classified as follicular or solid/trabecular and the presence or absence

of partially clear cytoplasm was noted. The presence or absence of microscopic tumor extension into the extrathyroid soft tissue stroma as well as the presence of microscopic extrathyroid vascular invasion were documented. Finally, microscopic resection margins were categorized as positive (tumor at the inked margin) or negative (no tumor at the inked margin).

Statistical Analysis

Descriptive statistics were used to summarize study data. The primary endpoint of interest was recurrence-free survival (RFS). Time intervals were calculated in months from the date of surgery to the date of recurrence for RFS. Survival outcomes were calculated by the Kaplan-Meier method; groups were compared in univariate analysis using the log-rank test. A *P*-value $\leq$.05 was considered statistically significant. Multivariate analysis was not attempted in view of the small number of events available for analysis. Nonparametric qualitative and quantitative comparisons were performed using the Fisher exact or Pearson chi-square tests and the Mann-Whitney *U*-test, respectively.

RESULTS

Clinical Parameters

Table 1 lists the distribution of the clinical and histopathologic variables in the patient population. Females comprised 29 of the 50 cases (58%) in the study group. The mean age at diagnosis was 52 years (range, 20–94 yrs). Twenty-one of 50 patients (42%) underwent total thyroidectomy and the remaining 29 patients (58%) had 1 thyroid lobe removed. Seventeen patients received radioactive iodine therapy and 31 did not. Iodine therapy status could not be assessed in 2 cases. At the time of presentation, there was no evidence of lymph node metastases from the Hurthle cell carcinoma in 49 cases. One case had postoperative iodine uptake in the neck consistent with lymph node metastases but no evidence of enlarged lymph nodes on structural imaging studies (ultrasound and CT scans). These iodine avid areas disappeared completely after only 1 dose of radioactive iodine therapy. This patient remained free of disease 5 years and 7 months after surgery. Overall, 7 of 50 patients (14%) developed disease recurrence. Three patients had disease recur in the neck, 2 in the mediastinum, 5 in the lung, 3 in bone, and 1 in the liver. One of those patients who recurred died of disease 6 years and 5 months after diagnosis. Of the remaining patients with available follow-up, 2 died of other causes and the remainder were alive at the time of last follow-up.

TABLE 1
Clinical and Pathologic Features of Encapsulated Hurthle Cell Follicular Carcinoma (*n* = 50)

Variable*	No.	% of total
Age, y (mean, 52)		
> 45	33	66
≤ 45	17	34
Gender		
Female	29	58
Male	21	42
Tumor size, cm (mean, 3.2)		
> 4	12	24
≤ 4	36	72
Unknown	2	4
Vascular invasion		
No	18	36
Focal (< 4 foci)	17	34
Extensive (≥ 4 foci)	15	30
Intracapsular vascular invasion		
No	18	36
Focal (< 4 foci)	19	38
Extensive (≥ 4 foci)	13	26
Extracapsular vascular invasion:		
No	39	78
Focal (< 4 foci)	8	16
Extensive (≥ 4 foci)	3	6
Capsular invasion		
No	11	22
Focal (< 4 foci)	32	64
Extensive (≥ 4 foci)	7	14
Mitosis		
Absent	40	80
Present	10	20
Growth pattern		
Solid/trabecular	25	50
Follicular	24	48
Unknown	1	2
Cell size		
Small	15	30
Large	33	66
Unknown	2	4
Partially clear cytoplasm		
Present	2	4
Absent	47	94
Unknown	1	2
Microscopic extrathyroid extension		
Present	2	4
Absent	47	94
Unknown	1	2
Margins		
Positive	3	6
Negative	47	94
Type of surgery		
Lobectomy	21	42
Total thyroidectomy	29	58
Iodine therapy		
Administered	17	34
Not given	31	62
Unknown	2	4

* A number < 50 indicates only those variables that could be determined with certainty after review of the clinical records, histopathologic slides, and pathology reports.

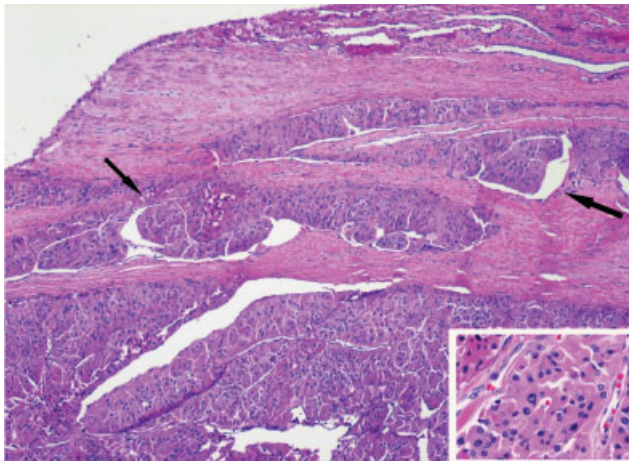

FIGURE 1. Encapsulated Hurthle cell follicular carcinoma with foci of intracapsular vascular invasion (arrows). The tumor grows in a predominantly solid growth pattern and is composed of oncocytic cells (inset).

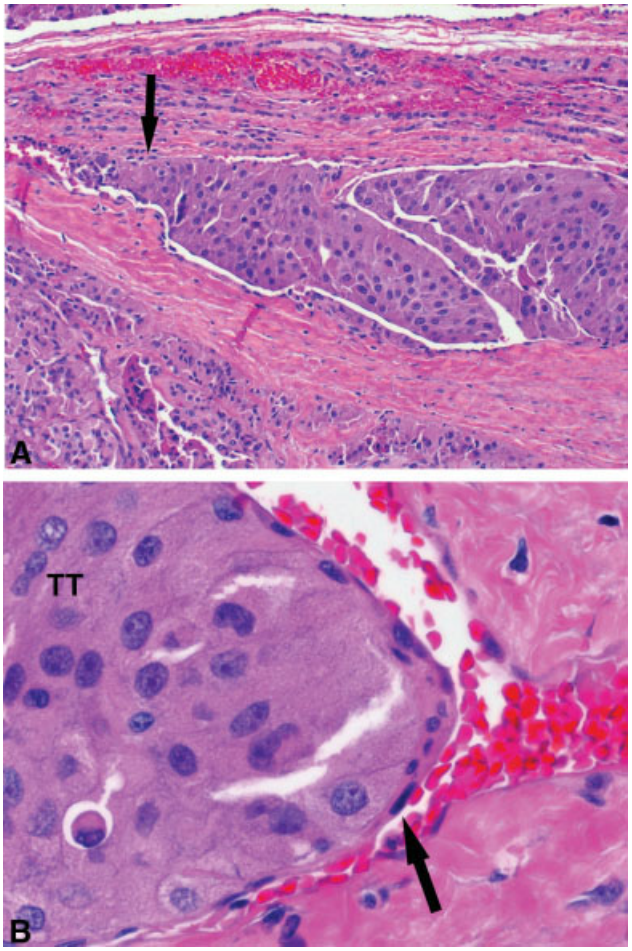

FIGURE 2. Vascular invasion in the same case as Figure 1. (A) The point of attachment of the tumor thrombus to the vessel wall is marked with an arrow. (B) High-power view of a tumor thrombus (TT) covered by endothelial cells (arrow).

Pathologic Parameters

Pathologic parameters are shown in Figures 1-3. The median tumor size was 3 cm (range, 1.2-10 cm) with 12 of 50 tumors (24%) exceeding 4 cm. All the neoplasms were totally encapsulated. A solid/trabecular growth pattern was found in 25 of 50 cases (50%) and a follicular architecture in 24 of 50 cases (48%). Fifteen of the 50 tumors (30%) were predominantly composed of small cells with a high nuclear/cytoplasmic ratio, whereas the majority (33 of 50 tumors [66%]) were populated by large cells with abundant cytoplasm. Mitoses were found in only 10 cases (20%) ranging from 1 mitosis to 4 mitosis per 10 high-power fields. Capsular invasion was found in 39 of 50 cases (78%) and angioinvasion was noted in 32 of 50 tumors (64%). Numerous foci of capsular invasion ($\geq$ 4 foci) were found in 7 of 50 cases (14%), whereas extensive vascular invasion ($\geq$ 4 foci) was observed in 15 of 50 cases (30%). Intracapsular vascular invasion was found in all angioinvasive tumors and extracapsular vascular invasion was noted in 11 of 50 tumors (22%). There was microscopic invasion of vessels immediately outside the thyroid capsule in only 2 of 50 cases. There was microscopic focal extrathyroid extension in only 2 of 50 tumors. The resection margins were positive for carcinoma in only 3 of 50 patients. Except for papillary carcinomas present in 16 cases, there were no significant additional thyroid lesions in these patients. These papillary carcinoma were subdivided as follows: 14 cases with subcentimeter papillary carcinoma; 1 case with subcentimeter papillary carcinoma and a separate, noninvasive, encapsulated follicular variant of papillary carcinoma, well differentiated, measuring 1.3 cm in greatest diameter; and 1 case of encapsulated, noninvasive, papillary carcinoma, well differentiated, measuring 1.5 cm in greatest dimension.

Survival Analysis

Follow-up was available on 48 of the 50 patients. The median follow-up for the entire patient population was 35.9 months (range, 0.1-190.8 mos). Overall, 7 of 50 patients (14%) developed disease recurrence with a 3-year and 5-year RFS rate of 85% and 76%, respectively. Table 2 lists the recurrence rate and P value for each variable on univariate analysis. Gender and age ($<$ 45 yrs and $\geq$ 45 yrs) did not appear to be correlated with recurrence ($P = .18$ and $P = .30$, respectively). Tumor size $>$ 4 cm was found to be correlated with a decreased RFS time ($P = .049$). The presence of a solid/trabecular growth pattern was found to be a significant adverse factor for RFS ($P = .009$). Indeed, there was no recurrence noted in the group of tumors with a follicular growth pattern. The

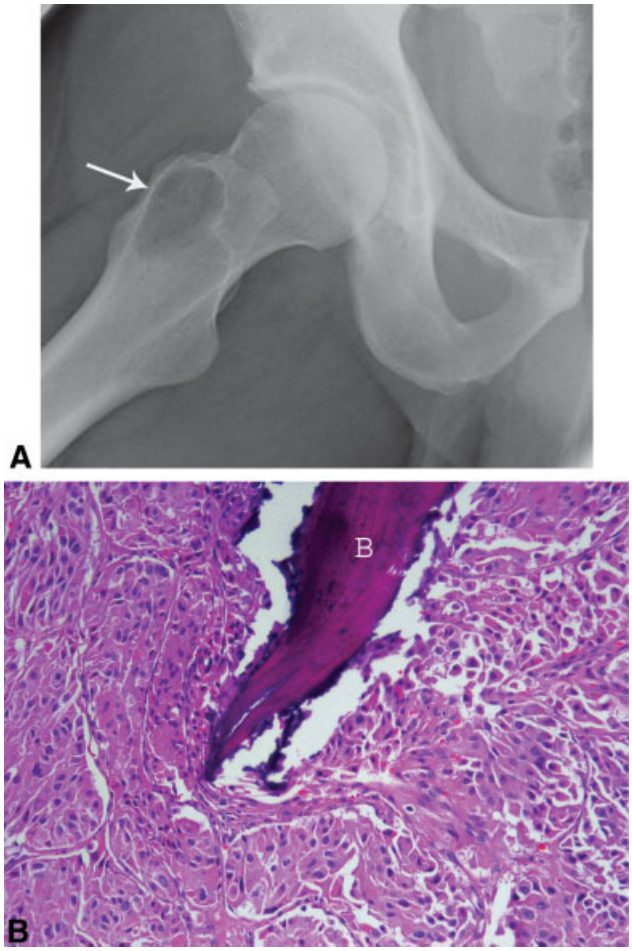

FIGURE 3. Distant metastasis from tumor shown in Figures 1 and 2. (A) X-ray of a lytic metastasis (arrow) to femur. (B) Microscopic examination shows the Hurthle cell follicular carcinoma growing around a bone trabeculae (B).

presence of partial cytoplasmic clearing in the tumor cells was found to be correlated with a worse RFS ($P = .02$). The presence of mitoses significantly decreased the RFS ($P = .018$). However, a predominance of small cells with a high nuclear/cytoplasmic ratio did not appear to correlate with RFS ($P = .87$). The presence of ≥ 5 foci of capsular invasion was not associated with a worse RFS ($P = .4$). The presence of ≥ 4 foci of capsular invasion also did not appear to be significantly correlated with outcome despite an improved P value (.069). In contrast, the presence of ≥ 4 foci of vascular invasion was found to be strongly predictive of recurrence and a decreased RFS ($P < .0001$) (Fig. 4). This correlation between increased vascular invasion and decreased outcome persisted when ≥ 5 foci of vascular invasion were considered as extensive angioinvasion ($P < .0001$). The presence of ≥ 4 foci of intracapsular vascular invasion was found to significantly worsen the survival time ($P < .0001$). A similar correlation was found between numerous foci of extracapsular vascular invasion (≥ 4) and outcome ($P = .0376$).The presence of extrathyroid extension (which was only focal and obviously microscopic) and positive margins did not appear to have an impact on RFS ($P = .06$ and $P = .08$, respectively).

TABLE 2
Recurrence Rate and Recurrence-Free Survival According to Clinical/Pathologic Features of Encapsulated Hurthle Cell Follicular Carcinoma (n = 48)

Variable*	Recurrence Rate No. (%)	Univariate RFS Analysis Curve (P as Determined by Log-Rank Test)
Age, y		
≥ 45 (n = 32)	4 (12.5)	.3
< 45 (n = 16)	3 (18.7)	
Gender		
Female (n = 27)	2 (7.4)	.18
Male (n = 21)	5 (23.8)	
Tumor size in cm		
> 4 (n = 11)	3 (27.2)	.049
≤ 4 (n = 35)	3 (8.5)	
Vascular invasion		
Absent or focal (< 4 foci) (n = 33)	0 (0)	< .0001
Extensive (≥ 4 foci) (n = 15)	7 (47)	
Capsular invasion		
Absent or focal (< 4 foci) (n = 41)	5 (12)	.069
Extensive (≥ 4 foci) (n = 7)	2 (22)	
Mitosis		
Present (n = 10)	4 (40)	.018
Absent (n = 38)	3 (8)	
Growth pattern		
Solid/trabecular (n = 24)	7 (29)	.009
Follicular (n = 23)	0 (0)	
Cell size		
Small (n = 15)	2 (13)	.8717
Large (n = 31)	5 (16)	
Partially clear cytoplasm		
Present (n = 2)	2 (100)	.0244
Absent (n = 45)	5 (11)	
Microscopic extrathyroid extension		
Present (n = 2)	1 (50)	.068
Absent (n = 45)	6 (13)	
Margins		
Positive (n = 3)	1 (33)	.085
Negative (n = 45)	6 (13)	

RFS: recurrence-free survival; N: number of recurrent cases for each variable (e.g., number of females who recurred); %: percentage of recurrent cases for each variable (e.g., percentage of females who recurred).

* Analysis was performed on the 48 cases with available follow-up. In some categories, the total number of cases analyzed is < 48 because only those variables that could be determined with certainty were included.

DISCUSSION

As expected, the recurrence rate of this current series of EHC (14%) is lower than that reported in widely invasive follicular carcinoma (43%).[4] The progression rate in the current study was found to be slightly

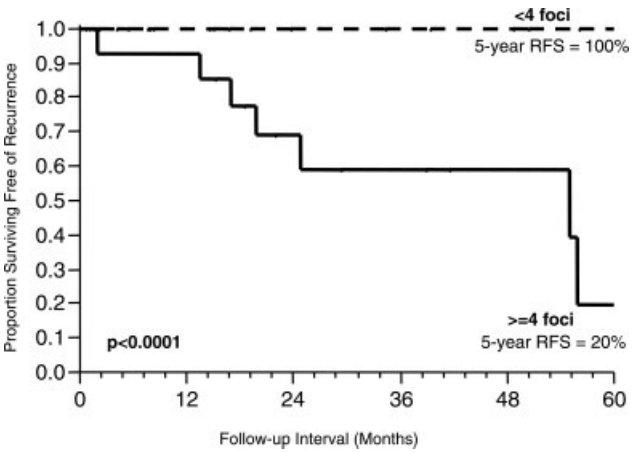

FIGURE 4. Recurrence-free survival curve according to extent of vascular invasion.

higher than that encountered in the majority of publications regarding encapsulated follicular carcinomas (range, 4-11%).[4,10–12] This could be due to the fact that a tertiary cancer center will have a higher fraction of large high-risk tumors or to the fact that oncocytic tumors are more aggressive than their nononcocytic counterparts. It is of interest that 5 of the 7 recurrences reported in the current series occurred within approximately 2 years of diagnosis. The remaining 2 patients experienced recurrence approximately 5 years after undergoing initial thyroidectomy. This is in agreement with the findings that the majority of follicular carcinomas recur 3-5 years after initial diagnosis.[4,13] Indeed, Lang et al.[4] demonstrated that the steepest increase in distant metastases and death for follicular carcinomas occurs during the first 4 years after presentation. There was a female preponderance, in agreement with the vast amount of literature available on differentiated thyroid carcinoma. The mean age at diagnosis was 52 years, which is at variance with most studies on encapsulated follicular carcinomas, which report a mean age range of 42 years to 48 years.[4,10,12] A referral bias could have caused this difference in age at presentation because high-risk older patients are more likely to be sent to a major cancer center. Both old age and male gender were not found to worsen prognosis within EHC. This is obviously in contrast with the majority of studies on differentiated thyroid carcinomas.[14,15] This lack of significance could be due to the fact that our recurrence population was very small. However, other authors did not find any prognostic impact for gender and age in encapsulated follicular carcinomas.[16] Large tumors (>4 cm) were correlated with a decreased RFS ($P = .049$). However, large tumor size is not absolutely specific for recurrence because patients with tumors measuring <4 cm (including a 2.2-cm carcinoma) experienced disease recurrence. This is in agreement with the study of Schroder et al.,[12] which reported a similar correlation between tumor size and outcome in patients with encapsulated follicular carcinoma. However, those authors did not analyze their oncocytic follicular carcinomas separately. The presence of small cell size did not increase the risk for recurrence. This contradicts a previous study in which small cell size conferred a worsened outcome within Hurthle cell carcinoma. However, the authors of that study analyzed the prognostic impact of cell size in a group of Hurthle cell carcinomas with a solid/trabecular pattern[17] and did not focus on EHC. Those researchers also found a decrease in cytoplasmic eosinophilia in the aggressive Hurthle cell carcinomas composed of small cells. It is noteworthy that the focal presence of partially clear cytoplasm in the tumor cells was correlated with decreased RFS ($P = .024$) in the current series. Nonetheless, our cases with focal clear cytoplasm were composed of large cells. The presence of a solid/trabecular growth pattern was associated with a strong and significant decrease in RFS within EHC ($P = .009$), in concordance with the notion that a follicular growth pattern correlates with better outcome in Hurthle cell tumors.[7,17] Although there were no tumors with follicular pattern that recurred in the current study, others have shown that Hurthle cell carcinoma with a predominant follicular growth can cause death, albeit rarely.[17] Within our population, mitotically active tumors were found to be at a higher risk for a short RFS ($P = .018$). This is consistent with 2 recent studies analyzing the proliferation rate in Hurthle cell carcinoma. Indeed, mitotic index was shown to be significantly higher in Hurthle cell carcinoma than in adenoma, and the Ki-67 proliferative rate was found to have a significant impact on the outcome in Hurthle cell tumors.[9,18] Capsular and vascular invasion are now accepted as the defining features of malignancy in follicular tumors.[1] However, controversy remains regarding their respective prognostic value. It was Shields Warren in 1931[19] who first emphasized the adverse prognostic value of vascular invasion. Seven decades later, the debate still continues regarding the exact prognostic impact of vascular invasion and specifically its relation with capsular invasion and what constitutes extensive vascular invasion.[16] In 2000, Goldstein et al.[10] compared metastatic with nonmetastatic encapsulated follicular carcinomas (including a mixture of oncocytic and nononcocytic variant) and reported no difference in the number of foci of capsular or vascular invasion between metastatic and nonmetastatic tumors. In the current series, vascular invasion was by far the most pow-

TABLE 3
Clinical and Pathologic Characteristics According to Degree of Vascular Invasion

Characteristic*	Focal VI (< 4 vessels) (n = 33) No. of patients (%)	Extensive VI (≥ 4 vessels) (n = 15) No. of patients (%)	$P^{\dagger}$
Age, y			
< 45	11 (33)	5 (33)	1.0
≥ 45	22 (67)	10 (67)	
Gender			
Female	19 (58)	8 (53)	1.0
Male	14 (42)	7 (47)	
Size			
≤ 4 cm	27 (84)	8 (57)	.06
> 4cm	5 (16)	6 (43)	
CI			
Focal (< 4 foci)	29 (88)	12 (80)	.66
Extensive (> 4 foci)	4 (12)	3 (20)	
Growth pattern			
Solid	12 (37.5)	12 (80)	.01
Follicular	20 (62.5)	3 (20)	
Mitoses			
Absent	30 (91)	8 (53)	.005
Present	3 (9)	7 (46)	
Partial cytoplasmic clearing			
Absent	32 (100)	12 (87)	.09
Present	0	2 (13)	
Small cell size	8 (26)	7 (47)	.19
Large cell size	23 (74)	8 (53)	

VI: vascular invasion; CI: capsular invasion.

* Only the 48 cases with available follow-up were included. Tumor size was not accurately recorded in 2 patients. One case had no data available regarding growth pattern, cell size, and cytoplasmic quality. Another patient lacked information regarding cell size.

† Fisher exact test, 2-tailed values.

erful predictor of recurrence (P <.0001) in patients with EHC, whereas capsular invasion was not significantly associated with tumor recurrence. This correlation between extent of vascular invasion and adverse outcome was found in a small series of encapsulated non-Hurthle cell follicular carcinomas[5] and in larger series analyzing follicular carcinomas in general without emphasis on its oncocytic variant.[4,20] It is truly remarkable that the number of foci of vascular invasion that place patients at high risk of disease recurrence (≥ 4 vessels) is very close to the number found by Lang et al.[4] in 1986 (≥ 5 foci). With regard to capsular invasion, the results of the current study are in congruence with those from the majority of studies regarding the subject, which did not find a correlation between the extent of capsular invasion and outcome in patients with encapsulated follicular carcinomas (including Hurthle and non-Hurthle cell phenotypes).[5,16] Based on the above data, we believe that EHCs cannot all be assembled under the "minimally invasive" category, a term that denotes limited invasion and, more important, excellent prognosis. Indeed, some EHCs harbor extensive vascular invasion, which implies a high risk for recurrence. Some have suggested naming encapsulated follicular tumors with extensive vascular invasion as "widely invasive."[4,21] Others find this designation quite arbitrary and prefer using descriptive terms such as "encapsulated follicular carcinomas with extensive vascular invasion."[5] Whatever the designation, we believe it is important to avoid the use of the term "minimally invasive" for these aggressive encapsulated follicular neoplasms. It is also crucial to explain in the pathology report the prognostic significance of an encapsulated follicular carcinoma with extensive vascular invasion. Indeed, we have encountered cases in which patients were undertreated because of the use of the minimally invasive terminology in the pathology report.

In our opinion, the number of foci of vascular invasion should be mentioned in the pathology reports on EHCs and a note should be made regarding the increased risk of recurrence if ≥ 4 foci of vascular invasion are noted. A diligent search for vascular invasion is highly recommended in the presence of a solid growth pattern and mitosis because these characteristics are highly associated with extensive angioinvasion (Table 3). These recommendations will render the management and prognostication of patients with EHCs more rational.

REFERENCES

1. Rosai J, Carcangiu ML, DeLellis RA. Tumors of the thyroid gland. In: Atlas of tumor pathology. Washington, DC: Armed Forces Institute of Pathology; 1992.
2. Thompson LD, Wieneke JA, Paal E, Frommelt RA, Adair CF, Heffess CS. A clinicopathologic study of minimally invasive follicular carcinoma of the thyroid gland with a review of the English literature. *Cancer.* 2001;91:505-524.
3. Evans HL, Vassilopoulou-Sellin R. Follicular and Hurthle cell carcinomas of the thyroid: a comparative study. *Am J Surg Pathol.* 1998;22:1512-1520.
4. Lang W, Choritz H, Hundeshagen H. Risk factors in follicular thyroid carcinomas. A retrospective follow-up study covering a 14-year period with emphasis on morphological findings. *Am J Surg Pathol.* 1986;10:246-255.
5. Collini P, Sampietro G, Pilotti S. Extensive vascular invasion is a marker of risk of relapse in encapsulated non-Hurthle cell follicular carcinoma of the thyroid gland: a clinicopathological study of 18 consecutive cases from a single institution with a 11-year median follow-up. *Histopathology.* 2004; 44:35-39.
6. Carcangiu ML. Minimally invasive follicular carcinoma. *Endocr Pathol.* 1997;8:231-234.
7. Stojadinovic A, Ghossein RA, Hoos A, et al. Hurthle cell carcinoma: a critical histopathologic appraisal. *J Clin Oncol.* 2001;19:2616-2625.

8. Stojadinovic A, Hoos A, Ghossein RA, et al. Hurthle cell carcinoma: a 60-year experience. *Ann Surg Oncol.* 2002;9:197-203.
9. Hoos A, Stojadinovic A, Singh B, et al. Clinical significance of molecular expression profiles of Hurthle cell tumors of the thyroid gland analyzed via tissue microarrays. *Am J Pathol.* 2002;160:175-183.
10. Goldstein NS, Czako P, Neill JS. Metastatic minimally invasive (encapsulated) follicular and Hurthle cell thyroid carcinoma: a study of 34 patients. *Mod Pathol.* 2000;13:123-130.
11. Segal K, Arad A, Lubin E, Shpitzer T, Hadar T, Feinmesser R. Follicular carcinoma of the thyroid. *Head Neck.* 1994;16:533-538.
12. Schroder S, Pfannschmidt N, Dralle H, Arps H, Bocker W. The encapsulated follicular carcinoma of the thyroid. A clinicopathologic study of 35 cases. *Virchows Arch A Pathol Anat Histopathol.* 1984;402:259-273.
13. Hazard B, Kenyon R. Encapsulated angioinvasive carcinoma (angioinvasive adenoma) of thyroid gland. *Am J Clin Pathol.* 1954;24:755-766.
14. Cady B. Presidential address: beyond risk groups—a new look at differentiated thyroid cancer. *Surgery.* 1998;124:947-957.
15. Palme CE, Waseem Z, Raza SN, Eski S, Walfish P, Freeman JL. Management and outcome of recurrent well-differentiated thyroid carcinoma. *Arch Otolaryngol Head Neck Surg.* 2004;130:819-824.
16. van Heerden JA, Hay ID, Goellner JR, et al. Follicular thyroid carcinoma with capsular invasion alone: a nonthreatening malignancy. *Surgery.* 1992;112:1130-1136; discussion, 1136-1138.
17. Papotti M, Torchio B, Grassi L, Favero A, Bussolati G. Poorly differentiated oxyphilic (Hurthle cell) carcinomas of the thyroid. *Am J Surg Pathol.* 1996;20:686-694.
18. Lazzi S, Spina D, Als C, et al. Oncocytic (Hurthle cell) tumors of the thyroid: distinct growth patterns compared with clinicopathological features. *Thyroid.* 1999;9:97-103.
19. Warren S. Significance of invasion of blood vessels in adenomas of the thyroid gland. *Arch Pathol.* 1931;11:255-257.
20. Kahn NF, Perzin KH. Follicular carcinoma of the thyroid: an evaluation of the histologic criteria used for diagnosis. *Pathol Annu.* 1983;18(Pt 1):221-253.
21. World Health Organization. International histological classification of tumours. Histological typing of thyroid tumors, 2nd ed. Berlin: Springer; 1988.