Endocrine Journal 2022, **69** (9), 1149-1156

ORIGINAL

Prognostic factors for follicular thyroid carcinoma: the importance of vascular invasion

Yasuhiro Ito[1)], Mitsuyoshi Hirokawa[2)], Hiroo Masuoka[1)], Takuya Higashiyama[1)], Minoru Kihara[1)], Naoyoshi Onoda[1)], Akihiro Miya[1)] and Akira Miyauchi[1)]

[1)] *Department of Surgery, Kuma Hospital, Kobe 650-0011, Japan*
[2)] *Department of Diagnostic Pathology, Kuma Hospital, Kobe 650-0011, Japan*

Abstract. The World Health Organization (WHO) classifies follicular thyroid carcinoma (FTC) into three categories: minimally invasive (mFTC), encapsulated angioinvasive (eaFTC), and widely invasive (wFTC). This study investigated whether this classification is appropriate. We enrolled 523 patients who underwent initial surgery at Kuma Hospital between 1998 and 2015 and were diagnosed with FTC. Capsular invasion (CI) was classified as none, minimal (microscopic), or wide (macroscopic) invasion. Vascular invasion (VI) was divided according to the number of invasive foci into three degrees: VI(–), VI(1+), and VI(2+). For 507 M0 patients, age ≥55 years ($p = 0.004$), non-oxyphilic histology ($p = 0.043$), and male sex ($p < 0.001$) predicted poor distant recurrence-free survival (DR-FS) on univariate analysis; however, tumor size >4 cm and wide CI did not. The DR-FS rates significantly decreased from VI(–) to VI(2+) in a step-by-step fashion, including VI(–) *vs.* VI(1+) ($p = 0.011$) and VI(1+) *vs.* VI(2+) ($p = 0.014$). Multivariate analysis revealed that older age ($p = 0.0004$), non-oxyphilic histology ($p = 0.041$), male sex ($p = 0.0052$), VI(1+) ($p = 0.017$), and VI(2+) ($p < 0.001$) independently predicted distant recurrence. The DR-FS rates did not significantly differ among mFTC, wFTC/VI(–), and eaFTC/VI(1+). The DR-FS rate of eaFTC/VI(2+) was worse than that of eaFTC/VI(1+) ($p = 0.042$), but did not differ from that of wFTC/VI(1+/2+). Our findings suggest that subclassifying eaFTC according to the degree of VI and restricting wFTC to VI-positive cases would be better in the WHO classification. Revising the definition for wide CI is recommended.

Key words: Follicular thyroid carcinoma, Vascular invasion, Capsular invasion, Prognosis

FOLLICULAR THYROID CARCINOMA (FTC) is the second-most common malignancy, followed by papillary thyroid carcinoma, that arises from thyroid follicular cells. Although lymph node metastasis is uncommon, distant metastases/recurrences occur often in FTC. Several clinicopathological prognostic factors for FTC have been identified, including patient age, tumor size, extrathyroid extensions, and distant metastasis at diagnosis (M1) [1-9].

Based on histology, the World Health Organization (WHO) currently classifies FTC into three categories: minimally invasive (mFTC), which has minimal capsular invasion (CI) only; encapsulated angioinvasive (eaFTC), which has vascular invasion (VI) with no or minimal CI; and widely invasive (wFTC), which has extensive CI [10]. We recently reported that the prognosis of VI-positive wFTC is significantly worse than that of VI-negative wFTC [11]. However, it remains unclear whether and how VI affects the prognosis of FTC other than wFTC. In this study, we investigated the prognostic factors, including CI and VI, of an entire series of FTC cases to identify FTC with high-risk features and evaluate the appropriateness of the WHO classification.

Submitted Feb. 18, 2022; Accepted Apr. 8, 2022 as EJ22-0077
Released online in J-STAGE as advance publication Apr. 29, 2022
Correspondence to: Yasuhiro Ito, Department of Surgery, Kuma Hospital, 8-2-35 Shimoyamate-dori, Chuo-ku, Kobe, Hyogo 650-0011, Japan.
E-mail: ito01@kuma-h.or.jp
List of abbreviations: CI, capsular invasion; CSS, cause-specific survival; DR-FS, distant recurrence-free survival; eaFTC, encapsulated angioinvasive follicular thyroid carcinoma; FTC, follicular thyroid carcinoma; mFTC, minimally invasive follicular thyroid carcinoma; wFTC, widely invasive follicular thyroid carcinoma; WHO, World Health Organization; VI, vascular invasion

Materials and Methods

Patients

We enrolled 523 patients who underwent initial surgery between January 1998 and December 2015 and were pathologically diagnosed with FTC. All hematoxylin and eosin-stained sections of these cases were reviewed by an expert pathologist (M.H.) to confirm the diagnosis. We excluded patients who were diagnosed

©The Japan Endocrine Society

with poorly differentiated carcinoma based on the present WHO classification [10], those who had other coexisting thyroid malignancies, and those who had an inadequate postoperative follow-up period (<12 months). This study was approved by the ethical committee of our hospital (approval number 20200709-1).

Evaluation of capsular and VI

For all cases, one pathologist (M.H.)—blinded to the patients' prognoses—reviewed the CI and VI. The definitions of CI and VI were based on the WHO classification [10]. According to the WHO classification, the FTC cases were divided into three groups: mFTC, eaFTC, and wFTC. Based on gross pathological examination, mFTC was defined as an encapsulated tumor that is indistinguishable from a benign adenoma, and wFTC as carcinoma that "shows extensive invasion of the thyroid and extra-thyroid soft tissues" [10]. Our pathologist's diagnostic criterion for a wFTC was an FTC with macroscopic (gross) CI.

For this study, the pathologist categorized the cases as either no invasion, microscopic (minimal) invasion, or macroscopic (wide) invasion; VI was defined as the presence of tumor cell nests covered with endothelium in a blood vessel within or beyond the capsule. Surgical specimens were cut at intervals of 3–4 mm. The number of VI sites was counted in all preparations by M.H., who classified the VI-positive cases into two categories: VI(1+), which had <4 VI foci, and VI(2+), which had ≥4 VI foci. This classification was adopted because previous studies demonstrated a difference in prognosis between the two grades of VI [12, 13].

Postoperative follow-up

The patients were followed-up once or twice per year using imaging studies (mainly ultrasonography) and blood examinations that included thyroid stimulating hormone, thyroglobulin, and (sometimes) anti-thyroglobulin antibody analyses. For high-risk cases, such as M1 and persistent disease, computed tomography and positron emission tomography were also performed, at the attending physicians' discretion. For patients who were referred to other hospitals, questionnaires were sent once a year to evaluate their conditions. The median follow-up period was 132 months (range: 12–277 months). Cases were regarded as showing carcinoma recurrence when recurrent structural lesions were detected on imaging studies, but not when thyroglobulin and/or anti-thyroglobulin antibody levels were elevated.

The endpoints of patients' prognoses were mainly distant recurrence-free survival (DR-FS). M1 cases were deleted from the analysis.

Statistical analyses

Univariate and multivariate analyses were performed using StatFlex software (Artec, Osaka, Japan). The chi-square test and stepwise regression analysis were used to compare variables. In time series analyses, the Kaplan–Meier method and log-rank test were used for univariate analysis. Logistic regression models were used for multivariate analysis. Statistical significance was set at $p < 0.05$, and $0.05 \leq p < 0.1$ was regarded as a strong tendency. The assumption of proportionality of explanatory variables was checked in the model.

Results

Background and clinicopathological features of patients

The background and clinicopathological features of the 523 patients included in the case series are summarized in Table 1. Sixteen patients (3.1%) had distant metastases at diagnosis and were classified as M1: three with mFTC, four with wFTC/VI(–), six with wFTC/VI(1+), and two with wFTC/VI(2+). The remaining patient had no CI or VI in the primary lesion but was diagnosed as FTC based on their M1 classification. On pathological examination, VI and wide CI were detected in 158 (30.2%) and 138 patients (26.4%), respectively.

Total thyroidectomy was performed as an initial surgery in 98 patients (18.7%); in the 425 patients who did not receive a total thyroidectomy, 33 (7.8%) underwent a complete total thyroidectomy as a second surgery at the physician's discretion (mainly because they were diagnosed with wFTC on postoperative pathology). Sixty-three patients underwent central node dissection; 11 (17.5%) of these patients also underwent lateral node dissection, mainly because they were considered to have a possibility of papillary thyroid carcinoma before surgery. Fifty-one patients (9.8%) underwent various doses (13–100 mCi) of radioactive iodine administration after total or complete total thyroidectomy for the purpose of scintigraphy, ablation, or adjuvant therapy.

Based on the diagnostic criteria of the WHO classification, 267 (51.0%), 117 (22.4%), and 138 patients (26.4%) were diagnosed with mFTC, eaFTC, and wFTC, respectively. The number of patients with wFTC was higher than that in our previous study [11]. In the previous study, our coauthor (M.H.) rechecked those cases that the attending pathologists diagnosed as wFTC. For the current study, M.H. rechecked all cases that were diagnosed as FTC, including mFTC: this accounts for the discrepancy in the number of wFTC patients between this study and our previous one. According to the degree of VI, eaFTC cases were subdivided into two categories [11, 12], eaFTC/VI(1+) and eaFTC/VI(2+); wFTC cases

Table 1 Backgrounds and clinicopathological features of 523 FTC patients

Variable	*N* (%)
Age ≥55 years	229 (43.8%)
<55 years	294 (56.2%)
Sex Male	86 (16.4%)
Female	437 (83.6%)
Tumor size >4 cm	246 (47.0%)
≤4 cm	277 (53.0%)
Distant metastasis at presentation	
Yes	16 (3.1%)
No	507 (96.9%)
Number of vascular invasion foci*	
0	365 (69.8%)
1–3	113 (21.6%)
≥4	45 (8.6%)
Capsular invasion	
None or minimal	385 (73.6%)
Wide	138 (26.4%)
Oxyphilic	
Yes	77 (14.7%)
No	446 (85.3%)
Extent of thyroidectomy at initial surgery	
Total	98 (18.7%)
Non-total	425 (81.3%)
Classification	
Widely invasive/VI(–)	97 (19.1%)
Widely invasive/VI(1+)	19 (3.6%)
Widely invasive/VI(2+)	22 (3.7%)
Encapsulated angioinvasive/VI(1+)	91 (17.4%)
Encapsulated angioinvasive/VI(2+)	26 (5.0%)
Minimally invasive	267 (51.0%)
Other**	1 (0.2%)

FTC: follicular thyroid carcinoma, VI: vascular invasion.
* In all preparations
** No capsular/vascular invasion; positive for distant metastasis at presentation

were subdivided into three categories: wFTC/VI(–), wFTC/VI(1+), and wFTC/VI(2+). As indicated above, one patient (0.2%) had no CI or VI but showed distant metastasis at presentation; this patient was also diagnosed with FTC.

Identification of risk factors for distant metastasis/recurrence in FTC patients

Sixteen M1 cases and 37 cases showed distant recurrence after surgery. We performed univariate analysis for various factors by adopting distant metastasis and recurrence as objective variables. Wide CI ($p = 0.008$), VI(1+) ($p = 0.021$), VI(2+) ($p < 0.001$), age ≥55 years ($p = 0.001$), male sex ($p = 0.001$), and non-oxyphilic histology ($p = 0.018$)—but not tumor size >4 cm ($p = 0.984$)—were significantly related to distant metastasis. By stepwise regression analysis, these six factors were independently related to distant metastasis/recurrence (Table 2).

Table 2 Multivariate analysis for predictors of distant metastasis/recurrence in follicular thyroid carcinoma

Variable	*p*-value	Odds ratio (95% CI)
Male sex	<0.001	3.600 (1.793–7,230)
Age ≥55 years	0.001	3.009 (1.579–5.737)
Tumor size >4 cm	0.492	0.800 (0.423–1.513)
Wide capsular invasion	0.031	2.037 (1.065–3.896)
VI(1+)	0.026	3.000 (1.466–6.137)
VI(2+)	<0.001	7.324 (3.192–16.807)
Non-oxyphilic	0.013	6.494 (1.495–28.571)

VI: vascular invasion, CI: confidence interval.

Prognostic factors for DR-FS in FTC patients

We performed time series analyses for DR-FS of patients with FTC in our series. To date, 37 patients have shown recurrence in distant organs. The organs to which FTC recurred were the lung ($n = 22$), bone ($n = 21$), adrenal gland ($n = 2$), and liver ($n = 1$). Nine patients showed recurrence to two or more organs.

The prognostic values for DR-FS of the patients' backgrounds and clinicopathological features were analyzed. Univariate analysis showed that age ≥55 years ($p = 0.004$), male sex ($p < 0.001$), and non-oxyphilic histology ($p = 0.043$) predicted a poor DR-FS (Fig. 1a–c); contrarily, tumor size >4 cm ($p = 0.234$) did not. As for VI, the DR-FS rate significantly decreased from VI(–) to VI(2+), including VI(–) *vs.* VI(1+) ($p = 0.011$) and VI(1+) *vs.* VI(2+) ($p = 0.014$) (Fig. 1d). In contrast, a wide CI based on our criterion did not affect the DR-FS of patients ($p = 0.494$) (Fig. 1e). Table 3 presents the results of multivariate analysis achieved by adopting variables with $p < 0.15$ after univariate analysis. Male sex, age ≥55 years, VI(1+), and VI(2+), and non-oxyphilic histology were shown to be independently related to DR-FS.

Table 4 shows the 5-, 10-, 15-, and 20-year DR-FS rates for all types of FTC. Comparison of DR-FS rates among FTCs based on subclassification indicated that the DR-FS rates did not significantly differ between wFTC/VI(1+) and wFTC/VI(2+) cases ($p = 0.513$). Therefore, we further analyzed these as a single group: wFTC/VI(1+/2+). Fig. 1f shows the Kaplan–Meier

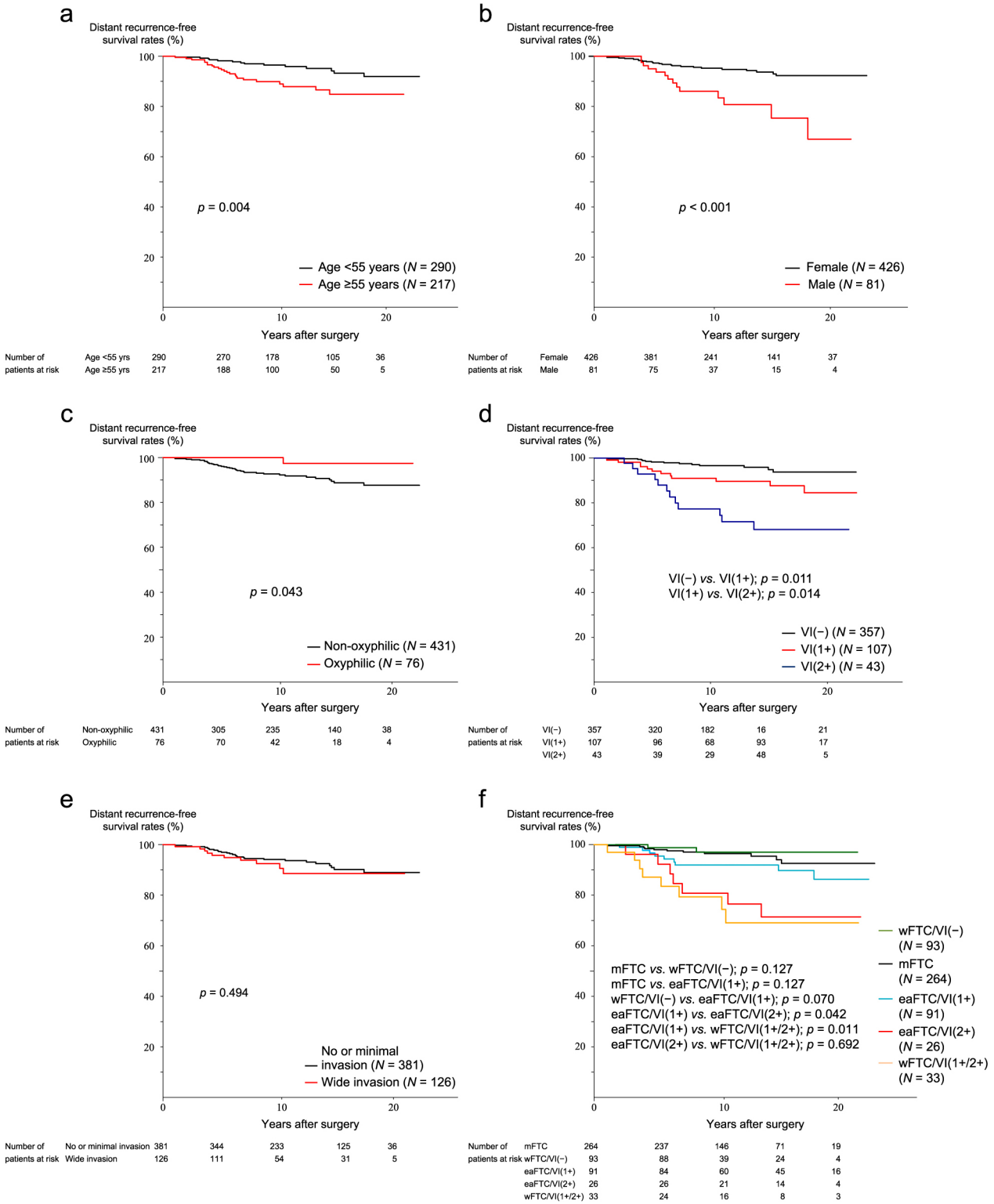

Fig. 1 Kaplan–Meier curves for distant recurrence-free survival of follicular thyroid carcinoma (FTC) patients (a) who were ≥55 years and <55 years of age; (b) who were males and females; (c) who had oxyphilic and non-oxyphilic histology; (d) who had VI(–), VI(1+), and VI(2+); (e) who had minimal and wide CI; and (f) who had mFTC, wFTC/VI(–), eaFTC/VI(1+), eaFTC/VI(2+), and wFTC(1+/2+). VI: vascular invasion, CI: capsular invasion, mFTC: minimally invasive FTC, eaFTC: encapsulated angioinvasive FTC, wFTC: widely invasive FTC.

Table 3 Multivariate analysis for predictors of distant recurrence in follicular thyroid carcinoma

Variable	*p*-value	Odds ratio (95% CI)
Male sex	0.001	3.338 (1.686–6.604)
Age ≥55 years	0.001	3.043 (1.543–6.002)
VI(1+)	0.021	2.542 (1.150–5.623)
VI(2+)	<0.001	8.030 (3.642–17.704)
Non-oxyphilic	0.041	8.000 (1.092–58.824)

VI: vascular invasion, CI: confidence interval.

Table 4 Distant recurrence-free survival rates of patients with follicular thyroid carcinoma

Carcinoma type	5-year	10-year	15-year	20-year
mFTC	98.0%	96.5%	94.1%	92.6%
wFTC/VI(–)	98.8%	97.0%	97.0%	97.0%
eaFTC/VI(1+)	94.3%	91.9%	91.9%	86.3%
eaFTC/VI(2+)	96.2%	80.8%	71.4%	71.4%
wFTC/VI(1+/2+)	87.1%	79.3%	69.1%	69.1%

FTC: follicular thyroid carcinoma, VI: vascular invasion, mFTC: minimally invasive FTC, eaFTC: encapsulated angioinvasive FTC, wFTC: widely invasive FTC.

curves for DR-FS of the five categories of FTC. The DR-FS rate did not significantly differ between mFTC and wFTC/VI(–) cases. The DR-FS in eaFTC/VI(1+) cases tended to be worse than that in wFTC/VI(–) cases, although the difference was not significant (p = 0.070). The DR-FS rate in eaFTC/VI(2+) cases was significantly worse than that in eaFTC/VI(1+) cases (p = 0.042), mFTC cases (p < 0.001), and wFTC/VI(–) cases (p = 0.001). The DR-FS rate in wFTC/VI(1+/2+) cases was significantly worse (p = 0.011) than that in eaFTC/VI (1+) cases; however, it did not differ from that in eaFTC/VI(2+) cases (p = 0.692).

Cause-specific survival (CSS) analysis of FTC patients

To date, 10 patients have died of distant metastasis/recurrence of thyroid carcinoma; 6 of these patients had distant metastasis at initial surgery, which is a significant predictor of carcinoma death (Fig. 2). Of these 10 patients, 5 were male, 8 were ≥55 years of age at initial surgery, and 6 were positive for VI. Additionally, 1, 3, 3, and 3 patients were diagnosed with mFTC, eaFTC/VI(2+), wFTC/VI(–), and wFTC/VI(1+/2+), respectively. All of these FTCs were non-oxyphilic.

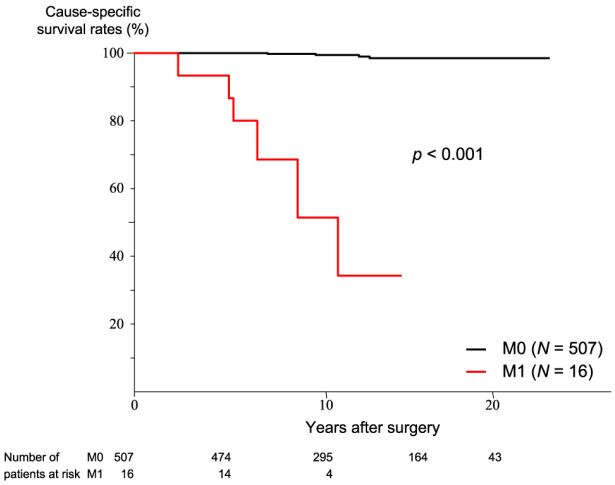

Fig. 2 Kaplan–Meier curves for cause-specific survival of M0 and M1 follicular thyroid carcinoma patients.

Discussion

In this study, we investigated prognostic factors for FTC and evaluated the appropriateness of the newest WHO classification. In the analysis that excluded time series, male sex, older age (≥55 years), wide CI, VI, and non-oxyphilic histology were related to distant metastasis/recurrence. Time series analyses revealed that older age was an independent predictor of distant recurrence, which is consistent with the findings of previous studies [1-9]. Furthermore, male sex, both VI(1+) and VI(2+), and non-oxyphilic histology were regarded as significant predictors of distant recurrence; in contrast, tumor size >4 cm and wide CI were not. Previous studies showed that male sex predicted a poor prognosis for patients with FTC, although the numbers of enrolled patients were small [6, 7]. Thyroid carcinomas in male patients could be detected and diagnosed in more advanced stage than those in female patients. However, in this study, multivariate analysis showed that male sex was an independent predictor of distant recurrence. Further studies using pathological and molecular aspects are needed to elucidate this issue.

With respect to oxyphilic FTC, previous studies reported controversial findings [8, 14-16]; nevertheless, two high-volume centers in Japan showed that the prognosis of oxyphilic and non-oxyphilic FTCs did not significantly differ [17, 18]. In this study's patient series, the prognosis of non-oxyphilic FTC was worse than that of oxyphilic FTC both on univariate and multivariate analyses. The reason for this discrepancy remains unknown and requires further elucidation.

In 2007, before the publication of the newest WHO classification, we showed that FTC with wide CIs had a significantly worse prognosis than those with minimal CI

[17]. However, that study included wFTC/VI(–) and wFTC/VI(1+/2+) in the wide-CI group and mFTC and eaFTC in the minimal-CI group; these are changed in the present WHO classification [10]. In a study published in 2021, we showed that the prognoses of wFTC/VI(1+/2+) cases were significantly worse than those of wFTC/VI(–) cases [11]. Further, in 2013, we demonstrated that in the series of mFTC cases, defined according to the previous WHO classification, extensive VI significantly affected patients' prognoses [19]. These findings indicate that VI is an important prognostic factor for FTC.

In this study, we subdivided VI-positive cases into two categories (namely, VI(1+) and VI(2+)) according to the number of invasion sites and in line with previous publications [11, 12]. In the entire series, the DR-FS became poorer in a step-by-step manner from VI(–) to VI(2+), and the prognoses of eaFTC/VI(2+) cases were significantly worse than those of eaFTC/VI(1+) cases, suggesting that the degree of VI significantly affects patients' prognoses in eaFTC cases. As the DR-FS rate in eaFTC/VI(2+) cases did not significantly differ from that in wFTC/VI(1+/2+) cases, significant VI could be considered a high-risk feature of distant recurrence. The DR-FS rates did not significantly differ among eaFTC/VI(1+), mFTC, and wFTC/VI(–) cases; however, the DR-FS rate of eaFTC/VI(1+) tended to be poorer than that of wFTC/VI(–) (p = 0.070). Furthermore, in the entire series, VI(1+) was determined to be an independent predictor of distant recurrence on multivariate analysis. Therefore, if a larger number of cases were analyzed, eaFTC/VI(1+) cases might show worse prognoses than VI-negative FTC cases. A recent study enrolling 264 patients with eaFTC reported that disease-free survival and CSS rates significantly differed between eaFTC with VI ≥2 and eaFTC with VI = 1, but not between eaFTC with VI ≥4 and eaFTC with VI = 1–3 [20]. Multivariate analysis showed that age ≥55 years and VI ≥2 were independent predictors of carcinoma recurrence. The study design is novel in that the study focused on eaFTC only, as opposed to previous studies [21]. While the cutoff for the number of VI differs between their study and ours, the number of VI probably has a significant influence on the prognosis of patients with eaFTC.

In our entire series, the DR-FS rate of FTC cases with wide CI did not differ from that of FTC cases with no or minimal CI, suggesting that the degree of CI does not significantly affect DR-FS. Indeed, wFTC/VI(–) cases showed similar DR-FS to mFTC cases in our study. According to the WHO classification, mFTC is defined as an encapsulated tumor that is macroscopically indistinguishable from benign adenoma. wFTC is defined as an FTC showing "extensive invasion of the thyroid and extra-thyroidal soft tissues" [10]. The classification also states that "vascular invasion is often prominent, but alone, does not categorize a FTC as widely-invasive." Furthermore, it states that "more important than the extent of thyroid or soft tissue invasion is the identification of extensive angioinvasion, which is associated with a worse prognosis." This indicates that while VI has a strong prognostic impact, wide CI is mandatory for the diagnosis of wFTC [10]. However, the definition of "extensive invasion of the thyroid" is unclear. According to previous studies, observer variation in the diagnosis of FTC more often occurs in tumors with minimal or questionable CI [22, 23]. On the other hand, observer variation in the diagnosis of malignancy could less likely occur in tumors with nonminimal CI; nonetheless, the equivocal definition of wide CI in the present WHO classification may cause observer variation in the diagnosis whether the tumor is minimally or widely invasive. Indeed, Rosai *et al.* described that the differentiation between wFTC and mFTC largely depends on "the liberality of the pathologist in making the former diagnosis" [24]. Moreover, the description lacks clear information on how to classify an FTC with a wide CI but no VI; in this study, we diagnosed such cases as wFTC. Pathologists in our institution, including M.H., diagnosed FTC with macroscopic CI as wFTC; however, we recommend that the WHO classification should provide a more concrete and detailed definition for "extensive extension of the thyroid." It may also be better to further subdivide cases of FTC with macroscopic CI based on the degree of invasion. Furthermore, in our series, very few cases showed invasion of extrathyroid tissues (T3b or T4a cases); if we could analyze a series with a larger number of such cases, the results might differ from those of this study. The appropriateness of classifying an FTC with wide CI but without VI as a wFTC should also be carefully considered. In our series, the distant recurrence rate did not differ between patients with wFTC/VI(–) and those with mFTC. This finding strongly indicates that VI is a very important prognostic factor. Based on the results of this study, VI positivity could be mandatory for the diagnosis of wFTC.

There were 16 M1 cases in our series, among which were three cases of mFTC and four cases of wFTC/VI(–), but none of eaFTC. In addition, on analyses where M1 and distant recurrence were the objective variables, wide CI was significantly related to distant metastasis/recurrence. These findings raise the question, which remains a concern, about whether mFTC and wFTC/VI(–) are truly indolent and always show favorable outcomes. Therefore, further studies with a large number of enrolled patients and a longer follow-up period should be conducted to draw more confirmative conclusions.

Only 10 patients died of thyroid carcinoma in our

series, and M1 significantly affected CSS. Because of the small number of patients who died from thyroid carcinoma, it is impossible to perform statistical analysis for the death of patients with carcinoma. However, other than M1, male sex, age ≥55 years at initial surgery, non-oxyphilic histology, and being positive for VI might be prognostic indicators, because the incidence of having one or more of these factors was high in patients who died of thyroid carcinoma. However, 1 and 3 patients were originally diagnosed with mFTC and wFTC/VI(–), respectively. This again raises the question about whether minimal CI and VI-negativity can be claimed to be confirmative signs of a favorable prognosis.

Our study has some limitations. This was a retrospective study, and the therapeutic strategy for each patient was not uniform in the case series. In addition, the number of patients and the length of the follow-up period were not adequate for the analysis of patients' CSS. Furthermore, because the subdivisions of FTC are not clearly defined in the current WHO classification, it is possible that different pathologists might have diagnosed the cases in this series differently, thereby producing rather diverse results. Reproducibility could be secured if diagnoses were based on our interpretation. Despite these limitations, this study clearly demonstrates the prognostic value of various clinicopathological features, including the degree of VI.

In summary, cases of FTC without VI showed favorable DR-FS regardless of the degree of CI, and VI had a strong prognostic effect. Our findings strongly suggest that both wFTC/VI(1+/2+) and eaFTC/VI(2+) cases should be considered as high-risk cases for distant recurrence. Regarding the appropriateness of the WHO classification, our findings suggest that eaFTC cases should be subdivided according to the degree of VI, and the wFTC category should be restricted to VI-positive cases. In addition, a more concrete definition of CI corresponding to wide invasion or further subdivision of wide CI is recommended.

Disclosure

The authors declare that they have no competing financial interests.

Funding

There is no funding information to declare.

References

1. Passler C, Scheuba C, Prager G, Kaczirek K, Kaserer K, *et al.* (2004) Prognostic factors of papillary and follicular thyroid cancer: differences in an iodine-replete endemic goiter region. *Endocr Relat Cancer* 11: 131–139.
2. Su DH, Chang TC, Chang SH (2019) Prognostic factors on outcomes of follicular thyroid cancer. *J Formos Med Assoc* 118: 1144–1153.
3. Yamazaki H, Sugino K, Katoh R, Matsuzu K, Masaki C, *et al.* (2021) Outcomes for minimally invasive follicular thyroid carcinoma in relation to the change in age stratification in the AJCC 8th edition. *Ann Surg Oncol* 28: 3576–3583.
4. Sugino K, Ito K, Nagahama M, Kitagawa W, Shibuya H, *et al.* (2011) Prognosis and prognostic factors for distant metastases and tumor mortality in follicular thyroid carcinoma. *Thyroid* 21: 751–757.
5. Sugino K, Kameyama K, Ito K, Nagahama M, Kitagawa W, *et al.* (2012) Outcomes and prognostic factors of 251 patients with minimally invasive follicular thyroid carcinoma. *Thyroid* 22: 798–804.
6. Stenson G, Nilsson IL, Mu N, Larsson C, Lundgren CI, *et al.* (2016) Minimally invasive follicular thyroid carcinomas: prognostic factors. *Endocrine* 53: 505–511.
7. Zidan J, Kassem S, Kuten A (2000) Follicular carcinoma of the thyroid gland: prognostic factors, treatment, and survival. *Am J Clin Oncol* 23: 1–5.
8. Besic N, Auersperg M, Golouh R (1999) Prognostic factors in follicular carcinoma of the thyroid—a multivariate survival analysis. *Eur J Surg Oncol* 25: 599–605.
9. Ríos A, Rodríguez JM, Ferri B, Martínez-Barba E, Torregrosa NM, *et al.* (2015) Prognostic factors of follicular thyroid carcinoma. *Endocrinol Nutr* 62: 11–18.
10. Lloyd RV, Osamura RY, Kloppel G, Rosai J (eds.) (2017) WHO classification of tumours of endocrine organs (4th). IARC, Lyon, France.
11. Ito Y, Hirokawa M, Fujishima M, Masuoka H, Higashiyama T, *et al.* (2021) Prognostic significance of vascular invasion and cell-proliferation activity in widely invasive follicular carcinoma of the thyroid. *Endocr J* 68: 881–888.
12. Lang W, Choritz H, Hundeshagen H (1986) Risk factors in follicular thyroid carcinomas. A retrospective follow-up study covering a 14-year period with emphasis on morphological findings. *Am J Surg Pathol* 10: 246–255.
13. Collini P, Sampietro G, Pilotti S (2004) Extensive vascular invasion is a marker of risk of relapse in encapsulated non-Hurthle cell follicular carcinoma of the thyroid gland: a clinicopathological study of 18 consecutive cases from a single institution with a 11-year median follow-up. *Histopathology* 44: 35–39.
14. Ernaga Lorea A, Migueliz Bermejo I, Anda Apiñániz E, Pineda Arribas J, Toni García M, *et al.* (2018) Comparison of clinical characteristics of patients with follicular thyroid carcinoma and Hurthle cell carcinoma. *Endocrinol*

Diabetes Nutr (Engl Ed) 65: 136–142.
15. Grani G, Lamartina L, Durante C, Filetti S, Cooper DS (2018) Follicular thyroid cancer and Hurthle cell carcinoma: challenges in diagnosis, treatment, and clinical management. *Lancet Diabetes Endocrinol* 6: 500–514.
16. Yutan E, Clark OH (2001) Hurthle cell carcinoma. *Curr Treat Options Oncol* 2: 331–335.
17. Ito Y, Hirokawa M, Higashiyama T, Takamura Y, Miya A, *et al.* (2007) Prognosis and prognostic factors of follicular carcinoma in Japan: importance of postoperative pathological examination. *World J Surg* 31: 1417–1424.
18. Sugino K, Kameyama K, Ito K, Nagahama M, Kitagawa W, *et al.* (2013) Does Hurthle cell carcinoma of the thyroid have a poorer prognosis than ordinary follicular thyroid carcinoma? *Ann Surg Oncol* 20: 2944–2950.
19. Ito Y, Hirokawa M, Masuoka H, Yabuta T, Kihara M, *et al.* (2013) Prognostic factors of minimally invasive follicular thyroid carcinoma: extensive vascular invasion significantly affects patient prognosis. *Endocr J* 60: 637–642.
20. Yamazaki H, Katoh R, Sugino K, Matsuzu K, Masaki C, *et al.* (2022) Encapsulated Angioinvasive follicular thyroid carcinoma: prognostic impact of the extent of vascular invasion. *Ann Surg Oncol* doi: 10.1245/s10434-022-11401-x. Online ahead of print.
21. Matsuura D, Ganly I (2022) New insights on the importance of the extent of vascular invasion in encapsulated angio-invasive follicular thyroid carcinoma. *Ann Surg Oncol* doi: 10.1245/s10434-022-11405-7. Online ahead of print.
22. Zhu Y, Li Y, Jung CK, Song DE, Hang JF, *et al.* (2020) Histopathologic assessment of capsular invasion in follicular thyroid neoplasms- an observer variation study. *Endocr Pathol* 31: 132–140.
23. Franc B, de La Salmoniere P, Lange F, Hoang C, Louvel A, *et al.* (2003) Interobserver and intraobserver reproducibility in the histopathology of follicular thyroid carcinoma. *Hum Pathol* 34: 1092–1100.
24. Rosai J, Carcangiu ML, DeLellis RA (1992) Tumors of the thyroid gland. Armed Forces Institute of Pathology, Washington, DC., USA.