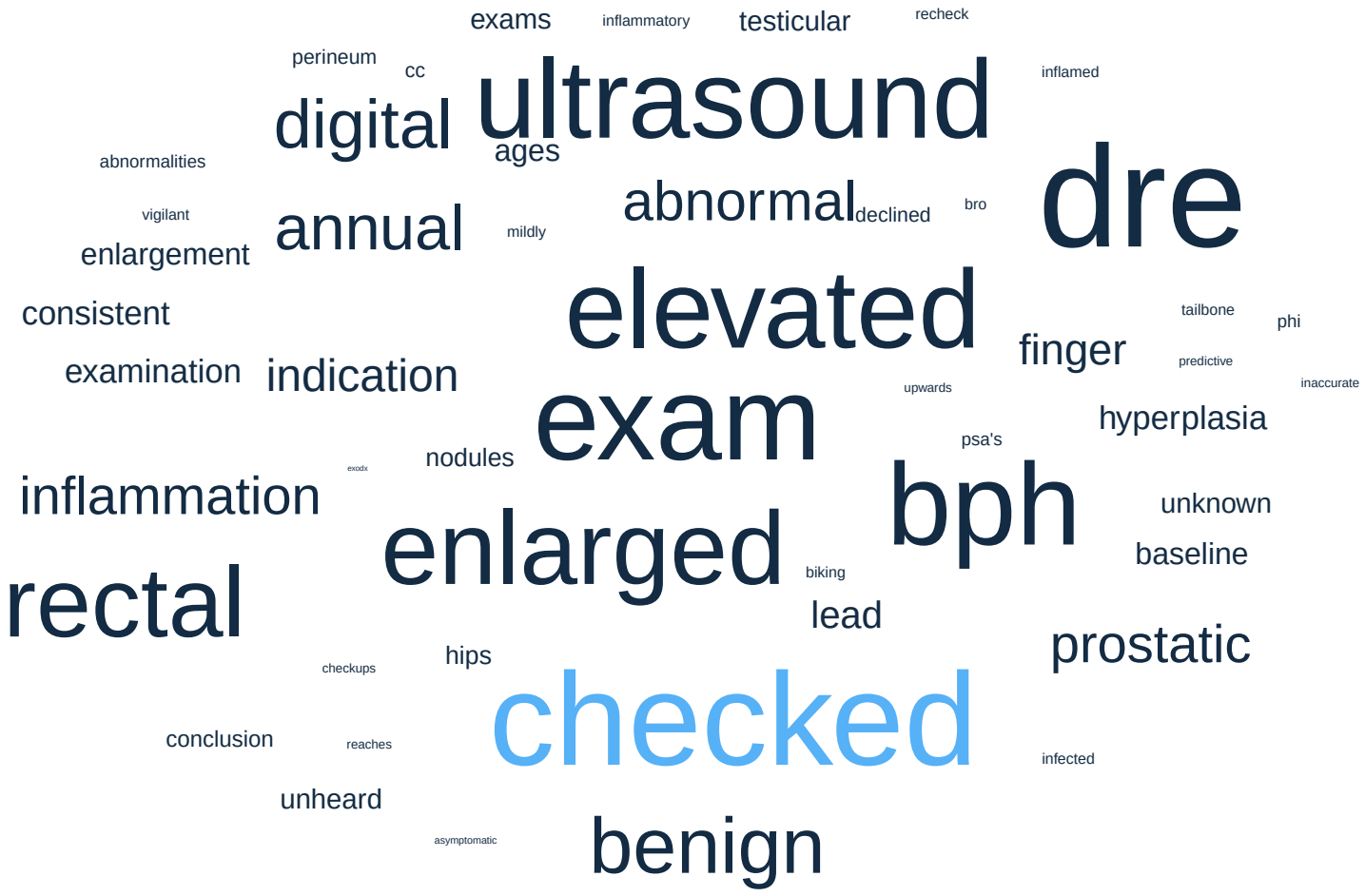
exams
inflammatory
testicular
recheck
perineum
cc
ultrasound
inflamed
digital
ages
abnormalities
dre
abnormal
declined
bro
vigilant
annual
mildly
enlargement
elevated
consistent
tailbone
phi
finger
predictive
examination
indication
inaccurate
upwards
exam
hyperplasia
psa's
nodules
exodx
inflammation
bph
unknown
enlarged
baseline
biking
rectal
lead
prostatic
hips
checkups
checked
conclusion
reaches
infected
unheard
benign
asymptomatic