Journal of Neuro-Oncology (2005) 73: 19–27
DOI 10.1007/s11060-004-3013-3
© Springer 2005

Laboratory Investigation

HUlip, a human homologue of *unc*-33-like phosphoprotein of *Caenorhabditis elegans*; Immunohistochemical localization in the developing human brain and patterns of expression in nervous system tumors

Yoon-La Choi[1,2], Chong Jai Kim[2,3], Tatsuya Matsuo[4], Carlo Gaetano[4], Rita Falconi[5], Yeon-Lim Suh[1], Seok-Hyung Kim[2], Young Kee Shin[2], Seong Hoe Park[2], Je Geun Chi[2] and Carol J. Thiele[4]
[1]*Department of Diagnostic Pathology, Samsung Medical Center, Sungkyunkwan University School of Medicine;* [2]*Department of Pathology, Seoul National University College of Medicine;* [3]*Laboratory of Pathology, Clinical Research Institute, Seoul National University Hospital, Seoul, Korea;* [4]*Cell and Molecular Biology Section, Pediatric Oncology Branch, Center for Cancer Research, National Cancer Institute, Bethesda, Maryland, USA;* [5]*Laboratory of Molecular Oncology, Instituto Regina Elena, Rome, Italy*

Key words: brain tumor, development, hUlip, nervous system, neuron

Summary

HUlip is a human homologue of a *C. elegans* gene, unc-33, that is developmentally regulated during maturation of the nervous system. HUlip is highly expressed only in the fetal brain and spinal cord, and is undetected in the adult brain. The purpose of this study was to investigate the pattern of hUlip expression in the developing human brain and nervous system tumors. Ten human brains at different developmental stages and 118 cases of nervous system tumor tissues were examined by immunohistochemistry. Twelve related tumor cell lines were also analyzed by northern blotting and immunoblotting. HUlip was expressed in late fetal and early postnatal brains; strongly in the neurons of the brain stem, basal ganglia/thalamus, and dentate gyrus of the hippocampus, and relatively weakly in the cerebral and cerebellar cortex. Among tumors, hUlip expression was easily detected in tumor cells undergoing neuronal differentiation such as ganglioneuroblastomas and ganglioneuromas. Furthermore, hUlip immunoreactivity was also found in various brain tumors showing neuronal differentiation: central neurocytomas (6 of 6 cases were positive), medulloblastomas (5/11), atypical teratoid rhabdoid tumor (1/1) and gangliogliomas (4/7). Some astrocytic tumors also showed weak positivity: astrocytomas (1 of 5 cases), anaplastic astrocytomas (2/5), and glioblastomas (3/11). Subependymal giant cell astrocytomas and subependymomas, which are of controversial histogenetic origin, showed strong hUlip immunoreactivity. The results of this study indicate that the expression of hUlip protein is distinctly restricted to the late fetal and early postnatal periods of human nervous system development and to certain subsets of nervous system tumors. The exact function of hUlip needs to be further clarified; yet the results of our study strongly imply that hUlip function is important in human nervous system development and its aberrant expression in various types of nervous system tumors suggests a role of hUlip as an oncofetal neural antigen.

Introduction

One of the genes whose expression increased in retinoic acid (RA)-treated, differentiated neuroblastoma cells is *hUlip*, the human homologue of the *Caenorhabditis elegans* (*C. elegans*) uncoordinated 33 (*unc*-33)-like phosphoprotein gene [1]. Ulip (unc-33-like phosphoprotein) cytosolic phosphoprotein shows structural and functional homologies with the *C. elegans* gene product unc-33, which is associated with neuritic outgrowth and axonal guidance. In *C. elegans*, mutations in unc-33 lead to premature termination of axonal processes and severely uncoordinated nematode movement [2,3]. This protein is known variously as TOAD-64 (turned on after divisions) [4], CRMP (collapsin response mediator protein) [5], DRP (dihydropyrimidinase related protein) [6], or C-22 [7]. In rodents, Ulip is highly expressed in neural cells of the developing brain, with its highest expression occurring at the end of embryonic life during the period of maximal axonal growth [5,8]. At least six mammalian homologues of unc-33 have been recognized (Table 1), and they are expressed in distinct, yet partially overlapping, patterns during the development of the nervous system.

Ulip1/hUlip/CRMP-4/DRP-3 is highly expressed in fetal, but not adult, neural tissues, as determined by in situ analysis and evaluation of total RNA [1]. Animal studies have shown that Ulip1 and Ulip3 are highly expressed from E16 (embryonic day 16) until P6 (postnatal day 6) and then are markedly decreased. Their expression is hardly detectable in the adult brain. The function of the unc-33 gene family is largely unknown. Ulip2/CRMP-2/CRMP62 may be part of the intracellular signaling components of the collapsin-stimulated collapse of growth cones that is important in developing neurons during the process of neuronal path finding [9]. The expression of Ulip2/CRMP-2 prior to neuritogenesis in postmitotic neurons of the

developing cerebral cortex supports a role of this gene family in neuronal differentiation [4,8]. Interestingly, members of the Ulip/CRMP family have been implicated in human neurodegenerative disorders. In paraneoplastic, autoimmune, neurodegenerative disorders involving the cerebellum and dentate gyrus, some patients develop autoantibodies (anti-CV2 antibodies) that recognize the Ulip/CRMP protein [10]. Serologic tests revealed that a neuronal autoantibody in optic neuropathy and cerebellar ataxia associated with small cell carcinoma of the lung was specific for Ulip6/CRMP-5 [11].

Although hUlip seems to be important in neurobiological events during ontogeny and early postnatal development, its expression pattern in the developing human brain has not been investigated to date. The increased expression of hUlip in cell lines undergoing neuronal differentiation, along with the high expression of hUlip in the fetal brain and spinal cord [1], led us to extend our analysis of hUlip expression in human brains. In this study, we investigated the temporal and spatial changes in hUlip expression during human brain development and found that hUlip expression markedly diminished after the postnatal period. Additional screening of hUlip expression in nervous system tumors demonstrated selective expression in limited subsets of tumors. Expression of hUlip is de-repressed in certain nervous system tumors, indicating the 'oncofetal' nature of hUlip in these tumors.

Materials and methods

Cell culture

SMS-KCNR and SH-SY5Y neuroblastoma cell lines were cultured as previously described [1,12,13] in 4-chamber slides, and were treated with all-trans retinoic acid (Sigma, St. Louis, MO, USA), at the concentration of 5 μM, and control solvent. Cells were grown for 5 days, washed with PBS and fixed with 4% paraformaldehyde in PBS. For the screening of hUlip expression in brain tumor cell lines, human medulloblastoma (Daoy, D283: American Type Culture Collection) and glioblastoma cell lines (A172, T98G, U87MG: American Type Culture Collection, SF539: Dr. Mark Rosenblum, University of California at San Francisco, USA) were cultured in Dulbecco's modified Eagle's medium containing 10% fetal bovine serum, 4.5 gm/l glucose, and antibiotics in the presence and absence of RA.

Table 1. Nomenclature of the Ulip family

Ulip1	Ulip2	Ulip3	Ulip4	Ulip5	Ulip6
Crmp-4	Crmp-2	Crmp-1	Crmp-3	DHP	Crmp-5
DRP-3	DRP-2	DRP-1			
hUlip	Toad-64	C-22			
nsp-1	Crmp-62				

Immunoblotting

Cells were lysed in ice-cold Tris-buffered saline (TBS) containing 1% Nonidet P-40, 10% glycerol, 1 mM phenylmethylsulfonyl fluoride, 10 mg/ml aprotinin, 1 mg/ml leupeptin, and 500 mM sodium orthovanadate for 30 min on ice. The concentration of the protein was measured with Bradford assay kit (Bio-Rad Laboratories Inc., Hercules, CA, USA) and 20 μg of protein from each lysate was electrophoresed in 8% SDS-polyacrylamide gel. Proteins were subsequently transferred to nitrocellulose membrane (Protran, Schleicher & Schuell, Keene, NH, USA) at 140 V for 2 h, and then blocked with 10% non-fat dried milk containing 0.5% Tween 20. The membrane was incubated with 1: 500 diluted primary antibody for an hour, washed three times with TBS-0.5% Tween 20 (TBS-T) and incubated with 1: 1000 diluted horseradish peroxidase (HRP)-conjugated goat anti-rabbit IgG for an hour. After washing, signals were detected with enhanced chemiluminescence reagents (Amersham Life Science Inc., Arlington Heights, IL, USA).

Northern blotting

Total RNA was isolated by repeated phenol–chloroform extractions and isopropanol precipitations. Twenty-five micrograms of total RNA were denatured by heating in formamide/formaldehyde at 65 °C for 20 min and then subjected to electrophoresis in a 1.2% agarose gel containing 2.2 M formaldehyde. The RNA was then vacuum blotted onto nylon membranes (Hybond-N^+; Amersham Life Science Inc.), and the filters were UV cross-linked. The cloned cDNA was used as a probe. The cDNA inserts were labeled with [^{32}P]dATP (Amersham Life Science Inc.) using hexamer primers. Prehybridization, hybridization, washing, and autoradiography were performed as previously described in detail [14].

Immunohistochemistry

Ten specimens of human fetal and postnatal brains were procured at the time of elective termination of pregnancy or autopsy in the Department of Pathology, Seoul National University Children's Hospital (Table 2). The tissues were fixed in 10% buffered formalin, and coronal or sagittal sections were obtained and paraffin-embedded. Five micrometer-thick paraffin sections were obtained on silanized slides, and subsequently submitted for analysis. Two term neonates who died of non-neurological causes shortly after birth were also examined at autopsy in a similar manner. None of the fetuses had central nervous system malformations except a case with hydrocephalus, severe hypoxic/ischemic changes, hemorrhages, and other significant lesions of the brain, grossly or histologically. A total of 118 nervous system tumors, composed of 31 cases of neuroblastic tumors and 87 of brain tumors, were selected from the files of the Department of Pathology, Seoul National University Hospital. All cases were

diagnosed based on the combination of clinical, histopathologic, immunohistochemical, and ultrastructural findings. Neuroblastic tumors were classified as neuroblastoma, ganglioneuroblastoma, and ganglioneuroma [14].

Representative sections of each normal brain and tumor were stained with hematoxylin-eosin (H&E) for histological examination. For immunohistochemistry, sections were deparaffinized in xylene and rehydrated through graded ethanol. Endogenous peroxidase activity was quenched by incubation in 3% hydrogen peroxide in methanol for 10 min. After washing with distilled water and TBS, the sections were incubated with 8% casein for 30 min at room temperature and then incubated with 1:1000 diluted cocktail of polyclonal rabbit anti-peptide A and anti-peptide B (corresponding to hUlip amino acid residues 499–511 and 486–500, respectively) at 4 °C overnight. A pilot study demonstrated indistinguishable immunoreactivity with both of the anti-hUlip peptide antibodies in immunoblot analysis and immunohistochemistry. The specificity of the antibodies was described previously [1] and was also analyzed by peptide competition. Sections were incubated with biotinylated goat anti-rabbit IgG for 30 min at room temperature, and then incubated with streptavidin–peroxidase conjugate for 30 min at room temperature. 3,3′-Diaminobenzidine was used as a chromogen (DiNonA, Seoul, Korea). After incubation with primary antibody, each step was followed by meticulous washing with TBS. Immunoreactivity was lost with omission of primary antibody, application of normal rabbit serum, and application of primary antibody adsorbed with immunogenic peptide (data not shown). Sections were counterstained with Meyer's hematoxylin. The pattern of hUlip expression was graded as negative (−), trace (±), positive (+), and strongly positive (++) according to the intensity of immunoreactivity in each specimen.

Results

HUlip expression in neuroblastoma cell lines

To evaluate hUlip protein expression, we utilized our previously characterized antibodies to hUlip peptides A and B that specifically recognize hUlip, as opposed to other unc-33 related proteins [1]. The anti-hUlip antibodies (rabbit, polyclonal anti-peptide A and anti-peptide B sera) detected proteins of 58, 60, 65, and 70 kD in RA-treated neuroblastoma cells (Figure 1a) and immunoreactivity was blocked by incubation of the immunogenic peptides with the primary antibodies (Figure 1b). The multiple bands corresponded to different phosphorylated forms as well as a differentially spliced hUlip (TUC4b) isoform [15]. SMS-KCNR and SH-SY5Y cell lines extended neurites following RA treatment. In untreated SH-SY5Y cells, hUlip expression was observed as diffuse, weak or barely discernible cytosolic staining (Figure 1c-a). In RA-treated differentiated cells, intense hUlip immunoreactivity was observed in the cytoplasm and neurites (Figure 1c-b).

Table 2. Clinicopathologic findings of fetuses used in this study

		Age	Sex	Diagnosis
I	1	GA18 wks	M	Chorioamnionitis
	2	GA 19wks + 4ds	F	Chorioamnionitis
II	3	GA 24wks + 1ds	M	Chorioamnionitis
	4	GA 24wks + 6ds	M	Asplenia
III	5	GA 31wks + 1ds	M	Hypoplastic heart syndrome
	6	GA 30 wks	M	Chorioamnionitis
IV	7	GA 37 wks	F	Hydrocephalus
	8	GA 38 wks	M	TAPVR
V	9	PN 3mo + 26ds	M	SIDS
	10	PN 4mo	F	SIDS

GA: gestational age, PN: post-natal age, wks: weeks, ds: days, mo: months, M: male, F: female, TAPVR: total anomalous pulmonary venous return, SIDS: sudden infant death syndrome.

Immunohistochemical localization of hUlip in normal developing human brains

In general, hUlip expression was limited to neuronal cytoplasm mainly in the late fetal and early postnatal period. Table 3 summarizes the developmental change of hUlip protein expression in various regions of the brain. Neither immature nor mature glial cells, including radial glia and Bergmann cells, were reactive for hUlip. Tegmental neurons and internal granule cells of the cerebellum were among the earliest neurons to exhibit hUlip immunoreactivity in the brain of the early fetus of 18–19 weeks gestation (Figure 2A). Undifferentiated neuroepithelial cells of the ventricular zone were not immunoreactive. The great majority of postmitotic, premigratory cells of the germinal matrix were also nonreactive. The extent of hUlip expression in the brain stem increased with gestational age. In fetuses of 30 weeks gestation, occasional cells in the basal ganglia/thalamus and basis pontis also showed hUlip immunoreactivity. However, weak hUlip immunoreactivity was found in the cerebral and cerebellar cortex only from 37 weeks of gestation and postnatally. The neurons of the brain stem showed highest expression in 38-week fetus (Figure 2B), while the immunoreactivity rapidly declined after birth. Within the cortical plate of fetuses of 20 weeks gestation or less, all neurons of the deep stratum, corresponding to the future layers 4–6, showed hUlip positive cells, but more superficial stratum that would become layers 2 and 3 showed only occasional reactive cells. By 24 weeks gestation, most neurons of both deep and superficial portions of the cortical plate showed weak immunoreactivity. The Cajal-Retzius cells of the molecular zone were notable by their lack of immunoreactivity to hUlip at all developmental ages examined.

In the cerebellar cortex, the external granule cells showed no immunoreactivity in either the superficial proliferative or deeper premigratory zones, although the internal granule cells, which are postmigratory and more mature, showed trace immunoreactivity until term. Purkinje cells were not reactive until 30 weeks, after which they became strongly reactive. Immunoreactivity

was slightly decreased postnatally. Neurons of the dentate nucleus were non-reactive. Among brainstem neurons, the inferior olivary nuclei remained non-reactive until 30 gestational weeks, as in Purkinje cells, but the reactivity remained until the postnatal period. The basal pontine nuclei were reactive from 24 weeks gestation and the tegmental neurons from 18 weeks. The immunoreactivity was sustained until term. Tegmental neurons were reactive from 18 weeks. The neurons of the hippocampus were available from 38 weeks gestation and showed hUlip reactivity in dentate gyrus. The three cases of normal adult brain tissues showed trace hUlip immunoreactivity only in the dentate gyrus (data not shown).

HUlip expression in neuroblastoma and brain tumor cell lines

Previously, we have shown that hUlip mRNA increases in neuroblastoma cell lines induced to differentiate with RA and in tissues. HUlip is highly expressed in the fetal brain and spinal cord, but not in the adult brain [1]. Given the expression of hUlip in both central and peripheral nervous system tissues, we extended our analysis to tumor cell lines derived from these tissues. Northern analysis of 25 μg of total RNA indicated that hUlip is expressed in RA-treated SMS-KCNR cells but barely in peripheral neuroepithelioma cell lines (TC32, CHP100, SK-N-MC) (Figure 3a). A Ewing's sarcoma cell line TC106 did not express hUlip mRNA. HUlip expression was not induced by RA in the peripheral neuroepithelioma or Ewing's sarcoma cell lines (date not shown). We did detect a low level of expression in Daoy medulloblastoma cell line (Figure 3a). Analysis of control and RA-treated brain tumor cell lines showed variable expression of hUlip mRNA in glioblastoma cell lines (A172, T98G, SF539), as well as in another medulloblastoma cell line D283 (Figure 3b). Unlike neuroblastoma cells, RA did not dramatically alter hUlip mRNA expression level in these brain tumor cell lines.

Immunoblotting analysis demonstrated that hUlip is variably expressed in glioblastoma cell lines as well as in two medulloblastoma cell lines tested, Daoy and D283 (Figure 3c). Among glioblastoma cell lines, hUlip expression was readily detected in the A172, T98G, and U87MG cell lines, but not in the SF539 cells. In these brain tumor cell lines, the antibodies recognized proteins of 58, 60, 65, and 70 kD, similar to those detected in RA-treated neuroblastoma cells.

HUlip protein expression in neuroblastoma and brain tumor tissues

We analyzed hUlip expression in neuroblastic tumor tissues. Poorly differentiated neuroblastic cells were devoid of hUlip expression (Figure 4A-a, b). However, cells undergoing neuronal differentiation with abundant neuropils in ganglioneuroblastomas (Figure 4A-c, d), or the fully differentiated ganglionic cells in ganglioneuromas (Figure 4A-e, f), were hUlip positive. HUlip

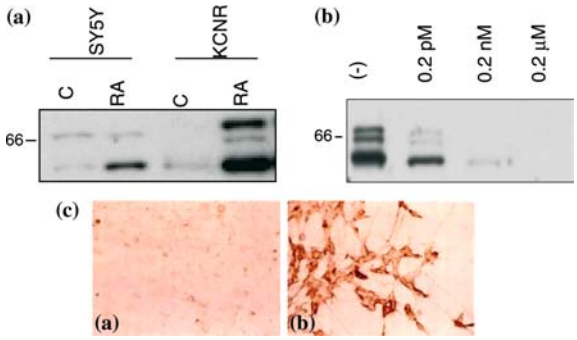

Figure 1. Up-regulation of hUlip by RA treatment in neuroblastoma cells and the specificity of antibodies used. (a) Immunoblot analysis of hUlip expression in SH-SY5Y and SMS-KCNR neuroblastoma cells after treatment with 5 μM RA for 5 days. Twenty micrograms of proteins were loaded in each lane and electrophoresed in 8% SDS-polyacrylamide gel. The antibody recognized polypeptides at 58, 60, 65, and 70 kD, with 58 and 65 kD species being dephosphorylated forms of 60 and 70 kD species, respectively. (b) Specificity of the anti-peptide A antibody as determined by peptide competition of anti-peptide A reactivity on immunoblot (similar results using peptide B were obtained for anti-peptide B antibody; data not shown). Proteins extracted from SMS-KCNR treated with RA for 5 days were transferred to nitrocellulose membrane, and probed with anti-peptide A in the presence of the indicated amounts of immunogenic peptide. (c) Induction of hUlip expression by RA of SH-SY5Y cells. Control (a) and RA-treated (b). Strong hUlip immunoreactivity is present in the cytoplasm and also along neurites (×400).

expression was found to be cytoplasmic and membranous staining. In ganglioneuroblastomas and ganglioneuromas, the immunoreactivity was stronger in cells undergoing neuronal differentiation than in the cells with more fully differentiated features. HUlip expression was not found in normal ganglion cells of the surrounding ganglia in contrast to neoplastic neuronal cells (data not shown). This suggests that either hUlip is not expressed in normal ganglion cells or the level of expression is much lower than that of neoplastic ganglionic cells. Neuropils in ganglioneuroblastomas and ganglioneuromas were hUlip positive, but the schwannian/fibroblastic components completely lacked hUlip immunoreactivity.

Following the detection of hUlip expression in brain tumor cell lines, we further screened brain tumors. The expression patterns of hUlip in nervous system tumors are summarized in Table 4 and selected examples of hUlip immunoreactivity are shown in Figure 4B. Some of the astrocytic tumors were weakly immunoreactive. Three out of eleven glioblastoma cases were immunoreactive for hUlip. The tumors lacking neuronal differentiation (oligodendroglioma, ependymoma, choroid plexus papilloma, and meningioma) completely lacked hUlip expression. Primitive neuroectodermal tumor (PNET) and dysembryoplastic neuroepithelial tumor (DNET) were also non-reactive. Five out of eleven medulloblastoma cases were positive (Figure 4B-a, b). In one case of atypical teratoid rhabdoid tumor (ATRT), the cells with large and vesicular nuclei were negative, while the cells with small and homogenous nuclei showed strong positivity for hUlip (Figure 4B-c).

Table 3. Developmental change of hUlip protein expression in the human brain

Region	Fetal brain tissue				Post-natal brain tissue
	I	II	III	IV	V
Brain stem					
Tegmental neuron	±	+	+ +	+ +	+
Basis pontis neuron		−	+	+ +	+
Inferior olivary nucleus	−	−	−	+	+ +
Cerebellum					
External granule cells	−	−	−	−	−
Purkinje cells	−	−	−	+ +	+
Internal granule cells	±	±	±	±	−
Dentate nucleus	−	−	−	−	−
Cerebral cortex					
Layer 1	−	−	−	−	−
Layers 2–3	−	−	−	+	±
Layers 4–6	−	−	−	+	±
Basal ganglia/thalamus	−	−	+ +	+ +	+ +
Periventricular germinal matrix	−	−	−	−	−
Hippocampus					
Ammon's horn	NA	NA	NA	−	−
Dentate gyrus	NA	NA	NA	+	+ +

−: negative, ±: trace, +: weak positive, + +: strong positive, NA: not available.

In gangliogliomas, only the ganglionic components were positive while both the fibrillary and pilocytic astrocytomas components were negative. The majority of subependymal giant cell astrocytomas (SEGA) (11/12) and subependymomas (2/2) were positive (Figure 4B-d, e). SEGA is usually composed of large cells, which have a plump eosinophilic cytoplasm, and the cells with cytoplasmic process. HUlip was expressed in both types of cells, but the cytoplasm of large cells was especially strongly positive. All of the cases (6/6) of central neurocytoma were diffusely strongly positive (Figure 4B-f). Non-neoplastic cortical neurons and glial cells in the white matter of the specimens analyzed were hUlip negative (data not shown).

Discussion

A key component in the development of the central nervous system is the process of making synapses between neurons, thereby locating specific neurons into specific points and so 'hardwiring the brain'. The process begins in the fetal developing stage [16]. Our major interest was to document the temporal and spatial changes in hUlip expression during the development of

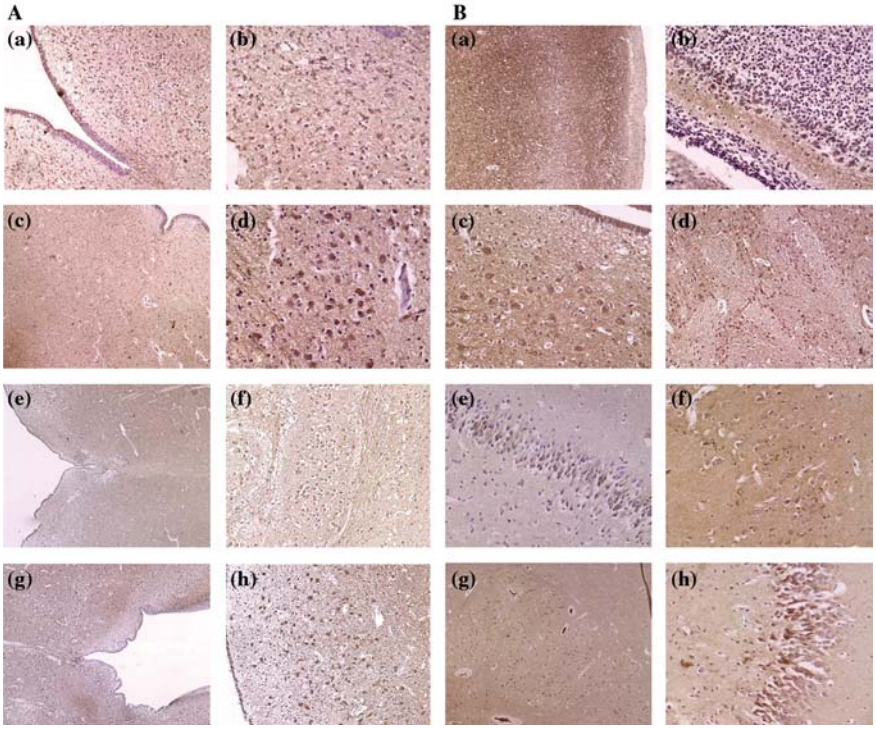

Figure 2. Expression of hUlip protein in developing brain tissue. (A) Groups I–III. (a,b): Transverse section of the floor of the fourth ventricle in the lower medulla oblongata of a 19-week old fetus. The tegmentum of the medulla exhibits scattered hUlip positive neurons (a: ×40, b: ×200). (c,d) Transverse section of the isthmus region of the brain stem of a 19-week old fetus. Scattered hUlip positive neurons are shown (c: ×40, d: ×400). (e,f) Transverse section of the floor of the fourth ventricle in the medulla oblongata, showing hUlip reactivity in the tegmentum of the medulla of a 24-week old fetus (e: ×40). However, inferior olivary nuclei show no immunoreactivity (f: ×100). (g,h) Transverse section of the upper pons. The nuclei in the tegmentum are positive for hUlip in a 24-week old fetus (g: ×40, h: ×400). (B) Group IV–V. (a) Cerebral cortex of a 37-week old fetus. HUlip reactivity is found in the layers 2 and 4 of the cortex (×40). (b) Cerebellar cortex of a 38-week old fetus showing only weak reactivity for hUlip Purkinje cells (×100). (c) Transverse section of the upper medulla oblongata of a 37-week old fetus. The tegmentum of the medulla exhibits strong hUlip reactivity in the neurons (×200). (d) Transverse section of the basis pontis of a 38-week old fetus, showing strong hUlip reactivity in the cytoplasm of the pontine nuclei, but not in the white matter of the corticospinal or corticopontocerebellar tracts (×100). (e) Dentate gyrus of the hippocampus from a 38-week old fetus showing weak positivity for hUlip (×100). (f) Cerebral cortex of a 4-month old neonate. HUlip reactivity is present throughout the layers 2 and 4 of the cortex (×200). (g) Inferior olivary nuclei show strong positivity for hUlip (×40). (h) Dentate gyrus of the hippocampus shows weak positivity for hUlip (×200).

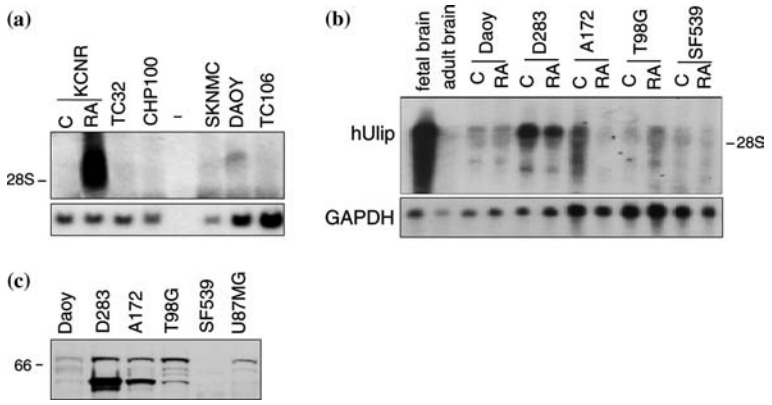

Figure 3. Expression patterns of hUlip in various nervous tumor system cell lines. (a) Northern analysis of hUlip expression in 25 μg of total RNA isolated from selected pediatric tumor cell lines. (b) Northern analysis of hUlip expression in 25 μg of total RNA from selected brain tumor cell lines cultured for 5 days in control solvent or 5 μM RA and in human fetal and adult brain RNA. (c) Immunoblot analysis of hUlip expression in selected brain tumor cell lines. Two of the medulloblastoma cell lines (Daoy and D283) and three out of four glioblastoma cell lines (A172, T98G, SF539, and U87MG) expressed detectable levels of hUlip.

the human brain. HUlip immunoreactivity was prominent in the late fetal and early postnatal period, especially in the brain stem, cerebral cortex, basal ganglia/thalamus neurons, hippocampal dentate gyrus neurons, and cerebellar Purkinje cells. This finding is consistent with our assumption that hUlip is expressed at a particular time during development [1]. Animal studies on nervous system development have shown that Ulip expression is greatest during the late embryonic period and then rapidly decreases in the postnatal period with its expression being restricted to the period of initial neuronal differentiation [4,5,8]. Along with lack of immunoreactivity in normal mature neurons, these findings suggest that hUlip expression, like its rodent homologues, is transiently up-regulated during ongoing neuronal differentiation. The cortical neurons start to differentiate after migration at 15–16 weeks of gestation. HUlip protein expression peaks at around 38 weeks of gestation and is maintained until 4 months after birth, suggesting a role of hUlip in the terminal maturation of developing neurons. These findings are very similar to the expression pattern of hUlip in neuroblastic tumors.

Several molecules are differentially regulated and belong to the surrogate markers of neuronal differentiation. These include NeuN, MAP2 (microtubule-associated protein), NSE (neuron specific enolase), NFP (neurofilament protein), synaptophysin, chromogranins, neurite growth-associated proteins (for example, GAP43, class 3 beta-tubulin, and Tau), calbindins, and various neurotransmitters [17–19]. In comparison with other markers, the expression of hUlip is relatively strictly regulated within a narrow period. Identification of maturing neurons allows more objective documentation of cerebral maturation in fetuses and preterm infants, and more precise definition of neuronal maturation. Based on these results, hUlip appears to be a good marker of the late stages of ongoing neuronal maturation.

Most regions of the embryo brain express ULIP4/CRMP3 during development, whereas its expression in adulthood remains restricted to the dentate gyrus, cerebellar granular layer and inferior olive. The persistent expression of the ULIP4/CRMP3 gene in these selected areas of the adult nervous system suggests that the ULIP signaling pathway is implicated in some specific aspects of neuronal plasticity and disorders. An in situ hybridization study in mice showed that ULIP mRNA is expressed mainly in the dentate gyrus of the hippocampus, in the granular layers of the cerebellum and in the inferior olive of the pons. These mice results are in agreement with the results of this study [7]. Considering that these nuclei control movement and posture, and adjust the major output of the descending motor system, the function of hUlip may be related with the fine regulation of neurons.

Some variables may have interfered with the interpretation of our results. The fetal brain tissues used in this study were relatively well preserved and had no specific histologic abnormalities. However, among the 10 selected autopsy cases, the cases with chorioamnionitis and heart problem may have been influenced by secondary hypoxic/ischemic effect. Hypoxia/ischemia is known to suppress expression of NeuN antigen [20], and the expression of MAP2 is also diminished in neonatal rat brains with hypoxic/ischemic encephalopathy [21]. Infants who have suffered fetal distress or perinatal asphyxia, therefore, may have neuronal hUlip expression lower than that of infants. Another variable is the presence of associated lesions such as hydrocephalus (case 7) and asplenia (case 4). The changes associated with hydrocephalus in case 7 were minimal and there was no histologic abnormality. The case with asplenia had no associated brain lesion.

Neuroblastic tumors exhibit variable degrees of differentiation, across the histologic spectrum of neuroblastoma, ganglioneuroblastoma and ganglioneuroma. HUlip immunoreactivity was stronger in the differentiating neuronal cells of ganglioneuroblastoma than in the more mature ganglionic cells of ganglioneuroma. This finding also supports our view that hUlip is expressed at a specific stage during neuronal differentiation. Among the central nervous system tumors, hUlip expression was detected in most tumors with neuronal differentiation. Interestingly, some astrocytic tumors also showed hUlip

immunoreactivity. Two astrocytic cell lines expressed hUlip. Ulip in neuronal cells is believed to mediate inhibition of the extension of cytoplasmic processes by the activation of certain signaling pathways such as collapsin. As neurons and astrocytes are closely related developmentally, it is possible that hUlip and other unc-33 related proteins play a similar role in astrocytes. HUlip and related proteins may act as signaling intermediaries that contribute to the particular changes in morphological phenotype of these cells with effector molecules such as collapsin or other myelin-associated glycoproteins [9, 22]. Recently, bipotent progenitor cell lines that can differentiate into both neurons and astrocytes have been reported [23]. The finding of hUlip expression in brain tumors is not as surprising as the finding that astrocytic tumors [24,25], and embryonal tumors of childhood may coexpress neuronal as well as glial markers [26,27]. Therefore, hUlip expression may be evidence of biphenotypic or neuronal differentiation in these tumors, particularly because hUlip and its related proteins are overexpressed in neuronally differentiating cells [1,4,8,9]. MAP2, a specific neuron marker, immunoreactivity was detected in oligodendrogliomas and glial precursor cells [28]. Ectopic expression of various proteins is frequently observed in tumor cells, and hUlip expression may be ectopic.

Another interesting finding is that SEGA and subependymoma are strongly positive for hUlip. SEGA is a distinct entity occurring in about 7% of tuberous sclerosis patients, and subependymoma has a similar histology with ependymoma. The histogenetic origin of these tumors remains controversial despite intensive investigations. The presence of both ultrastructural and immunophenotypic evidence of concomitant neuronal differentiation was found in SEGA [29]. Ultrastructural investigation of subependymoma demonstrated that it is a tumor of ependymal or neuroglial cell origin [30]. The findings of this study seemingly support a role for hUlip in neuronal differentiation of both tumors. However, the diffuse, strong and specific immunoreactivity in SEGA cells, when compared with neuronally differentiating

Table 4. Profile of hUlip protein expression in nervous system tumors

Diagnosis	hUlip expression			No. of hUlip positive cases/ no. of cases examined
	±	+	++	
Neuroblastoma	–	–	–	0/10
Ganglioneuroblastoma	1	3	1	5/7
Ganglioneuroma	3	2	–	5/14
Astrocytoma	1	–	–	1/5
Anaplastic astrocytoma	1	1	–	2/5
Glioblastoma	–	3	–	3/11
Subependymal giant cell astrocytoma	–	3	8	11/12
Oligodendroglioma	–	–	–	0/8
Anaplastic oligodendroglioma	–	–	–	0/2
Choroid plexus papilloma	–	–	–	0/3
Ependymoma	–	–	–	0/4
Subependymoma	1	–	1	2/2
Ganglioglioma	2	2	–	4/7
ATRT	–	1	–	1/1
Medulloblastoma	2	3	–	5/11
Central neurocytoma	–	–	6	6/6
PNET	–	–	–	0/3
DNET	–	–	–	0/4
Meningioma	–	–	–	0/3

hUlip positivity: –: negative, ±: trace, +: positive, ++: strong positive, PNET: Primitive neuroectodermal tumor, DNET: Dysembryonic neuroectodermal tumor, ATRT: A typical teratoid rhabdoid tumor.

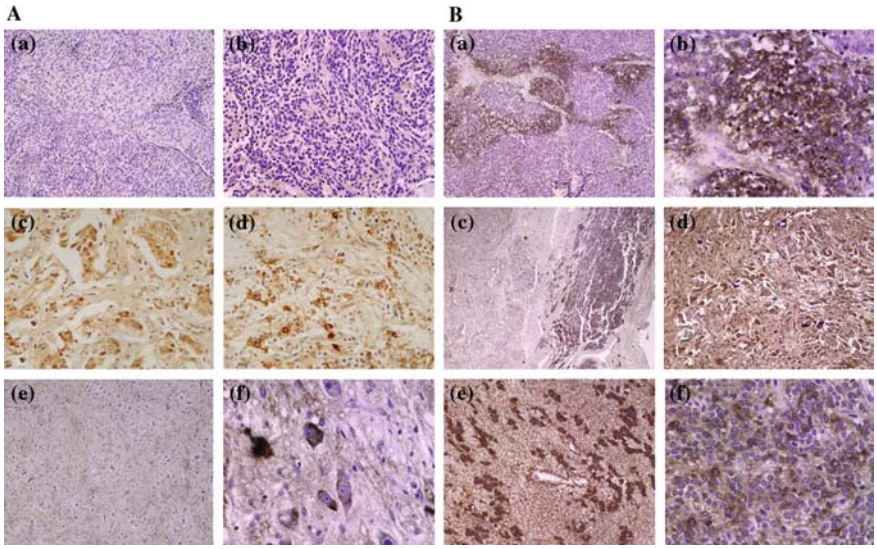

Figure 4. hUlip expression profiles in nervous system tumors. (A) Representative examples of hUlip expression in neuroblastic tumors. (a,b): HUlip expression is not found in poorly differentiated neuroblastoma cells (a: ×100, b: ×200). (c,d) The cells undergoing neuronal differentiation with increased neuropils in ganglioneuroblastomas are positive for hUlip (c: ×200, d: ×200). (e,f) Fully differentiated ganglionic cells in ganglioneuroma show positive immunoreaction to hUlip while schwannian/fibroblastic stroma is negative (e: ×200, f: ×400). (B) Positive hUlip expression in various brain tumors. (a,b) Medulloblastoma shows focal hUlip positive area (a: ×40, b: ×200). (c) A case of ATRT showing hUlip expression in some proportion of the tumor (×40). (d) SEGA shows strong and diffuse immunoreactivity for hUlip (×200). (e) Strong hUlip expression is found in a case of subependymoma (×200). (f) All cases of central neurocytoma show immunoreactivity for hUlip (×200).

cells in other tumors, makes it difficult to give a conclusive explanation for hUlip expression in these cells. The reason why these peculiar tumors strongly express hUlip needs to be further elucidated.

In summary, the present study investigated the detailed aspects of hUlip expression in the human nervous system and tumors. HUlip expression was up-regulated in the late fetal and early postnatal period and in various tumors. Our findings are generally consistent with those of previous rat and mouse studies. HUlip immunoreactive cells are seen after migration and hUlip appears to be a relevant marker for the late stages of neuronal maturation. As differentiation in neuroblastoma is one of the major prognostic parameters in neuroblastic tumors [31], further investigation is necessary to assess the prognostic significance of hUlip in these tumors. Although the exact function of hUlip has not yet been elucidated, the results of our study indicate that hUlip function is important in human nervous system development and its aberrant expression in various types of nervous system tumors suggests a role of hUlip as an oncofetal neural antigen.

Acknowledgements

This work was supported in part by a grant of the Korean National Cancer Control Program, 1999, Ministry of Health & Welfare, Republic of Korea, and in part by the 2003 BK21 Project for Medicine, Dentistry and Pharmacy.

References

1. Gaetano C, Matsuo T, Thiele CJ: Identification and characterization of a retinoic acid-regulated human homologue of the unc-33-like phosphoprotein gene (hUlip) from neuroblastoma cells. J Biol Chem 272: 12195–12201, 1997
2. Hedgecock EM, Culotti JG, Thomson JN, Perkins LA: Axonal guidance mutants of Caenorhabditis elegans identified by filling sensory neurons with fluorescein dyes. Dev Biol 111: 158–170, 1985
3. Li W, Herman RK, Shaw JE: Analysis of the Caenorhabditis elegans axonal guidance and outgrowth gene unc-33. Genetics 132: 675–689, 1992
4. Minturn JE, Fryer HJ, Geschwind DH, Hockfield S: TOAD-64, a gene expressed early in neuronal differentiation in the rat, is related to unc-33, a C. elegans gene involved in axon outgrowth. J Neurosci 15: 6757–6766, 1995
5. Wang LH, Strittmatter SM: A family of rat CRMP genes is differentially expressed in the nervous system. J Neurosci 16: 6197–6207, 1996
6. Hamajima N, Matsuda K, Sakata S, Tamaki N, Sasaki M, Nonaka M: A novel gene family defined by human dihydropyrimidinase and three related proteins with differential tissue distribution. Gene 180: 157–163, 1996
7. Quach TT, Mosinger B Jr, Ricard D, Copeland NG, Gilbert DJ, Jenkins NA, Stankoff B, Honnorat J, Belin MF, Kolattukudy P: Collapsin response mediator protein-3/unc-33-like protein-4 gene: organization, chromosomal mapping and expression in the developing mouse brain. Gene 242: 175–182, 2000
8. Minturn JE, Geschwind DH, Fryer HJ, Hockfield S: Early postmitotic neurons transiently express TOAD-64, a neural specific protein. J Comp Neurol 355: 369–379, 1995
9. Goshima Y, Nakamura F, Strittmatter P, Strittmatter SM: Collapsin-induced growth cone collapse mediated by an intracellular protein related to UNC-33. Nature 376: 509–514, 1995
10. Honnorat J, Byk T, Kusters I, Aguera M, Ricard D, Rogemond V, Quach T, Aunis D, Sobel A, Mattei MG, Kolattukudy P, Belin MF, Antoine JC: Ulip/CRMP proteins are recognized by autoantibodies in paraneoplastic neurological syndromes. Eur J Neurosci 11: 4226–4232, 1999
11. Thambisetty MR, Scherzer CR, Yu Z, Lennon VA, Newman NJ: Paraneoplastic optic neuropathy and cerebellar ataxia with small cell carcinoma of the lung. J Neuroophthalmol 21: 164–167, 2001
12. Kaplan DR, Matsumoto K, Lucarelli E, Thiele CJ: Induction of TrkB by retinoic acid mediates biologic responsiveness to BDNF and differentiation of human neuroblastoma cells. Eukaryotic Signal Transduction Group. Neuron 11: 321–331, 1993
13. Lucarelli E, Kaplan DR, Thiele CJ: Selective regulation of TrkA and TrkB receptors by retinoic acid and interferon-gamma in human neuroblastoma cell lines. J Bio Chem 270: 24725–24731, 1995
14. Joshi VV, Cantor AB, Altshuler G et al: Age-linked prognostic categorization based on a new histologic grading system of neuroblastomas. A clinicopathologic study of 211 cases from the Pediatric Oncology Group. Cancer 69: 2197–2211, 1992
15. Quinn CC, Chen E, Kinjo TG, Kelly G, Bell AW, Elliott RC, McPherson PS, Hockfield S: TUC-4b, a novel TUC family variant, regulates neurite outgrowth and associates with vesicles in the growth cone. J Neurosci 23: 2815–2823, 2003
16. Hatten ME. Heintz N: Mechanisms of neural patterning and specification in the developing cerebellum. Annu Rev Neurosci 18: 385–408, 1995
17. Sarnat HB, Nochlin D, Born DE: Neuronal nuclear antigen (NeuN): a marker of neuronal maturation in the early human fetal nervous system. Brain Dev 20: 88–94, 1998
18. Sarnat HB, Born DE: Synaptophysin immunocytochemistry with thermal intensification: a marker of terminal axonal maturation in the human fetal nervous system. Brain Dev 21: 41–50, 1999
19. Honig LS, Herrmann K, Shatz CJ: Developmental changes revealed by immunohistochemical markers in human cerebral cortex. Cereb Cortex 6: 794–806, 1996
20. Xu GPP, Dave KR, Vivero R, Schmidt-Kastner R, Sick TJ, Perez-Pinzon MA: Improvement in neuronal survival after ischemic preconditioning in hippocampal slice cultures. Brain Res 952: 153–158, 2002
21. Silverstein FS, Malinak C: Hypoxic-ischemic injury acutely disrupts microtubule-associated protein 2 immunostaining in neonatal rat brain. Biol Neonate 69: 257–267, 1996
22. McKerracher L, David S, Jackson DL, Kottis V, Dunn RJ, Braun PE: Identification of myelin-associated glycoprotein as a major myelin-derived inhibitor of neurite growth. Neuron 13: 805–811, 1994
23. Sah DW, Ray J, Gage FH: Bipotent progenitor cell lines from the human CNS. Nat Biotechnol 15: 574–580, 1997
24. Royds JA, Ironside JW, Taylor CB, Graham DI, Timperley WR: An immunohistochemical study of glial and neuronal markers in primary neoplasms of the central nervous system. Acta Neuropathol 70: 320–326, 1986
25. Bodey B, Zeltzer PM, Saldivar V, Kemshead J: Immunophenotyping of childhood astrocytomas with a library of monoclonal antibodies. Int J Cancer 45: 1079–1087, 1990
26. Molenaar WM, Jansson DS, Gould VE, Rorke LB, Franke WW, Lee VM, Packer RJ, Trojanowski JQ: Molecular markers of primitive neuroectodermal tumors and other pediatric central nervous system tumors. Monoclonal antibodies to neuronal and glial antigens distinguish subsets of primitive neuroectodermal tumors. Lab Invest 61: 635–643, 1989
27. Gould VE, Jansson DS, Molenaar WM, Rorke LB, Trojanowski JQ, Lee VM, Packer RJ, Franke WW: Primitive neuroectodermal tumors of the central nervous system. Patterns of expression of neuroendocrine markers, and all classes of intermediate filament proteins. Lab Invest 62: 498–509, 1990

28. Blumcke I, Becker AJ, Normann S, Hans V, Riederer BM, Krajewski S, Wiestler OD, Reifenberger G: Distinct expression pattern of microtubule-associated protein-2 in human oligodendrogliomas and glial precursor cells. J Neuropathol Exp Neurol 60: 984–993, 2001
29. Green AJ, Sepp T, Yates JR: Clonality of tuberous sclerosis harmatomas shown by non-random X-chromosome inactivation. Hum Genet 97: 240–243, 1996
30. Moss TH: Observations on the nature of subependymoma: an electron microscopic study. Neuropathol Appl Neurobiol 10: 63–75, 1984
31. Shimada H, Chatten J, Newton WA Jr, Sachs N, Hamoudi AB, Chiba T, Marsden HB, Misugi K: Histopathologic prognostic factors in neuroblastic tumors: definition of subtypes of ganglioneuroblastoma and an age-linked classification of neuroblastomas. J Natl Cancer Inst 73: 405–416, 1984
32. Wolf E, Wagner JP, Black IB, DiCicco-Bloom E: Cerebellar granule cells elaborate neurites before mitosis. Brain Res Dev Brain Res 102: 305–308, 1997

Address for offprints: Chong Jai Kim, Department of Pathology, Seoul National University College of Medicine, 28 Yongon-dong, Chongno-gu, Seoul 110-799, Korea; Tel.: +82-2-745-7966; Fax: +82-2-745-7966; E-mail: cjkim@snu.ac.kr