Check for updates

Received: 11 July 2024 | Accepted: 30 January 2025

DOI: 10.1002/hem3.70128

GUIDELINES - CONSENSUS-BASED

HemaSphere eha

Peripheral T- and natural killer-cell lymphomas: ESMO-EHA Clinical Practice Guideline for diagnosis, treatment, and follow-up

Francesco d'Amore[1,2,^] | Massimo Federico[3,^] | Laurence de Leval[4] | Fredrik Ellin[5,6] | Olivier Hermine[7,8] | Won Seog Kim[9] | François Lemonnier[10,11] | Joost S. P. Vermaat[12] | Gerald Wulf[13] | Christian Buske[14] | Martin Dreyling[15] | Mats Jerkeman[16] | on behalf of the ESMO and EHA Guidelines Committees

Correspondence: EHA Executive Office/EHA Guidelines Committee (guidelines@ehaweb.org); ESMO Guidelines Committee/ESMO Head Office (clinicalguidelines@esmo.org)

INCIDENCE AND EPIDEMIOLOGY

Peripheral T-cell and natural killer (NK)-cell lymphomas (PTCLs) represent a heterogeneous group of neoplasms derived from post-thymic T- or NK cells, with diverse morphological patterns, phenotypes, and clinical presentations. The International Consensus Classification and World Health Organization (WHO) classification of lymphoid and hematopoietic neoplasms recognize >30 PTCL entities[1,2] (Supporting Information: Table S1 and Supporting Information Section 1). The incidence and epidemiology of PTCL are described in Supporting Information Section 2. This clinical practice guideline (CPG) covers PTCLs with primary nodal, extranodal, and leukemic presentation. Guidelines for primary cutaneous T-cell lymphomas are reported elsewhere.[3]

DIAGNOSIS, PATHOLOGY, AND MOLECULAR BIOLOGY

Accurate identification and diagnosis of PTCL is mandatory for adequate clinical management, as treatment should be adapted for each entity. Several entities present with a wide pathological spectrum and there is substantial overlap in morphology, immunophenotype, and mutational landscape between diseases. The differential diagnosis of PTCL is broad and includes various reactive conditions, particularly primary immune deficiencies, inflammation, autoimmune diseases, infections, Hodgkin lymphoma, and, in some instances, B-cell lymphomas.[4] Overtly malignant PTCLs must be distinguished from the recently recognized indolent clonal T- or NK-cell lymphoproliferative disorders.[1,2] Given the low prevalence of PTCLs, most pathologists

[1]Department of Haematology, Aarhus University Hospital, Aarhus, Denmark
[2]Department of Clinical Medicine, Aarhus University Hospital, Aarhus, Denmark
[3]CHIMOMO Department, University of Modena and Reggio Emilia, Emilia-Romagna, Italy
[4]Department of Laboratory Medicine and Pathology, Institute of Pathology, Lausanne University Hospital, Lausanne University, Lausanne, Switzerland
[5]Department of Clinical Sciences, Lund University, Lund, Sweden
[6]Department of Internal Medicine, Kalmar County Hospital, Kalmar, Sweden
[7]Department of Hematology, Université de Paris, Assistance Publique-Hôpitaux de Paris (AP-HP), Paris, France
[8]Imagine Institute, Hôpital Necker, INSERM U1163, Paris, France
[9]School of Medicine, Samsung Medical Center, Sungkyunkwan University, Seoul, Korea
[10]Lymphoid Malignancies Unit, Hôpital Henri Mondor, Assistance Publique-Hôpitaux de Paris (AP-HP), Créteil, France
[11]Institut Mondor de Recherche Biomédicale, Université Paris Est Créteil, INSERM, Créteil, France
[12]Department of Hematology, Leiden University Medical Centre, Leiden, The Netherlands
[13]Department of Hematology and Medical Oncology, University Medical Center Göttingen, Göttingen, Germany
[14]Institute of Experimental Cancer Research, Ulm Medical University, Ulm, Sweden
[15]Department of Medicine III, Ludwig Maximilian University, Munich, Germany
[16]Department of Oncology, Skåne University Hospital, Lund, Sweden
^Francesco d'Amore is the primary author for ESMO, and Massimo Federico is the primary author for EHA.

This guideline was developed by the EHA and ESMO. The two societies nominated authors to write the guideline as well as reviewers to comment on it. This guideline was approved by the EHA Board and the ESMO Guidelines Committee in July 2024.

This is an open access article under the terms of the Creative Commons Attribution-NonCommercial-NoDerivs License, which permits use and distribution in any medium, provided the original work is properly cited, the use is non-commercial and no modifications or adaptations are made.
© 2025 The Authors. *HemaSphere* Published by John Wiley & Sons Ltd on behalf of European Hematology Association and by Elsevier Ltd on behalf of European Society for Medical Oncology.

have insufficient experience to confidently diagnose them; therefore, diagnosis should be established or confirmed by a hematopathologist with expertise in PTCL who has access to all slides and ≥1 representative paraffin block of the biopsy.[5,6]

Clinicopathological correlation is critical for diagnosis, incorporating imaging findings, symptoms, and laboratory information. Anatomical localization can pre-sort for specific entities (e.g., hepatosplenic T-cell lymphoma [HSTCL], Epstein–Barr virus [EBV]-associated extranodal NK- or T-cell lymphoma [ENKTCL] nasal type, enteropathy-associated T-cell lymphoma [EATL], and breast implant-associated anaplastic large-cell lymphoma [BIA-ALCL]). Autoimmune and inflammatory diseases (e.g., celiac disease and inflammatory bowel disease), immunocompromised status, ethnicity, origin from endemic regions (e.g., within Asia, Africa, or South America for adult T-cell leukemia or lymphoma [ATLL]) or infection (e.g., EBV in tumor cells, human T-cell lymphotropic virus type 1 [HTLV-1]) may further support identification of entities.

Diagnosis should rely on surgical excisional or incisional biopsy whenever possible[5] to allow adequate histopathological assessment and provide sufficient tissue for immunohistochemistry (IHC) and molecular studies. When surgery is not possible, core needle biopsy or biopsies may be adequate for initial management[5]; however, their accuracy is substantially lower than surgical biopsies for diagnosis and subclassification.[7,8] Several cores are warranted to anticipate future needs for archived biopsy material. In addition to IHC, flow cytometry has a role in diagnosing and staging PTCL in fluids (blood, ascites, pleural effusion, and cerebrospinal fluid).

The indication of the neoplastic nature of a T-cell population is based on (i) morphology (including overall tissue architecture), atypical cytology and microenvironment features; (ii) aberrant T-cell phenotype; and (iii) presence of a disease-associated genetic alteration, pathogenic mutation(s) or clonally rearranged T-cell receptor (TCR) genes.[9] Morphological clues, immunophenotypical markers, and genetic molecular studies are summarized in Supporting Information: Tables S2 and S3. Various phenotypic aberrancies occur in PTCLs. Loss or reduced expression of one or more pan-T-cell antigens (cluster of differentiation [CD]2, surface CD3, CD4, CD5, CD7, CD8, and TCR) is common across various entities. Coexpression of CD30 is a defining feature of anaplastic large-cell lymphoma (ALCL), but is also observed in many other entities. Demonstration of differentiation markers related to follicular helper T cells (CD10, B-cell lymphoma 6, programmed cell death protein 1 [PD-1], CXC chemokine ligand 13, inducible T-cell costimulatory) is key for diagnosing follicular helper T-cell-derived lymphoma (TFHL). Cytotoxic markers (cytotoxic granule-associated RNA binding protein, granzyme B, and perforin) are useful for the characterization of extranodal T-cell neoplasms and PTCL not otherwise specified (PTCL-NOS). The latter may be further defined according to the expression of markers of type 1 T helper cells (CXC chemokine receptor 3 and T-box transcription factor 21) and type 2 T helper cells (C–C chemokine receptor type 4 [CCR4] and GATA binding protein 3). FISH is commonly used to assess frequent gene rearrangements or fusions, notably for genetic subtyping of anaplastic lymphoma kinase (ALK)-negative ALCL based on *DUSP22* with or without *TP63* rearrangement. The detection of gene variants may rely on targeted assays for certain hotspots (e.g., *RHOA* p.G17V or *IDH2* p.R172 mutations, which both support a diagnosis of TFHL) but is more commonly achieved by high-throughput sequencing (HTS) of panels of genes. Many of the recurrent aberrations found in PTCLs involve genes related to epigenetic regulation (*TET2*, *DNMT3A*, *IDH2*, *ARID1A*, *SETD2*, and *INO80*), components of the TCR, nuclear factor kappa B and Janus kinase (JAK)–signal transducer, and activator of transcription signaling pathways (*CD28*, *CARD11*, *RHOA*, *PIK3CD*, *PLCG1*, *JAK1*, *JAK3*, *STAT3*, and *STAT5B*) or genes involved in the regulation of cell cycle and apoptosis (*ATM*, *CDKN2A*, *FAS*, and *TP53*).[9] HTS complements classical TCR gene rearrangement studies to determine clonality, given that TCR gene-based assays may give false-positive results for non-malignant clones or false-negative polyclonal results in T-cell malignancies. HTS may also assist therapeutic decisions, as some PTCL-associated genetic lesions may support a rationale for subtype-specific intervention.[10] An overview of the main defining features of common PTCL entities is presented in Supporting Information: Table S4. The diagnostic approach to nodal PTCLs is summarized in Supporting Information: Figure S1 and Supporting Information Section 3.

Bone marrow (BM) is often the main tissue source providing conclusive diagnostic documentation in leukemic entities such as T-cell prolymphocytic leukemia (T-PLL), T-cell large granular lymphocytic leukemia (T-LGL), NK-cell large granular lymphocytic leukemia (NK-LGL), aggressive NK-cell leukemia (ANKL), and ATLL. HSTCL is the only non-leukemic PTCL with evidence of BM involvement in almost all cases. BM involvement is characterized by a typical intrasinusoidal lymphoid infiltrate, and its diagnosis often relies on BM biopsy.[11] When primary BM diagnosis is required in rare cases of extranodal lymphomas presenting with isolated BM disease, PTCL diagnosis can be particularly challenging.[12]

Recommendations

- Clinicopathological correlation, incorporating imaging findings, symptoms, and laboratory information, should be a mainstay of diagnosis (III, A).
- Diagnosis of PTCL should, whenever possible, rely on a surgical excisional or incisional biopsy (II, A).
- Diagnosis should be based on morphology, aberrant T-cell phenotypes, and the presence of pathogenic mutations, virus infection (EBV or HTLV-1), or TCR clonality (II, A).

STAGING AND RISK ASSESSMENT

Multidisciplinary team (MDT) approach

An MDT approach is preferred, including hematopathologists, diagnostic imaging physicians, hematologist-oncologists, and radiotherapists with expertise in PTCL. MDT evaluation should occur at diagnosis for clinicopathological validation of disease entity, assessment of disease extent, and overall risk profiling and to facilitate a rational, evidence-based treatment strategy, including potential planning of hematopoietic stem-cell transplantation (HSCT). Subsequent MDT evaluations can occur, if needed, at interim and end-of-treatment (EOT) assessments.

Pretreatment laboratory tests

Laboratory tests include complete blood count, flow cytometry of peripheral blood (in primary leukemic entities), blood chemistry (e.g., lactate dehydrogenase [LDH] and uric acid), renal and hepatic function tests, serum immunoglobulins and screening for human immunodeficiency virus, HTLV-1 (in ATLL), hepatitis B, hepatitis C, and EBV.

Diagnostic imaging and BM evaluation

If available, positron emission tomography (PET)–computed tomography (CT) is the preferred imaging modality before treatment, at

25729241, 2025, 5, Downloaded from https://onlinelibrary.wiley.com/doi/10.1002/hem3.70128 by CochraneItalia, Wiley Online Library on [28/03/2026]. See the Terms and Conditions (https://onlinelibrary.wiley.com/terms-and-conditions) on Wiley Online Library for rules of use; OA articles are governed by the applicable Creative Commons License

first restaging (optional) and EOT.[13] If PET–CT is not available, diagnostic CT of the neck, chest, abdomen, and pelvis can be used, acknowledging that PTCL often presents with extranodal disease, which may not be adequately imaged by CT. The role of PET–CT in primary leukemic PTCL requires further elucidation, but it is established in acute and lymphoma-type ATLL. While PET–CT is useful for detecting potential residual lesions at EOT, [^{18}F]2-fluoro-2-deoxy-D-glucose (FDG)-avid lesions are not sufficient for a conclusive diagnosis; therefore, biopsy confirmation is necessary. Nodal PTCLs are virtually all FDG-avid on PET–CT, and additional sites of disease are identified in ≤50% of patients at diagnosis.[13] Magnetic resonance imaging (MRI) is a useful tool in ENKTCL for an accurate evaluation of sites of disease (e.g., facial skeleton, central nervous system [CNS], and upper aerodigestive tract) and, if applicable, for planning radiotherapy (RT) for involved anatomical structures. Some studies have reported lower sensitivity of PET–CT in identifying BM disease in PTCL compared to Hodgkin lymphoma and diffuse large B-cell lymphoma (DLBCL).[14] BM aspiration and biopsy should, therefore, be included in staging. BM involvement has been retrospectively reported in 35.8% of nodal PTCLs.[15] BM might disclose associated myeloid disorders[16] given the frequency of underlying clonal hematopoiesis, especially in TFHL.[17]

Clinical progression or recurrence of systemic PTCL is not typically associated with histological transformation; however, suspected relapses may represent proliferation of a different lineage (B cell or even myeloid), reactive conditions including granulomatosis reactions, or infectious processes, which require different treatments. Rebiopsy, when possible, can guide further therapy. In case of relapse, the most recent biopsy material is preferred for biomarker assessment and identification of potential therapeutic targets.

Prognostic indices

Supporting Information Section 4 provides a summary of prognostic indices in PTCL overall and for specific entities.

Recommendations

- Management of all patients should be discussed by an MDT including hematopathologists (including specialists in pathology, cytology, and molecular biology), diagnostic imaging specialists, hematologist-oncologists, and radiotherapists with specific experience in PTCL (I, A).
- If available, PET–CT at diagnosis, interim (optional) and at EOT can be considered the preferred imaging modality for all nodal and extranodal (non-leukemic) PTCLs (I, B). If PET–CT is not available, diagnostic CT can be used (III, C), although CT detection of extranodal disease may be inadequate in some cases.
- In all cases, a BM biopsy is recommended for accurate staging, including studies of virus expression (I, A).
- Additional tests should be carried out in some entities, such as assessment of peripheral blood cells for immunophenotype (e.g., flow cytometry for primary leukemic entities) and measurement of viral load (e.g., EBV DNA in ENKTCL) (II, A).
- Rebiopsy is recommended at relapse or progression (I, A).

FIRST-LINE TREATMENT

All patients with PTCL should be offered the opportunity to participate in a clinical trial whenever possible. An overview of first-line treatment strategies is shown in Figure 1 (nodal PTCL), Figure 2 (extranodal PTCL), and Figure 3 (leukemic PTCL). Complementary and subtype-specific algorithms can be found in the Supporting Information as outlined below.

PTCL-NOS and TFHL (angioimmunoblastic and follicular types and NOS)

First-line treatment

Although outcomes are poor, cyclophosphamide–doxorubicin–vincristine–prednisolone (CHOP) remains the standard of care for non-ALCL nodal subtypes. Attempts to replace the CHOP or CHOP-like backbone have not yielded superior results. A detailed algorithm for the first-line management of PTCL-NOS and TFHL is shown in Supporting Information: Figure S2.

Addition of etoposide to CHOP

In a retrospective analysis of 289 patients treated within trials of the German High-Grade Non-Hodgkin Lymphoma Study Group, CHOP–etoposide (CHOEP) was associated with a superior 3-year event-free survival (EFS) rate versus CHOP in patients with ALK-positive ALCL aged <60 years with normal serum LDH and in patients with ALK-negative ALCL, PTCL-NOS, or angioimmunoblastic T-cell lymphoma (AITL) with International Prognostic Index (IPI) score of <1.[18] In the Nordic NLG-T-01 study, 160 patients with PTCL (of which 58% had PTCL-NOS or AITL) received six cycles of CHOEP-14 followed, in responding patients, by autologous HSCT (auto-HSCT).[19] The 5-year overall survival (OS) and progression-free survival (PFS) rates were 51% and 44%, respectively. The trial did not include patients with ALK-positive ALCL. In two real-world data reports from the Swedish Lymphoma Registry, the addition of etoposide to CHOP was associated with improved OS (hazard ratio [HR] 0.38) and PFS in ALK-positive ALCL[20] and improved PFS (HR 0.49) in other nodal subtypes and EATL.[21] A recent population-based cohort study from The Netherlands evaluated CHOEP and consolidative auto-HSCT in 1427 patients with PTCL aged 18–64 years.[22] A cohort from the "pre-etoposide and -auto-HSCT era" (1989–2009) was compared to one from the "etoposide and auto-HSCT era" (2009–2018). The risk of lymphoma-related mortality in patients with ALK-positive ALCL was 6.3 times lower for those who received CHOEP than for those who received CHOP. Differences observed in other PTCL subtypes were not significant.

CHOP in combination with novel drugs

In the randomized ECHELON-2 trial, the anti-CD30 antibody–drug conjugate brentuximab vedotin (BV) combined with cyclophosphamide–doxorubicin–prednisolone (CHP) was superior to standard CHOP in ALCL, particularly ALK-positive ALCL.[23] No improvement was observed in PTCL-NOS or TFHL, although the number of patients with these subtypes was limited. BV-CHP is not approved for PTCL-NOS and TFHL in Europe. A small single-arm phase II study of cyclophosphamide–etoposide–vincristine–prednisolone–pralatrexate (CEOP-P) reported modest responses (2-year PFS and OS rates of 39% and 60%, respectively) that were not superior to historical outcomes with CHOP.[24] Recent randomized studies evaluating the addition of the anti-CD52 monoclonal antibody alemtuzumab (DSHNHL2006-1B/ACT-2 trial[25]) or the histone deacetylase inhibitor romidepsin (Ro-CHOP trial[26]) to CHOP did not demonstrate improved survival. A post hoc exploratory subgroup analysis of Ro-CHOP data, however,

25729241, 2025, 5, Downloaded from https://onlinelibrary.wiley.com/doi/10.1002/hem3.70128 by CochraneItalia, Wiley Online Library on [28/03/2026]. See the Terms and Conditions (https://onlinelibrary.wiley.com/terms-and-conditions) on Wiley Online Library for rules of use; OA articles are governed by the applicable Creative Commons License

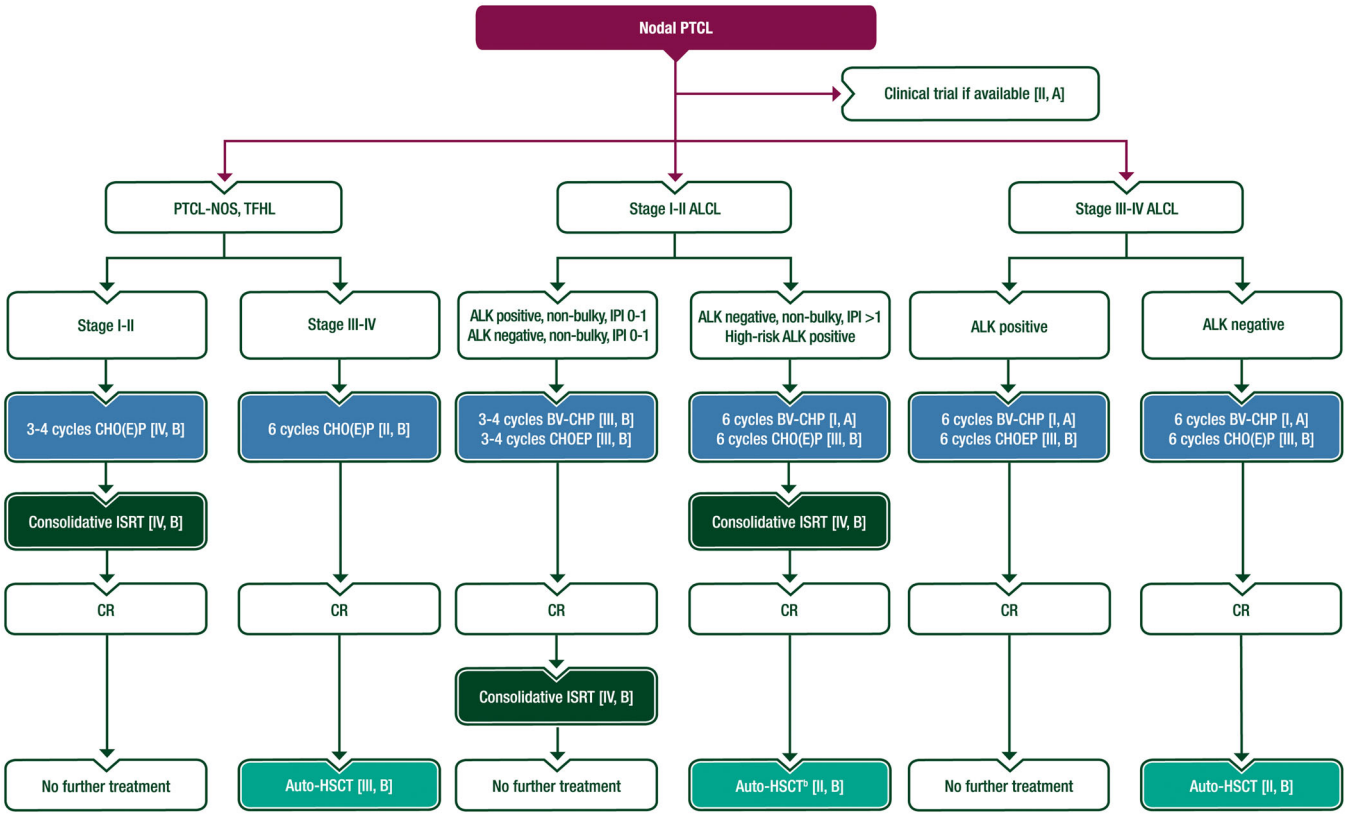

FIGURE 1 **Overview of first-line treatment in nodal PTCL.**[a] Purple: algorithm title; dark green: RT; blue: systemic anticancer therapy or their combination; turquoise: non-systemic anticancer therapies or combination of treatment modalities; white: other aspects of management and non-treatment aspects. ALCL, anaplastic large cell lymphoma; ALK, anaplastic lymphoma kinase; auto-HSCT, autologous hematopoietic stem-cell transplantation; BV-CHP, brentuximab vedotin–cyclophosphamide–doxorubicin–prednisolone; CHOEP, cyclophosphamide–doxorubicin–vincristine–etoposide–prednisolone; CHO(E)P, cyclophosphamide–doxorubicin–vincristine(–etoposide)–prednisolone; ChT, chemotherapy; CR, complete remission; IPI, International Prognostic Index; ISRT, involved-site radiotherapy; NOS, not otherwise specified; PTCL, peripheral T-cell or natural killer-cell lymphoma; RT, radiotherapy; TFHL, follicular helper T-cell-derived lymphoma. [a]For subtype-specific treatment algorithms, see Supporting Information: Figures S2 and S3. [b]Can be considered for patients with high-risk ALK-positive ALCL with no CR after three cycles of ChT (III, B).

reported improved outcomes in romidepsin-treated patients with TFHL.[27] DSHNHL2006-1B/ACT-2 excluded patients with ALCL (due to lack of CD52 expression in ALCL) and Ro-CHOP excluded patients with ALK-positive ALCL. A recent phase II trial testing the addition of 5-azacitidine (5-aza) to CHOP in 17 patients with newly diagnosed TFHL reported a complete remission (CR) rate of 88.2%.[28]

Consolidative auto-HSCT in the first response

Prospective[19,29] and retrospective[22,30,31] studies have reported favorable outcomes in patients with PTCL undergoing consolidative auto-HSCT in the first response; however, other studies did not replicate this.[32] In a randomized phase III study evaluating auto-HSCT versus allogeneic HSCT (allo-HSCT) following anthracycline-based first-line therapy in high-risk nodal PTCL, EFS, and OS outcomes were similar with both treatments.[33] At a median follow-up of 42 months, 3-year EFS rates were 43% for allo-HSCT and 38% for auto-HSCT, and 3-year OS rates were 57% and 70%, respectively. Auto-HSCT was associated with a higher relapse rate (36% vs. 0% with allo-HSCT), while allo-HSCT was associated with higher transplant-related mortality (31% vs. 0% with auto-HSCT). In a Swedish intention-to-treat analysis of real-world data from 252 patients with nodal PTCL (ALK-positive ALCL excluded) or EATL, patients who received consolidative auto-HSCT had improved OS (HR 0.58, $p = 0.004$) and PFS (HR 0.56; $p = 0.002$) compared to patients who were treated without auto-HSCT.[21] In a population-based cohort study in The Netherlands, patients across all subtypes undergoing auto-HSCT consolidation had a higher 5-year OS rate than those who did not (81% vs. 39%, respectively, $p < 0.01$), regardless of CR achievement.[22] Overall, auto-HSCT is an acceptable option in chemosensitive disease responding to first-line therapy. A randomized study comparing auto-HSCT with observation in patients who achieved CR after first-line treatment is ongoing (NCT05444712; TRANSCRIPT).

Management of limited-stage PTCL

Recent reports suggest that patients with low-risk, limited-stage nodal PTCL have similar outcomes regardless of whether they receive abbreviated chemotherapy (ChT) (e.g., three to four cycles) plus involved-site RT (ISRT) or a full ChT course (e.g., six cycles).[34–36]

ALCL, systemic types

Limited stage

Most patients with ALCL present with advanced-stage nodal disease; however, extranodal involvement can occur, often involving bone,

25729241, 2025, 5, Downloaded from https://onlinelibrary.wiley.com/doi/10.1002/hem3.70128 by CochraneItalia, Wiley Online Library on [28/03/2026]. See the Terms and Conditions (https://onlinelibrary.wiley.com/terms-and-conditions) on Wiley Online Library for rules of use; OA articles are governed by the applicable Creative Commons License

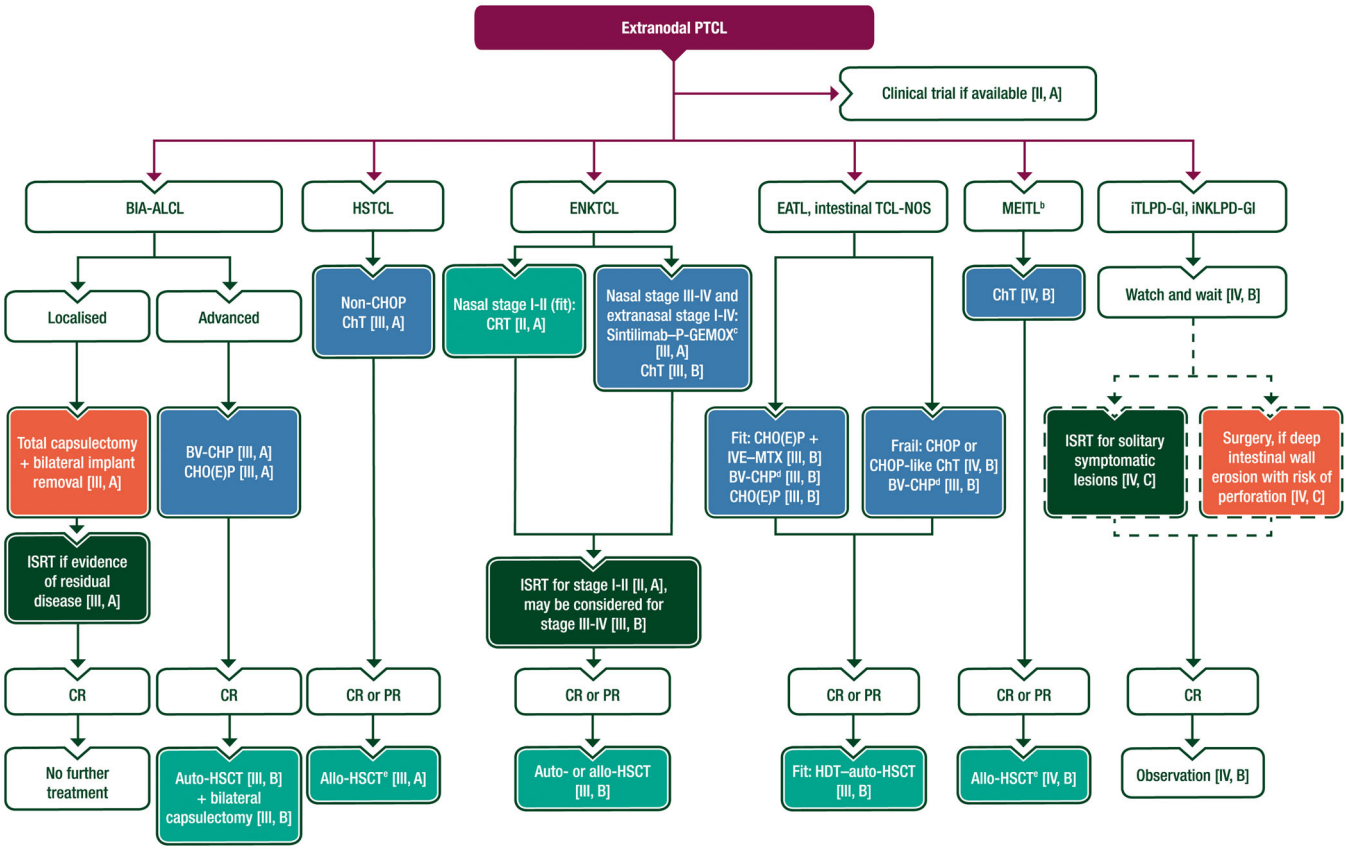

FIGURE 2 **Overview of first-line treatment in extranodal PTCL.**[a] Purple: algorithm title; orange: surgery; dark green: RT; blue: systemic anticancer therapy or their combination; turquoise: non-systemic anticancer therapies or combination of treatment modalities; white: other aspects of management and non-treatment aspects; dashed lines: optional therapy. ALCL, anaplastic large cell lymphoma; allo-HSCT, allogeneic hematopoietic stem-cell transplantation; auto-HSCT, autologous hematopoietic stem-cell transplantation; BIA, breast implant associated; BV-CHP, brentuximab vedotin–cyclophosphamide–doxorubicin–prednisolone; CHO(E)P, cyclophosphamide–doxorubicin–vincristine(–etoposide)–prednisolone; CHOP, cyclophosphamide–doxorubicin–vincristine–prednisolone; ChT, chemotherapy; CR, complete remission; CRT, chemoradiotherapy; EATL, enteropathy-associated T-cell lymphoma; EMA, European Medicines Agency; ENKTCL, extranodal natural killer- or T-cell lymphoma; FDA, Food and Drug Administration; HDT, high-dose chemotherapy; HSTCL, hepatosplenic T-cell lymphoma; iNKLPD-GI, indolent natural killer-cell lymphoproliferative disorders of the gastrointestinal tract; ISRT, involved-site radiotherapy; iTLPD-GI, indolent T-cell lymphoproliferative disorders of the gastrointestinal tract; IVE, ifosfamide–etoposide–epirubicin; MEITL, monomorphic epitheliotropic intestinal T-cell lymphoma; MTX, methotrexate; NOS, not otherwise specified; P-GEMOX, pegylated L-asparaginase–gemicitabine–oxaliplatin; PR, partial remission; PTCL, peripheral T-cell or natural killer-cell lymphoma; RT, radiotherapy; TCL, T-cell lymphoma. [a]For subtype-specific treatment algorithms, see Supporting Information: Figures S4–S10. [b]New entity with insufficient data for clinical recommendation. Small case series suggest poor efficacy of anthracycline-based regimens and biological studies indicate similarities with HSTCL. Consider a strategy similar to HSTCL. [c]Not EMA or FDA approved. [d]FDA approved, not EMA approved. [e]If chemosensitive (CR or PR), consider early allo-HSCT due to the high risk of early progression.

soft tissue, and skin. Limited-stage disease is uncommon and poorly investigated. In recent retrospective studies of nodal PTCL, including limited-stage ALK-positive and ALK-negative ALCL, good outcomes have been observed after combined modality treatment comprising abbreviated ChT (three to four cycles) consolidated with ISRT.[34,36,37] A detailed algorithm for the first-line management of ALCL is shown in Supporting Information: Figure S3.

Advanced stage

ECHELON-2 reported significant improvements in PFS and OS with BV-CHP versus CHOP in patients with ALCL, especially those with ALK-positive disease.[23] This benefit was not observed across other PTCL entities. At a median follow-up of 47.6 months, 5-year PFS rates were 51.4% for BV-CHP versus 43.0% for standard CHOP (HR 0.70, 95% confidence interval [CI] 0.53–0.91) and 5-year OS rates were 70.1% versus 61.0%, respectively (HR 0.72, 95% CI 0.53–0.99).[38] Entity-specific survival analyses from ECHELON-2 have not yet been reported.

Etoposide

Reports from population-based registries[20,22] and a retrospective subset analysis of prospective trials[18] demonstrated a survival benefit with CHOEP versus CHOP, particularly in ALK-positive ALCL. Furthermore, a pooled analysis of individual patient data ($N = 263$) from six clinical studies reported a significant increase in 3-year PFS rate (92% vs. 49%, $p = 0.005$) and OS rate (100% vs. 56%, $p = 0.002$) in patients with ALK-positive ALCL and an IPI ≥ 2 receiving etoposide-containing first-line regimens compared with CHOP.[39] Interestingly, the PFS and OS improvements observed with CHOEP were similar to those seen with BV-CHP versus CHOP in ECHELON-2. A single-arm phase II study evaluated the addition of etoposide to BV-CHP (BV-CHEP) in CD30-positive ALCL.[40] Of 47 patients, 37 achieved a

25729241, 2025, 5, Downloaded from https://onlinelibrary.wiley.com/doi/10.1002/hem3.70128 by CochraneItalia, Wiley Online Library on [28/03/2026]. See the Terms and Conditions (https://onlinelibrary.wiley.com/terms-and-conditions) on Wiley Online Library for rules of use; OA articles are governed by the applicable Creative Commons License

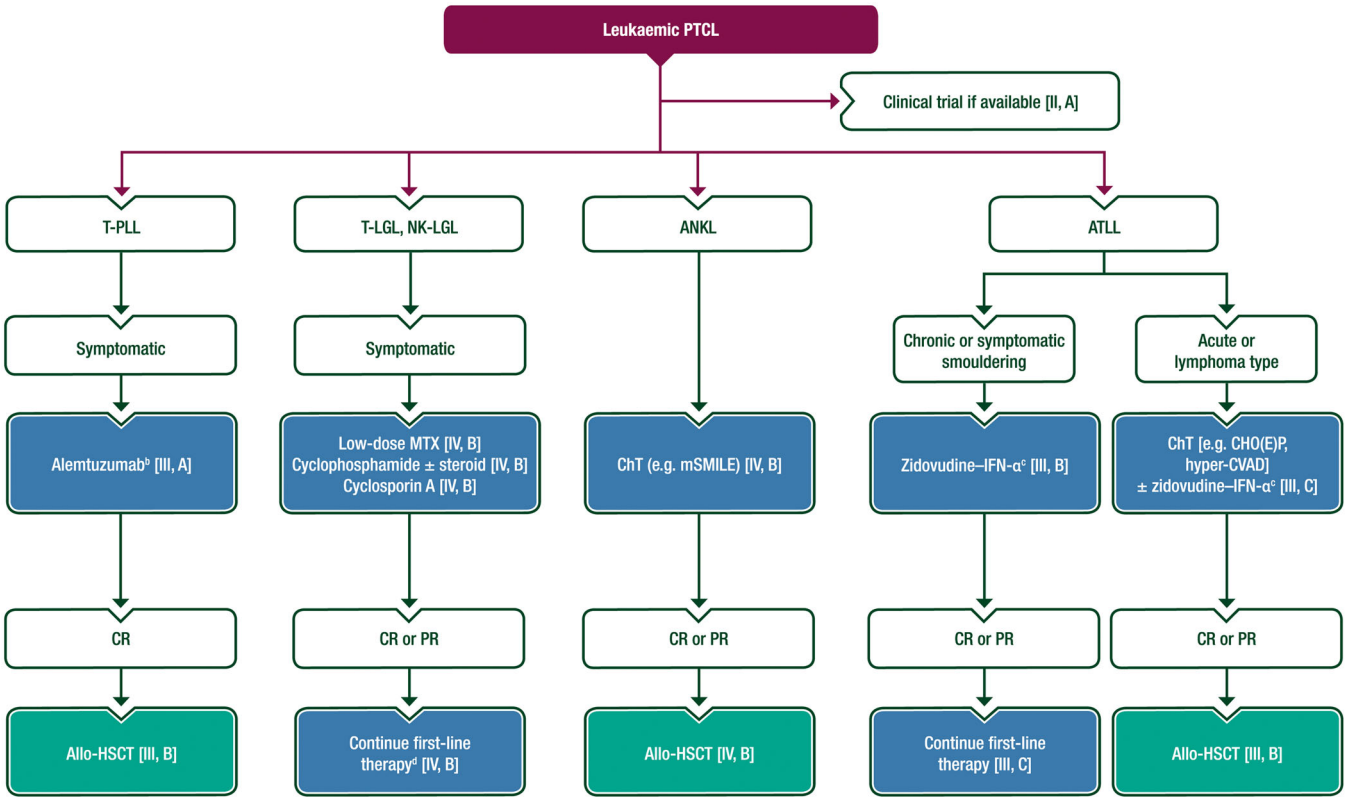

FIGURE 3 **Overview of first-line treatment in leukemic PTCL.**[a] Purple: algorithm title; blue: systemic anticancer therapy or their combination; turquoise: non-systemic anticancer therapies or combination of treatment modalities; white: other aspects of management and non-treatment aspects. Allo-HSCT, allogeneic hematopoietic stem-cell transplantation; ANKL, aggressive natural killer-cell leukemia; ATLL, adult T-cell leukemia or lymphoma; CHO(E)P, cyclophosphamide–doxorubicin–vincristine(–etoposide)–prednisolone; ChT, chemotherapy; CR, complete remission; EMA, European Medicines Agency; FDA, Food and Drug Administration; hyper-CVAD, hyperfractionated cyclophosphamide–vincristine–doxorubicin–dexamethasone–methotrexate–cytarabine; IFN-α, interferon-α; mSMILE, modified dexamethasone–methotrexate–ifosfamide–pegylated L-asparaginase–etoposide; MTX, methotrexate; NK-LGL, natural killer-cell large granular lymphocytic leukemia; PR, partial remission; PTCL, peripheral T-cell or natural killer-cell lymphoma; T-LGL, T-cell large granular lymphocytic leukemia; T-PLL, T-cell prolymphocytic leukemia. [a]For subtype-specific treatment algorithms, see Supporting Information: Figures S11–S14. [b]Not EMA or FDA approved but available via named-patient access. [c]Not EMA or FDA approved. [d]No limitation in treatment duration for MTX and cyclosporin A; treatment with cyclophosphamide should be limited to 12 months due to the risk of second malignancy.

CR (79%; 95% CI 64%–89%). BV-CHEP with auto-HSCT yielded better outcomes than BV-CHEP alone.

Role of HSCT

Due to the favorable outcome of low-risk ALK-positive ALCL (IPI < 2 and age <40 years) after standard CHOP, consolidative auto-HSCT is not recommended in the first remission. In high-risk ALK-positive ALCL (bulky disease, IPI ≥ 2, age >40 years, no CR after three ChT cycles) auto-HSCT can be considered on a case-by-case basis. The NLG-T-01 trial reported a 5-year PFS rate of 61% and a 5-year OS rate of 70% in 31 patients with ALK-negative ALCL.[19] In ECHELON-2, a comparative outcome analysis of consolidative HSCT versus no further treatment showed a survival benefit after auto-HSCT in both treatment arms (BV-CHP and CHOP) in patients with ALK-negative ALCL.[41] Interestingly, the survival advantage was more evident in the BV-CHP arm.

BIA-ALCL

Early diagnosis of BIA-ALCL is crucial for optimal outcomes; therefore, raising awareness of potential BIA-ALCL development in individuals with textured-surface breast implants and associated breast symptoms is important. A multidisciplinary approach is fundamental for staging and optimal treatment, which can limit morbidity and the need for systemic treatment, resulting in better outcomes.[42] An adapted overview of the TNM (tumor–node–metastasis) staging system for BIA-ALCL, proposed by Clemens et al.[43] and modified in Turton et al.[42] is shown in Supporting Information: Table S5.

Total capsulectomy with removal of the breast implant and excision of any associated mass is the standard treatment for patients with no signs of further disease dissemination (stage IA-IC).[43] If enlarged regional lymph nodes are detected on physical examination and/or diagnostic imaging, they should not be assumed to represent lymphoma, as they can be reactively enlarged due to silicone.[44] A representative biopsy (preferably excision) is preferred. Removal of the contralateral implant, particularly if textured, should be considered since bilateral breast involvement has been reported in ~5% of patients.[45] In a retrospective study, patients presenting with an isolated seroma with or without an associated tumor mass, but without signs of further disease dissemination, had a good prognosis with a 5-year OS rate of 91% and a 5-year EFS rate of 49%.[43] Results were better following complete surgical excision versus partial capsulectomy, systemic ChT, or RT.[46] Mastectomy or sentinel node

25729241, 2025, 5, Downloaded from https://onlinelibrary.wiley.com/doi/10.1002/hem3.70128 by CochraneItalia, Wiley Online Library on [28/03/2026]. See the Terms and Conditions (https://onlinelibrary.wiley.com/terms-and-conditions) on Wiley Online Library for rules of use; OA articles are governed by the applicable Creative Commons License

biopsy is not required, since BIA-ALCL is not a disease of the breast parenchyma, except in rare cases of deeply infiltrating disease. Patients with no residual disease on PET–CT after complete surgical excision of stage IA-IC disease can be followed up according to the UK national guidelines without further treatment.[42] RT may be beneficial for localized residual disease.[42,43] In patients with more advanced disease (stage IIA-IV), systemic treatment similar to the approach for systemic ALK-negative ALCL should be considered; however, evidence-based data are scarce in this setting and treatment should be defined on a case-by-case basis within a multidisciplinary setting. A detailed algorithm for the first-line management of BIA-ALCL is shown in Supporting Information: Figure S4.

HSTCL

Due to the paucity of prospective data, treatment recommendations for HSTCL are mainly based on results from small, retrospective case series. Aggressive platinum-based regimens (such as ifosfamide–carboplatin–etoposide [ICE]) or ifosfamide–etoposide–cytarabine (IVAC) seem to yield superior outcomes versus CHOP, as reported by a meta-analysis of 166 patients.[47] Patients treated with CHOP or CHOP-like regimens ($n = 50$) were compared with those who received non-CHOP multiagent ChT-containing platinum, cytarabine, and/or etoposide ($n = 34$). The objective response rate (ORR) was 52% versus 82% ($p = 0.006$) and the median OS was 18 versus 37 months ($p = 0.00014$), respectively. Purine analogs (pentostatin or cladribine), as monotherapy or combined with alemtuzumab, have also been associated with durable responses.[48] A retrospective study has reported improved outcomes with HSCT consolidation (mostly allo-HSCT due to graft-versus-lymphoma effect) for patients in the first or second remission.[49] HSCT has also shown efficacy in patients experiencing partial remission (PR) after the first- or second-line therapy. Due to the frequent involvement of the BM in HSTCL, PET–CT-based response assessment should be corroborated by BM biopsy and, if possible, liver biopsy since disseminated, non-focal intrahepatic tumor cell infiltration can be difficult to identify on PET–CT.[50] A detailed algorithm for the first-line management of HSTCL is shown in Supporting Information: Figure S5.

ENKTCL

Limited stage

Localized ENKTCL most commonly involves the nasal cavity, paranasal sinuses, Waldeyer's ring, and upper aerodigestive tract, but can also affect distant extranasal sites, such as the gastrointestinal (GI) tract, testis, and skin. RT is a central component of first-line treatment for localized disease.[51] Patients with non-bulky stage I disease, or patients with localized disease who are too frail to tolerate ChT, may be treated with RT alone to a dose of ≥50 Gy.[52] The optimal timing for RT is not clearly defined. For fit patients with localized stage I-II disease, concomitant, interposed ("sandwich schedule") or rapidly sequential chemoradiotherapy (CRT), with an early RT dose of ≥50 Gy and a platinum- and/or L-asparaginase-containing regimen, have been applied.[53] A large retrospective Asian and European study comparing the efficacy of concomitant and sequential CRT in limited-stage ENKTCL reported similar outcomes for both schedules.[54] ENKTCL is often locally destructive and may infiltrate extensively in the submucosa of the upper aerodigestive tract. A generous ISRT volume is required, covering the entire organ(s) pretherapeutically involved plus adjacent structures with concern for subclinical disease. Advanced imaging (e.g., PET–CT and MRI for intracranial and facial anatomy) and conformal RT techniques should be applied to guide therapy.[55] A detailed algorithm for the first-line management of ENKTCL is shown in Supporting Information: Figure S6.

Advanced stage

CHOP or CHOP-like ChT is not used in ENKTCL due to the upregulation of multidrug resistance p-glycoprotein. L-asparaginase is effective as it deprives tumor cells of L-asparagine, an important nutrient that cannot be efficiently synthesized by ENKTCL cells due to innate low L-asparagine synthetase levels.[56] A prospective trial from the Asia Lymphoma Study Group of 87 patients with ENKTCL (43 de novo and 44 relapsed or refractory [r/r]) evaluating dexamethasone–methotrexate–ifosfamide–pegylated L-asparaginase–etoposide (SMILE) reported an ORR of 81%.[57] At a median follow-up of 31 months, the 5-year OS rate was 50% and the 4-year disease-free survival rate was 64%. Twenty-four patients received consolidative auto- or allo-HSCT. The cumulative treatment-related mortality rate was 6%–7%. A randomized study of 42 patients comparing dexamethasone–cisplatin–gemcitabine–pegylated L-asparaginase (DDGP) with SMILE showed significantly improved 1-year PFS (86% vs. 38%, $p = 0.006$) and 2-year OS (74% vs. 45%, $p = 0.027$) rates in favor of DDGP, which was also better tolerated.[58] However, DDGP does not contain blood–brain barrier penetrating agents and may be less suitable for patients at high risk of CNS relapse. The L-asparaginase–methotrexate–dexamethasone (AspMetDex) regimen developed by Jaccard et al. is less intensive than SMILE, has CNS-penetrating capacity and is a good option for older or less fit patients.[59] Other regimens, such as pegylated L-asparaginase–gemicitabine–oxaliplatin (P-GEMOX),[60] have shown good efficacy and lower toxicity than SMILE. Very promising efficacy (ORR 100%; CR rate 87.5%) was recently reported in a multicentre phase II study evaluating P-GEMOX combined with the PD-1 inhibitor sintilimab in advanced ENKTCL.[61] At a median follow-up of 16.7 months, median PFS and OS were not reached and the estimated 1-year OS and PFS rates were 100% and 95%, respectively.

Consolidation with HSCT in responding patients

HSCT should be considered for the first-line consolidation in advanced-stage nasal ENKTCL and in distant extranasal disease of all stages, with the arguable exception of truly localized disease. There is no international consensus on which criteria to adopt for selecting auto- or allo-HSCT. A retrospective study based on the European Society for Bone Marrow Transplantation registry analyzed data from 28 patients treated with various first-line regimens and consolidated with auto-HSCT. The 2-year PFS and OS rates were 33% and 40%, respectively.[62] Regarding allo-HSCT, a retrospective analysis of 82 patients treated with L-asparaginase-containing regimens reported a 3-year OS rate of 35% in white patients and 33% in Asian patients.[63] A retrospective analysis of 65 French patients showed, after a median follow-up of 79.9 months, similar 4-year PFS and OS rates for auto- and allo-HSCT (PFS 34% vs. 26%, respectively; OS 52% vs. 53%, respectively).[64] Response status at HSCT was the major independent prognostic factor for survival (OS HR 4.013, 95% CI 1.137–14.16; PFS HR 5.231, 95% CI 1.625–16.838). Compared with ChT and/or RT alone, consolidative HSCT did not improve outcomes in responding patients, including those treated with L-asparaginase. Despite heterogeneity among studies of allo-HSCT in ENKTCL, a common feature is the low relapse rate beyond 2 years after transplant.[63]

25729241, 2025, 5, Downloaded from https://onlinelibrary.wiley.com/doi/10.1002/hem3.70128 by CochraneItalia, Wiley Online Library on [28/03/2026]. See the Terms and Conditions (https://onlinelibrary.wiley.com/terms-and-conditions) on Wiley Online Library for rules of use; OA articles are governed by the applicable Creative Commons License

EATL and intestinal T-cell lymphoma (TCL) NOS

Due to the rarity of EATL and intestinal TCL-NOS, evidence for treatment recommendations is limited, and enrollment in a first-line clinical trial is encouraged. An algorithm for first-line management is shown in Supporting Information: Figure S7. A retrospective study of 26 patients with previously untreated EATL who received one course of CHOP followed by ifosfamide–etoposide–epirubicin (IVE) alternated with intermediate-dose (3 g/m^2) methotrexate (MTX) and consolidative high-dose ChT and auto-HSCT (in responding patients) reported median PFS and OS of 3.4 months and 7.1 months, respectively.[65] The 5-year PFS and OS rates (52% and 60%, respectively) were higher than historical CHOP controls (5-year PFS and OS rates of 20%–22%). Recent interim analyses from an ongoing phase II single-arm trial evaluating BV-CHP and auto-HSCT in responding patients have demonstrated 2-year PFS and OS rates of 63% and 68%, respectively.[66] Further information on the first-line management of EATL and intestinal TCL-NOS is provided in Supporting Information Section 5.

T-PLL

International T-PLL-specific guidelines were updated in 2019.[67] An algorithm for the first-line management of T-PLL is shown in Supporting Information: Figure S8. Patients who are symptomatic or have signs of BM insufficiency, and who are HSCT eligible, should be treated with the aim of achieving a CR. The first-line treatment of choice is alemtuzumab.[68,69] In case of CR, consolidative non-myeloablative allo-HSCT is indicated. Further information on the first-line management of T-PLL is provided in Supporting Information Section 5.

T-LGL and NK-LGL

An algorithm for the first-line management of T-LGL and NK-LGL is shown in Supporting Information: Figure S9. Patients with symptomatic T-LGL or NK-LGL should initially receive monotherapy with drugs used in the treatment of autoimmune diseases. Existing evidence is primarily based on retrospective studies supporting the use of immunosuppressive rather than cytotoxic approaches. The most common first-line drugs are low-dose (weekly) MTX,[70] cyclophosphamide with or without steroids[71] or cyclosporin A.[72] The reported ORRs for these approaches in both T-LGL and NK-LGL are in the range of 40%–70% with response durations of 14–36 months.[70–72] Further information on the first-line management of T-LGL and NK-LGL is provided in Supporting Information Section 5.

Monomorphic epitheliotropic intestinal T-cell lymphoma, type II refractory celiac disease (RCD), indolent T- and NK-cell lymphoproliferative disorders of the GI tract, ANKL, and ATLL

First-line treatment options for monomorphic epitheliotropic intestinal T-cell lymphoma (MEITL), type II RCD, indolent T- and NK-cell lymphoproliferative disorders of the GI tract (iTLPD-GI and iNKLPD-GI), ANKL, and ATLL are described in Supporting Information Section 5. Detailed algorithms for the first-line management of these entities are shown in Supporting Information: Figures S10–S14.

Recommendations

- Patients should, whenever possible, be enrolled in a clinical trial (II, A).

PTCL-NOS and TFHL

- CHOP or CHOP-like ChT (e.g., CHOEP) can be recommended as the first-line therapy (II, B).
- In patients with limited-stage, non-bulky disease, and a favorable pre-therapeutic risk profile, an abbreviated course of ChT (e.g., three to four cycles of CHOP or CHOEP) can be considered (IV, B).
- Consolidative ISRT (e.g., 30-40 Gy in 15–20 fractions) can be considered for responding patients with limited-stage disease after CHOP or CHOP-like ChT (IV, B).
- Consolidative auto-HSCT can be considered in responding patients with high-risk limited-stage or advanced disease (III, B).

ALCL, systemic types

- In patients with limited-stage, non-bulky ALK-positive or ALK-negative disease, and a favorable pretherapeutic risk profile (IPI 0-1), an abbreviated course of ChT (e.g., three to four cycles of BV-CHP or CHOEP) can be considered (III, B).
- Six cycles of BV-CHP are recommended for all other ChT-eligible patients (i.e., both ALK negative and ALK positive) (I, A). Alternatively, six cycles of CHO(E)P can be considered (III, B).
- Consolidative ISRT (e.g., 30–40 Gy in 15–20 fractions) can be considered for limited-stage ALCL (IV, B).
- Consolidative auto-HSCT in the first CR can be considered for HSCT-eligible, chemosensitive patients with ALK-negative ALCL (II, B).
- In general, auto-HSCT cannot be recommended for patients with ALK-positive ALCL in the first CR (III, D). It can, however, be considered for patients with high-risk features (IPI ≥ 2, bulky disease) with no CR after three cycles of ChT (III, B).

BIA-ALCL

- A multidisciplinary approach is recommended for diagnostic assessment, staging, and treatment planning (III, A).
- Total capsulectomy with removal of the breast implant and excision of any associated mass is recommended for patients with no signs of further disease dissemination (III, A).
- A representative biopsy (excision preferred) should be obtained if suspicious regional lymph nodes are found (III, A).
- Removal of the contralateral implant is recommended, particularly if textured (III, A).
- Mastectomy cannot be recommended (IV, D).
- ISRT (e.g., 30 Gy in 15 fractions) is recommended following surgery in adapted TNM stage IIA-IIB disease and in stage IA-IC disease if there is evidence of residual disease (III, A).
- Six cycles of BV-CHP, CHOP, or CHOEP is recommended for patients with residual disease following ISRT and those with advanced disease (stages III–IV) (III, A).
- Auto-HSCT can be considered in responding patients following ChT (III, B).
- Bilateral capsulectomy can be considered in responding patients with advanced disease following ChT (III, B).

HSTCL

- In the absence of clinical trials, ChT that is more aggressive than CHOP is recommended for fit and HSCT-eligible patients (III, A).
- ICE is suggested as the preferred regimen for first-line therapy (IV, B). Other options include IVAC, dexamethasone–high-dose cytarabine–

25729241, 2025, 5, Downloaded from https://onlinelibrary.wiley.com/doi/10.1002/hem3.70128 by CochraneItalia, Wiley Online Library on [28/03/2026]. See the Terms and Conditions (https://onlinelibrary.wiley.com/terms-and-conditions) on Wiley Online Library for rules of use; OA articles are governed by the applicable Creative Commons License

cisplatin (DHAP), dexamethasone–cytarabine–oxaliplatin (DHAX), and CHOEP (IV, C).
- ChT options for frail and/or HSCT-ineligible patients include dose-reduced ICE and gemcitabine–oxaliplatin (GEMOX) (IV, C).
- Due to the frequent involvement of the BM in HSTCL, response assessment via PET–CT should be corroborated by BM biopsy and, if possible, liver biopsy, since diffuse intrahepatic tumor cell infiltration can be difficult to identify on PET–CT (III, A).
- If possible, BM and peripheral blood specimens should be analyzed by flow cytometry for assessment of surface antigens on tumor cells that are not reliably identifiable by routine IHC (e.g., CD52) (III, B).
- Eligible responding (CR or PR) patients should undergo consolidative HSCT, preferably allo-HSCT (III, A). Auto-HSCT is recommended for patients who are ineligible for allo-HSCT (III, A).

ENKTCL

- EBV DNA in peripheral blood should be monitored by quantitative PCR at baseline and during therapy as a biomarker of response, in addition to imaging-based response assessment (II, A).
- Fit patients with limited-stage disease should receive ISRT (≥50 Gy) with concurrent, interposed, or sequential anthracycline-free, L-asparaginase-containing ChT (e.g., DDGP or modified SMILE [mSMILE] for HSCT-eligible and AspMetDex or P-GEMOX for HSCT-ineligible patients) (II, A).
- A multiagent, anthracycline-free, L-asparaginase-containing regimen can be recommended for patients with stages III and IV nasal disease or stages I–IV extranasal disease (e.g., DDGP or mSMILE for HSCT-eligible and AspMetDex or P-GEMOX for HSCT-ineligible patients) (III, B). The addition of ISRT can be decided on a case-by-case basis (III, B).
- First-line treatment with anti-PD-1 antibodies such as sintilimab (not European Medicines Agency [EMA] or Food and Drug Administration [FDA] approved) in combination with L-asparaginase-containing regimens (e.g., P-GEMOX) should also be considered in patients with stages III and IV nasal disease or stages I–IV extranasal disease (III, A).
- If available, crisantaspase (*Erwinia chrysanthemi*-derived L-asparaginase) is recommended for patients who have developed hypersensitivity or inactivating antibodies to *Escherichia coli*-derived L-asparaginase (III, A; not EMA or FDA approved in ENKTCL).
- In HSCT-eligible responding high-risk patients, consolidative auto- or allo-HSCT can be considered (III, B). The choice of HSCT should be made on a case-by-case basis considering factors such as pretherapeutic risk profile, response to first-line therapy, performance status (PS), and donor availability (III, B).

EATL and intestinal TCL-NOS

- In fit and HSCT-eligible patients, one cycle of CHOP or CHOEP, followed by three cycles of IVE alternated with intermediate-dose MTX can be recommended (III, B). Alternative regimens are six cycles of BV-CHP (FDA approved, not EMA approved), CHOP, or CHOEP (III, B).
- Consolidative high-dose ChT–auto-HSCT can be considered for HSCT-eligible responding patients (III, B).
- Six cycles of CHOP or CHOP-like ChT (IV, B) or six cycles of BV-CHP (III, B; FDA approved, not EMA approved) can be recommended for frail or otherwise HSCT-ineligible patients.

T-PLL

- A watch-and-wait approach can be recommended for asymptomatic T-PLL (III, B).
- Alemtuzumab (given intravenously with a dose escalation of 3, 10, and 30 mg in the first week followed by 30 mg three times per week over a total of 10–12 weeks) is recommended for newly diagnosed symptomatic T-PLL (III, A; not EMA or FDA approved but available via named-patient access).
- Assessment of CD52 status by flow cytometry can be recommended before, during, and after treatment (III, B).
- During alemtuzumab therapy, antimicrobial prophylaxis against herpes zoster and *Pneumocystis jirovecii* is recommended, as well as quantitative cytomegalovirus DNA monitoring (III, A).
- Consolidative non-myeloablative allo-HSCT can be recommended in eligible patients achieving CR who have a donor (III, B); otherwise, auto-HSCT can be considered on a case-by-case basis (IV, C).

T-LGL and NK-LGL

- Asymptomatic patients without severe cytopenias or substantial splenomegaly can be managed initially by observation only (IV, B).
- Symptomatic patients (e.g., transfusion-requiring anemia and/or thrombocytopenia, severe neutropenia [neutrophils $<0.5 \times 10^9$/L] and/or symptomatic splenomegaly) can begin immunosuppressive first-line treatment with low-dose weekly MTX (preferred in patients with associated autoimmune disease), cyclophosphamide (with or without a steroid) or cyclosporin A (the last two preferred in patients with severe cytopenias) (IV, B).
- The efficacy of first-line treatment can be evaluated after 3–4 months, and the same treatment can continue if response (CR or PR) and feasibility are satisfactory (IV, B).

MEITL

- Non-CHOP multiagent ChT can be recommended (preferred) (IV, B).
  - Options for HSCT-eligible patients include ICE (preferred), IVAC, DHAP, DHAX, and CHOEP (IV, B).
  - Options for HSCT-ineligible patients include dose-reduced ICE, gemcitabine–dexamethasone–cisplatin (GDP), and GEMOX (V, B).
- Allo-HSCT consolidation can be considered in chemosensitive (CR or PR) HSCT-eligible patients with a suitable donor (IV, B).

Type II RCD

- If aberrant, clonal intraepithelial lymphocytes are found, small bowel imaging with capsule endoscopy and a PET–CT scan (possibly supplemented by magnetic resonance enterography) should be carried out to exclude EATL and ulcerative jejunoileitis (III, A).
- Tissue biopsies should be examined by an experienced hematopathologist to identify lesions suggestive of EATL (including CD30 expression) (III, A).
- If EATL is diagnosed, specific management for this entity should be initiated. If not, checks for EATL, including small bowel imaging in case of new symptoms or signs concerning for EATL, at 6–12-month intervals can be considered (IV, B).

25729241, 2025, 5, Downloaded from https://onlinelibrary.wiley.com/doi/10.1002/hem3.70128 by CochraneItalia, Wiley Online Library on [28/03/2026]. See the Terms and Conditions (https://onlinelibrary.wiley.com/terms-and-conditions) on Wiley Online Library for rules of use; OA articles are governed by the applicable Creative Commons License

iTLPD-GI and iNKLPD-GI

- Aggressive approaches based on conventional combination ChT should only be used in case of verified dissemination and/or histological transformation (IV, B).
- An observational approach can be recommended, focusing primarily on ruling out disease progression and dissemination (IV, B). Individual lesions may be endoscopically verified for risk of intestinal wall perforation (e.g., presence of deep erosions) (IV, C).
- ISRT may be considered in case of solitary symptomatic lesions (IV, C).
- Limited surgical resection may be considered in case of deep intestinal wall erosion (e.g., superficial mucosal erosion deepened by subsequent local infection or inflammation) with a high perforation risk (IV, C).

ANKL

- In fit, HSCT-eligible patients, an intensive L-asparaginase-containing ChT first-line regimen (e.g., mSMILE) can be recommended (IV, B), with the aim of consolidating a primary response with allo-HSCT (IV, B).
- In patients who are frail and/or HSCT ineligible, a non-intensive L-asparaginase-containing ChT regimen (e.g., AspMetDex) can be considered (IV, B).

ATLL

- Testing for HTLV-1 can be recommended in first-degree relatives and partners of patients with ATLL (II, B).
- Antimicrobial prophylaxis for opportunistic infections can be recommended for all patients (II, B). In case of positive *Strongyloides stercoralis* serology, treatment can be initiated even if the patient is asymptomatic (III, B).
- Asymptomatic smoldering ATLL can be managed with active monitoring without immediate therapeutic intervention (III, B).
- Zidovudine–interferon-α (IFN-α) can be recommended for patients with symptomatic smoldering (skin or lung lesions, opportunistic infections), primary cutaneous with tumoural lesions or chronic ATLL (III, B; not EMA or FDA approved), along with skin-directed therapy in case of skin lesions (III, B).
- CNS prophylaxis can be recommended for all patients with acute or lymphoma-type ATLL (III, B).
- High-dose zidovudine–IFN-α can be recommended as first-line therapy for patients with acute, non-bulky, non-lymphomatous ATLL whenever feasible, particularly for those who are unsuitable for intensive ChT or allo-HSCT (III, B; not EMA or FDA approved).
- Patients with acute or lymphoma-type ATLL with bulky lesions may receive intensive combination ChT (e.g., CHOP, CHOEP or hyperfractionated cyclophosphamide–vincristine–doxorubicin–dexamethasone–MTX–cytarabine [hyper-CVAD]) with or without concurrent or sequential zidovudine–IFN-α (if tolerated) (III, C; not EMA or FDA approved).
- Chemosensitive patients can proceed to allo-HSCT (III, B). An antiretroviral agent can be added to the conditioning regimen to prevent HTLV-1 neoinfection of donor cells (III, B).
- Responding patients who are ineligible for allo-HSCT may receive maintenance therapy with zidovudine–IFN-α with or without arsenic trioxide (III, C; not EMA or FDA approved). If zidovudine–IFN-α is poorly tolerated or there is no longer a response, oral low-dose etoposide may be considered as monotherapy or as part of a regimen (III, C).

TREATMENT OF R/R DISEASE

Patients with r/r PTCL have a poor prognosis, with a study reporting median PFS and OS of 3.1 months and 5.5 months, respectively.[73] Algorithms for the management of r/r PTCL are shown in Figure 4 (r/r nodal PTCL), Figure 5 (r/r extranodal PTCL), and Figure 6 (r/r leukemic PTCL).

r/r nodal and extranodal PTCL, except ALK-positive ALCL, ENKTCL, iTLPD-GI, and iNKLPD-GI

Allo-HSCT is the best curative option for HSCT-eligible, chemosensitive patients, if not already applied. The poor prognosis justifies enrollment in a clinical trial whenever possible; otherwise, ChT used to treat r/r DLBCL (e.g., ICE, DHAP, and GDP) is widely used, although efficacy data are limited. BV monotherapy has shown efficacy in ALK-negative ALCL.[74,75] Single-agent romidepsin,[76] belinostat[77] and pralatrexate[78] have been conditionally approved by the FDA but not by the EMA. The phosphoinositide 3-kinase (PI3K)δ and PI3Kγ inhibitor duvelisib have demonstrated efficacy[79] but are not approved for use in PTCL. Bendamustine has demonstrated an ORR of 50%, although response duration is usually short.[80] Cyclosporin A, lenalidomide, and 5-aza have shown efficacy in r/r AITL.[81–83] Oral 5-aza has also been investigated in a phase III trial of r/r TFHL, comparing it with investigator's choice of gemcitabine, bendamustine, or romidepsin.[84] Although the trial did not meet its primary endpoint (superior PFS in the experimental arm), 5-aza was associated with prolonged OS and a favorable safety profile, suggesting it could be useful in some patients with TFHL. Notably, romidepsin, bendamustine, cyclosporin A, lenalidomide, 5-aza, and gemcitabine given as monotherapy have achieved ORRs <40%, with rare sustained responses.

HSCT

Data supporting auto-HSCT consolidation in chemosensitive r/r PTCL are limited and based on retrospective series, with a 3-year OS rate of ~50%. Patients may experience sustained response and prolonged survival after allo-HSCT,[85] with retrospective series reporting a 5-year OS rate of ~50%. The type of conditioning regimen does not seem to affect failure rate, PFS or OS, suggesting that less-toxic, non-myeloablative conditioning should be favored.[86] Recent data suggest that transplantation using a haploidentical donor provides similar outcomes to a matched related donor.[87]

r/r ALK-positive ALCL

Patients with r/r ALK-positive ALCL benefit from BV monotherapy (ORR 86%, CR rate 57%)[88]; however, most patients receive BV-CHP in first line. Limited data suggest that patients achieving a sustained response after first-line BV-containing treatment could benefit from BV retreatment[89]; however, the relevance of BV retreatment as monotherapy or in combination with ChT in the r/r setting is unclear. For patients who are refractory to BV, first-generation (e.g., crizotinib) and second-generation (e.g., alectinib, brigatinib, ceritinib) ALK inhibitors have been associated with CR rates of 25%–80% and a 1-year PFS rate of 60%.[90–92] Responding patients should undergo consolidation; auto-HSCT was associated with poor outcomes in a cohort of patients aged ≤21 years, supporting the use of allo-HSCT.[93]

r/r ENKTCL

The anti-PD-1 antibodies pembrolizumab and nivolumab have induced responses in r/r ENKTCL following L-asparaginase-

25729241, 2025, 5, Downloaded from https://onlinelibrary.wiley.com/doi/10.1002/hem3.70128 by CochraneItalia, Wiley Online Library on [28/03/2026]. See the Terms and Conditions (https://onlinelibrary.wiley.com/terms-and-conditions) on Wiley Online Library for rules of use; OA articles are governed by the applicable Creative Commons License

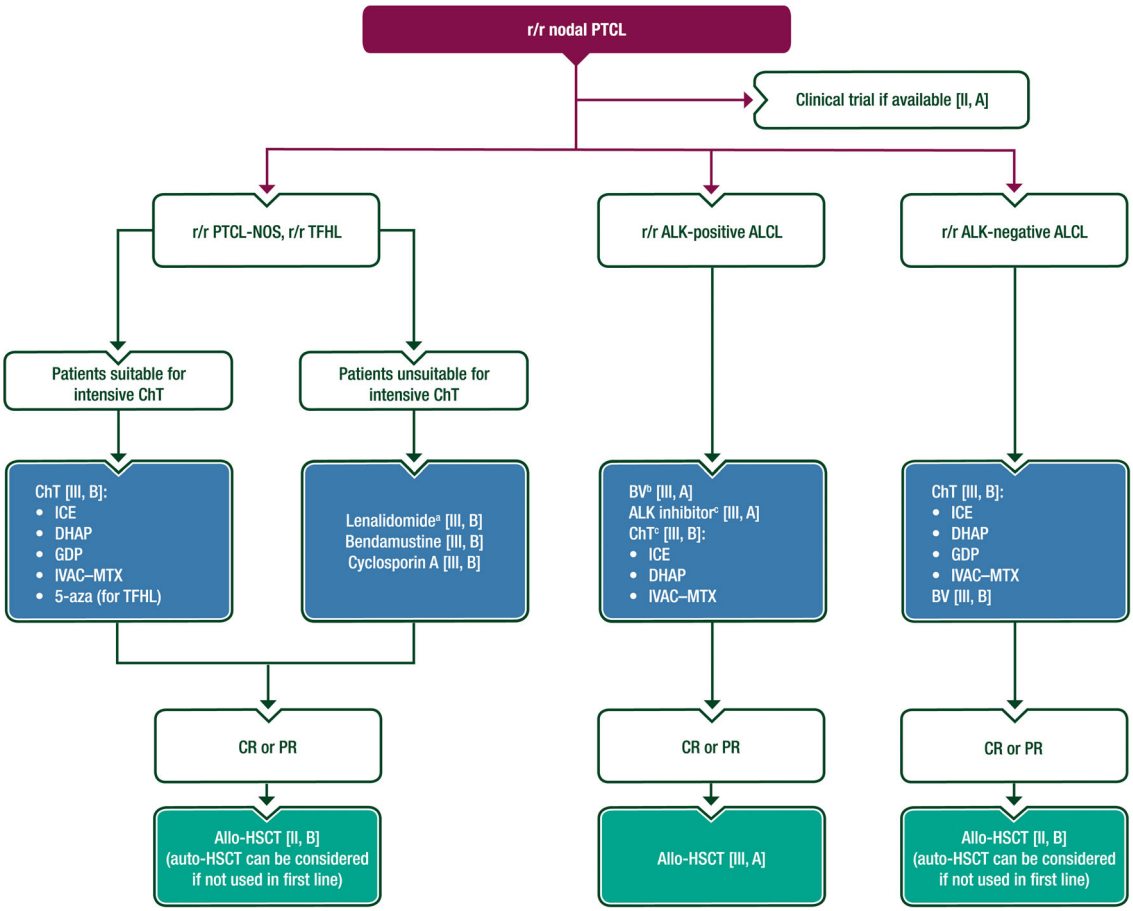

FIGURE 4 **Treatment of r/r nodal PTCL.** Purple: algorithm title; blue: systemic anticancer therapy or their combination; turquoise: non-systemic anticancer therapies or combination of treatment modalities; white: other aspects of management and non-treatment aspects. 5-aza, 5-azacitidine; ALCL, anaplastic large cell lymphoma; ALK, anaplastic lymphoma kinase; allo-HSCT, allogeneic hematopoietic stem-cell transplantation; auto-HSCT, autologous hematopoietic stem-cell transplantation; BV, brentuximab vedotin; ChT, chemotherapy; CR, complete remission; DHAP, dexamethasone–high-dose cytarabine–cisplatin; EMA, European Medicines Agency; FDA, Food and Drug Administration; GDP, gemcitabine–dexamethasone–cisplatin; ICE, ifosfamide–carboplatin–etoposide; IVAC, ifosfamide–etoposide–cytarabine; MTX, methotrexate; NOS, not otherwise specified; PR, partial remission; PTCL, peripheral T-cell or natural killer-cell lymphoma; r/r, relapsed or refractory; TFHL, follicular helper T-cell derived lymphoma. [a]Not EMA or FDA approved. [b]Patients who did not receive first-line BV or those with late relapse after an initial response. [c]Patients refractory to BV.

based regimens.[94,95] BV efficacy has been demonstrated only in anecdotal case reports of CD30-positive r/r ENKTCL.[96] For HSCT-eligible patients responding to salvage therapy, HSCT (preferably allo-HSCT) is an option based on small case series and case reports.[64]

r/r T-PLL

r/r T-PLL is an extremely treatment-refractory condition with limited therapeutic options that can induce responses to allow consolidative allo-HSCT in HSCT-eligible patients. Inclusion in a clinical trial should always be considered. A new course of alemtuzumab, preferably in combination with a purine analog (e.g., pentostatin), should be considered at relapse after a treatment-free period of ≥6 months in patients who still have CD52-positive tumor cells.[67] A phase II study of 13 patients with r/r T-PLL who received alemtuzumab–pentostatin reported an ORR of 69%, median OS of 10.2 months, and median PFS of 7.8 months.[48]

r/r T-LGL and NK-LGL

Alemtuzumab was investigated prospectively in 25 patients with T-LGL (23 with r/r T-LGL), of which six were diagnosed with T-LGL after allo-HSCT transplant or co-existing with a myelodysplastic syndrome.[97] The 19 patients with "classical" T-LGL had a 3-month ORR of 74% and a 12-month ORR of 68%. *STAT3* mutational status had no prognostic impact. Purine analogs (pentostatin, cladribine, fludarabine) and splenectomy have also shown some activity in r/r T-LGL and NK-LGL in small case series or individual case reports. Ruxolitinib has demonstrated preliminary efficacy in r/r T-LGL and across other PTCL subtypes.[98,99]

r/r iTLPD-GI, iNKLPD-GI, ANKL, and ATLL

Treatment options for r/r iTLPD-GI, iNKLPD-GI, ANKL, and ATLL are described in Supporting Information Section 6.

25729241, 2025, 5, Downloaded from https://onlinelibrary.wiley.com/doi/10.1002/hem3.70128 by CochraneItalia, Wiley Online Library on [28/03/2026]. See the Terms and Conditions (https://onlinelibrary.wiley.com/terms-and-conditions) on Wiley Online Library for rules of use; OA articles are governed by the applicable Creative Commons License

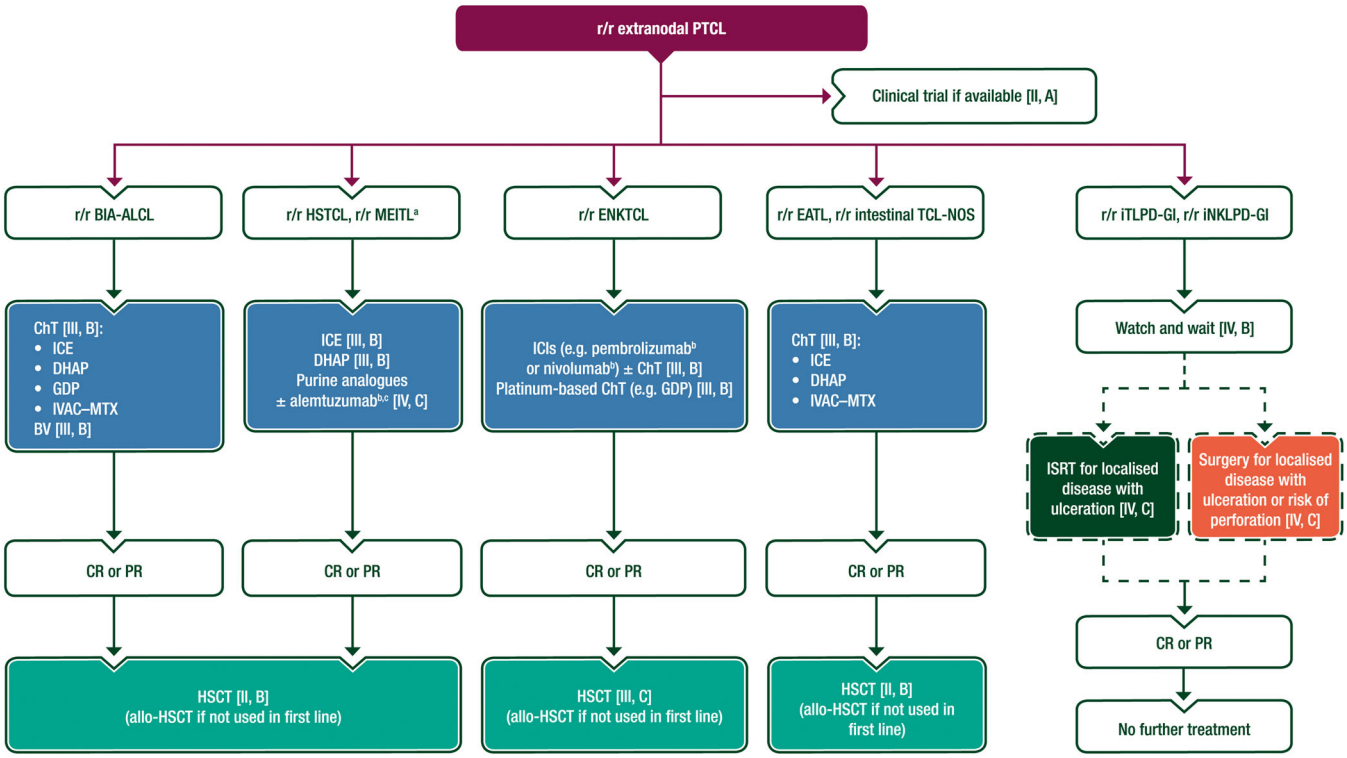

FIGURE 5 **Treatment of r/r extranodal PTCL.** Purple: algorithm title; orange: surgery; dark green: RT; blue: systemic anticancer therapy or their combination; turquoise: non-systemic anticancer therapies or combination of treatment modalities; white: other aspects of management and non-treatment aspects; dashed lines: optional therapy. ALCL, anaplastic large cell lymphoma; ALK, anaplastic lymphoma kinase; allo-HSCT, allogeneic hematopoietic stem-cell transplantation; BIA, breast implant associated; BM, bone marrow; BV, brentuximab vedotin; CD, cluster of differentiation; ChT, chemotherapy; CR, complete remission; DHAP, dexamethasone–high-dose cytarabine–cisplatin; EATL, enteropathy-associated T-cell lymphoma; EMA, European Medicines Agency; ENKTCL, extranodal natural killer- or T-cell lymphoma; FDA, Food and Drug Administration; GDP, gemcitabine–dexamethasone–cisplatin; HSCT, hematopoietic stem-cell transplantation; HSTCL, hepatosplenic T-cell lymphoma; ICE, ifosfamide–carboplatin–etoposide; ICI, immune checkpoint inhibitor; iNKLPD-GI, indolent natural killer-cell lymphoproliferative disorders of the gastrointestinal tract; ISRT, involved-site radiotherapy; iTLPD-GI, indolent T-cell lymphoproliferative disorders of the gastrointestinal tract; IVAC, ifosfamide–etoposide–cytarabine; MEITL, monomorphic epitheliotropic intestinal T-cell lymphoma; MTX, methotrexate; NOS, not otherwise specified; PR, partial remission; PTCL, peripheral T-cell or natural killer-cell lymphoma; r/r, relapsed or refractory; RT, radiotherapy; TCL, T-cell lymphoma. [a]No specific recommendations available. Due to shared biological features, consider treating as r/r HSTCL. [b]Not EMA or FDA approved. [c]Consider alemtuzumab if CD52-positive tumor cells demonstrated by flow cytometry (e.g., BM or peripheral blood sample).

Recommendations

- The poor prognosis of r/r PTCL justifies patient inclusion in a clinical trial whenever possible (II, A).

r/r nodal and extranodal PTCL, except ALK-positive ALCL, ENKTCL, iTLPD-GI, and iNKLPD-GI

- If a clinical trial is not available, platinum-based regimens that are non-cross resistant to the first-line anthracycline-based ChT can be considered (III, B).
  - Options for r/r PTCL-NOS and TFHL include ICE, DHAP, GDP, IVAC–MTX, and 5-aza (for TFHL only) (III, B). Options for patients who are not fit enough for intensive ChT include lenalidomide (not EMA or FDA approved), bendamustine, and cyclosporin A (III, B).
  - Options for r/r ALK-negative ALCL and BIA-ALCL include ICE, DHAP, GDP, IVAC–MTX (III, B). BV monotherapy is also an option (III, B).
  - Options for r/r HSTCL and MEITL include ICE and DHAP (III, B). A purine analog with or without alemtuzumab is also an option if CD52-positive tumor cells are demonstrated by flow cytometry (e.g., BM or peripheral blood sample) (IV, C; not EMA or FDA approved).
  - Options for r/r EATL and intestinal TCL-NOS include ICE, DHAP, and IVAC–MTX (III, B).
- For HSCT-eligible patients responding to salvage therapy, HSCT (preferably allo-HSCT if not used in first line) can be considered (II, B).

r/r ALK-positive ALCL

- BV is recommended in patients who did not receive first-line BV or those with late relapse after an initial response (III, A).
- For patients refractory to BV, ALK inhibitors such as crizotinib (EMA and FDA approved in children and young adults), alectinib (not EMA or FDA approved), brigatinib (not EMA or FDA approved), or ceritinib (not EMA or FDA approved) should be considered (III, A). ChT (e.g., ICE, DHAP, or IVAC–MTX) is also an option (III, B).
- Consolidative allo-HSCT should be considered, based on response to salvage therapy, current remission quality, comorbid conditions, and predicted tolerability (III, A).

25729241, 2025, 5, Downloaded from https://onlinelibrary.wiley.com/doi/10.1002/hem3.70128 by CochraneItalia, Wiley Online Library on [28/03/2026]. See the Terms and Conditions (https://onlinelibrary.wiley.com/terms-and-conditions) on Wiley Online Library for rules of use; OA articles are governed by the applicable Creative Commons License

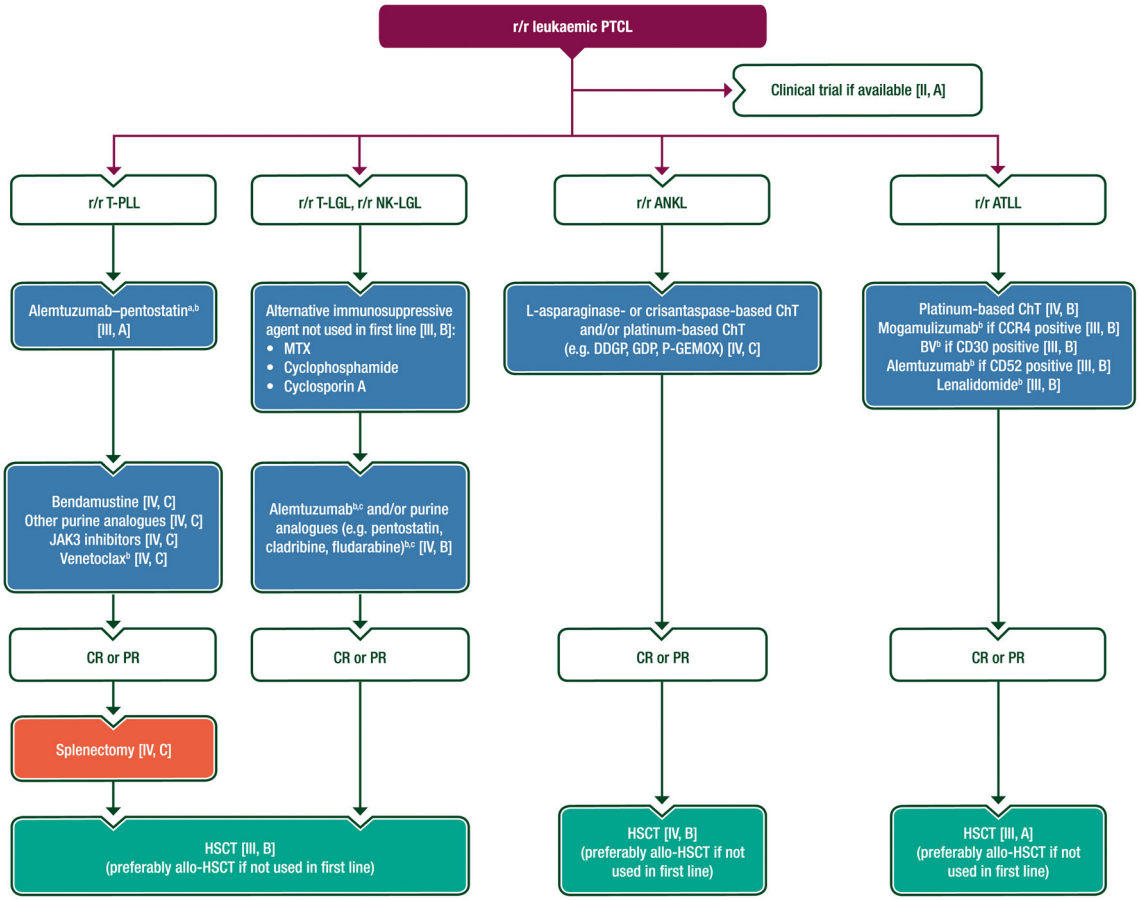

FIGURE 6 **Treatment of r/r leukemic PTCL.** Purple: algorithm title; orange: surgery; blue: systemic anticancer therapy or their combination; turquoise: non-systemic anticancer therapies or combination of treatment modalities; white: other aspects of management and non-treatment aspects. Allo-HSCT, allogeneic hematopoietic stem-cell transplantation; ANKL, aggressive natural killer-cell leukemia; ATLL, adult T-cell leukemia or lymphoma; BV, brentuximab vedotin; CCR4, C-C chemokine receptor type 4; CD, cluster of differentiation; ChT, chemotherapy; CR, complete remission; DDGP, dexamethasone–cisplatin–gemcitabine–pegylated L-asparaginase; EMA, European Medicines Agency; FDA, Food and Drug Administration; GDP, gemcitabine–dexamethasone–cisplatin; HSCT, hematopoietic stem-cell transplantation; JAK3, Janus kinase 3; MTX, methotrexate; NK-LGL; natural killer-cell large granular lymphocytic leukemia; P-GEMOX, pegylated L-asparaginase–gemicitabine–oxaliplatin; PR, partial remission; PTCL, peripheral T-cell or natural killer-cell lymphoma; r/r, relapsed or refractory; T-LGL, T-cell large granular lymphocytic leukemia; T-PLL, T-cell prolymphocytic leukemia. [a]After a treatment-free period of ≥6 months in patients who still have CD52-positive tumor cells. [b]Not EMA or FDA approved. [c]In patients who do not respond to MTX, cyclophosphamide, or cyclosporin A.

r/r ENKTCL

- If available, an anti-PD-1 antibody such as pembrolizumab (not EMA or FDA approved) or nivolumab (not EMA or FDA approved) can be considered as monotherapy or in combination with gemcitabine and/or L-asparaginase or crisantaspase (III, B).
- As an alternative, platinum-based regimens (e.g., GDP) can be considered (III, B).
- For HSCT-eligible patients responding to salvage therapy, HSCT (preferably allo-HSCT if not used in first line) may be considered (III, C).

r/r T-PLL

- Alemtuzumab–pentostatin is recommended after a treatment-free period of ≥6 months in patients who still have CD52-positive tumor cells (III, A; not EMA or FDA approved). Bendamustine, other purine analogs, JAK3 inhibitors, and venetoclax (not EMA or FDA approved) are options following alemtuzumab–pentostatin (IV, C).
- Splenectomy may be considered in responding patients (IV, C).
- Consolidative HSCT (preferably allo-HSCT if not used in first line) can be recommended for HSCT-eligible responding patients (III, B).

r/r T-LGL and NK-LGL

- An alternative immunosuppressive agent from the list of those suggested for first-line treatment (MTX, cyclophosphamide, cyclosporin A) can be considered (III, B).
- Alemtuzumab (not EMA or FDA approved) and/or purine analogs (not EMA or FDA approved; e.g., pentostatin, cladribine, fludarabine) can be considered in patients who do not respond to MTX, cyclophosphamide, or cyclosporin A (IV, B).
- Consolidative HSCT (preferably allo-HSCT if not used in first line) can be recommended for HSCT-eligible responding patients (III, B).

25729241, 2025, 5, Downloaded from https://onlinelibrary.wiley.com/doi/10.1002/hem3.70128 by CochraneItalia, Wiley Online Library on [28/03/2026]. See the Terms and Conditions (https://onlinelibrary.wiley.com/terms-and-conditions) on Wiley Online Library for rules of use; OA articles are governed by the applicable Creative Commons License

r/r iTLPD-GI and iNKLPD-GI

- Watch and wait can be recommended (IV, B), with ISRT considered for localized disease with ulceration (IV, C) and surgery as an option for localized disease with ulceration or risk of perforation (IV, C).

r/r ANKL

- If a clinical trial is not available and patient PS allows, an alternative L-asparaginase- or crisantaspase- and/or platinum-based regimen (e.g., DDGP, GDP, P-GEMOX) may be considered (IV, C).
- Allo-HSCT (if not used in first line) can be considered in HSCT-eligible patients who are responding to salvage therapy (IV, B).

r/r ATLL

- A second-line platinum-based regimen can be considered (IV, B).
- Monotherapy with mogamulizumab (if CCR4-positive; not EMA or FDA approved), BV (if CD30-positive; not EMA or FDA approved), alemtuzumab (if CD52-positive; not EMA or FDA approved), or lenalidomide (not EMA or FDA approved) can be considered (III, B).
- Allo-HSCT (if not used in first line) should be considered in HSCT-eligible responding patients (III, A).
- In case of planned allo-HSCT, mogamulizumab should not be administered within 50 days before allo-HSCT (III, A).

RESPONSE EVALUATION AND FOLLOW-UP

Response evaluation and follow-up in patients with PTCL are described in Supporting Information Section 7.

Recommendations

- An interim evaluation can be carried out to assess chemosensitivity (II, B).
- Diagnostic imaging (preferably PET–CT) can be repeated at EOT along with a BM biopsy, if initially involved (II, B).
- Interim PET response has outcome-predictive value in nodal PTCLs, except for ALK-positive ALCL (II, B).
- Follow-up may include history and physical examination every 3 months for 1 year and every 6 months for 2 further years (non-auto-HSCT consolidated patients) or 4 further years (auto-HSCT consolidated patients) (IV, C).
- Routine surveillance with PET–CT or diagnostic CT cannot be recommended for patients with CR (III, D).
- EBV DNA monitoring is recommended for patients with ENKTCL (II, A) and is optional for patients with nodal PTCL and circulating EBV DNA at diagnosis (IV, C).
- Follow-up can be discontinued after 3 years in non-transplanted asymptomatic patients (III, B) and after 5 years in asymptomatic patients who have received auto-HSCT (III, B), if the patient is considered to be in ongoing CR. In patients who have received allo-HSCT, the general guidelines for allo-HSCT should be applied (III, A).

METHODOLOGY

This CPG was developed in accordance with the ESMO standard operating procedures for CPG development (http://www.esmo.org/Guidelines/ESMO-Guidelines-Methodology). The relevant literature has been selected by the expert authors. The FDA/EMA or other regulatory body approval status of new therapies/indications is reported at the time of writing this CPG. Levels of evidence and grades of recommendation have been applied using the system shown in Supporting Information: Table S6. Statements without grading were considered justified standard clinical practice by the authors. For future updates to this CPG, including eUpdates and Living Guidelines, please see the ESMO Guidelines website: https://www.esmo.org/guidelines/guidelines-by-topic/haematological-malignancies/peripheral-t-cell-lymphomas.

ACKNOWLEDGMENTS

This article has been simultaneously co-published in *HemaSphere* and *Annals of Oncology*. The articles are identical except for minor stylistic and spelling differences in keeping with each journal's style. Either citation can be used when citing this article. Manuscript editing support was provided by Ioanna Ntai, Lisa Farrar and Claire Bramley (ESMO Guidelines staff), and Angela Corstorphine and Sian-Marie Lucas of Kstorfin Medical Communications Ltd (KMC); this support was funded by ESMO.

AUTHOR CONTRIBUTIONS

All authors conceptualized, performed the literature search, and reviewed and edited the manuscript. Francesco d'Amore and Massimo Federico performed the literature review and development of clinical recommendations. Francesco d'Amore and Laurence de Leval visualized the work. Francesco d'Amore, Laurence de Leval, Massimo Federico, François Lemonnier, Olivier Hermine, Fredrik Ellin, and Joost S. P. Vermaat wrote the original draft. The following authors contributed to section-specific contributions: epidemiology, staging and risk assessment, follow-up—Fredrik Ellin, Massimo Federico, and Francesco d'Amore; diagnosis and pathology—Laurence de Leval and Joost S. P. Vermaat; primary treatment—Francesco d'Amore, François Lemonnier, Olivier Hermine, Massimo Federico, Won Seog Kim, Gerald Wulf, and Fredrik Ellin; treatment of relapsed/refractory disease—Francesco d'Amore, François Lemonnier, Olivier Hermine, Massimo Federico, Won Seog Kim, Gerald Wulf, and Fredrik Ellin.

CONFLICT OF INTEREST STATEMENT

F. d. A. reports institutional fees for an advisory role from Frost; institutional fees as local principal investigator (PI) from Genmab; institutional fees for the implementation of a clinical trial as coordinating PI from Servier; non-remunerated membership of the Scientific Committee for the European School of Haematology and the Clinical Advisory Committee for the WHO (T-cell lymphoma working group); and non-remunerated roles as project lead for the European Union's HARMONY Alliance (contact person of associated member institution Aarhus University Hospital), lead author of ESMO–EHA CPG for T-cell lymphomas, Chairman of the Nordic Lymphoma Group (NLG) T-cell lymphoma working group and PI for the RESILIENCE trial at Aarhus University Hospital.

M. F. reports no potential conflicts of interest.

L. D. L. reports institutional fees for advisory board membership from AbbVie, Blueprint Medicines, and Novartis; and institutional fees for expert testimony and travel support from Roche.

F. E. reports institutional fees for writing educational material from Roche Sweden; and a non-remunerated role as local PI for Celgene (observational study).

O. H. reports personal fees from AB Science (as consultant, co-founder, and for scientific support); personal stocks and shares from AB Science (co-founder); personal ownership interest in Inatherys (co-founder); institutional fees for advisory board membership from

25729241, 2025, 5, Downloaded from https://onlinelibrary.wiley.com/doi/10.1002/hem3.70128 by CochraneItalia, Wiley Online Library on [28/03/2026]. See the Terms and Conditions (https://onlinelibrary.wiley.com/terms-and-conditions) on Wiley Online Library for rules of use; OA articles are governed by the applicable Creative Commons License

Bristol Myers Squibb (BMS), Celgene and Novartis; and institutional funding from AbbVie, AB Science, Alexion, Blueprint, BMS, Celgene, Novartis, Roche, and Takeda.

W. S. K. reports personal and institutional fees as a coordinating PI from BeiGene, Boryong, Kyowa-Kirin, Roche, and Sanofi; and a non-remunerated advisory role for Celltrion (regular consulting).

F. L. reports personal fees for advisory board membership from BMS, Kiowa, and Miltenyi; personal fees as an invited speaker from AstraZeneca and Takeda; and personal travel grants from Gilead, Janssen, and Roche.

J. S. P. V. reports no potential conflicts of interest.

G. W. reports personal fees for advisory board membership from Clinigen, Novartis, and Takeda; personal fees as an invited speaker from Gilead and Takeda; an institutional role as local PI from Gilead, Janssen, Miltenyi, Novartis, Roche, and Verastem; non-remunerated speaker for the German Society of Hematology and Medical Oncology (DGHO); non-remunerated membership of the DGHO, Experimental Cancer Research (AEK), German Cancer Aid (DKH), and German Lymphoma Alliance (GLA); and has received product samples from Gilead and Roche.

C. B. reports personal fees for advisory board membership from AbbVie, BeiGene, Celltrion, Gilead Sciences, Incyte, Janssen, Lilly Deutschland GmbH, MorphoSys, Novartis, Pfizer, Regeneron, Roche, and Sobi; personal fees as an invited speaker from AbbVie, BeiGene, Celltrion, Gilead Sciences, Incyte, Janssen, Lilly Deutschland GmbH, MorphoSys, Novartis, Pfizer, Regeneron, Roche, and Sobi; and institutional funding from AbbVie, Amgen, Bayer, Celltrion, Janssen, MSD, Pfizer, and Roche (all for investigator-sponsored clinical trials and registries).

M. D. reports personal fees as an advisory board member from AbbVie, AstraZeneca, BeiGene, BMS/Celgene, Gilead, Janssen, Lilly/Loxo, Novartis, and Roche; personal fees as an invited speaker for AstraZeneca, BeiGene, Gilead/Kite, Janssen, Lilly, Novartis, and Roche; institutional research grants from AbbVie, Bayer, Celgene, Gilead/Kite, Janssen, Lilly, and Roche; and non-renumerated membership of the American Society of Clinical Oncology (ASCO), American Society of Hematology (ASH; subcommittee), DGHO (prior Board member), European Hematology Association (EHA; Executive Board), ESMO (Faculty), and the Lymphoma Research Foundation (Mantle Cell Lymphoma Consortium).

M. J. reports personal fees for advisory board membership from Genmab, Gilead, and Roche; personal fees as an invited speaker from AbbVie; institutional funding from AbbVie, AstraZeneca, Celgene, and Roche; an institutional role as coordinating PI from BioInvent; and non-remunerated membership of ASCO, ASH, and the EHA.

DATA AVAILABILITY STATEMENT

Data sharing is not applicable to this article as no new data were created or analyzed in this study.

FUNDING

No external funding has been received for the preparation of this guideline. Production costs have been covered by ESMO (for *Annals of Oncology*) and EHA (for *HemaSphere*) from central funds.

SUPPORTING INFORMATION

Additional supporting information can be found in the online version of this article.

REFERENCES

1. Campo E, Jaffe ES, Cook JR, et al. The International Consensus Classification of Mature Lymphoid Neoplasms: a report from the Clinical Advisory Committee. *Blood*. 2022;140(11):1229-1253.
2. Alaggio R, Amador C, Anagnostopoulos I, et al. The 5th edition of the World Health Organization Classification Of Haematolymphoid Tumours: Lymphoid Neoplasms. *Leukemia*. 2022;36(7):1720-1748.
3. Willemze R, Hodak E, Zinzani PL, Specht L, Ladetto M. Primary cutaneous lymphomas: ESMO Clinical Practice Guidelines for diagnosis, treatment and follow-up. *Ann Oncol*. 2018;29(suppl 4):iv30-iv40.
4. Ondrejka SL, Amador C, Climent F, et al. Follicular helper T-cell lymphomas: disease spectrum, relationship with clonal hematopoiesis, and mimics. A report of the 2022 EA4HP/SH lymphoma workshop. *Virchows Arch*. 2023;483(3):349-365.
5. Horwitz SM, Ansell S, Ai WZ, et al. T-cell lymphomas, version 2.2022, NCCN Clinical Practice Guidelines in oncology. *J Natl Compr Canc Netw*. 2022;20(3):285-308.
6. Laurent C, Baron M, Amara N, et al. Impact of expert pathologic review of lymphoma diagnosis: study of patients from the French lymphopath network. *J Clin Oncol*. 2017;35(18):2008-2017.
7. Syrykh C, Chaouat C, Poullot E, et al. Lymph node excisions provide more precise lymphoma diagnoses than core biopsies: a French Lymphopath network survey. *Blood*. 2022;140(24):2573-2583.
8. Gonçalves MC, de Oliveira CRGCM, Sandes AF, et al. Core needle biopsy in lymphoma diagnosis: the diagnostic performance and the role of the multidisciplinary approach in the optimization of results. *Am J Surg Pathol*. 2023;47(1):111-123.
9. de Leval L, Gaulard P, Dogan A. A practical approach to the modern diagnosis and classification of T- and NK-cell lymphomas. *Blood*. 2024;144(18):1855-1872.
10. de Leval L, Alizadeh AA, Bergsagel PL, et al. Genomic profiling for clinical decision making in lymphoid neoplasms. *Blood*. 2022;140(21):2193-2227.
11. Pro B, Allen P, Behdad A. Hepatosplenic T-cell lymphoma: a rare but challenging entity. *Blood*. 2020;136(18):2018-2026.
12. Attygalle AD, Zamò A, Fend F, Johnston P, Arber DA, Laurent C. Challenges and limitations in the primary diagnosis of T-cell and natural killer cell/T-cell lymphoma in bone marrow biopsy. *Histopathology*. 2020;77(1):2-17.
13. Mehta-Shah N, Ito K, Bantilan K, et al. Baseline and interim functional imaging with PET effectively risk stratifies patients with peripheral T-cell lymphoma. *Blood Adv*. 2019;3(2):187-197.
14. Abe Y, Kitadate A, Usui Y, et al. Diagnostic and prognostic value of using 18F-FDG PET/CT for the evaluation of bone marrow involvement in peripheral T-cell lymphoma. *Clin Nucl Med*. 2019;44(5):e336-e341.
15. Koh Y, Lee JM, Woo GU, et al. FDG PET for evaluation of bone marrow status in T-cell lymphoma. *Clin Nucl Med*. 2019;44(1):4-10.
16. Johanne M. Holst H, Trine L. Plesner P, Martin B. Pedersen P, et al. Myeloproliferative and lymphoproliferative malignancies occurring in the same patient: a nationwide discovery cohort. *Haematologica*. 2020;105(10):2432-2439.
17. Lewis NE, Petrova-Drus K, Huet S, et al. Clonal hematopoiesis in angioimmunoblastic T-cell lymphoma with divergent evolution to myeloid neoplasms. *Blood Adv*. 2020;4(10):2261-2271.
18. Schmitz N, Trümper L, Ziepert M, et al. Treatment and prognosis of mature T-cell and NK-cell lymphoma: an analysis of patients with T-cell lymphoma treated in studies of the German High-Grade Non-Hodgkin Lymphoma Study Group. *Blood*. 2010;116(18):3418-3425.
19. d'Amore F, Relander T, Lauritzsen GF, et al. Up-front autologous stem-cell transplantation in peripheral T-cell lymphoma: NLG-T-01. *J Clin Oncol*. 2012;30(25):3093-3099.
20. Cederleuf H, Bjerregård Pedersen M, Jerkeman M, Relander T, d'Amore F, Ellin F. The addition of etoposide to CHOP is associated with improved outcome in ALK+ adult anaplastic large cell lymphoma: a Nordic Lymphoma Group study. *Br J Haematol*. 2017;178(5):739-746.
21. Ellin F, Landström J, Jerkeman M, Relander T. Real-world data on prognostic factors and treatment in peripheral T-cell lymphomas: a study from the Swedish Lymphoma Registry. *Blood*. 2014;124(10):1570-1577.

25729241, 2025, 5, Downloaded from https://onlinelibrary.wiley.com/doi/10.1002/hem3.70128 by CochraneItalia, Wiley Online Library on [28/03/2026]. See the Terms and Conditions (https://onlinelibrary.wiley.com/terms-and-conditions) on Wiley Online Library for rules of use; OA articles are governed by the applicable Creative Commons License

22. Brink M, Meeuwes FO, van der Poel MWM, et al. Impact of etoposide and ASCT on survival among patients aged <65 years with stage II to IV PTCL: a population-based cohort study. *Blood*. 2022;140(9):1009-1019.
23. Horwitz S, O'Connor OA, Pro B, et al. Brentuximab vedotin with chemotherapy for CD30-positive peripheral T-cell lymphoma (ECHELON-2): a global, double-blind, randomised, phase 3 trial. *Lancet*. 2019;393(10168):229-240.
24. Advani RH, Ansell SM, Lechowicz MJ, et al. A phase II study of cyclophosphamide, etoposide, vincristine and prednisone (CEOP) alternating with Pralatrexate (P) as front line therapy for patients with peripheral T-cell lymphoma (PTCL): final results from the T-cell consortium trial. *Br J Haematol*. 2016;172(4):535-544.
25. Wulf GG, Altmann B, Ziepert M, et al. Alemtuzumab plus CHOP versus CHOP in elderly patients with peripheral T-cell lymphoma: the DSHNHL2006-1B/ACT-2 trial. *Leukemia*. 2021;35(1):143-155.
26. Bachy E, Camus V, Thieblemont C, et al. Romidepsin plus CHOP versus CHOP in patients with previously untreated peripheral T-Cell lymphoma: results of the Ro-CHOP phase III study (conducted by LYSA). *J Clin Oncol*. 2022;40(3):242-251.
27. Camus V, Thieblemont C, Gaulard P, et al. Romidepsin plus cyclophosphamide, doxorubicin, vincristine, and prednisone versus cyclophosphamide, doxorubicin, vincristine, and prednisone in patients with previously untreated peripheral T-cell lymphoma: final analysis of the Ro-CHOP trial. *J Clin Oncol*. 2024;42(14):1612-1618.
28. Ruan J, Moskowitz A, Mehta-Shah N, et al. Multicenter phase 2 study of oral azacitidine (CC-486) plus CHOP as initial treatment for PTCL. *Blood*. 2023;141(18):2194-2205.
29. Reimer P, Rüdiger T, Geissinger E, et al. Autologous stem-cell transplantation as first-line therapy in peripheral T-cell lymphomas: results of a prospective multicenter study. *J Clin Oncol*. 2009;27(1):106-113.
30. García-Sancho AM, Bellei M, López-Parra M, et al. Autologous stem-cell transplantation as consolidation of first-line chemotherapy in patients with peripheral T-cell lymphoma: a multicenter GELTAMO/FIL study. *Haematologica*. 2022;107(11):2675-2684.
31. Baek DW, Moon JH, Lee JH, et al. Real-world data of long-term survival in patients with T-cell lymphoma who underwent stem cell transplantation. *Blood Cancer J*. 2023;13(1):95.
32. Fossard G, Broussais F, Coelho I, et al. Role of up-front autologous stem-cell transplantation in peripheral T-cell lymphoma for patients in response after induction: an analysis of patients from LYSA centers. *Ann Oncol*. 2018;29(3):715-723.
33. Schmitz N, Truemper L, Bouabdallah K, et al. A randomized phase 3 trial of autologous vs allogeneic transplantation as part of first-line therapy in poor-risk peripheral T-NHL. *Blood*. 2021;137(19):2646-2656.
34. Ludvigsen Al-Mashhadi A, Cederleuf H, Kuhr Jensen R, et al. Outcome of limited-stage peripheral T-Cell lymphoma after CHOP(-like) therapy: a population based study of 239 patients from the Nordic lymphoma epidemiology group. *Am J Hematol*. 2023;98(3):388-397.
35. Chen Z, Huang H, Li X, et al. Chemotherapy plus radiotherapy versus chemotherapy alone for patients with peripheral T-cell lymphoma, not otherwise specified. *Front Oncol*. 2021;11:607145.
36. Meeuwes FO, Brink M, Plattel W, et al. Outcome of combined modality treatment in first-line for stage I(E) peripheral T-cell lymphoma: a nationwide population-based cohort study from the Netherlands. *Haematologica*. 2024;109(4):1163-1170.
37. Zhang XM, Li YX, Wang WH, et al. Favorable outcome with doxorubicin-based chemotherapy and radiotherapy for adult patients with early stage primary systemic anaplastic large-cell lymphoma. *Eur J Haematol*. 2013;90(3):195-201.
38. Horwitz S, O'Connor OA, Pro B, et al. The ECHELON-2 Trial: 5-year results of a randomized, phase III study of brentuximab vedotin with chemotherapy for CD30-positive peripheral T-cell lymphoma. *Ann Oncol*. 2022;33(3):288-298.
39. Sibon D, Nguyen DP, Schmitz N, et al. ALK-positive anaplastic large-cell lymphoma in adults: an individual patient data pooled analysis of 263 patients. *Haematologica*. 2019;104(12):e562-e565.
40. Herrera AF, Zain J, Savage KJ, et al. Brentuximab vedotin plus cyclophosphamide, doxorubicin, etoposide, and prednisone followed by brentuximab vedotin consolidation in CD30-positive peripheral T-cell lymphomas: a multicentre, single-arm, phase 2 study. *Lancet Haematol*. 2024;11(9):e671-e681.
41. Savage KJ, Horwitz SM, Advani R, et al. Role of stem cell transplant in CD30+ PTCL following frontline brentuximab vedotin plus CHP or CHOP in ECHELON-2. *Blood Adv*. 2022;6(19):5550-5555.
42. Turton P, El-Sharkawi D, Lyburn I, et al. UK guidelines on the diagnosis and treatment of breast implant-associated anaplastic large cell lymphoma on behalf of the Medicines and Healthcare products Regulatory Agency Plastic, Reconstructive and Aesthetic Surgery Expert Advisory Group. *Br J Haematol*. 2021;192(3):444-458.
43. Clemens MW, Medeiros LJ, Butler CE, et al. Complete surgical excision is essential for the management of patients with breast implant-associated anaplastic large-cell lymphoma. *J Clin Oncol*. 2016;34(2):160-168.
44. Lee Y, Song SE, Yoon ES, Bae JW, Jung SP. Extensive silicone lymphadenopathy after breast implant insertion mimicking malignant lymphadenopathy. *Ann Surg Treat Res*. 2017;93(6):331-335.
45. Bautista-Quach MA, Nademanee A, Weisenburger DD, Chen W, Kim YS. Implant-associated primary anaplastic large-cell lymphoma with simultaneous involvement of bilateral breast capsules. *Clin Breast Cancer*. 2013;13(6):492-495.
46. Miranda RN, Aladily TN, Prince HM, et al. Breast implant-associated anaplastic large-cell lymphoma: long-term follow-up of 60 patients. *J Clin Oncol*. 2014;32(2):114-120.
47. Klebaner D, Koura D, Tzachanis D, Ball ED, Horwitz S, Goodman AM. Intensive induction therapy compared with CHOP for hepatosplenic T-cell lymphoma. *Clin Lymphoma Myeloma Leuk*. 2020;20(7):431-437.e2.
48. Ravandi F, Aribi A, O'Brien S, et al. Phase II study of alemtuzumab in combination with pentostatin in patients with T-cell neoplasms. *J Clin Oncol*. 2009;27(32):5425-5430.
49. Tanase A, Schmitz N, Stein H, et al. Allogeneic and autologous stem cell transplantation for hepatosplenic T-cell lymphoma: a retrospective study of the EBMT Lymphoma Working Party. *Leukemia*. 2015;29(3):686-688.
50. Cho MW, Chin BB. 18F-FDG PET/CT findings in hepatosplenic Gamma-Delta T-cell lymphoma: case reports and review of the literature. *Am J Nucl Med Mol Imaging*. 2018;8(2):137-142.
51. Kwong YL, Anderson BO, Advani R, Kim WS, Levine AM, Lim ST. Management of T-cell and natural-killer-cell neoplasms in Asia: consensus statement from the Asian Oncology Summit 2009. *Lancet Oncol*. 2009;10(11):1093-1101.
52. Huang M, Jiang Y, Liu W, et al. Early or up-front radiotherapy improved survival of localized extranodal NK/T-cell lymphoma, nasal-type in the upper aerodigestive tract. *Int J Radiat Oncol Biol Phys*. 2008;70(1):166-174.
53. Yamaguchi M, Tobinai K, Oguchi M, et al. Concurrent chemoradiotherapy for localized nasal natural killer/T-cell lymphoma: an updated analysis of the Japan clinical oncology group study JCOG0211. *J Clin Oncol*. 2012;30(32):4044-4046.
54. Kwong YL, Kim SJ, Tse E, et al. Sequential chemotherapy/radiotherapy was comparable with concurrent chemoradiotherapy for stage I/II NK/T-cell lymphoma. *Ann Oncol*. 2018;29(1):256-263.
55. Bi XW, Li YX, Fang H, et al. High-dose and extended-field intensity modulated radiation therapy for early-stage NK/T-cell lymphoma of Waldeyer's ring: dosimetric analysis and clinical outcome. *Int J Radiat Oncol Biol Phys*. 2013;87(5):1086-1093.
56. Liu W, Wang H, Peng X, et al. Asparagine synthetase expression is associated with the sensitivity to asparaginase in extranodal natural

25729241, 2025, 5, Downloaded from https://onlinelibrary.wiley.com/doi/10.1002/hem3.70128 by CochraneItalia, Wiley Online Library on [28/03/2026]. See the Terms and Conditions (https://onlinelibrary.wiley.com/terms-and-conditions) on Wiley Online Library for rules of use; OA articles are governed by the applicable Creative Commons License

killer/T-cell lymphoma in vivo and in vitro. *Onco Targets Ther*. 2018;11:6605-6615.
57. Kwong YL, Kim WS, Lim ST, et al. SMILE for natural killer/T-cell lymphoma: analysis of safety and efficacy from the Asia Lymphoma Study Group. *Blood*. 2012;120(15):2973-2980.
58. Li X, Cui Y, Sun Z, et al. DDGP versus SMILE in newly diagnosed advanced natural killer/T-cell lymphoma: a randomized controlled, multicenter, open-label study in China. *Clin Cancer Res*. 2016;22(21): 5223-5228.
59. Jaccard A, Gachard N, Marin B, et al. Efficacy of L-asparaginase with methotrexate and dexamethasone (AspaMetDex regimen) in patients with refractory or relapsing extranodal NK/T-cell lymphoma, a phase 2 study. *Blood*. 2011;117(6):1834-1839.
60. Wei W, Wu P, Li L, Zhang Z. Effectiveness of pegaspargase, gemcitabine, and oxaliplatin (P-GEMOX) chemotherapy combined with radiotherapy in newly diagnosed, stage IE to IIE, nasal-type, extranodal natural killer/T-cell lymphoma. *Hematology*. 2017;22(6):320-329.
61. Tian XP, Cai J, Xia Y, et al. First-line sintilimab with pegaspargase, gemcitabine, and oxaliplatin in advanced extranodal natural killer/T cell lymphoma (SPIRIT): a multicentre, single-arm, phase 2 trial. *Lancet Haematol*. 2024;11(5):e336-e344.
62. Fox CP, Boumendil A, Schmitz N, et al. High-dose therapy and autologous stem cell transplantation for extra-nodal NK/T lymphoma in patients from the Western hemisphere: a study from the European Society for Blood and Marrow Transplantation. *Leuk Lymphoma*. 2015;56(12):3295-3300.
63. Kanate AS, DiGilio A, Ahn KW, et al. Allogeneic haematopoietic cell transplantation for extranodal natural killer/T-cell lymphoma, nasal type: a CIBMTR analysis. *Br J Haematol*. 2018;182(6):916-920.
64. Philippe Walter L, Couronné L, Jais JP, et al. Outcome after hematopoietic stem cell transplantation in patients with extranodal natural killer/T-Cell lymphoma, nasal type: a French study from the Société Francophone de Greffe de Moelle et de Thérapie Cellulaire (SFGM-TC). *Am J Hematol*. 2021;96(7):834-845.
65. Sieniawski M, Angamuthu N, Boyd K, et al. Evaluation of enteropathy-associated T-cell lymphoma comparing standard therapies with a novel regimen including autologous stem cell transplantation. *Blood*. 2010;115(18):3664-3670.
66. Sibon D, Khater S, Bruneau J, et al. The Eatl-001 trial: results of a phase 2 study of brentuximab vedotin and CHP followed by consolidation with high-dose therapy - autologous stem-cell transplantation (HDT-ASCT) in the frontline treatment of patients with enteropathy-associated T-cell lymphoma. *Blood*. 2021;138(suppl 1):136.
67. Staber PB, Herling M, Bellido M, et al. Consensus criteria for diagnosis, staging, and treatment response assessment of T-cell prolymphocytic leukemia. *Blood*. 2019;134(14):1132-1143.
68. Dearden CE, Matutes E, Cazin B, et al. High remission rate in T-cell prolymphocytic leukemia with CAMPATH-1H. *Blood*. 2001;98(6): 1721-1726.
69. Dearden CE, Khot A, Else M, et al. Alemtuzumab therapy in T-cell prolymphocytic leukemia: comparing efficacy in a series treated intravenously and a study piloting the subcutaneous route. *Blood*. 2011;118(22):5799-5802.
70. Hamidou MA, Bani Sadr F, Lamy T, Raffi F, Grolleau JY, Barrier JH. Low-dose methotrexate for the treatment of patients with large granular lymphocyte leukemia associated with rheumatoid arthritis. *Am J Med*. 2000;108(9):730-732.
71. Moignet A, Hasanali Z, Zambello R, et al. Cyclophosphamide as a first-line therapy in LGL leukemia. *Leukemia*. 2014;28(5):1134-1136.
72. Pawarode A, Wallace PK, Ford LA, Barcos M, Baer MR. Long-term safety and efficacy of cyclosporin A therapy for T-cell large granular lymphocyte leukemia. *Leuk Lymphoma*. 2010;51(2):338-341.
73. Mak V, Hamm J, Chhanabhai M, et al. Survival of patients with peripheral T-cell lymphoma after first relapse or progression: spectrum of disease and rare long-term survivors. *J Clin Oncol*. 2013;31(16):1970-1976.
74. Pro B, Advani R, Brice P, et al. Five-year results of brentuximab vedotin in patients with relapsed or refractory systemic anaplastic large cell lymphoma. *Blood*. 2017;130(25):2709-2717.
75. Brink M, Huisman F, Meeuwes FO, et al. Treatment strategies and outcome in relapsed peripheral T-cell lymphoma: results from the Netherlands Cancer Registry. *Blood Adv*. 2024;8(14):3619-3628.
76. Coiffier B, Pro B, Prince HM, et al. Results from a pivotal, open-label, phase II study of romidepsin in relapsed or refractory peripheral T-cell lymphoma after prior systemic therapy. *J Clin Oncol*. 2012;30(6): 631-636.
77. O'Connor OA, Horwitz S, Masszi T, et al. Belinostat in patients with relapsed or refractory peripheral T-cell lymphoma: results of the pivotal phase II BELIEF (CLN-19) study. *J Clin Oncol*. 2015;33(23):2492-2499.
78. O'Connor OA, Pro B, Pinter-Brown L, et al. Pralatrexate in patients with relapsed or refractory peripheral T-cell lymphoma: results from the pivotal PROPEL study. *J Clin Oncol*. 2011;29(9):1182-1189.
79. Horwitz SM, Koch R, Porcu P, et al. Activity of the PI3K-δ,γ inhibitor duvelisib in a phase 1 trial and preclinical models of T-cell lymphoma. *Blood*. 2018;131(8):888-898.
80. Damaj G, Gressin R, Bouabdallah K, et al. Results from a prospective, open-label, phase II trial of bendamustine in refractory or relapsed T-cell lymphomas: the BENTLY trial. *J Clin Oncol*. 2013;31(1):104-110.
81. Advani R, Horwitz S, Zelenetz A, Horning SJ. Angioimmunoblastic T cell lymphoma: treatment experience with cyclosporine. *Leuk Lymphoma*. 2007;48(3):521-525.
82. Morschhauser F, Fitoussi O, Haioun C, et al. A phase 2, multicentre, single-arm, open-label study to evaluate the safety and efficacy of single-agent lenalidomide (Revlimid) in subjects with relapsed or refractory peripheral T-cell non-Hodgkin lymphoma: the EXPECT trial. *Eur J Cancer*. 2013;49(13):2869-2876.
83. Lemonnier F, Dupuis J, Sujobert P, et al. Treatment with 5-azacytidine induces a sustained response in patients with angioimmunoblastic T-cell lymphoma. *Blood*. 2018;132(21):2305-2309.
84. Dupuis J, Bachy E, Morschhauser F, et al. Oral azacitidine compared with standard therapy in patients with relapsed or refractory follicular helper T-cell lymphoma (ORACLE): an open-label randomised, phase 3 study. *The Lancet Haematology*. 2024;11(6):e406-e414.
85. Mamez AC, Dupont A, Blaise D, et al. Allogeneic stem cell transplantation for peripheral T cell lymphomas: a retrospective study in 285 patients from the Société Francophone de Greffe de Moelle et de Thérapie Cellulaire (SFGM-TC). *J Hematol Oncol*. 2020;13(1):56.
86. Savani M, Ahn KW, Chen Y, et al. Impact of conditioning regimen intensity on the outcomes of peripheral T-cell lymphoma, anaplastic large cell lymphoma and angioimmunoblastic T-cell lymphoma patients undergoing allogeneic transplant. *Br J Haematol*. 2022;197(2): 212-222.
87. Hamadani M, Ngoya M, Sureda A, et al. Outcome of allogeneic transplantation for mature T-cell lymphomas: impact of donor source and disease characteristics. *Blood Adv*. 2022;6(3):920-930.
88. Horwitz SM, Advani RH, Bartlett NL, et al. Objective responses in relapsed T-cell lymphomas with single-agent brentuximab vedotin. *Blood*. 2014;123(20):3095-3100.
89. Bartlett NL, Chen R, Fanale MA, et al. Retreatment with brentuximab vedotin in patients with CD30-positive hematologic malignancies. *J Hematol Oncol*. 2014;7:24.
90. Bossi E, Aroldi A, Brioschi FA, et al. Phase two study of crizotinib in patients with anaplastic lymphoma kinase (ALK)-positive anaplastic large cell lymphoma relapsed/refractory to chemotherapy. *Am J Hematol*. 2020;95(12):E319-E321.
91. Fukano R, Mori T, Sekimizu M, et al. Alectinib for relapsed or refractory anaplastic lymphoma kinase-positive anaplastic large cell lymphoma: an open-label phase II trial. *Cancer Sci*. 2020;111(12): 4540-4547.
92. Fischer M, Moreno L, Ziegler DS, et al. Ceritinib in paediatric patients with anaplastic lymphoma kinase-positive malignancies: an open-

25729241, 2025, 5, Downloaded from https://onlinelibrary.wiley.com/doi/10.1002/hem3.70128 by CochraneItalia, Wiley Online Library on [28/03/2026]. See the Terms and Conditions (https://onlinelibrary.wiley.com/terms-and-conditions) on Wiley Online Library for rules of use; OA articles are governed by the applicable Creative Commons License

label, multicentre, phase 1, dose-escalation and dose-expansion study. *Lancet Oncol*. 2021;22(12):1764-1776.

93. Knörr F, Brugières L, Pillon M, et al. Stem cell transplantation and vinblastine monotherapy for relapsed pediatric anaplastic large cell lymphoma: results of the international, prospective ALCL-relapse trial. *J Clin Oncol*. 2020;38(34):3999-4009.
94. Kwong YL, Chan TSY, Tan D, et al. PD1 blockade with pembrolizumab is highly effective in relapsed or refractory NK/T-cell lymphoma failing l-asparaginase. *Blood*. 2017;129(17):2437-2442.
95. Chan TSY, Li J, Loong F, Khong PL, Tse E, Kwong YL. PD1 blockade with low-dose nivolumab in NK/T cell lymphoma failing L-asparaginase: efficacy and safety. *Ann Hematol*. 2018;97(1):193-196.
96. Kim HK, Moon SM, Moon JH, Park JE, Byeon S, Kim WS. Complete remission in CD30-positive refractory extranodal NK/T-cell lymphoma with brentuximab vedotin. *Blood Res*. 2015;50(4):254-256.
97. Dumitriu B, Ito S, Feng X, et al. Alemtuzumab in T-cell large granular lymphocytic leukaemia: interim results from a single-arm, open-label, phase 2 study. *Lancet Haematol*. 2016;3(1):e22-e29.
98. Marchand T, Pastoret C, Damaj G, et al. Efficacy of ruxolitinib in the treatment of relapsed/refractory large granular lymphocytic leukaemia. *Br J Haematol*. 2024;205(3):915-923.
99. Moskowitz AJ, Ghione P, Jacobsen E, et al. A phase 2 biomarker-driven study of ruxolitinib demonstrates effectiveness of JAK/STAT targeting in T-cell lymphomas. *Blood*. 2021;138(26):2828-2837.

25729241, 2025, 5, Downloaded from https://onlinelibrary.wiley.com/doi/10.1002/hem3.70128 by CochraneItalia, Wiley Online Library on [28/03/2026]. See the Terms and Conditions (https://onlinelibrary.wiley.com/terms-and-conditions) on Wiley Online Library for rules of use; OA articles are governed by the applicable Creative Commons License