Check for updates

European Journal of Neurology 2002, **9:** 207–219

EFNS TASK FORCE

EFNS guideline on mild traumatic brain injury: report of an EFNS task force

P. E. Vos[a], L. Battistin[b], G. Birbamer[c], F. Gerstenbrand[c], A. Potapov[d], T. Prevec[e], Ch. A. Stepan[f], P. Traubner[g], A. Twijnstra[h], L. Vecsei[i] and K. von Wild[j]

[a]*Department of Neurology, University Medical Centre Nijmegen, Nijmegen, The Netherlands;* [b]*Clinica Neurologica I, Padova, Italy;* [c]*Ludwig Boltzmann Institute for Restorative Neurology and Neuromodulation, Vienna, Austria;* [d]*Institute of Neurosurgery, Russian Academy of Medical Sciences, Moscow, Russia;* [e]*University Institute of Clinical Neurophysiology, University Medical Centre, Ljubljana, Slovenia;* [f]*Neurological Hospital Rosenhügel, Vienna, Austria;* [g]*Department of Neurology, Comenius University School of Medicine, Bratislava, Slovak Republic;* [h]*Department of Neurology, University Medical Centre Maastricht, Maastricht, The Netherlands;* [i]*Department of Neurology, Szent-Györgyi University Hospital, Szeged, Hungary; and* [j]*Neurochirurgische Klinik, Clemens Hospital, Münster, Germany*

Keywords:
clinical decision rule, computed tomography, guideline, head injury, intracranial complication, mild traumatic brain injury, risk factors

In 1999, a Task Force on Mild Traumatic Brain Injury (MTBI) was set up under the auspices of the European Federation of Neurological Societies. Its aim was to propose an acceptable uniform nomenclature for MTBI and definition of MTBI, and to develop a set of rules to guide initial management with respect to ancillary investigations, hospital admission, observation and follow-up.

Received 21 February 2002
Accepted 21 February 2002

Introduction

That trauma of the head can cause brain injury has long been recognized. Indeed, the term commotio cerebri was used already in the sixteenth century by Ambroise Pare (cf. Denny-Brown and Russell, 1941; Frowein and Firsching, 1990). Trauma of the head is a common cause of morbidity and mortality in European countries. The incidence of traumatic brain injury (TBI) varies between 229 and 1967 per 100 000, with the highest incidence occurring in men aged 15–24 years (Jennett, 1996; Kraus *et al*., 1996). TBI is the leading cause of death among people younger than 45 years (Jennett, 1996; Kraus *et al*., 1996).

Usually, TBI is classified as mild, moderate or severe (Table 1). There is general agreement that in mild traumatic brain injury (MTBI) patients have a hospital admission Glasgow Coma Score (GCS) of 13–15 (Teasdale and Jennett, 1974; Williams *et al*., 1990; Gomez *et al*., 1996; Haydel *et al*., 2000; Stiell *et al*., 2001). In moderate TBI, patients have an admission GCS of 9–12, and in severe TBI an admission GCS of 8 or less after resuscitation (Table 1) (Bullock *et al*., 1996). A fourth (critical) grade refers to the severest form of TBI, in which there is evidence of brain stem damage (with acute midbrain or bulbar syndrome), with diminished or no pupillary reactions and decerebrate motor posturing, or absent pupillary and motor reactions. The outcome is almost invariably poor (death or a vegetative state/traumatic apallic syndrome) (Table 1) (Gerstenbrand and Lucking, 1970; Frowein and Firsching, 1990; Stein and Spettell, 1995).

More than 95% of all TBIs are considered mild, with moderate and severe TBI together accounting for only 5% of cases (Meerhoff *et al*., 2000). Mortality in MTBI is low (between 0.04 and 0.29%) and almost exclusively caused by intracranial haemorrhage (Klauber *et al*., 1989). Intracranial haemorrhage (extradural or subdural) that often requires neurosurgical intervention occurs in 0.2–3.1% of all MTBI patients and between 6.3 and 21% have other intracranial complications [computed tomography (CT) abnormalities] (Shackford *et al*., 1992; Stein and Ross, 1992; Borczuk, 1995; Culotta *et al*., 1996; Dunham *et al*., 1996; Hsiang *et al*., 1997; Haydel *et al*., 2000; Stiell *et al*., 2001).

Early recognition of symptoms and signs known to increase the risk of development of an intracranial haemorrhage is the key issue of initial management (Haydel *et al*., 2000; Stiell *et al*., 2001).

Search strategy

The Task Force systematically searched the English literature in the MEDLINE database (1966–2001) using the keywords minor head injury, mild head injury, mild traumatic brain injury, traumatic brain injury and management. Additional articles were identified from the bibliographies of the articles retrieved (including also the German language) and from textbooks. Articles were included if they contained data on at least one

Correspondence: Dr Pieter E. Vos, University Medical Centre Nijmegen, PO Box 9101, 6500 HB, Nijmegen, The Netherlands (fax: + 31 24 354 1122; e-mail: p.vos@czzoneu.azn.nl).

© 2002 EFNS

Table 1 Classification of traumatic brain injury

Classification	Admission Glasgow Coma Scale Score (GCS) and clinical characteristics modified from the Dutch, Scandinavian and American classification systems (Teasdale and Jennett, 1974; Stein and Spettell, 1995; Maas *et al.*, 1997; Ingebrigtsen *et al.*, 2000; Twijnstra *et al.*, 2001)
Mild	GCS = 13–15
Category 0	GCS = 15
	No LOC, no PTA, = head injury, no TBI
	No risk factors
Category 1	GCS = 15
	LOC < 30 min, PTA < 1 h
	No risk factors
Category 2	GCS = 15 and risk factors present*
Category 3	GCS = 13–14
	LOC < 30 min, PTA < 1 h
	With or without risk factors present*
Moderate	GCS = 9–12
Severe	GCS ≤ 8
Critical	GCS = 3–4, with loss of pupillary reactions and absent or decerebrate motor reactions

TBI, traumatic brain injury; GCS, Glasgow Coma Scale; LOC, loss of consciousness; PTA, post-traumatic amnesia. *Risk factors are shown in Table 2.

of the following: patients classified according to known classification systems (i.e. admission GCS 13–15), outcome data (CT abnormalities, need for neurosurgical intervention, mortality) or management. Articles judged to be of historical value were also included. For the purpose of this report a total of 125 papers were finally included. Additional information can be found on the European Federation of Neurological Societies (EFNS) website. Where appropriate, a classification of evidence level (EL) was given for interventions, diagnostic tests and grades of recommendation for management according to the neurological management guidelines of the EFNS (Hughes *et al.*, 2001).

Mechanisms of traumatic brain injury

Traumatic brain injury is usually the consequence of impact to the head, during which energy (impulse) is transmitted to the head, which undergoes sudden acceleration, deceleration or rotation. Head trauma can be closed, blunt, if the skull remains intact, or penetrating if the skull and (often) the dura are penetrated by sharp objects (including gunshot, knives, screwdrivers, arrows, darts) (Bayston *et al.*, 2000).

Focal damage, or contact injuries, such as skull fracture, extradural haematoma, contusion-related subdural haematoma, cortical contusion, are produced by direct collisional forces acting on the skull, resulting in compression of underlying tissue (coup) or of tissue remote from the site of the impact (contre coup) (Pudenz and Shelden, 1946; Sellier and Unterharnscheidt, 1963).

Impact to the head *per se* is not mandatory to evoke brain dysfunction or brain damage. Except for skull fracture and extradural haematoma, all types of brain injury can be produced by (angular) acceleration of the head without impact, provided there is a period of loss of consciousness (LOC) (Gennarelli *et al.*, 1982). Thus, shear forces generated in the brain upon sudden rotation may cause damage to axons and blood vessels (Houlbourn, 1943; Gennarelli, 1983; Grcevic, 1988; Gerstenbrand and Stepan, 2001). Controversy exists on whether diffuse brain dysfunction can occur in MTBI without there being structural damage. Spatz and others defined commotio cerebri as a functional disturbance without any damage to brain tissue ('traceless disturbances') (Trotter, 1924; Spatz, 1936). This has considerable consequences for the terminology used and is a frequent source of problems in forensic and insurance issues after TBI.

Brain damage after head injury can also be classified by its time course (Teasdale, 1995; Maas *et al.*, 1997). Primary damage occurs at the moment of impact and is thought to be irreversible. Secondary brain damage evolves in hours or days after the injury as a consequence of systemic (predominantly hypoxia and hypotension) or intracranial complications (brain oedema, tentorial or foraminal herniation). Tertiary complications (sepsis, thromboembolic complications, critical illness polyneuropathy) may occur days or weeks after the trauma as a result of an altered catabolic state or increased thrombosis because of bed rest, paralysis or infection (Gerstenbrand, 1977).

Classification of MTBI

Many different terms exist to describe and define MTBI (Frowein and Firsching, 1990; Williams *et al.*, 1990;

14681331, 2002, 3, Downloaded from https://onlinelibrary.wiley.com/doi/10.1046/j.1468-1331.2002.00407.x by CochraneItalia, Wiley Online Library on [28/03/2026]. See the Terms and Conditions (https://onlinelibrary.wiley.com/terms-and-conditions) on Wiley Online Library for rules of use; OA articles are governed by the applicable Creative Commons License

Evans, 1992; Pople *et al*., 1993; Birbamer *et al*., 1994; Stein and Spettell, 1995; Teasdale, 1995; Culotta *et al*., 1996; Gomez *et al*., 1996; Saab *et al*., 1996; Arienta *et al*., 1997; Ingebrigtsen *et al*., 2000 Gerstenbrand and Stepan, 2001; von Wild and Terwey, 2001). Here, a classification is proposed based on admission GCS, trauma history [i.e. the duration of LOC and post-traumatic amnesia (PTA)], neurological findings and risk factors for intracranial complications. Several subclassifications have been proposed to facilitate initial management decisions (Grade B, recommendation) (Table 1, and Fig. 1 later).

Recommendation: MTBI is defined as the consequence of blunt (non-penetrating) impact with sudden acceleration, deceleration or rotation of the head with a GCS score of 13–15 on admission to hospital. If the duration of LOC is maximally 30 min and PTA is less than 60 min, the outcome is considered good (mortality $<1\%$), especially in the absence of risk factors (mortality approaching 0) (Grade B, recommendation) (Table 1).

Admission GCS

Accurate determination of the admission GCS is important because the number of intracranial abnormalities and the need for neurosurgical interventions are inversely related to the admission GCS (Culotta *et al*., 1996; Gomez *et al*., 1996). The time between the accident and hospital admission can influence the GCS. Recent studies used 24 h as the maximum delay for hospital admission, but this delay is often not mentioned (Jennett, 1996; Haydel *et al*., 2000; Stiell *et al*., 2001). The GCS is also the most frequently used scoring tool in children; however, it is less appropriate for very young children whose motor and verbal skills are not yet fully developed, and for this reason alternative scales have been developed (Simpson *et al*., 1991; Durham *et al*., 2000). The Paediatric Glasgow Coma Scale uses age-adjusted maximal scores but is based on a 14-point GCS instead of the 15-point GCS (Reilly *et al*., 1988).

Duration of loss of consciousness

Verification of whether LOC has occurred and accurate assessment of the duration of LOC are essential because LOC increases the risk of skull fracture and intracranial complications (EL = Class III) (Teasdale *et al*., 1990; Stein and Spettell, 1995; Gomez *et al*., 1996).

There is little agreement on how long LOC should last for the trauma to be defined as MTBI. Times of 5, 10, 15–20, or 30 min have been reported (Rimel *et al*., 1981; Williams *et al*., 1990; Evans, 1992; Hahn and McLone, 1993; Gomez *et al*., 1996; Jennett, 1996; Haydel *et al*., 2000; Ingebrigtsen *et al*., 2000). Likewise, there is no uniform duration of coma to define MTBI, and thus any limit set is necessarily arbitrary. The aim of the Task Force is to align these guidelines with other international classifications (e.g. Mild Traumatic Brain Injury Committee of the American Congress of Rehabilitation Medicine, 1993). There are studies showing that outcome is not adversely affected by a short period of LOC. In children, a 100% good outcome was found if LOC was less than 15 min (Hahn and McLone, 1993) (EL = II). In another study, the number of post-traumatic subjective complaints, neurocognitive performance and pre-existing emotional risk factors did not correlate with the duration of LOC after MTBI (EL = II) (Ruff and Jurica, 1999). Jennett (1996) stated that a duration of altered consciousness of less than 15–30 min could be considered as mild (EL = IV).

PTA

Post-traumatic (or anterograde) amnesia is the period of inability to lay down continuous memories (amnesic for ongoing events) and is often characterized by confusion (Levin *et al*., 1979; Tate *et al*., 2000). A distinction is usually made between disorientation and amnesia because the two do not always disappear at the same time (Tate *et al*., 2000). The outcome of MTBI and return to work are determined more by the duration of PTA than by the admission GCS (EL = III) III) (van der Naalt *et al*., 1999a). If the PTA is shorter than 24 h, a good outcome (as measured with the Glasgow Outcome Scale) is found in 100% of patients (EL = II) (van der Naalt *et al*., 1999a). Retrograde amnesia is the loss of memory for the period before the accident.

Recommendation: Post-traumatic amnesia shorter than 1 h and/or a retrograde amnesia shorter than 30 min are compatible with MTBI and are associated with a good outcome (Grade B, recommendation).

Risk factors

Several symptoms, signs and risk factors associated with an increased risk of intracranial injury have been identified (EL = II–III) (see Table 2 for overview) (Masters *et al*., 1987; Chan *et al*., 1990; Arienta *et al*., 1997; Haydel *et al*., 2000).

Recommendation: Recognition of risk factors is important and such factors should be included in a classification system to further assess the risk of immediate complications (extracerebral haematoma) (Grade B, recommendation). Moreover, this may enable assessment of the risk for long-term complaints.

14681331, 2002, 3, Downloaded from https://onlinelibrary.wiley.com/doi/10.1046/j.1468-1331.2002.00407.x by CochraneItalia, Wiley Online Library on [28/03/2026]. See the Terms and Conditions (https://onlinelibrary.wiley.com/terms-and-conditions) on Wiley Online Library for rules of use; OA articles are governed by the applicable Creative Commons License

Table 2

Risk factors for intracranial complications after mild traumatic brain injury	References
Unclear or ambiguous accident history	Masters *et al.* (1987), Vos *et al.* (2000)
Continued post-traumatic amnesia*	Haydel *et al.* (2000), Stiell *et al.* (2001)
Retrograde amnesia longer than 30 min	Stiell *et al.* (2001)
Trauma above the clavicles including clinical signs of skull fracture (skull base or depressed skull fracture)	Feuerman *et al.* (1988), Haydel *et al.* (2000), Masters *et al.* (1987), Stiell *et al.* (2001), Teasdale *et al.* (1990)
Severe headache	Haydel *et al.* (2000)
Vomiting	Nee *et al.* (1999), Haydel *et al.* (2000), Stiell *et al.* (2001)
Focal neurological deficit	Masters *et al.* (1987), Teasdale *et al.* (1990)
Seizure	Masters *et al.* (1987)
Age < 2 years	Masters *et al.* (1987), Levin *et al.* (1992b)
Age > 60**	Gomez *et al.* (1996), Haydel *et al.* (2000), Stiell *et al.* (2001)
Coagulation disorders	Saab *et al.* (1996), Stein *et al.* (1992), Volans (1998)
High-energy accident***	American College of Surgeons (1997), Bartlett *et al.* (1998), Stiell *et al.* (2001)
Intoxication with alcohol/drugs	Cardoso and Galbraith (1985), Boyle *et al.* (1991), Kelly (1995)

*Continued post-traumatic amnesia may be interpreted as a GCS verbal reaction of 4 and hence may be defined as GCS < 15. **The Canadian CT head rule found age above 65 to be a risk factor (Stiell *et al.*, 2001). ***According to Advanced Trauma Life Support principles, a high-energy (vehicle) accident is defined as initial speed > 64 km/h, major auto-deformity, intrusion into passenger compartment > 30 cm, extrication time from vehicle > 20 min, falls > 6 m, roll over, auto–pedestrian accidents, or motor cycle crash > 32 km/h or with separation of rider and bike (American College of Surgeons Committee on Trauma, 1997; Bartlett *et al.*, 1998).

Complications

Intracranial abnormalities

The various cranial, extracerebral and intracerebral complications of (mild) TBI can be divided into abnormalities that (often) need neurosurgical intervention (extracerebral haematoma, depressed skull fracture, growing skull fracture) and those that cannot be treated neurosurgically (contusion zones, brain oedema, diffuse injury, small haemorrhages, traumatic subarachnoid haemorrhage, pneumocephalus) (Teasdale *et al.*, 1990; Lloyd *et al.*, 1997; Ingebrigtsen *et al.*, 2000). CT is very sensitive for the detection of extracerebral haematoma and other intracranial abnormalities, although no formal CT classification for MTBI exists, and the sensitivity and specificity and the interrater and intrarater variability of the various intracranial CT abnormalities are not known. The percentage of patients with intracranial abnormalities varies with the definitions used, the clinical inclusion criteria and the radiography method used (Stein and Spettell, 1995; Culotta *et al.*, 1996). Reported rates vary between 3 and 13% in patients with an admission GCS of 15 and between 25 and 37.5% in patients with an admission GCS of 13 (Stein and Ross, 1992; Culotta *et al.*, 1996; Dunham *et al.*, 1996; Stiell *et al.*, 2001).

Recommendation: The term intracranial complication includes all cranial, extracerebral, and intracerebral abnormalities in relation to head trauma that can be visualized on CT and that are likely to be the result of the head trauma (Grade C, recommendation).

This definition of intracranial complication affects short- and long-term management issues and makes it possible to relate short- and long-term complications to intracranial abnormalities present after MTBI. CT findings can also predict the absence of late disease progression. In a study in 2032 patients, no neurological deterioration occurred and no haematoma was found when the findings of CT performed within 24 h were normal (EL = Class II) (Dunham *et al.*, 1996).

Recommendation: MTBI may produce a variety of (intra)cranial abnormalities that can be divided into those that can be neurosurgically treated and those that cannot. CT is the gold standard for the detection of intracranial abnormalities and is a safe method for home triage (Livingston *et al.*, 1991; Dunham *et al.*, 1996) (Grade B, recommendation).

Neurosurgical intervention

The probability of neurosurgical intervention after MTBI is between 0.2 and 3.1%. Neurosurgical intervention is defined in different studies as craniotomy or craniectomy for haematoma evacuation or exploration, elevation of depressed skull fracture, intracranial pressure monitoring, intubation for head injury, aggressive medical treatment or not specified (Stein and Ross, 1992; Culotta *et al.*, 1996; Gomez *et al.*, 1996; Haydel *et al.*, 2000; Stiell *et al.*, 2001). An extradural, or epidural, haematoma is a collection of blood

14681331, 2002, 3, Downloaded from https://onlinelibrary.wiley.com/doi/10.1046/j.1468-1331.2002.00407.x by CochraneItalia, Wiley Online Library on [28/03/2026]. See the Terms and Conditions (https://onlinelibrary.wiley.com/terms-and-conditions) on Wiley Online Library for rules of use; OA articles are governed by the applicable Creative Commons License

between the dura and skull bone, often as a result of a ruptured meningeal middle artery in close relation to a temporal bone fracture or at other sites as a result of torn dural vessels or oozing from the skull bone (including the fossa posterior) (Frowein and Firsching, 1990). Although such haematomas are probably present from the moment of impact and visible on CT as collections of blood, there is often a delay (lucid interval) between the trauma and the moment the extradural haematoma enlarges and becomes symptomatic (usually within 6 h) (Knuckey *et al*., 1989; Smith and Miller, 1991). The lower the admission GCS, the higher the risk of an intracranial extracerebral haematoma (Teasdale *et al*., 1990; Stein and Spettell, 1995; Gomez *et al*., 1996). The frequency of extracerebral haematoma (extradural or subdural) has been estimated to range from 1 in 31 370 in fully conscious patients without a history of altered consciousness to 1 in 8 (12.7%) in patients with a hospital admission GCS of 13 (Teasdale *et al*., 1990; Culotta *et al*., 1996). In a meta-analysis of 10 studies in which at least 50% of the patients underwent CT, the weighted mean frequency of intracranial haemorrhage after MTBI was 0.083% [95% confidence interval (CI): 0.03–0.13%] (Hofman *et al*., 2000).

The mortality of MTBI, after systemic (multiple) injuries are excluded, is very low and almost exclusively caused by the late or missed diagnosis of deterioration in patients with an intracranial haemorrhage (specifically an extradural haematoma) (EL = II–III) (Mendelow *et al*., 1979; Klauber *et al*., 1989; Shackford *et al*., 1992; Culotta *et al*., 1996; Dunham *et al*., 1996; Gomez *et al*., 1996; Jennett, 1996; Servadei *et al*., 2001; Stiell *et al*., 2001). The prognosis of extradural haematoma is good, especially when it is detected early in fully conscious patients and surgery is performed as soon as possible (Paterniti *et al*., 1994; Servadei *et al*., 1995; Servadei, 1997). However, when rapid neurological deterioration occurs or when patients are already in coma, mortality rises sharply with the delay between deterioration and surgery (EL = III) (Mendelow *et al*., 1979; Seelig *et al*., 1984; Servadei, 1997).

The growing skull fracture has a very low frequency of 0.05–0.6%. It is most likely to occur in children younger than 6 years, when a dural tear beneath a skull fracture is present and systolic–diastolic pulsations result in widening of the fracture margins and interposition of leptomeninges or brain tissue into the fracture. It is mentioned here as a long-term complication that occurs if early diagnosis and intervention are deferred.

Recommendation: The extracerebral haemorrhage (extradural haematoma) that can be treated neurosurgically is potentially the most threatening complication after MTBI (Grade B, recommendation). An extradural haematoma can be easily identified with CT, which should be carried out urgently (Grade B, recommendation).

Recommendation: The primary goal of initial management in MTBI is to identify the patients at risk of intracranial abnormalities and especially those that may need neurosurgical intervention. Use of a clinical decision scheme based on risk factors may facilitate this process (Grade B, recommendation) (see Fig. 1).

Seizures

Patients with MTBI have only a slightly increased risk of developing post-traumatic seizures including early post-traumatic seizures (a seizure occurring in the first week) (Schierhout and Roberts, 1997; Annegers *et al*., 1998). Prophylactic antiepileptic treatment is not warranted. A systematic review of randomized controlled trials including 2036 patients showed that prophylactic antiepileptic treatment did not reduce mortality, neurological disability or late seizures (EL = I) (Schierhout and Roberts, 1998). If recurrent seizures occur, treatment is probably necessary and alternative explanations (i.e. delayed haematoma, Wernicke–Korsakoff syndrome, alcohol withdrawal or electrolyte disturbances) should be taken into account.

Recommendation: There is insufficient proof for prophylactic antiepileptic treatment after an early seizure (Grade A).

Skull base fracture

A skull base or temporal bone fracture or open fracture increases the risk of cerebrospinal fluid (CSF) leakage and CSF fistula formation (Dagi *et al*., 1983; Brodie, 1997; Brodie and Thompson, 1997). The reported incidence of CSF leakage after basal skull fracture varies from approximately 10 to 20%, and the incidence of bacterial meningitis from 2 to 50% (Leech and Paterson, 1973; Dagi *et al*., 1983; Helling *et al*., 1988; Marion, 1991; Brodie, 1997; Brodie and Thompson, 1997). The role of antibiotic prophylaxis in open or basilar skull fractures remains controversial; the conclusions of two recent meta-analyses on the prophylactic use of antibiotics were contradictory (Demetriades *et al*., 1992; Brodie, 1997; Villalobos *et al*., 1998).

Recommendation: There is insufficient proof for prophylactic antibiotic treatment against meningitis in patients with clinical signs of a skull base fracture, and a definitive study of prophylactic administration

14681331, 2002, 3, Downloaded from https://onlinelibrary.wiley.com/doi/10.1046/j.1468-1331.2002.00407.x by CochraneItalia, Wiley Online Library on [28/03/2026]. See the Terms and Conditions (https://onlinelibrary.wiley.com/terms-and-conditions) on Wiley Online Library for rules of use; OA articles are governed by the applicable Creative Commons License

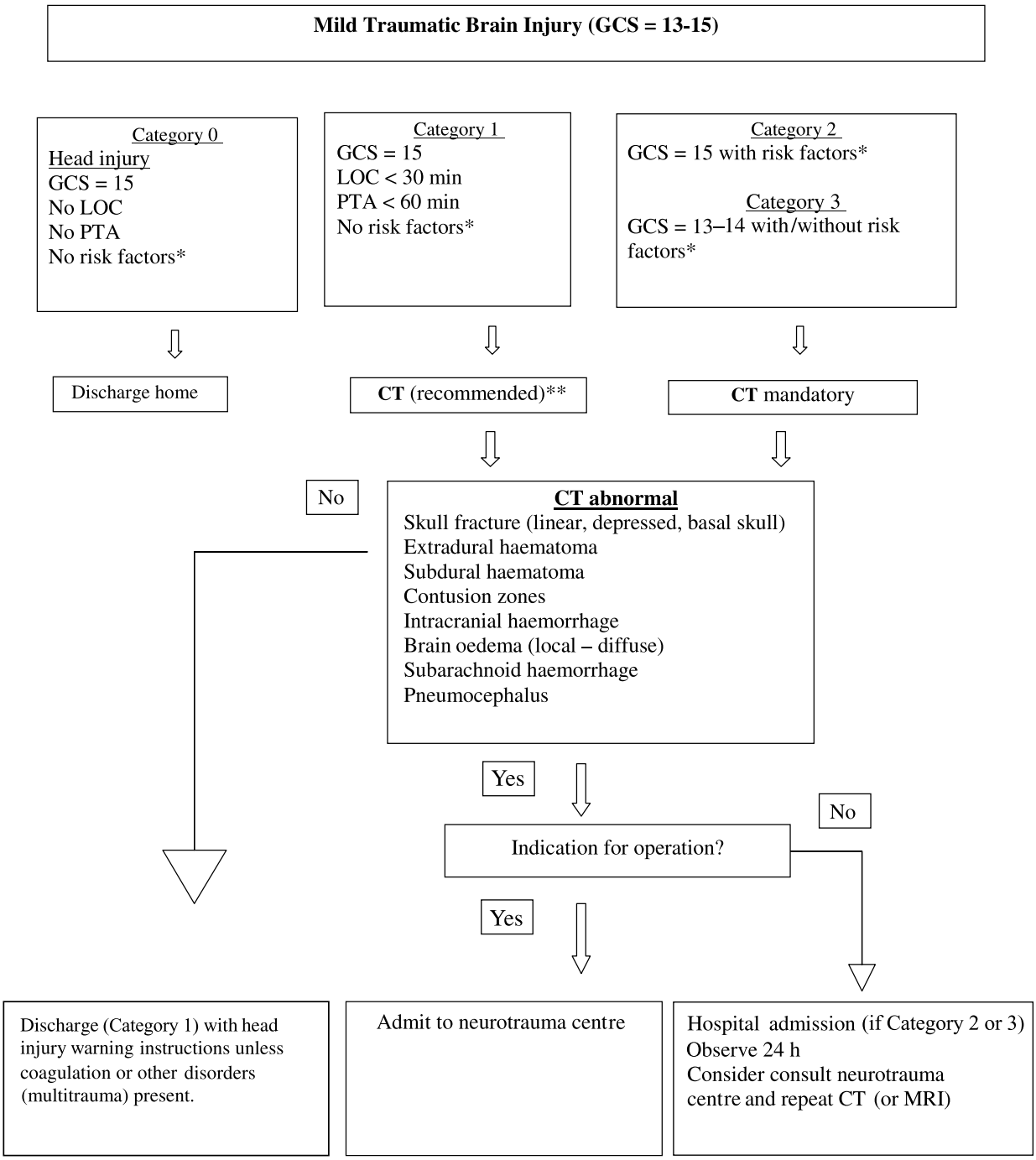

Figure 1 Decision scheme for initial management in mild traumatic brain injury (modified from the Dutch and Scandinavian guidelines) (Ingebrigtsen *et al.*, 2000; Twijnstra *et al.*, 2001). GCS, Glasgow Coma Scale; LOC, loss of consciousness; PTA, post-traumatic amnesia; TBI, traumatic brain injury; CT, computed tomography; MRI, magnetic resonance imaging. *Risk factors are shown in Table 2. **If CT availability is limited, conventional skull radiography can be performed but the sensitivity and specificity for intracranial abnormalities is low.

of antibiotics for post-traumatic CSF fistula has yet to be performed (Grade C) (Working Party of the British Society for Antimicrobial Chemotherapy, 1994).

Patients on anticoagulation

Recommendation: All patients with head injury should be questioned about the use of anticoagulation therapy

14681331, 2002, 3, Downloaded from https://onlinelibrary.wiley.com/doi/10.1046/j.1468-1331.2002.00407.x by CochraneItalia, Wiley Online Library on [28/03/2026]. See the Terms and Conditions (https://onlinelibrary.wiley.com/terms-and-conditions) on Wiley Online Library for rules of use; OA articles are governed by the applicable Creative Commons License

(Grade C, recommendation). All patients with head injury on anticoagulation therapy should have their INR checked and the indication for anticoagulation reviewed (Grade C). These patients should be admitted for neurological observation (Grade C, recommendation) (Saab *et al*., 1996). If CT demonstrates an intracranial haematoma, the INR should be corrected immediately. (Over-)anticoagulation can be best corrected with fresh frozen plasma and vitamin K. If spontaneous coagulation disorders or additional injuries with bleeding exist consultation with a coagulation specialist should be sought (Grade C, recommendation).

Ancillary investigations

Skull radiography versus CT

The diagnostic value of plain skull radiography is debated. Because earlier studies showed that radiographic evidence of a skull fracture increases the risk of intracranial haemorrhage, skull radiography was used as the principle triage tool on which management decisions were based (EL = Class III) (Mendelow *et al*., 1983; Masters *et al*., 1987; Teasdale *et al*., 1990; Nee *et al*., 1999). However, recent studies comparing skull radiography with CT showed a low sensitivity and specificity of the presence of a skull fracture on skull radiographs for intracranial haemorrhage (Borczuk, 1995). A meta-analysis confirmed that skull radiography is of little value in the initial assessment of MTBI (EL = I) (Hofman *et al*., 2000). On the basis of studies in which at least 50% of patients had a CT of the brain, the estimated sensitivity of radiographic evidence of skull fracture for a diagnosis of intracranial haemorrhage was only 0.38 with a corresponding specificity of 0.95 (Hofman *et al*., 2000).

Recommendation: Skull radiography is of insufficient value in the detection of intracranial abnormalities in patients with MTBI (Grade A, recommendation).

CT

Two large prospective studies investigated a clinical decision rule for use of CT to demonstrate the need for neurosurgical intervention or clinically important brain injury after MTBI (Haydel *et al*., 2000; Stiell *et al*., 2001). In a prospective study involving 1429 patients with minor head injury (minor head injury in this study defined as LOC and an admission GCS of 15), seven predictors (headache, vomiting, seizure, PTA, trauma above the clavicles, drug or alcohol intoxication, or age over 60 years) were retrieved after chi-square analysis and determination of likelihood ratios for each criterion. This model showed 100% (95% CI: 95–100%) sensitivity for intracranial complications. Application of the criteria would have resulted in a CT ordering proportion of 78% (or reduced use of CT of 22%) (Haydel *et al*., 2000).

In the Canadian prospective cohort study involving 3121 patients, 250 patients (8%) had clinically important brain injury and 31 (1%) required neurosurgical intervention. Five high-risk factors (failure to reach GCS of 15 within 2 h, suspected open skull fracture, any signs of basal skull fracture, vomiting >2 episodes or age >65 years) were derived which had 100% sensitivity (95% CI: 92–100%) for predicting the need for neurosurgical intervention (Stiell *et al*., 2001). Interestingly, this would lead to a CT ordering proportion of 32%. In addition, two medium-risk factors (amnesia before impact >30 min and dangerous mechanism of injury) were 98.4% sensitive (95% CI 96–99%) and 49.6% specific for predicting clinically important brain damage. This would lead to a CT ordering proportion of 54%. Both studies concluded that in patients with MTBI the use of CT can be safely limited to those who have certain clinical findings (Haydel *et al*., 2000; Stiell *et al*., 2001).

Recommendation: CT is considered a gold standard for the detection of life threatening (and other intracranial) abnormalities after MTBI and recommended in those with documented LOC and/or PTA and considered mandatory in all patients with certain clinical findings (GCS = 13–14, presence of risk factors) (Grade B, recommendation).

MRI

Cerebral magnetic resonance imaging (MRI) is not routinely used in TBI, although in the acute stage (within 3 days of injury) MRI is more sensitive than CT for detecting intracranial abnormalities (Wilson *et al*., 1988; Yokota *et al*., 1991; Levin *et al*., 1992a; van der Naalt *et al*., 1999b). Diffusion tensor imaging may reveal abnormalities not detected by conventional MRI (Wieshmann *et al*., 1999; Rugg-Gunn *et al*., 2001).

The relationship between intracranial abnormalities on MRI and outcome is not entirely clear, and more research is needed (Voller *et al*., 2001). When early MRI (within 21 days from the injury) and late MRI (between 5 and 18 months) findings were compared in patients with mild, moderate or severe TBI, measures of neuropsychological outcome correlated with late MRI findings only (Wilson *et al*., 1988).

Recommendation: MRI may be of value for the detection of structural brain damage in patients without CT abnormalities, and especially in those with long-term complaints (Grade B, recommendation).

14681331, 2002, 3, Downloaded from https://onlinelibrary.wiley.com/doi/10.1046/j.1468-1331.2002.00407.x by CochraneItalia, Wiley Online Library on [28/03/2026]. See the Terms and Conditions (https://onlinelibrary.wiley.com/terms-and-conditions) on Wiley Online Library for rules of use; OA articles are governed by the applicable Creative Commons License

PET and SPECT

Positron emission tomography (PET) and technetium ^{99m}-hexa-methylpropyleneamineoxime single photon emission computed tomography (SPECT) may show abnormalities in the acute and chronic stages when CT or MRI and neurological examination do not show damage (Ichise *et al.*, 1994; Jacobs *et al.*, 1994; Ruff *et al.*, 1994). Normal findings for SPECT performed within 1–4 weeks of mild and moderate TBI were predictive of a good outcome after 1 year, with a negative predictive value of 97% (Jacobs *et al.*, 1994). The specificity of abnormal findings, however, has been questioned (Alexander, 1998). A similar pattern of hypometabolism in the frontopolar and lateral temporal cortices and the basal ganglia has been reported among patients with depression but no injury (Dolan *et al.*, 1994; Mayberg, 1994).

Recommendation: No recommendations for the use of PET or SPECT in the initial phase after MTBI can be given at present.

Biochemical markers of traumatic brain injury

Brain-specific proteins, in particular S100B and neurone-specific enolase, may be released into the circulation after TBI. Serum levels of S100B are higher in patients with intracranial pathology and correlate with clinical outcome and the severity of primary and secondary brain damage (EL = II) (Raabe *et al.*, 1999; Romner *et al.*, 2000). Undetectable serum levels of S100B are predictive of normal intracranial findings on CT, and thus S100B could be used to select patients for CT after MTBI (EL = Class I) (Romner *et al.*, 2000). However, these results have to be confirmed in large prospective studies. In the future, this may be of relevance in the medico–legal context, to prove that the acute symptoms and signs and/or the long-term disability or neuropsychological impairments after MTBI are indeed a consequence of structural brain damage or of psychological stress in reaction to the event, alcohol intoxication, preexistent disorders, systemic injury or other causes (see also Romner *et al.*, 2000).

Recommendation: The study of biochemical markers of MTBI is of considerable interest (especially the negative predictive value of normal serum concentrations for the absence of intracranial abnormalities), but at present no recommendations can be given and more research is needed (Grade B, recommendation).

Initial patient management

According to the Advanced Trauma Life Support guidelines, any patient with head injury should be evaluated for surgical trauma (EL = III) (American College of Surgeons Committeee on Trauma, 1997). Proper triage includes assessing the airways, breathing, and circulation, and also the cervical spine. A neurological examination is obligatory and should include level of consciousness, presence of anterograde or retrograde amnesia and/or disorientation, higher cognitive functions, presence of focal neurological deficit (asymmetrical motor reactions or reflexes, unilateral paresis or cranial nerve deficit), pupillary responses, blood pressure and pulse rate (Valadka and Narayan, 1996; Ingebrigtsen *et al.*, 2000; Tate *et al.*, 2000). In addition, the presence of frontal lobe signs, cerebellar symptoms or sensory deficits should be actively investigated.

Recommendation: All patients with TBI should undergo a neurological examination, in addition to a surgical examination. Furthermore, obtaining accurate history (including medication), preferably with information being obtained from a witness of the accident or personnel involved in first-aid procedures outside the hospital, is important to ascertain the circumstances under which the accident took place and to assess the duration of LOC and amnesia (Grade C, recommendation).

The key issue in daily practice remains the question whether patients should be routinely admitted but not necessarily undergo CT of the head or whether patients should be admitted selectively but undergo CT of the head. MTBI category 2 and 3 patients should be evaluated with CT (EL = III) (Teasdale *et al.*, 1990; Shackford *et al.*, 1992; Stein and Ross, 1992). An algorithm for the initial management of MTBI is given in Fig. 1.

Recommendations: Hospitals should have a protocol for resuscitation and triage of patients with MTBI (Grade C). Category 2 and 3 patients should be admitted to a neurotrauma centre. All children with MTBI should be seen by a paediatrician or a child neurologist (Grade C). CT is recommended for category 1 patients and is mandatory for all category 2 and 3 patients (see Fig. 1) (Grade B, recommendation).* If CT findings are normal, adult category 1 patients can be discharged. Head injury warning instructions should be given to the patient and family members. Compliance is greater if both verbal and written instructions are given (EL = III) (de Louw *et al.*, 1994; Valadka and Narayan, 1996; Ingebrigtsen *et al.*, 2000). A repeat CT should be considered if the admission CT findings were abnormal or if risk factors are present (Table 2) (Grade C, recommendation).

*If CT availability is limited, conventional skull radiography can be performed but the sensitivity and specificity for intracranial abnormalities is low.

14681331, 2002, 3, Downloaded from https://onlinelibrary.wiley.com/doi/10.1046/j.1468-1331.2002.00407.x by CochraneItalia, Wiley Online Library on [28/03/2026]. See the Terms and Conditions (https://onlinelibrary.wiley.com/terms-and-conditions) on Wiley Online Library for rules of use; OA articles are governed by the applicable Creative Commons License

Clinical observation

Another issue is the necessity for and duration of neurological observation after MTBI. Patients in category 1 can be discharged home with head injury warning instructions if CT findings are normal (appendix to appear on the website of the EFNS: http://www.efns.org/) (Warren and Kissoon, 1989; Ward *et al*., 1992; Valadka and Narayan, 1996). Patients in categories 2 or 3 should preferably be admitted to hospital for observation, although the necessity of this can be questioned in some patients in category 2 (e.g. patients older then 60 years of age who are not on anticoagulation therapy). Scandinavian guidelines recommend an observation period of minimally 12 h, whereas other guidelines recommend a period of 24 h or longer (Masters *et al*., 1987; Bartlett *et al*., 1998; American Academy of Pediatrics, 1999; Ingebrigtsen *et al*., 2000; Twijnstra *et al*., 2001). The main goal of clinical observation is to detect, at an early stage, the development of extradural or subdural haematoma or diffuse cerebral oedema. A secondary goal is to determine the duration of PTA. An extradural haematoma usually develops within 6 h, and thus the initial CT may be false negative when performed very early (within 1 h) (Frowein *et al*., 1989; Smith and Miller, 1991; Servadei *et al*., 1995). Repeated neurological observation (see above) is therefore obligatory for the timely detection of clinical deterioration and other neurological deficits (such as sensory deficits, frontal lobe signs, cerebellar symptoms, etc.).

Recommendation: A repeat neurological examination should be carried out, its frequency being dependent on the clinical condition of the patient and the presence of CT abnormalities. For instance, the patient should be examined every 15–30 min and if no complications or deterioration occurs, every 1–2 h. The use of a neurological checklist may be helpful to document the neurological condition and its course. If deterioration occurs, possible intracranial causes should be evaluated with (repeated) CT (Grade C, recommendation).

Bed rest

No randomized trials exist on the value and duration of bed rest and on the duration of sick leave after MTBI. A survey among various European hospitals showed major differences in management with regard to the ordering (and duration) of bed rest, home observation, sick leave and follow-up examination (de Kruijk *et al*., 2001). A study in which patients were randomized for complete bed rest (for a period of 6 days) versus no bed rest showed no treatment effect on the number of post-traumatic complaints and quality of life 6 months after the trauma (de Kruijk, 2001). Graded resumption of activities after discharge and follow-up may beneficially influence the recovery process (EL = IV) (Alexander, 1995; Kibby and Long, 1997; Ingebrigtsen *et al*., 1998).

Recommendation: No recommendations can be given for the need for or duration of bed rest. Graded resumption of activities (including return to work) is probably the best strategy (Grade B, recommendation).

Follow-up

It has been shown that regular specialized outpatient follow-up visits are effective in reducing social morbidity and the severity of symptoms after MTBI (Wade *et al*., 1998). In a large randomized controlled trial, patients with a PTA shorter than 7 days and who received specialist intervention had significantly less social disability and fewer post-concussion symptoms 6 months after injury than those who did not receive the service (EL = II) (Wade *et al*., 1998).

Recommendation: It is recommended that all patients in MTBI category 3 who have been admitted to hospital should be seen at least once in the outpatient clinic approximately 1–2 weeks after discharge (Grade C) (Wade *et al*., 1998). Patients who are discharged immediately with head injury instructions should contact their general practitioners, who can decide to refer the patient to the neurologist if complaints persist (Grade C, recommendation).

Most patients return to work despite having complaints (van der Naalt *et al*., 1999a). Typical post-traumatic complaints are headache, dizziness, fatigue, irritability, anxiety, insomnia, photophobia, phonophobia, and memory and concentration disturbances (Dikmen *et al*., 1986; Evans, 1992; Binder, 1997). Post-traumatic complaints usually occur in the first 6–12 weeks after the trauma and tend to disappear by 6 months; however, in 7–8% of patients the post-traumatic complaints become chronic (Fenton *et al*., 1993; Bohnen *et al*., 1994; Dikmen *et al*., 1994, 1995; Binder, 1997). Follow-up visits in this patient group are determined by the presence and persistence of post-traumatic complaints such as headache, dizziness, poor concentration and memory disturbances.

Recommendation: Neuropsychological examination may be useful after 6 months in patients with persistent complaints, to determine whether these complaints are organic in nature or the result of pre-morbid personality, anxiety, psychological stress in reaction to the event, other pre-existent disorders or other causes (Grade C, recommendation) (Alexander, 1995).

14681331, 2002, 3, Downloaded from https://onlinelibrary.wiley.com/doi/10.1046/j.1468-1331.2002.00407.x by CochraneItalia, Wiley Online Library on [28/03/2026]. See the Terms and Conditions (https://onlinelibrary.wiley.com/terms-and-conditions) on Wiley Online Library for rules of use; OA articles are governed by the applicable Creative Commons License

Conclusions

The guidelines presented in this paper incorporate extensive use of CT. Moreover, the use of a clinical decision rule for CT and hospital admission after MTBI may increase the use of CT compared with other existing protocols. There is no agreement in the literature on whether patients with MTBI should be admitted selectively but undergo CT or whether all patients should be admitted but only a few undergo CT (Stiell *et al.*, 2001; Twijnstra *et al.*, 2001). A strategy that uses CT for all MTBI patients regardless of clinical findings is probably not cost-effective. The established risk factors for intracranial sequelae are predominantly based on retrospective studies which did not always use CT as the gold standard. Therefore, the value of clinical risk factors in predicting early and late sequelae (complaints, neuropsychological disturbances) should be validated in prospective European studies. It should also be evaluated whether it is feasible to use a clinical prediction rule to reduce the use of CT without negatively affecting clinical outcome. If feasible, this would increase the time- and cost-effectiveness of investigations. In future studies, outcome should include the need for neurosurgical interventions, CT abnormalities, and late (6 months to 1 year) clinical outcome measured with neuropsychological and/or neurological and quality of life scales.

Computed tomography is the preferred imaging method for MTBI although MRI is more sensitive. As MRI becomes more widely available, it may have a greater role in the evaluation of more subtle intracranial abnormalities in patients with MTBI (Haydel *et al.*, 2000; Voller *et al.*, 2001). Finally, it may be of interest to further explore the usefulness of biochemical markers as indicators of brain damage after MTBI.

References

Alexander MP (1995). Mild traumatic brain injury: pathophysiology, natural history, and clinical management. *Neurology* **45:**1253–1260.

Alexander MP (1998). In the pursuit of proof of brain damage after whiplash injury. *Neurology* **51:**336–340.

American Academy of Pediatrics (1999). The management of minor closed head injury in children. Committee on Quality Improvement, American Academy of Pediatrics. Commission on Clinical Policies and Research, American Academy of Family Physicians. *Pediatrics* **104:**1407–1415.

American College of Surgeons Committee on Trauma (1997). *Advanced Trauma Life Support for Doctors* **6th edn.** pp. 1–444.

Annegers JF, Hauser WA, Coan SP, Rocca WA (1998). A population-based study of seizures after traumatic brain injuries. *N Engl J Med* **338:**20–24.

Arienta C, Caroli M, Balbi S (1997). Management of head-injured patients in the emergency department: a practical protocol. *Surg Neurol* **48:**213–219.

Bartlett J, Kett-White R, Mendelow AD *et al.* (1998). Recommendations from the Society of British Neurological Surgeons. *Br J Neurosurg* **12:**349–352.

Bayston R, de Louvois J, Brown EM *et al.* (2000). Use of antibiotics in penetrating craniocerebral injuries. 'Infection in Neurosurgery' Working Party of British Society for Antimicrobial Chemotherapy. *Lancet* **355:**1813–1817.

Binder LM (1997). A review of mild head trauma. Part II: clinical implications. *J Clin Exp Neuropsychol* **19:**432–457.

Birbamer G, Gerstenbrand F, Aichner F *et al.* (1994). Imaging of inner cerebral trauma. *Acta Neurol (Napoli)* **16:**114–120.

Bohnen N, Van Zutphen W, Twijnstra A *et al.* (1994). Late outcome of mild head injury: results from a controlled postal survey. *Brain Inj* **8:**701–708.

Borczuk P (1995). Predictors of intracranial injury in patients with mild head trauma. *Ann Emerg Med* **25:**731–736.

Boyle MJ, Vella L, Moloney E (1991). Role of drugs and alcohol in patients with head injury. *J Royal Soc Med* **84:**608–610.

Brodie HA (1997). Prophylactic antibiotics for posttraumatic cerebrospinal fluid fistulae. A meta-analysis. *Arch Otolaryngol Head Neck Surg* **123:**749–752.

Brodie HA, Thompson TC (1997). Management of complications from 820 temporal bone fractures. *Am J Otol* **18:**188–197.

Bullock R, Chesnut RM, Clifton G *et al.* (1996). Guidelines for the management of severe head injury. Brain Trauma Foundation. *Eur J Emerg Med* **3:**109–127.

Cardoso ER, Galbraith S (1985). Posttraumatic hydrocephalus – a retrospective review. *Surg Neurol* **23:**261–264.

Chan KH, Yue CP, Mann KS (1990). The risk of intracranial complications in pediatric head injury. Results of multivariate analysis. *Childs Nerv Syst* **6:**27–29.

Culotta VP, Sementilli ME, Gerold K, Watts CC (1996). Clinicopathological heterogeneity in the classification of mild head injury. *Neurosurgery* **38:**245–250.

Dagi TF, Meyer FB, Poletti CA (1983). The incidence and prevention of meningitis after basilar skull fracture. *Am J Emerg Med* **1:**295–298.

Demetriades D, Charalambides D, Lakhoo M, Pantanowitz D (1992). Role of prophylactic antibiotics in open and basilar fractures of the skull: a randomized study. *Injury* **23:**377–380.

Denny-Brown D, Russell WR (1941). Experimental cerebral concussion. *Brain* **64:**93–163.

Dikmen SS, McLean A, Temkin N (1986). Neuropsychological and psychosocial consequences of minor head injury. *J Neurol Neurosurg Psychiatry* **49:**1227–1232.

Dikmen SS, Temkin NR, Machamer JE *et al.* (1994). Employment following traumatic head injuries. *Arch Neurol* **51:**177–186.

Dikmen SS, Ross BL, Machamer JE, Temkin NR (1995). One year psychosocial outcome in head injury. *J Int Neuropsychol Soc* **1:**67–77.

Dolan RJ, Bench CJ, Brown RG, Scott LC, Frackowiak RS (1994). Neuropsychological dysfunction in depression: the relationship to regional cerebral blood flow. *Psychol Med* **24:**849–857.

14681331, 2002, 3, Downloaded from https://onlinelibrary.wiley.com/doi/10.1046/j.1468-1331.2002.00407.x by CochraneItalia, Wiley Online Library on [28/03/2026]. See the Terms and Conditions (https://onlinelibrary.wiley.com/terms-and-conditions) on Wiley Online Library for rules of use; OA articles are governed by the applicable Creative Commons License

Dunham CM, Coates S, Cooper C (1996). Compelling evidence for discretionary brain computed tomographic imaging in those patients with mild cognitive impairment after blunt trauma. *J Trauma* **41:**679–686.

Durham SR, Clancy RR, Leuthardt E *et al*. (2000). CHOP infant coma scale ('Infant Face Scale'): a novel coma scale for children less than two years of age. *J Neurotrauma* **17:**729–737.

Evans RW (1992). The postconcussion syndrome and the sequelae of mild head injury. *Neurol Clin* **10:**815–847.

Fenton G, McClelland R, Montgomery A, MacFlynn G, Rutherford W (1993). The postconcussional syndrome: social antecedents and psychological sequelae. *Br J Psychiatry* **162:**493–497.

Feuerman T, Wackym PA, Gade GF, Becker DP (1988). Value of skull radiography, head computed tomographic scanning, and admission for observation in cases of minor head injury. *Neurosurgery* **22:**449–453.

Frowein RA, Firsching R (1990). Classification of head injury. In: Brackman R, ed. *Handbook of Clinical Neurology*. Elsevier Science Publishers, pp. 101–122.

Frowein RA, Schiltz F, Stammler U (1989). Early post-traumatic intracranial hematoma. *Neurosurg Rev* **12:**184–187.

Gennarelli TA (1983). Head injury in man and experimental animals: clinical aspects. *Acta Neurochir Suppl (Wien)* **32:**1–13.

Gennarelli TA, Thibault LE, Adams JH *et al*. (1982). Diffuse axonal injury and traumatic coma in the primate. *Ann Neurol* **12:**564–574.

Gerstenbrand F (1977). The symptomatology of the apallic syndrome. In: Dalle Ore G, Gerstenbrand F, Lucking CH, Peters G, Peters WH, eds. *The Apallic Syndrome*. Springer-Verlag, Berlin, pp. 14–21.

Gerstenbrand F, Lucking CH (1970). Acute traumatic brain-stem lesions. *Arch Psychiatrie Nervenkrankheit* **213:**264–281.

Gerstenbrand F, Stepan CH (2001). Mild traumatic brain injury. *Brain Inj* **15:**95–97.

Gomez PA, Lobato RD, Ortega JM, De La Cruz J (1996). Mild head injury: differences in prognosis among patients with a Glasgow Coma Scale score of 13–15 and analysis of factors associated with abnormal CT findings. *Br J Neurosurg* **10:**453–460.

Grcevic N (1988). The concept of inner cerebral trauma. *Scand J Rehabil Med Suppl* **17:**25–31.

Hahn YS, McLone DG (1993). Risk factors in the outcome of children with minor head injury. *Pediatr Neurosurg* **19:**135–142.

Haydel MJ, Preston CA, Mills TJ *et al*. (2000). Indications for computed tomography in patients with minor head injury [see comments]. *N Engl J Med* **343:**100–105.

Helling TS, Evans LL, Fowler DL, Hays LV, Kennedy FR (1988). Infectious complications in patients with severe head injury. *J Trauma* **28:**1575–1577.

Hofman PA, Nelemans P, Kemerink GJ, Wilmink JT (2000). Value of radiological diagnosis of skull fracture in the management of mild head injury: meta-analysis. *J Neurol Neurosurg Psychiatry* **68:**416–422.

Houlbourn AHS (1943). Mechanics of head injuries. *Lancet* **1:**438–441.

Hsiang JN, Yeung T, Yu AL, Poon WS (1997). High-risk mild head injury [see comments]. *J Neurosurg* **87:**234–238.

Hughes RA, Barnes MP, Baron JC, Brainin M (2001). Guidance for the preparation of neurological management guidelines by EFNS scientific task forces. *Eur J Neurol* **8:**549–550.

Ichise M, Chung DG, Wang P *et al*. (1994). Technetium-99m-HMPAO SPECT, CT and MRI in the evaluation of patients with chronic traumatic brain injury: a correlation with neuropsychological performance. *J Nucl Med* **35:**217–226.

Ingebrigtsen T, Romner B, Kock-Jensen C (2000). Scandinavian guidelines for initial management of minimal, mild, and moderate head injuries. The Scandinavian Neurotrauma Committee. *J Trauma* **48:**760–766.

Ingebrigtsen T, Waterloo K, Marup Jensen S, Attner E, Romner B (1998). Quantification of post-concussion symptoms 3 months after minor head injury in 100 consecutive patients. *J Neurol* **245:**609–612.

Jacobs A, Put E, Ingels M, Bossuyt A (1994). Prospective evaluation of technetium-99m-HMPAO SPECT in mild and moderate traumatic brain injury. *J Nucl Med* **35:**942–947.

Jennett B (1996). Epidemiology of head injury. *J Neurol Neurosurg Psychiatry* **60:**362–369.

Kelly DF (1995). Alcohol and head injury: an issue revisited. *J Neurotrauma* **12:**883–890.

Kibby MY, Long CJ (1997). Effective treatment of minor head injury and understanding its neurological consequences. *Appl Neuropsychol* **4:**34–42.

Klauber MR, Marshall LF, Luerssen TG *et al*. (1989). Determinants of head injury mortality: importance of the low risk patient [see comments]. *Neurosurgery* **24:**31–36.

Knuckey NW, Gelbard S, Epstein MH (1989). The management of 'asymptomatic' epidural hematomas. A prospective study. *J Neurosurg* **70:**392–396.

Kraus JF, McArthur DL, Silverman TA, Jayaraman M (1996). Epidemiology of brain injury. *Neurotrauma*: McGraw-Hill, New York, pp. 13–30.

de Kruijk JR (2001). Effectiveness of bed rest after mild traumatic brain injury. Mild traumatic brain injury: intervention and prognosis. Thesis: Maastricht, pp. 103–119.

de Kruijk JR, Twijnstra A, Meerhoff S, Leffers P (2001). Management of mild traumatic brain injury: lack of consensus in Europe. *Brain Inj* **15:**117–123.

Leech PJ, Paterson A (1973). Conservative and operative management for cerebrospinal-fluid leakage after closed head injury. *Lancet* **1:**1013–1016.

Levin HS, O'Donnell VM, Grossman RG (1979). The Galveston orientation and amnesia test. A practical scale to assess cognition after head injury. *J Nerv Ment Dis* **167:**675–684.

Levin HS, Williams DH, Eisenberg HM, High WM Jr, Guinto FC Jr (1992a). Serial MRI and neurobehavioural findings after mild to moderate closed head injury. *J Neurol Neurosurg Psychiatry* **55:**255–262.

Levin HS, Aldrich EF, Saydjari C *et al*. (1992b). Severe head injury in children: experience of the Traumatic Coma Data Bank. *Neurosurgery* **31:**435–443.

Livingston DH, Loder PA, Koziol J, Hunt CD (1991). The use of CT scanning to triage patients requiring admission following minimal head injury. *J Trauma* **31:**483–487.

Lloyd DA, Carty H, Patterson M, Butcher CK, Roe D (1997). Predictive value of skull radiography for intracranial injury in children with blunt head injury. *Lancet* **349:**821–824.

de Louw A, Twijnstra A, Leffers P (1994). Lack of uniformity and low compliance concerning wake-up advice following head trauma. *Ned Tijdschr Geneeskd* **138:**2197–2199.

14681331, 2002, 3, Downloaded from https://onlinelibrary.wiley.com/doi/10.1046/j.1468-1331.2002.00407.x by CochraneItalia, Wiley Online Library on [28/03/2026]. See the Terms and Conditions (https://onlinelibrary.wiley.com/terms-and-conditions) on Wiley Online Library for rules of use; OA articles are governed by the applicable Creative Commons License

Maas AI, Dearden M, Teasdale GM *et al.* (1997). EBIC-guidelines for management of severe head injury in adults. European Brain Injury Consortium. *Acta Neurochir (Wien)* **139:**286–294.

Marion DW (1991). Complications of head injury and their therapy. *Neurosurg Clin N Am* **2:**411–424.

Masters SJ, McClean PM, Arcarese JS *et al.* (1987). Skull x-ray examinations after head trauma. Recommendations by a multidisciplinary panel and validation study. *N Engl J Med* **316:** 84–91.

Mayberg HS (1994). Frontal lobe dysfunction in secondary depression. *J Neuropsychiatry Clin Neurosci* **6:**428–442.

Meerhoff SR, de Kruijk JR, Rutten J, Leffers P, Twijnstra A (2000). De incidentie van traumatisch schedel- of hersenletsel in het adherentie gebied van het Academisch Ziekenhuis Maastricht in 1997. *Ned Tijdschr Geneeskd* **144:**1915–1918.

Mendelow AD, Karmi MZ, Paul KS, Fuller GA, Gillingham FJ (1979). Extradural haematoma: effect of delayed treatment. *Br Med J* **1:**1240–1242.

Mendelow AD, Teasdale GM, Jennett B *et al.* (1983). Risks of intracranial haematoma in head injured adults. *Br Med J Clin Res Ed* **287:**1173–1176.

Mild Traumatic Brain Injury Committee (1993). Definition of mild traumatic brain injury. *J Head Trauma Rehabil* **8:**86–87.

van der Naalt J, van Zomeren AH, Sluiter WJ, Minderhoud JM (1999a). One year outcome in mild to moderate head injury: the predictive value of acute injury characteristics related to complaints and return to work [In Process Citation]. *J Neurol Neurosurg Psychiatry* **66:**207–213.

van der Naalt J, Hew JM, van Zomeren AH, Sluiter WJ, Minderhoud JM (1999b). Computed tomography and magnetic resonance imaging in mild to moderate head injury: early and late imaging related to outcome. *Ann Neurol* **46:**70–78.

Nee PA, Hadfield JM, Yates DW, Faragher EB (1999). Significance of vomiting after head injury. *J Neurol Neurosurg Psychiatry* **66:**470–473.

Paterniti S, Fiore P, Macri E *et al.* (1994). Extradural haematoma. Report of 37 consecutive cases with survival. *Acta Neurochir (Wien)* **131:**207–210.

Pople IK, Stranjalis G, Nelson R (1993). Anticoagulant-related intracranial haemorrhage [see comments]. *Br J Hosp Med* **49:**428–429.

Pudenz RH, Shelden CH (1946). The lucite calvarium – a method for direct observation of the brain. *J Neurosurg* **3:**487–505.

Raabe A, Grolms C, Sorge O, Zimmermann M, Seifert V (1999). Serum S-100B protein in severe head injury [see comments]. *Neurosurgery* **45:**477–483.

Reilly PL, Simpson DA, Sprod R, Thomas L (1988). Assessing the conscious level in infants and young children: a paediatric version of the Glasgow Coma Scale. *Childs Nerv Syst* **4:**30–33.

Rimel RW, Giordani B, Barth JT, Boll TJ, Jane JA (1981). Disability caused by minor head injury. *Neurosurgery* **9:**221–228.

Romner B, Ingebrigtsen T, Kongstad P, Borgesen SE (2000). Traumatic brain damage: serum S-100 protein measurements related to neuroradiological findings [in process citation]. *J Neurotrauma* **17:**641–647.

Ruff RM, Crouch JA, Troster AI *et al.* (1994). Selected cases of poor outcome following a minor brain trauma: comparing neuropsychological and positron emission tomography assessment. *Brain Inj* **8:**297–308.

Ruff RM, Jurica P (1999). In search of a unified definition for mild traumatic brain injury. *Brain Inj* **13:**943–952.

Rugg-Gunn FJ, Symms MR, Barker GJ, Greenwood R, Duncan JS (2001). Diffusion imaging shows abnormalities after blunt head trauma when conventional magnetic resonance imaging is normal. *J Neurol Neurosurg Psychiatry* **70:**530–533.

Saab M, Gray A, Hodgkinson D, Irfan M (1996). Warfarin and the apparent minor head injury. *J Accid Emerg Med* **13:**208–209.

Schierhout G, Roberts I (1997). The cochrane brain and spinal cord injury group [editorial]. *J Neurol Neurosurg Psychiatry* **63:**1–3.

Schierhout G, Roberts I (1998). Prophylactic antiepileptic agents after head injury: a systematic review. *J Neurol Neurosurg Psychiatry* **64:**108–112.

Seelig JM, Marshall LF, Toutant SM *et al.* (1984). Traumatic acute epidural hematoma: unrecognized high lethality in comatose patients. *Neurosurgery* **15:**617–620.

Sellier K, Unterharnscheidt F (1963). Hefte zur Unfallheilkunde; Mechanik und Pathomorphologie der Hirnschaden nach stumpfer gewalteinwirkung auf den schade l8–111.

Servadei F (1997). Prognostic factors in severely head injured adult patients with epidural haematoma's. *Acta Neurochir (Wien)* **139:**273–278.

Servadei F, Vergoni G, Staffa G *et al.* (1995). Extradural haematomas: how many deaths can be avoided? Protocol for early detection of haematoma in minor head injuries. *Acta Neurochir (Wien)* **133:**50–55.

Servadei F, Teasdale G, Merry G (2001). Defining acute mild head injury in adults: a proposal based on prognostic factors, diagnosis, and management. *J Neurotrauma* **18:**657–664.

Shackford SR, Wald SL, Ross SE *et al.* (1992). The clinical utility of computed tomographic scanning and neurologic examination in the management of patients with minor head injuries [see comments]. *J Trauma* **33:**385–394.

Simpson DA, Cockington RA, Hanieh A, Raftos J, Reilly PL (1991). Head injuries in infants and young children: the value of the Paediatric Coma Scale. Review of literature and report on a study. *Childs Nerv Syst* **7:**183–190.

Smith HK, Miller JD (1991). The danger of an ultra-early computed tomographic scan in a patient with an evolving acute epidural hematoma. *Neurosurgery* **29:**258–260.

Spatz H (1936). Pathologie der gedeckten Hirnverletzung unter besonderer Beruecksichtigung der Rindkontusion. *Z Fur die Gesamte Neurologie Psychiatrie* **78:**615–616.

Stein SC, Ross SE (1992). Mild head injury: a plea for routine early CT scanning. *J Trauma* **33:**11–13.

Stein SC, Spettell C (1995). The Head Injury Severity Scale (HISS): a practical classification of closed-head injury. *Brain Inj* **9:**437–444.

Stein SC, Young GS, Talucci RC, Greenbaum BH, Ross SE (1992). Delayed brain injury after head trauma: significance of coagulopathy. *Neurosurgery* **30:**160–165.

Stepan CH, Binder H, Gerstenbrand F (2001). Terminology of mild traumatic brain injury, results of a survey in Austria 2000 (abstract). *World Congress on Traumatic Brain Injury*, Torino, p. 209.

Stiell IG, Wells GA, Vandemheen K *et al.* (2001). The Canadian CT Head Rule for patients with minor head injury. *Lancet* **357:**1391–1396.

14681331, 2002, 3, Downloaded from https://onlinelibrary.wiley.com/doi/10.1046/j.1468-1331.2002.00407.x by CochraneItalia, Wiley Online Library on [28/03/2026]. See the Terms and Conditions (https://onlinelibrary.wiley.com/terms-and-conditions) on Wiley Online Library for rules of use; OA articles are governed by the applicable Creative Commons License

Tate RL, Pfaff A, Jurjevic L (2000). Resolution of disorientation and amnesia during post-traumatic amnesia. *J Neurol Neurosurg Psychiatry* **68:**178–185.

Teasdale GM (1995). Head injury [see comments]. *J Neurol Neurosurg Psychiatry* **58:**526–539.

Teasdale GM, Jennett B (1974). Assessment of coma and impaired consciousness. A practical scale. *Lancet* **2:**81–84.

Teasdale GM, Murray G, Anderson E *et al*. (1990). Risks of acute traumatic intracranial haematoma in children and adults: implications for managing head injuries. *Br Med J* **300:**363–367.

Trotter W (1924). Annual oration on certain minor head injuries of the brain. *Lancet* **1:**935–939.

Twijnstra A, Brouwer OF, Keyser A *et al*. (2001). Richtlijnen voor de diagnostiek en behandeling van patienten met licht schedel-hersenletsel. *Commissie Kwaliteitsbevordering van de Nederlandse Vereniging voor Neurologie* 1–26.

Valadka AB, Narayan RK (1996). Emergency room management of the head-injured patient. *Neurotrauma*. McGraw-Hill, New York, pp. 119–135.

Villalobos T, Arango C, Kubilis P, Rathore M (1998). Antibiotic prophylaxis after basilar skull fractures: a meta-analysis. *Clin Infect Dis* **27:**364–369.

Volans AP (1998). The risks of minor head injury in the warfarinised patient. *J Accid Emerg Med* **15:**159–161.

Voller B, Auff E, Schnider P, Aichner F (2001). To do or not to do? Magnetic resonance imaging in mild traumatic brain injury. *Brain Inj* **15:**107–115.

Vos PE, Zwienenberg M, O'Hannian KL, Muizelaar JP (2000). Subarachnoid haemorrhage following rupture of an ophthalmic artery aneurysm presenting as traumatic brain injury. *Clin Neurol Neurosurg* **102:**29–32.

Wade DT, King NS, Wenden FJ, Crawford S, Caldwell FE (1998). Routine follow up after head injury: a second randomised controlled trial. *J Neurol Neurosurg Psychiatry* **65:**177–183.

Ward AB, Boughey AM, Aung TS, Barrett K (1992). Use of head injury instruction cards in accident centres. *Arch Emerg Med* **9:**314–316.

Warren D, Kissoon N (1989). Usefulness of head injury instruction forms in home observation of mild head injuries. *Pediatr Emerg Care* **5:**83–85.

Wieshmann UC, Symms MR, Clark CA *et al*. (1999). Blunt-head trauma associated with widespread water-diffusion changes [letter]. *Lancet* **353:**1242–1243.

von Wild K, Terwey S (2001). Diagnostic confusion in mild traumatic brain injury (MTBI). Lessons from clinical practice and EFNS – inquiry. European Federation of Neurological Societies. *Brain Inj* **15:**273–277.

Williams DH, Levin HS, Eisenberg HM (1990). Mild head injury classification. *Neurosurgery* **27:**422–428.

Wilson JT, Wiedmann KD, Hadley DM *et al*. (1988). Early and late magnetic resonance imaging and neuropsychological outcome after head injury. *J Neurol Neurosurg Psychiatry* **51:**391–396.

Working Party of the British Society for Antimicrobial Chemotherapy (1994). Infection in neurosurgery. Antimicrobial prophylaxis in neurosurgery and after head injury. *Lancet* **344:**1547–1551.

Yokota H, Kurokawa A, Otsuka T, Kobayashi S, Nakazawa S (1991). Significance of magnetic resonance imaging in acute head injury. *J Trauma* **31:**351–357.

14681331, 2002, 3, Downloaded from https://onlinelibrary.wiley.com/doi/10.1046/j.1468-1331.2002.00407.x by CochraneItalia, Wiley Online Library on [28/03/2026]. See the Terms and Conditions (https://onlinelibrary.wiley.com/terms-and-conditions) on Wiley Online Library for rules of use; OA articles are governed by the applicable Creative Commons License