CORTEX 58 (2014) 325–337

Available online at www.sciencedirect.com

SciVerse ScienceDirect

Journal homepage: www.elsevier.com/locate/cortex

Special section: Review

The huge plastic potential of adult brain and the role of connectomics: New insights provided by serial mappings in glioma surgery

Hugues Duffau [a,b,*]

[a] *Department of Neurosurgery, Gui de Chauliac Hospital, Montpellier University Medical Center, Montpellier, France*
[b] *National Institute for Health and Medical Research (INSERM), U1051 Laboratory, Team "Brain Plasticity, Stem Cells and Glial Tumors", Institute for Neurosciences of Montpellier, Montpellier University Medical Center, Montpellier, France*

ARTICLE INFO

Article history:
Received 14 June 2013
Reviewed 21 July 2013.
Revised 28 July 2013
Accepted 8 August 2013
Published online 19 August 2013

Keywords:
Neuroplasticity
Brain connectomics
Serial mappings
Awake surgery
Direct electrical stimulation

ABSTRACT

While prominent in the traditional literature, the localizationist and static view of brain processing does not explain numerous observations of functional recovery following cerebral damages. Here, the goal is to revisit this classical modular and inflexible model by proposing a dynamic organization of brain circuits, which allows postlesional cerebral adaptative phenomena able to maintain neurological and cognitive functions, even in adults. In this state of mind, recent data provided by serial mappings performed in patients who underwent awake surgery for diffuse glioma infiltrating eloquent structures will be reviewed. Firstly, the use of intraoperative electrical mapping enables the realization of online anatomo-functional correlations both at cortical and subcortical levels, supporting a network distribution of the brain, and resulting in the reappraisal of cognitive models – notably regarding language. Secondly, combination of neuropsychological assessments and functional neuroimaging before and after operation demonstrates that it is possible to achieve massive resections of "critical" regions without eliciting permanent sequelae, thanks to reorganization of cerebral circuits. Thirdly, repeated surgeries in cases of tumor relapse show functional remapping in the same patients over time. Taken together, these findings open the window toward a huge plastic potential of human central nervous system (CNS) in adults. However, a better understanding of cerebral connectomics leads to the conclusion that the white matter connectivity constitutes a main limitation of such brain plasticity, explaining the lack of recovery in patients with extensive subcortical damages.
© 2013 Elsevier Ltd. All rights reserved.

* Department of Neurosurgery, Gui de Chauliac Hospital, Montpellier University Medical Center, 80 Avenue Augustin Fliche, 34295 Montpellier, France.
E-mail address: h-duffau@chu-montpellier.fr.
0010-9452/$ – see front matter © 2013 Elsevier Ltd. All rights reserved.
http://dx.doi.org/10.1016/j.cortex.2013.08.005

1. Introduction

For more than one century, human brain functioning was conceived in a localizationist and fixed workframe, especially in adults. According to this view, the central nervous system (CNS) was thought to be organized in highly specialized critical zones (e.g., Broca's and Wernicke's areas) for which any damage generates severe and irrevocable functional deficits, combined with "non-eloquent" regions – inducing no neurological consequences when injuried. This dogma of a static functional organization of the brain had numerous implications both in fundamental neurosciences, by resulting notably in the elaboration of simplistic and rigid models of cognition, as well as in clinical practice – in particular by claiming that surgery was impossible in the so-called "eloquent" structures.

Nonetheless, owing to regular observations of functional improvement after lesion involving the cerebral areas considered as essential, this concept of modular and inflexible brain processing has been questioned. Therefore, the purpose here is to review the recent findings issued from serial mappings achieved in patients who underwent awake surgery for diffuse glioma infiltrating these "eloquent" structures. Indeed, intraoperative electrical mapping enables to perform real-time anatomo-functional correlations both at cortical and subcortical levels, supporting a network organization of the brain, and leading to the reappraisal of cognitive models – notably regarding language. In addition, combination of neuropsychological examinations and functional neuroimaging before and after operation demonstrated that it was possible to achieve massive resections of "critical" regions without eliciting permanent neurological deficits, thanks to reshaping of cerebral circuits. Finally, repeated surgeries for tumor reccurrence showed functional remapping in the same patients over time. Taken together, these original data open the window toward a huge plastic potential of human CNS in adults. Nonetheless, it seems that the white matter connectivity should be preserved to allow networks redistribution, meaning that cerebral connectomics might constitute a main limitation of such brain plasticity.

2. Intraoperative electrical mapping of brain networks in awake patients: towards revisited models of cognition

2.1. *The principle of direct electrostimulation of CNS*

Here, the goal is to re-examine the neural dynamics of brain functions on the basis of data provided by direct electrostimulation mapping (DEM) of CNS in awake patients. Indeed, during surgery for a lesion (such as a tumor) invading both cortical and subcortical structures, it has become common clinical practice to awaken patients in order to assess the functional role of restricted cerebral regions. The surgeon can maximize the extent of resection, and thereby improve the overall survival, without eliciting permanent neurological worsening, owing to an individual mapping and preservation of critical structures. This means that the resection is achieved according to functional boundaries (Duffau, Gatignol, Mandonnet, Capelle, & Taillandier, 2008). In practice, patients perform several sensori-motor, language, cognitive or emotional tasks (e.g., line bissection or picture naming) while the surgeon temporarily interacts with discrete areas within the gray and white matter around the tumor, using DEM. If the patients stops moving, speaking or produces wrong response, the surgeon avoid removing the stimulated site (Duffau, 2011). Although the exact mechanism of DEM remains matter of debate, the usual view is that DEM transiently interacts locally with a small cortical or axonal site, but also non-locally, as the focal perturbation will indeed disrupt the whole sub-network sustaining a given function (Mandonnet, Winkler, & Duffau, 2010). Thus, conversely to functional neuroimaging, *DEM is able to detect the structures essential for brain functions*, by inducing a transient virtual lesion based on the inhibition of a sub-circuit during approximately 4 s – with the possibility to check whether the same functional disorders are reproduced when repeated stimulations are applied over the same area. Interestingly, by gathering all cortical and axonal sites where the same type of errors have been observed when stimulated, one would build up the sub-network of the disrupted sub-function. As a consequence, DEM was extensively demonstrated to represent a unique opportunity to identify with a great accuracy (about 5 mm) and reproducibility, in vivo in humans, the structures that are crucial for cognitive functions, both at cortical and subcortical (white matter and deep gray nuclei) levels. In addition, combining neurological disturbances elicited by intrasurgical DEM with the anatomical data provided by pre- and postoperative Magnetic resonance imaging (MRI) has enabled to perform reliable anatomo-functional correlations (Bello et al., 2008; Duffau, Gatignol, Mandonnet et al., 2005).

Original findings given by intraoperative DEM during awake surgery allows the proposal of revisited models of brain processes, by switching from a modular to a delocalized and dynamic view (Duffau, 2008a). In this framework, brain functioning is underlain by large-scale sub-networks interacting together and able to compensate themselves after brain lesion (at least to some degrees), opening the door to brain plasticity.

2.2. *The example of anatomo-functional connectivity of language: the model of picture naming process revisited by intraoperative DEM*

One of the best examples of circuit which should be better understood is the network underlying picture naming, a task considered as a cornerstone in intraoperative mapping of language (Ojemann, Ojemann, Lettich, & Berger, 1989). Indeed, DEM allowed a re-examination of the classical Broca-Wernicke's model, which took precedence over all others for many decades. According to this revisited model (Duffau, Moritz-Gasser, & Mandonnet, 2013) (Fig. 1), in the naming process, the first step is visual perception and recognition. DEM of the optic pathways may elicit reversible phosphenes or visual loss in the contralateral visual fiel (described by the awake patients) due to an inhibition of visual perception (Gras-Combes, Moritz-Gasser, Herbet, & Duffau, 2012). Visual formal paraphasia has also been induced by electrical interferences with a second stage of visual processing, i.e., visual recognition. These

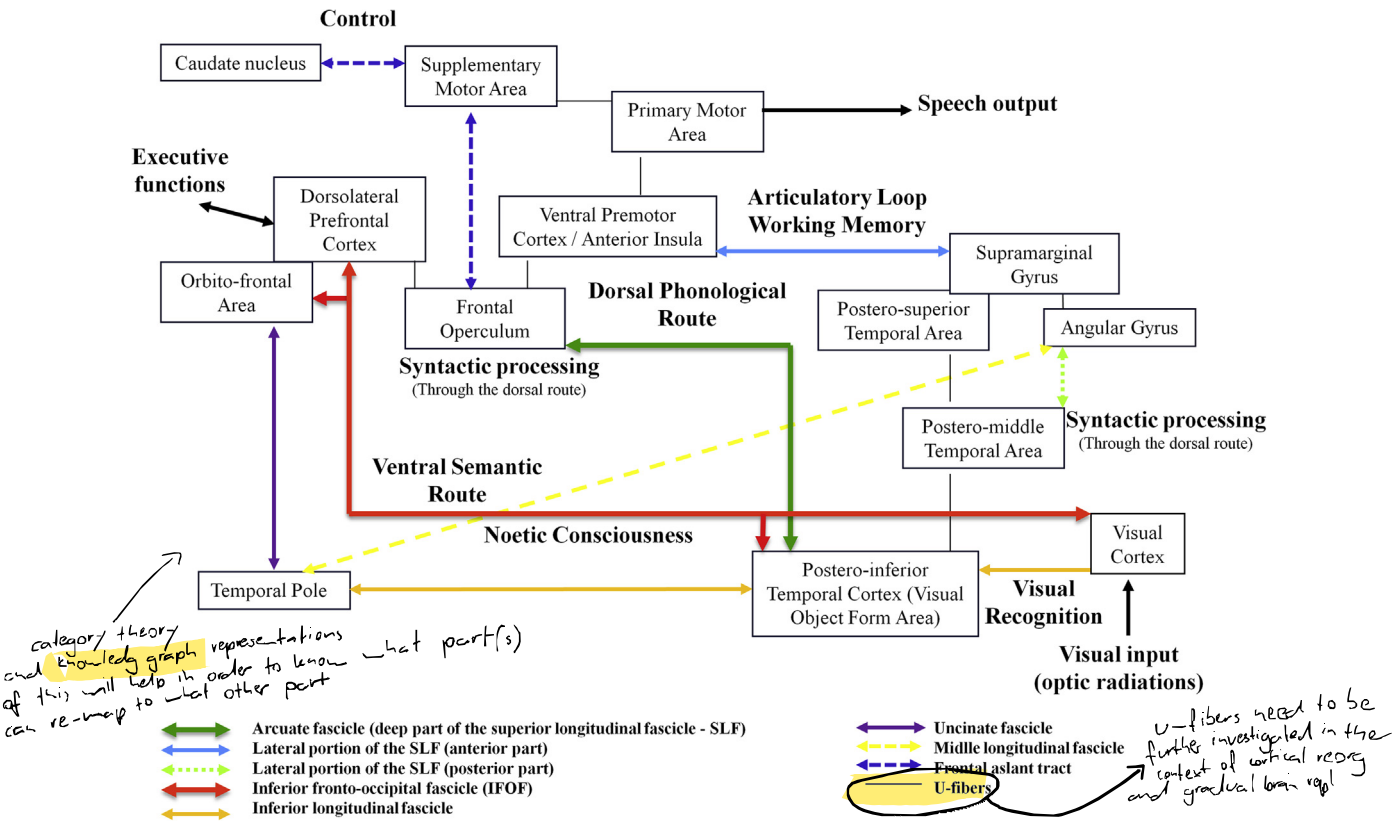

Fig. 1 – Modified from Duffau et al. (2013): Proposal of a hodotopical model of language and its relationships with other cognitive functions, with incorporation of anatomic constraints, elaborated on the basis of structural–functional correlations issued from intrasurgical DEM.

disorders have been generated by axonal DEM of a sub-part of the posterior inferior longitudinal fascicle, which links the visual cortex with the "visual object form area" (Mandonnet, Gatignol, & Duffau, 2009). This area, participating in object recognition, is close to the visual word form area, which receives another sub-part of the inferior longitudinal fascicle as afference, a sub-pathway involved in reading – thus generating alexia when injuried (Gaillard et al., 2006). Furthermore, by performing subcortical DEM of distinct sub-components within left the occipito-temporal white matter, a double dissociation between alexia (lower fibers) and anomia (upper fibers) has been generated in the same patients (Gil Robles et al., 2013). Thus, these data support the existence of parallel pathways coming from the occipital cortex, specifically involved in word versus object recognition.

Following this first step of visual recognition, an original dual model for visual language processing was proposed on the basis of DEM findings, with a ventral stream involved in mapping visual information to meaning (the "what" pathway) and a dorsal stream dedicated to mapping visual information to articulation through visuo-phonological conversion. Because double dissociation between phonemic and semantic errors has been demonstrated by DEM (Maldonado, Moritz-Gasser, & Duffau, 2011), both processes seem to be performed in parallel, and not serially. Indeed, concerning the ventral semantic stream, cortically, semantic paraphasias have been induced by DEM along the posterior part of superior temporal sulcus, in the dorso-lateral prefrontal cortex and in the pars orbitaris of the inferior frontal gyrus (Bello et al., 2007; Duffau, Gatignol, Mandonnet et al., 2005). Axonally, such disturbances were generated by stimulation of the left inferior fronto-occipital fascicle (IFOF), a pathway which connects the posterior occipital lobe and visual object form area to anterior cortical frontal areas, including the inferior frontal gyrus and dorso-lateral prefrontal cortex (Martino, Brogna, Gil Robles, Vergani, & Duffau, 2010; Sarubbo, De Benedictis, Maldonado, Basso, & Duffau, 2013) – known to be involved in language semantics and higher cognitive functions as plurimodal integration or judgment (Duffau, Gatignol, Mandonnet et al., 2005; Moritz-Gasser, Herbet, & Duffau, 2013; Plaza, Gatignol, Cohen, Berger, & Duffau, 2008). Thus, pretreated information by the visual recognition system is subsequently processed by the semantic system (in parallel to the dorsal phonological stream, see below) before being processed by the executive system. In addition to this direct ventral route subserved by the IFOF, there is an indirect ventral semantic pathway with a relay at the level of the temporal pole, which represents a semantic "hub" allowing a plurimodal integration of the multiple data coming from the unimodal systems (Holland & Lambon-Ralph, 2010). This indirect ventral stream is constituted by the anterior part of the inferior longitudinal fascicle, connecting the visual object form area with the temporal pole (Mandonnet, Nouet, Gatignol, Capelle, & Duffau, 2007), and then relayed by the uncinate fascicle which links the temporal

pole with the pars orbitalis of the inferior frontal gyrus (Duffau, Gatignol, Moritz-Gasser, & Mandonnet, 2009).

Regarding the dorsal phonological stream, cortically, phonemic paraphasia can be elicited by DEM of the inferior parietal lobule and inferior frontal gyrus (Maldonado,Moritz-Gasser, de Champfleur et al., 2011). Axonally speaking, phonemic paraphasias were elicited when stimulating the arcuate fascicle, which is a fiber tract stemming from the caudal part of the temporal lobe, mainly the inferior and middle temporal gyri, that arches around the insula and advances forward to end within the frontal lobe, essentially within the ventral premotor cortex and pars opercularis of the inferior frontal gyrus (Duffau, Capelle et al., 2002; Martino et al., 2013). Geschwind has previously postulated that lesions of this tract would produce conduction aphasia, including phonemic paraphasia (Geschwind, 1970), and supporting the role of the sub-part of the dorsal stream mediated by the arcuate fascicle in phonological processing. Interestingly, the posterior cortical origin of this tract within the posterior part of the inferior temporal gyrus corresponds to the visual object form area (Martino et al., 2013). Indeed, this region represents a functional hub, involved both in semantic (see above) and phonological processing dedicated to visual material (Vigneau et al., 2006). Thus, phonological process subserved by the arcuate fascicle is performed in parallel to the semantic process underlain by the ventral route. In addition to this direct dorsal route, tractography studies evidenced the existence of an indirect dorsal stream, running more superficially, and underlain by the lateral superior longitudinal fascicle (Catani, Jones, & ffytche, 2005). This pathway is implied in articulation and phonological working memory, as demonstrated by DEM. Cortical areas eliciting articulatory disorders are located in the ventral premotor cortex, supramarginal gyrus and posterior part of the superior temporal gyrus (Duffau, Capelle, Denvil, Gatignol et al., 2003; Duffau, Gatignol, Denvil, Lopes, & Capelle, 2003). Axonally, stimulation of the white matter under the fronto-parietal operculum and supramarginal gyrus, laterally and ventrally to the arcuate fascicle, induces anarthria as well (van Geemen, Herbet, Moritz-Gasser, & Duffau, 2013). Indeed, this lateral operculo-opercular component of the superior longitudinal fascicle constitutes the articulatory loop, by connecting the supramarginal gyrus/posterior portion of the superior temporal gyrus (which receives feedback information from somatosensory and auditory areas) with the frontal operculum (which receives afferences bringing the phonological/phonetic information to be translated into articulatory motor programs and efferences) toward the primary motor area (Duffau, Gatignol, Denvil et al., 2003).

To sum up, DEM resulted in the elaboration of a new model of picture naming, based on multiple direct and indirect cortico-subcortical interacting sub-networks involved in semantic, phonological and articulatory processes. This model offers several advantages in comparison with previous ones (i) it explains double dissociations during DEM (e.g., semantic versus phonemic paraphasias); (ii) it takes into account the cortical and subcortical anatomic constraints; (iii) it explains the possible recovery of aphasia following a lesion within the "classical" language areas (see below).

2.3. *Reappraisal of other functional sub-networks*

Using the same paradigm, DEM allowed a reappraisal of cognitive models underlying other brain functions. For example, DEM demonstrated that syntactic processing was subserved by delocalized cortical regions (left inferior frontal gyrus and posterior middle temporal gyrus) connected by a sub-part of the left inferior superior longitudinal fascicle. Interestingly, this sub-circuit is interacting but independent of the sub-network involved in naming, as demonstrating by double dissociation between syntactic (especially grammatical gender) and naming processing during DEM. These findings support parallel rather than serial theory, calling into question the principle of "lemma" (Vidorreta, Garcia, Moritz-Gasser, & Duffau, 2011).

In the same vein, DEM showed that spatial cognition was subserved by several cortical areas, including the right supramarginal gyrus, connected together by a sub-part of the superior longitudinal fascicle (Thiebaut de Schotten et al., 2005). In addition, based on intraoperative DEM results, a large cortico-subcortical network including fronto-parietal connections as well as fibers running within the anterior limb of the internal capsule was recently described, as involved in control of movement. Indeed, arrest or acceleration of voluntary movements performed by awake patients have been reproducibly elicited by DEM of tracts around the pyramidal pathways (Schucht, Moritz-Gasser, Herbet, Raabe, & Duffau, 2012).

In such "connectionist" view of CNS organization, interactions between different systems have also been described. For instance, DEM evidenced the existence of an executive system (including prefrontal cortex, anterior cingulum and caudate nucleus) involved in the cognitive control of more dedicated sub-circuit as language switching – itself constituted by a wide cortico-subcortical network comprising postero-temporal areas, supramarginal and angular gyri, inferior frontal gyrus and a sub-part of the superior longitudinal fascicle (Moritz-Gasser & Duffau, 2009). In the same state of mind, a cortico-subcortical loop involving the deep gray nuclei was also demonstrated as participating in the control of language (selection/inhibition), since DEM of the head of the caudate nucleus in the left hemisphere generated perseverations with a high level of reliability (Gil Robles, Gatignol, Capelle, Mitchell, & Duffau, 2005). This cortico-striatal loop could be anatomically underlain by the frontal aslant tract (Thiebaut de Schotten, Dell'Acqua, Valabregue, & Catani, 2012).

More recently, by using semantic association task (e.g., Pyramidal and Palm Tree Test), it was reported that DEM of a wide sub-network comprising the left postero-superior temporal area, dorso-lateral prefrontal cortex and IFOF generated disturbances of comprehension, including non-verbal semantic processing and cross-modal judgment (Gatignol, Capelle, Le Bihan, & Duffau, 2004; Moritz-Gasser et al., 2013; Plaza et al., 2008). Interestingly, double dissociation between picture naming and comprehension has been observed during DEM, again supporting parallel sub-networks and not serial processing (Duffau et al., 2013). Of note, in this framework, the exact role of the middle longitudinal fascicle remains unclear

(De Witt Hamer, Moritz-Gasser, Gatignol, & Duffau, 2011). The next step is now to explore cortico-subcortical circuits involved in working memory and attention, with a likely implication of a fronto-parietal loop subserved by the lateral part of the superior longitudinal fascicle (Duffau et al., 2013), in emotional processing such as theory of mind and even in noetic consciousness – probably underlain by the ventral semantic pathway including the IFOF (Moritz-Gasser et al., 2013).

In summary, the vision of the neural basis of cognition begins to shift. For a long time, cognitive functions were conceived in associationist terms of centers and pathways, the general assumption being that information was processed in localized cortical regions with the serial passage of information between regions through white matter tracts. Currently, an alternative "hododopical" account is proposed, in which CNS function is conceived as resulting from parallel distributed processing performed by distributed groups of connected neurons rather that individual centers (Duffau, 2008a). Conversely to serial models in which one process must be finished before than the information accedes to another level of processing, these new models of "independent networks" state that different processing can be performed simultaneously with interactive feedbacks. A multimodality approach seems now mandatory, with a more accurate analysis of the interactions between the subnetworks underlying distinct cognitive functions (e.g., language, visuo-spatial component, executive functions, as well as behavioral aspects) in order to open new avenues to the effective connectivity – that is, the influence that one neural system exerts over another (Fig. 1).

3. Functional compensation in surgical resection of "eloquent" areas: serial mappings to investigate brain remodeling

3.1. *Preoperative assessment*

Tumors like diffuse low-grade gliomas (LGG) are very frequently located within "functional" regions, as the left frontal lobe including supplementary motor area or so-called "Broca's" area, the insular lobe or central region (Duffau & Capelle, 2004). However, it is amazing to note that the vast majority of patients enjoys a normal life, with no or only mild neurological deficits despite large tumoral volumes at diagnosis – the first symptom being seizures in most of cases. This is probably due to the fact that LGG is a slow-growing tumor which progressively invades the brain over years (Duffau, 2013). This slow time course of the disease explains why LGG has induced cerebral reshaping, as suggested by preoperative functional neuroimaging. Indeed, neuroplasticity cannot be fully understood without considering the temporal course of the injury inflicted to the brain. Therefore, in acute lesion such as stroke, even if many patients improved within the months following the damage, only around 25% of patients totally recovered, while more than 90% of patients with an LGG (same location than stroke) had a normal neurological examination (Desmurget, Bonnetblanc, & Duffau, 2007).

Interestingly, using a neurocomputational model based on a training of a series of parallel distributed processing neural network models, a recent work simulated acute versus slow-growing injuries (Keidel, Welbourne, & Lambon Ralph, 2010). The results showed a very different pattern emerging in the simulation of LGG in comparison with the simulation of stroke, with slow decay of the links within the same subnetwork leading to minimal performance decline, in agreement with the patient literature. Moreover, at the end of the decay regime, the entire affected hidden layer could be "removed" on the simulation with no effect on performance – which closely matches the lack of major impairment from LGG resection (see below). It is likely due to the fact that abrupt stroke occasions rapid neuronal death, while LGG initially spares neuronal tissue and thus gives time for cerebral remapping.

Concerning the neural foundations of such functional compensation in LGG before any treatment, the patterns of reorganization may differ between patients. Indeed, preoperative functional neuroimaging has shown that four kinds of preoperative functional redistribution are possible, in patients without any deficit (Duffau, 2005, 2006a). In the first one, due to the infiltrative feature of gliomas, function still persists within the tumor; in the second one, eloquent areas are redistributed around the tumor; in the third one, there is already a preoperative compensation by remote areas within the lesional hemisphere; in the last one, a network of areas can be recuited in the controlateral hemisphere; finally, these different patterns of reshaping can be associated. Therefore, in cases of brain lesions involving eloquent areas, plasticity mechanisms seem to be based on a hierarchically organized model, i.e., first with intrinsic reorganization within injured areas (indice of favorable outcome); second, when this reshaping is not sufficient, other regions implicated in the functional network are recruited, in the ipsilateral hemisphere (close and even remote to the damaged area) then in the controlateral hemisphere if necessary (Duffau, 2008b).

In other words, neuroplasticity is conceivable only in a dynamic and not static view of brain organization. According to new theories, the brain is an ensemble of complex networks that form, reshape and flush information dynamically (Varella, Lachaux, Rodriguez, and Martinerie, 2001; Werner, 2007). Thus, reorganization could occur, based on the existence of multiple and overlapping redundancies hierarchically organized (Duffau, Sichez, & Lehéricy, 2000). These findings have testified that neuronal aggregates, beside or outlying a lesion, can increasingly adopt the function of the damaged area and switch their own activation pattern to substitute the lesioned area while facilitating functional recovery following brain damage (Duffau, 2006a). In this context, the concept of the brain *connectome* has recently emerged. Its goal is to capture the characteristics of spatially-distributed dynamical neural processes at multiple spatial and temporal scales (Sporns, Tononi, & Kötter, 2005). The new science of brain "connectomics" i.e., a map of neural connection, is contributing both to theoretical and computational models of the brain as a complex system (Honey, Kötter, Breakspear, & Sporns, 2007), and experimentally, to new indices and metrics (e.g., nodes, hubs, efficiency, modularity) in order to characterize and scale the functional organization of the

healthy and diseased nervous system (Basset & Bullmore, 2009). This means that a focal ceberal lesion as LGG disturbs the functional and effective connectivity whithin the whole brain, and not only in the restricted area around the tumor, as recently supported by magnetoencephalography study (Bartolomei et al., 2006). Interestingly, these network dysfunctions are related to cognitive processing in LGG patients (Bosma et al., 2008). Indeed, beyond the normal standard neurological examination, extensive neuropsychological assessments performed before surgery in LGG patients have nonetheless often revealed disorders of executive functions, attention, concentration, working memory or emotion (Klein, Duffau, & de Witt Hamer, 2012). Such data illustrate that brain plastic potential has some limitations, which seem to be related to the involvement of the white matter connectivity by the glioma (see below).

3.2. *Intraoperative electrostimulation mapping*

DEM during surgery for LGG within eloquent areas has allowed the direct study of brain plasticity in humans. In this way, cortical stimulation after brain exposure and before any resection has confirmed the frequent existence of a perilesional functional redistribution, due to the slow-growing LGG, as suggested by preoperative neurofunctional imaging. For example, it was observed a reshaping of the language sites around the "Broca's area" invaded by an LGG, with a functional compensation related to recruitment of adjacent regions such as the left ventral premotor cortex, middle frontal gyrus and pars orbitaris of the inferior frontal gyrus (Benzagmout, Gatignol, & Duffau, 2007). Also, the compensation of left insula invaded by LGG thanks to the recruitment of the left inferior frontal gyrus, superior temporal gyrus and putamen, was demonstrated intraoperatively by DEM (Duffau, Taillandier, Gatignol, & Capelle, 2006). In the same vein, DEM showed language reshaping for glioma involving the left supramarginal gyrus, with a recruitment of the rolandic operculum, angular gyrus and posterior part of the superior temporal gyrus (Maldonado et al., 2011). These results fit very well with those reported using neurofunctional imaging previously reviewed.

Regarding intrasurgical plasticity, a very amazing observation concerns the existence of acute functional remapping triggered by the resection itself and taking place within 30–60 min of beginning the surgical act. This type of acute reorganization has been very well documented in the sensorimotor system. In several patients harboring a frontal lesion, although stimulation of the precentral gyrus induced motor responses only at the level of a limited number of cortical sites before resection, an acute unmasking of redundant motor sites located within the same precentral gyrus and eliciting the same movements than the previous adjacent sites when stimulated, was observed immediately following lesion removal (Duffau, 2001). Acute unmasking of redundant somatosensory sites was also regularly observed within the retrocentral gyrus in patients operated on for a parietal glioma. Furthermore, it was equally possible to detect a redistribution within a more larger network involving the whole rolandic region, i.e., with unmasking of functional homologuous located in the precentral gyrus for the first cortical representation and in the retrocentral gyrus for its redundancy (or vice versa)(Duffau et al., 2000). The most likely hypothesis suggests that a local increase of cortical excitability allows an acute unmasking of latent functional redundancies (i.e., multiple cortical representation of the same function), via a decrease of intracortical inhibition (Duffau, 2006b). In agreement with this idea, animal models have shown that focal brain damages induce large zones of enhanced cortical excitability in both the lesioned and the intact hemisphere (Buchkremer-Ratzmann, August, Hagemann, & Witte, 1996). Likewise, human studies have provided evidence that the level of intracortical inhibition is reduced in the damaged hemisphere in stroke patients (Cicinelli et al., 2003). Therefore, it is tempting to speculate that the latent redundant networks revealed by the resection process participate in functional recovery. This idea fits well with the importance of adjacent reorganizations for behavioral recuperation.

3.3. *Postsurgical assessment*

Thanks to these phenomena of preoperative and intraoperative remodeling, surgical series showed that it was possible to remove brain structures classically considered as "eloquent" with functional recovery (Fig. 2) (Duffau et al., 2003a):

Firstly, resection of Broca's area without generating permanent language deficits has been reported (Benzagmout et al., 2007; Lubrano, Draper, & Roux, 2010). Extensive neuropsychological examination following removal of LGG within the pars opercularis and triangularis of the left inferior frontal gyrus confirmed the complete functional recovery (Plaza, Gatignol, Leroy, & Duffau, 2009). Postoperative functional neuroimaging supports the fact that language compensation may be underlain by the recruitment of adjacent regions, in particular the ventral premotor cortex, pars orbitaris of the inferior frontal gyrus, dorso-lateral prefrontal cortex and insula (Duffau, 2012a).

Language compensation following resection of the left dominant temporal region in its posterior and superior part (Wernicke's area) has also been reported. This can be explained by the fact that this complex function is organized in multiple parallel networks, as illustrated in the new model of language previously described (Fig. 1). Consequently, beyond the recruitment of areas adjacent to the surgical cavity, the long-term reshaping might be related to progressive involvement of remote regions within the left dominant hemisphere – such as the supramarginal gyrus, pars triangularis of inferior frontal gyrus or other left frontolateral regions – as well as the controlateral right non-dominant hemisphere due to a transcallosal disinhibition phenomenon (Sarubbo, Le Bars, Moritz-Gasser, & Duffau, 2012).

The insular lobe can also be resected with no permanent deficit (Duffau, Bauchet, Lehéricy, & Capelle, 2001, Duffau et al., 2006). Moreover, it was possible in right non-dominant fronto-temporo-insular LGG involving the deep gray nuclei, to remove the clautrum without any cognitive disorders (despite its role suggested in consciousness) (Duffau, Mandonnet, Gatignol, & Capelle, 2007), and to remove the invaded striatum without inducing neither motor deficit nor movement disorders. This compensation could be explained

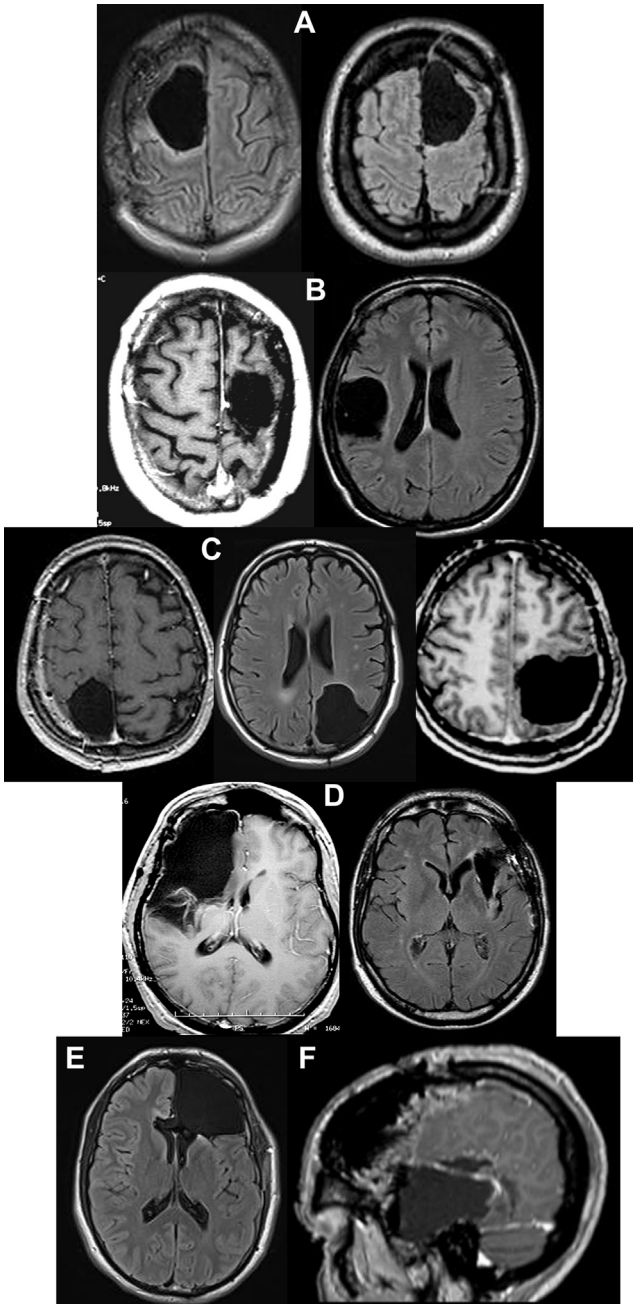

Fig. 2 – Modified from Duffau (2013): Examples of extensive resections of LGG performed within so-called "eloquent" areas using intrasurgical DEM, with preservation the quality of life thanks to brain plasticity: (A) right and left supplementary motor areas (B) left primary motor area of the hand ("knob of the hand") and right primary sensory-motor area of the face (C) parietal lobe in right and left hemispheres, including the primary somatosensory area (D) right paralimbic system and left insula (E) entire left frontal lobe including "Broca's area" and (F) left dominant temporal lobe, including "Wernicke's area".

by a recruitment of parallel subcortical circuits such as pallido-luyso-pallidal, strio-nigro-striate, cortico-strio-nigro-thalamo-cortical and cortico-luysal networks (Duffau, Denvil, & Capelle, 2002a).

Resection of the central area was also reported. It was suggested that following resection of primary sensory-motor area of the face, the recovery of the usual transient central facial palsy (with a potential transitory Foix–Chavany–Marie syndrome when the insula is also involved) was subserved by the disinhibition of the controlateral homologous sites, via transcallosal pathways (Duffau, Karachi, Gatignol, & Capelle, 2003). In addition, on the basis of the existence of multiple cortical motor representations evidenced in humans using functional neuroimaging and intraoperative stimulation mapping (as already mentioned), the compensation of the motor function after resection of primary motor area of the upper limb could be explained by the recruitment of parallel networks within the primary motor cortex – allowing the removal of the upper limb area, eventually using two consecutive surgeries in order to induce durable remapping following the first one (Duffau, Denvil, & Capelle, 2002b) (see below). In the same vein, resection of the primary somatosensory area was made with no permanent deficit. The first results using pre- and postoperative functional neuroimaging have suggested the possible recruitment of "redundant" eloquent sites around the cavity, within the postcentral gyrus (Meunier, Duffau, Garnero, Capelle, & Ducorps, 2000). It is in accordance with the intraoperative electrical mapping data, showing unmasking of redundant somatosensory sites during resection, likely explained by the decrease of the cortico-cortical inhibition. The recruitment of the second somatosensory area or posterior parietal cortex, primary motor area (due to strong anatomo-functional connections between the pre- and retrocentral gyri), and controlateral primary somatosensory area are also possible to explain the recovery (Duffau & Capelle, 2001).

Surgical removal of supplementary motor area is known to induce the occurrence of a specific syndrome, with a transient akinesia, potentially associated with a transient mutism in the dominant hemisphere (Fontaine, Capelle, & Duffau, 2002). However, all patients recovered, probably due to recuitment of the contralateral hemisphere (Krainik et al., 2004). Of note, deficit in bimanual coordination may nonetheless persist (Krainik et al., 2001), raising the question of the preservation of networks subserving motor control (Schucht et al., 2012).

Finally, resection of the (dominant) parietal posterior lobe can be performed without inducing any sequelae, and even with a possible improvement in comparaison to the preoperative status, especially using pointing task (Desmurget et al., 2007).

Taken together, these impressive results demonstrate the huge plastic potential of CNS in adults, breaking with the traditional concept of rigid organization of the brain after the adolescence. Again, the so-called "eloquent" areas should in fact be considered as nodes within a wide network: after their removal, the whole functional network will self-reorganize by dynamical and biological plasticity, and the function will finally be preserved. Indeed, the good clinical status 3 months after surgery, as evidenced by extensive neuropsychological testing as well as the return to a normal social and professional life, argue for efficient plasticity mechanisms for these regions (Moritz-Gasser, Herbet, Maldonado, & Duffau, 2012; Teixidor et al., 2007). Furthermore, such mechanisms were also studied by performing postoperative functional

neuroimaging once the patient has recovered his preoperative functional status. Indeed, as mentioned, postsurgical functional neuroimaging clearly showed a new recruitment of perilesional areas and/or remote regions within the ipsilesional hemisphere and/or a recruitment of controlateral structures (Sarubbo et al., 2012). For example, patients were examined following the resection of gliomas involving the supplementary motor area, which elicited a transient postsurgical syndrome. Functional MRI showed, in comparison to the preoperative imaging, the occurrence of activations of the supplementary motor area and premotor cortex contralateral to the lesion: the contrahemispheric homologous thus participated to the postsurgical functional compensation (Krainik et al., 2004). Interestingly, it seems that these mechanisms of reorganization could be potentiated by postoperative cognitive rehabilitation (Gerhing et al., 2009).

3.4. *Functional remapping over time: evidence by serial surgeries*

Relapse is frequent in LGG. Therefore, a reoperation is often considered several years after the first surgery, in patients who continue to enjoy a normal life (Capelle et al., 2013). An improvement of the extent of resection with represervation of this quality of life is nonetheless possible only if additional plasticity phenomena occurred in the meantime. Interestingly, functional neuroimaging can be easily repeated due to its non-invasive feature, in order to compare the new maps to those obtained before the first surgery. Subtraction between a pre- and postoperative acquisition many years later may shows a possible additional functional reshaping, due to (i) the first resection itself (ii) the postsurgical rehabilitation (iii) the re-growth of the residual LGG (as before the first operation) (Gil Robles, Gatignol, Lehéricy, & Duffau, 2008). Such findings have led to propose a new therapeutic strategy based on multi-stage surgical approach, which beyond the clinical interest for the patient, represents a unique opportunity to study functional remodeling in the same patient over time (Duffau, 2012b). This is due to the fact the second surgery is also conducted using intraoperative cortical and subcortical mapping, in order to validate the mechanisms of brain reshaping suggested by preoperative functional neuroimaging, before to perform the subsequent resection (Martino, Taillandier, Moritz-Gasser, Gatignol, & Duffau, 2009). Such concept of repeated resections enables to demonstrate changes of cortical maps, especially with disappearance of functional epicenters which were detected by DEM during the first surgery, but which elicited no disturbances when stimulated during the reoperation (Duffau et al., 2002b). This was particularly useful to optimize the extent of resection in traditional "critical" areas, such as the left premotor region, rolandic area or Wernicke's area (Duffau, 2005, 2006a, 2008b) (Fig. 3). Again, the functional recovery following the second resection was confirmed by objective postoperative cognitive assessment, in patients who were able to return to a normal life (including work). Thanks to the use of this plastic potential, it was possible to significantly increase the median survival while significantly decreasing the rate of permanent neurological deficits in LGG patients (Duffau, Lopes et al., 2005).

In summary, despite some limitations of brain plasticity (see below), it is worth noting that these conclusions were not made on the basis of a selection of good cases which don't represent the routine, but based on a wide experience about hundreds of patients who underwent maximal resection for diffuse LGG in eloquent areas – already detailed in previous original reports, e.g., a preliminary experience with 103 tumors in eloquent areas in 2003 (Duffau et al., 2003b); then more recently 115 cases with resection within language areas, including Broca's area and Wernicke's area (Duffau, Gatignol et al., 2008); 51 cases with resection involving the insular lobe (Duffau, 2009a); or even 33 cases with resection within the central area (Schucht, Ghareeb, and Duffau, 2013). Indeed, this subgroup of patients who underwent surgical resection for a diffuse LGG involving the central region was compared with a control cohort of 31 patients with frontal LGG, which did not invade the central area. In spite of a lower rate of seizure freedom in the "central cohort", the rate of mild neurological deficits was low and similar for both groups, demonstrating the concrete role of brain plasticity for central surgery (Shucht et al., 2013). In this state of mind, a recent meta-analysis reported 3230 patients (from 41 publications) who benefited from a surgical removal of gliomas in eloquent areas (including the central and language areas) using intraoperative stimulation mapping, with less than 3.5% of late severe deficits (despite a high rate of transient postoperative worsening). These data show the reproducibility and reliability of the use of cerebral plasticity in numerous surgical teams worldwide (De Witt, Robles, Zwinderman, Duffau, and Berger, 2012). Finally, the quantity and quality of recovery have been extensively reported, showing a high level of functional recovery – using different objective criteria, such as the Karnofsky Performance Scale score and Boston Diagnostic Aphasia Examination (see for instance Mandonnet et al., 2007; Duffau, Gatignol et al., 2008; Maldonado et al., 2011; Vidorreta et al., 2011); the assessment of working memory, executive functions as well as quality of life using EORTC QLQ C30, Brain Module BN 20 and the Beck depression inventory (Blonski et al., 2012; Teixidor et al., 2007); and even the naming task, reaction time (lexical access speed) and return to work (Moritz-Gasser et al., 2012).

4. Limitation of brain plasticity: the crucial role of axonal connectivity

Although plastic potential is high at the cortical level, subcortical plasticity is low, implying that axonal connectivity should be preserved to allow postlesional compensation. Indeed, lessons from stoke studies have thaught that a damage of the white matter pathways generated a more severe neurological worsening than lesions of the cortex. By combining cortical function and axonal connectivity, an updated model of cerebral processing has recently been proposed, moving from a traditional "localizationist" view to a "hodotopical" framework (de Benedictis & Duffau, 2011). In pathology, according to this new concept, a topological mechanism refers to a dysfunction of the cortex, whereas a hodological mechanism refers to dysfunction related to connecting pathways (Catani, 2007). Thus, it is mandatory to take

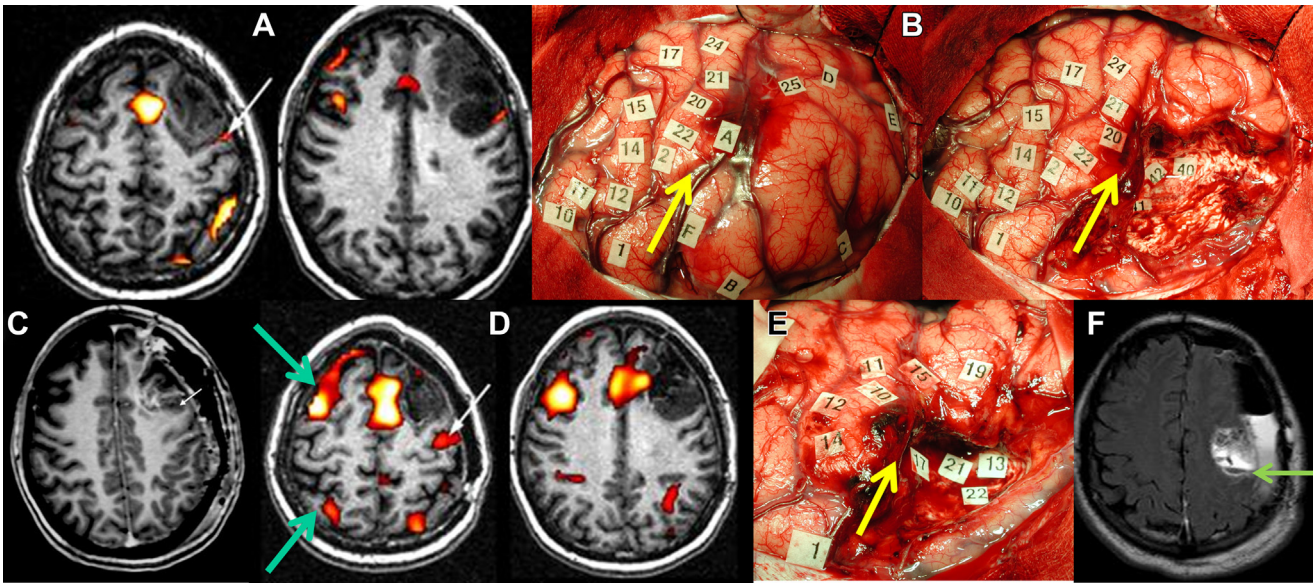

Fig. 3 – Modified from Gil Robles et al. (2008): Illustration of remapping in the same patient demonstrated by serial mappings (A) Preoperative language functional MRI in a patient without deficit, bearing an LGG which infiltrates the left premotor area: language activation are near the posterior part of the glioma, within the precentral sulcus (white arrow). (B) Intrasurgical views before (left) and after (right) removal of the tumor, delineated by letter tags. DEM shows a reshaping of the functional maps, with a recruitment of perilesional language sites, enabling a subtotal resection with nevertheless a posterior residue due to involvement of critical areas (number tags). The yellow arrow shows the precentral sulcus, demonstrating that it was not possible to remove the part of the LGG within the precentral gyrus (C) Immediate postoperative enhanced T1-weighted MRI showing the residue (arrow), in front of the precentral gyrus (D) Postoperative language functional MRI 4 years after the first functional MRI, showing a recruitment of the controlateral hemisphere (green arrows), and the posterior displacement of activation previously located at the posterior border of the tumor (within the precentral sulcus), now within the central sulcus on this new imaging (white arrow) (E) Intraoperative view during the second surgery, confirming the functional remapping, and making possible a more extensive glioma resection posteriorly, with no permanent deficit. Again, the yellow arrow shows the precentral sulcus, demonstrating that, this time, it was possible to remove a part of the glioma involving the precentral gyrus (F) Immediate postsurgical axial Fluid attenuated inversion recovery (FLAIR)-weighted MRI (3 h after operation) confirming the increase of the extent of resection within the left precentral gyrus, thanks to functional reshaping (the green arrow shows the central sulcus). The follow-up is now 11 years since the first surgery, with no reccurrence since the second operation, in a patient enjoying a normal social and professional life.

into account the complex functioning of a large-scale distributed cortico-subcortical network to understand both its physiology as well as the functional consequences of a lesion in this circuit – with possible different deficits depending on the location and the extent of the damage (e.g., purely cortical, or purely subcortical, or both).

Recently, it was proposed the elaboration of a probabilistic postsurgical residue atlas computed on a series of patients who underwent incomplete resection for an LGG on the basis of intraoperative DEM (Ius, Angelini, Thiebaut de Schotten, Mandonnet, & Duffau, 2011). The anatomo-functional correlations obtained by combining the intrasurgical functional data with postoperative anatomical MRI findings provided both a greater understanding of the functional limits of surgical removal, and new insights into the potentials and limitations of brain plasticity. Especially, this probabilistic atlas highlighted the crucial role of the axonal pathways in the reorganization of the brain after a lesion. It provided a general framework to establish anatomo-functional correlations by computing for each brain voxel its probability to be left – due to its functional role – on the postoperative MRI. Its overlap with the cortical Montral Neurological Institute (MNI) template and a diffusion tensor imaging atlas offered a unique tool to analyze the potentialities and the limitations of inter-individual variability and plasticity, both for cortical areas and axonal pathways. It was observed as a rule a low probability of residual tumors on the cortical surface, whereas most of the regions with high probability of residual tumor were located in the deep white matter. Thus, projection and association axonal pathways seem to play a critical role in the proper functioning of the brain. In other words, the functions subserved by long-range axonal pathways seem to be less subject to inter-individual variability and reorganization than cortical sites (Ius et al., 2011). Consequently, these pathways define the surgical deep limits (Gil Robles & Duffau, 2010) and, since LGG infiltrate these tracts (Mandonnet, Capelle, & Duffau, 2006), they constitute the main obstacle to radical surgical resection. For example, it was demonstrated that the plastic potential of the ventral premotor cortex was limited (crucial role in speech articulation), and that this limitation was due to a subcortical anatomical constraint, namely the necessity for this cortical area to remain connected to the

lateral part of the superior longitudinal fascicle (van Geemen et al., 2013). This highlights the importance of subcortical connectivity in shaping cortical reorganization following perturbations of normal function (Papagno et al., 2011).

Two questions arise on why there is no inter-individual variability for these structures and why their resection cannot be efficiently compensated by plasticity phenomena. For some of these areas, the explanation could be that they act as input or output areas: input sites convey or are the first relay of information entering the brain, whereas output sites are the last relay or the fiber tracts sending information outside the brain. These areas include the primary motor and somatosensory areas, the cortico-spinal and thalamo-cortical tracts and the optic radiations, that is, the projection fibers. These areas are mainly unimodal and probably organized serially. The absence of parallel alternative pathway explains the impossibility to restore their function after any damage (Duffau, 2009b).

For all other areas, their non-resectability should be analyzed within a network perspective. High-order cognitive processes are mediated by short- and long-range networks, with cortical epicenters connected by U-shaped fibers, associative and commissural pathways and a particular network topology (like the "small word" one) is required to allow proper synchronization between several distant areas (Stam, 2010). The link between the function and the anatomy is not as simple as for input–output areas: in fact, as already mentioned, a local lesion can disturb a whole network topology, which in turn could ultimately hamper the function sustained by this network. It has been hypothesized that, in the left dominant hemisphere, subcortical structures like the IFOF and the arcuate fascicle are non-resectable because their lesion would cause so major changes in the network topology that the dynamical plasticity potential would be overwhelmed. Interestingly, these areas are considered as "hubs" in revisited models of cognition – e.g., the posterior part of the left dominant superior temporal gyrus and its junction with the inferior parietal lobule (Hickok & Poeppel, 2007) – and they seem to have a limited plastic potential. Indeed, these functional epicenters allow a plurimodal integration of multiple data coming from the unimodal areas. In a step forward, this integration may lead to the conceptualization, performed at the level of a wide network which includes the hubs. As a consequence, these hubs are interconnected by subcortical pathways, themselves crucial for brain function, such as for instance the arcuate fascicle or the IFOF which enables a direct communication between the posterior temporal and frontal plurimodal regions. The reproducibility of these results, despite the inter-individual anatomo-functional variability and plastic mechanisms, may lead to suggest the existence of a "minimal common brain", necessary for the basic cognitive functions – even if likely not sufficient for more complex functions such as multi-processing. This hypothesis is in good agreement with recent bio-mathematical models, analyzing the effect of a simulated focal lesion on the whole brain network topology (Alstott, Breakspear, Hagmann, Cammoun, & Sporns, 2009). Note that for these areas, even biological plasticity – which has been shown to offer an axonal rewiring in animal models (Dancause et al., 2005) – would fail on the long–term to repair the connectivity required to rebuild an effective network topology, hence a functional network. Indeed, although different patterns of subcortical plasticity have recently been identified (Szalisznyo et al., 2013), namely unmasking of perilesional latent networks, recruitment of accessory pathways, introduction of additional relays within neuron-synaptic circuits, and involvement of parallel long–distance association pathways (e.g., resection of the anterior part of the left inferior longitudinal fascicle and left uncinate fascicle, because they can be compensated by the "direct ventral semantic pathways" subserved by the IFOF), the real capacity to build a new structural connectivity leading to functional recovery was not yet demonstrated in humans (Duffau, 2009b).

In practice, it means that neuroscientits should improve their knowledge concerning white matter circuitery, since brain plasticity seems to be possible only on the condition that the subcortical connectivity is preserved (Duffau, Thiebaut de Schotten, & Mandonnet, 2008), to allow spatial communication and temporal synchronization among large interconnected networks – according to the principle of connectomics.

5. Conclusions and perspectives

Combination of serial peri-operative functional neuroimaging and on-line intraoperative DEM has enabled one to elaborate new individual and integrative models of functioning of neurono-synaptic circuits. Such networking models have resulted in a better knowledge of the dynamic potential of spatio-temporal reorganization of the parallel and interactive networks in adults, namely the mechanisms of neuroplasticity – but also in a better understading of its limitation, mainly represented by the subcortical connectivity. The next step is now to use bio-mathematical models able to examine brain functional interaction through connectomics, with the purpose to calculate an index of plastic potential at the individual level. Such index would reflect the ratio between the potential of cerebral remapping and the subcortical constraints limiting such potential. It may have major clinical implications, by representing a predictive factor of recovery in patients with brain injury as well as a precious parameter to plan surgical (re)operations for cerebral tumors.

REFERENCES

Alstott, J., Breakspear, M., Hagmann, P., Cammoun, L., & Sporns, O. (2009). Modeling the impact of lesions in the human brain. *PLoS Computational Biology*, 5(6), e1000408.

Bartolomei, F., Bosma, I., Klein, M., Baayen, J. C., Reijneveld, J. C., Postma, T. J., et al. (2006). How do brain tumors alter functional connectivity? A magnetoencephalography study. *Annals of Neurology*, 59(1), 128–138.

Basset, D. S., & Bullmore, E. T. (2009). Human brain networks in health and disease. *Current Opinion in Neurology*, 22(4), 340–347.

Bello, L., Gallucci, M., Fava, M., Carrabba, G., Giussani, C., Acerbi, F., et al. (2007). Intraoperative subcortical language tract mapping guides surgical removal of gliomas involving speech areas. *Neurosurgery*, 60(1), 67–80.

Bello, L., Gambini, A., Castellano, A., Carrabba, G., Acerbi, F., Fava, E., et al. (2008). Motor and language DTI Fiber Tracking

combined with intraoperative subcortical mapping for surgical removal of gliomas. *NeuroImage, 39*(1), 369–382.
de Benedictis, A., & Duffau, H. (2011). Brain hodotopy: from esoteric concept to practical surgical applications. *Neurosurgery, 68*(6), 1709–1723.
Benzagmout, M., Gatignol, P., & Duffau, H. (2007). Resection of World Health Organization Grade II gliomas involving Broca's area: methodological and functional considerations. *Neurosurgery, 61*(4), 741–752.
Blonski, M., Taillandier, L., Herbet, G., Maldonado, I. L., Beauchesne, P., Fabbro, M., et al. (2012). Combination of neoadjuvant chemotherapy followed by surgical resection as a new strategy for WHO grade II gliomas: a study of cognitive status and quality of life. *Journal of Neurooncology, 106*(2), 353–366.
Bosma, I., Douw, L., Bartolomei, F., Heimans, J. J., van Dijk, B. W., Postma, T. J., et al. (2008). Synchronized brain activity and neurocognitive function in patients with low-grade glioma: a magnetoencephalography study. *Neuro Oncology, 10*(5), 734–744.
Buchkremer-Ratzmann, I., August, M., Hagemann, G., & Witte, O. W. (1996). Electrophysiological transcortical diaschisis after cortical photothrombosis in rat brain. *Stroke, 27*(6), 1105–1109.
Capelle, L., Fontaine, D., Mandonnet, E., Taillandier, L., Golmard, J. L., Bauchet, L., et al. (2013). Spontaneous and therapeutic prognostic factors in adult hemispheric World Health Organization Grade II gliomas: a series of 1097 cases. *Journal of Neurosurgery, 118*(6), 1157–1168.
Catani, M. (2007). From hodology to function. *Brain, 130*(Pt 3), 602–605.
Catani, M., Jones, D. K., & ffytche, D. H. (2005). Perisylvian language networks of the human brain. *Annals of Neurology, 57*(1), 8–16.
Cicinelli, P., Pasqualetti, P., Zaccagnini, M., Traversa, R., Oliveri, M., & Rossini, P. M. (2003). Interhemispheric asymmetries of motor cortex excitability in the postacute stroke stage: a paired-pulse transcranial magnetic stimulation study. *Stroke, 34*(11), 2653–2658.
Dancause, N., Barbay, S., Frost, S. B., Plautz, E. J., Chen, D., Zoubina, E. V., et al. (2005). Extensive cortical rewiring after brain injury. *Journal of Neuroscience, 25*(44), 10167–10179.
Desmurget, M., Bonnetblanc, F., & Duffau, H. (2007). Contrasting acute and slow growing lesions: a new door to brain plasticity. *Brain, 130*(Pt 4), 898–914.
De Witt Hamer, P., Moritz-Gasser, S., Gatignol, P., & Duffau, H. (2011). Is the human left middle longitudinal fascicle essential for language? A brain electrostimulation study. *Human Brain Mapping, 32*(6), 962–973.
De Witt Hamer, P., Robles, S. G., Zwinderman, A. H., Duffau, H., & Berger, M. S. (2012). Impact of intraoperative stimulation brain mapping on glioma surgery outcome: a meta-analysis. *Journal of Clinical Oncology, 30*(20), 2559–2565.
Duffau, H. (2001). Acute functional reorganisation of the human motor cortex during resection of central lesions: a study using intraoperative brain mapping. *Journal of Neurology, Neurosurgery and Psychiatry, 70*(4), 506–513.
Duffau, H. (2005). Lessons from brain mapping in surgery for low-grade glioma: insights into associations between tumour and brain plasticity. *Lancet Neurology, 4*(8), 476–486.
Duffau, H. (2006a). New concepts in surgery of WHO grade II gliomas: functional brain mapping, connectionism and plasticity. *Journal of Neurooncology, 79*(1), 77–115.
Duffau, H. (2006b). Brain plasticity: from pathophysiological mechanisms to therapeutic applications. *Journal of Clinical Neuroscience, 13*(9), 885–897.
Duffau, H. (2008a). The anatomo-functional connectivity of language revisited: new insights provided by electrostimulation and tractography. *Neuropsychologia, 46*(4), 927–934.
Duffau, H. (2008b). Brain plasticity and tumors. *Advances and Technical Standards in Neurosurgery, 3*, 3–33.
Duffau, H. (2009a). A personal consecutive series of surgically treated 51 cases of insular WHO Grade II glioma: advances and limitations. *Journal of Neurosurgery, 110*(4), 696–708.
Duffau, H. (2009b). Does post-lesional subcortical plasticity exist in the human brain? *Neuroscience Research, 65*(2), 131–135.
Duffau, H. (2011). In H. Duffau (Ed.), *Brain mapping: From neural basis of cognition to surgical applications*. New York: Springer Wien.
Duffau, H. (2012a). The "frontal syndrome" revisited: lessons from electrostimulation mapping studies. *Cortex, 48*(1), 120–131.
Duffau, H. (2012b). The challenge to remove diffuse low-grade gliomas while preserving brain functions. *Acta Neurochirurgica (Wien), 154*(4), 569–574.
Duffau, H. (2013). In H. Duffau (Ed.), *Diffuse low-grade gliomas in adults natural history, interaction with the brain, and new individualized therapeutic strategies*. London: Springer.
Duffau, H., Bauchet, L., Lehéricy, S., & Capelle, L. (2001). Functional compensation of the left dominant insula for language. *NeuroReport, 12*(10), 2159–2163.
Duffau, H., & Capelle, L. (2001). Functional recovery following lesions of the primary somatosensory fields. Study of the compensatory mechanisms. *Neurochirurgie, 47*(6), 557–563.
Duffau, H., & Capelle, L. (2004). Preferential brain locations of low-grade gliomas. *Cancer, 100*(12), 2622–2626.
Duffau, H., Capelle, L., Denvil, D., Gatignol, P., Sichez, N., Lopes, M., et al. (2003). The role of dominant premotor cortex in language: a study using intraoperative functional mapping in awake patients. *NeuroImage, 20*(4), 1903–1914.
Duffau, H., Capelle, L., Denvil, D., Sichez, N., Gatignol, P., Lopes, M., et al. (2003a). Functional recovery after surgical resection of low grade gliomas in eloquent brain: hypothesis of brain compensation. *Journal of Neurology, Neurosurgery and Psychiatry, 74*(7), 901–907.
Duffau, H., Capelle, L., Denvil, D., Sichez, N., Gatignol, P., Taillandier, L., et al. (2003b). Usefulness of intraoperative electrical subcortical mapping during surgery for low-grade gliomas located within eloquent brain regions: functional results in a consecutive series of 103 patients. *Journal of Neurosurgery, 98*(4), 764–778.
Duffau, H., Capelle, L., Sichez, N., Denvil, D., Bitar, A., Sichez, J. P., et al. (2002). Intraoperative mapping of the subcortical language pathways using direct stimulations. An anatomo-functional study. *Brain, 125*(Pt 1), 199–214.
Duffau, H., Denvil, D., & Capelle, L. (2002a). Absence of movement disorders after surgical resection of glioma invading the right striatum. *Journal of Neurosurgery, 97*(2), 363–369.
Duffau, H., Denvil, D., & Capelle, L. (2002b). Long term reshaping of language, sensory and motor maps following glioma resection: a new parameter to integrate in the surgical strategy. *Journal of Neurology, Neurosurgery and Psychiatry, 72*(4), 511–516.
Duffau, H., Gatignol, P., Denvil, D., Lopes, M., & Capelle, L. (2003). The articulatory loop: study of the subcortical connectivity by electrostimulation. *NeuroReport, 14*(15), 2005–2008.
Duffau, H., Gatignol, P., Mandonnet, E., Capelle, L., & Taillandier, L. (2008). Intraoperative subcortical stimulation mapping of language pathways in a consecutive series of 115 patients with Grade II glioma in the left dominant hemisphere. *Journal of Neurosurgery, 109*(3), 461–471.
Duffau, H., Gatignol, P., Mandonnet, E., Peruzzi, P., Tzourio-Mazoyer, N., & Capelle, L. (2005). New insights into the anatomo-functional connectivity of the semantic system: a study using cortico-subcortical stimulations. *Brain, 128*(Pt 4), 797–810.
Duffau, H., Gatignol, P., Moritz-Gasser, S., & Mandonnet, E. (2009). Is the left uncinate fasciculus essential for language? A

cerebral stimulation study. *Journal of Neurology, 256*(3), 382–389.
Duffau, H., Karachi, C., Gatignol, P., & Capelle, L. (2003). Transient Foix-Chavany-Marie syndrome after surgical resection of a right insulo-opercular low-grade glioma. *Neurosurgery, 53*(2), 426–431.
Duffau, H., Lopes, M., Arthuis, F., Bitar, A., Sichez, J. P., van Effenterre, R., et al. (2005). Contribution of intraoperative electrical stimulations in surgery of low grade gliomas: a comparative study between two series without (1985-96) and with (1996-2003) functional mapping in the same institution. *Journal of Neurology, Neurosurgery and Psychiatry, 76*(6), 845–851.
Duffau, H., Mandonnet, E., Gatignol, P., & Capelle, L. (2007). Functional compensation of the claustrum: lessons from low-grade glioma surgery. *Journal of Neurooncology, 81*(3), 327–329.
Duffau, H., Moritz-Gasser, S., & Mandonnet, E. (2013 Jul 15). A re-examination of neural basis of language processing: proposal of a dynamic hodotopical model from data provided by brain stimulation mapping during picture naming. *Brain and Language*. pii: S0093-934X(13)00109-0. http://dx.doi.org/10.1016/j.bandl.2013.05.011 (Epub ahead of print).
Duffau, H., Sichez, J. P., & Lehéricy, S. (2000). Intraoperative unmasking of brain redundant motor sites during resection of a precentral angioma. Evidence using direct cortical stimulations. *Annals of Neurology, 47*(1), 132–135.
Duffau, H., Taillandier, L., Gatignol, P., & Capelle, L. (2006). The insular lobe and brain plasticity: lessons from tumor surgery. *Clinical Neurology and Neurosurgery, 108*(6), 543–548.
Duffau, H., Thiebaut de Schotten, M., & Mandonnet, E. (2008). White matter functional connectivity as an additional landmark for dominant temporal lobectomy. *Journal of Neurology, Neurosurgery and Psychiatry, 79*(5), 492–495.
Fontaine, D., Capelle, L., & Duffau, H. (2002). Somatotopy of the supplementary motor area: evidence from correlation of the extent of surgical resection with the clinical patterns of deficit. *Neurosurgery, 50*(2), 297–303.
Gaillard, R., Naccache, L., Pinel, P., Clémenceau, S., Volle, E., Hasboun, D., et al. (2006). Direct intracranial, FMRI, and lesion evidence for the causal role of left inferotemporal cortex in reading. *Neuron, 50*(2), 191–204.
Gatignol, P., Capelle, L., Le Bihan, R., & Duffau, H. (2004). Double dissociation between picture naming and comprehension: an electrostimulation study. *NeuroReport, 15*(1), 191–195.
van Geemen, K., Herbet, G., Moritz-Gasser, S., & Duffau, H. (2013 Apr 24). Limited plastic potential of the left ventral premotor cortex in speech articulation: Evidence from intraoperative awake mapping in glioma patients. *Human Brain Mapping*. http://dx.doi.org/10.1002/hbm.22275 [Epub ahead of print].
Gehring, K., Sitskoorn, M. M., Gundy, C. M., Sikkes, S. A., Klein, M., Postma, T. J., et al. (2009). Cognitive rehabilitation in patients with gliomas: a randomized, controlled trial. *Journal of Clinical Oncology, 27*(22), 3712–3722.
Geschwind, N. (1970). The organization of language and the brain. *Science, 170*(3961), 940–944.
Gil Robles, S., Gatignol, P., Capelle, L., Mitchell, M. C., & Duffau, H. (2005). The role of dominant striatum in language: a study using intraoperative electrical stimulations. *Journal of Neurology, Neurosurgery and Psychiatry, 76*(7), 940–946.
Gil Robles, S., Gatignol, P., Lehéricy, S., & Duffau, H. (2008). Long-term brain plasticity allowing multiple-stages surgical approach for WHO grade II gliomas in eloquent areas: a combined study using longitudinal functional MRI and intraoperative electrical stimulation. *Journal of Neurosurgery, 109*(4), 615–624.
Gil Robles, S., & Duffau, H. (2010). Surgical management of World Health Organization Grade II gliomas in eloquent areas: the necessity of preserving a margin around functional structures? *Neurosurgical Focus, 28*(2), E8.
Gil Robles, S., Carvallo, A., Jimenez Mdel, M., Gomez Caicoya, A., Martinez, R., Ruiz-Ocaña, C., et al. (2013). Double dissociation between visual recognition and picture naming: a study of the visual language connectivity using tractography and brain stimulation. *Neurosurgery, 72*(2), 678–686.
Gras-Combes, G., Moritz-Gasser, S., Herbet, G., & Duffau, H. (2012). Intraoperative subcortical electrical mapping of optic radiations in awake surgery for glioma involving visual pathways. *Journal of Neurosurgery, 117*(3), 466–473.
Hickok, G., & Poeppel, D. (2007). The cortical organization of speech processing. *Nature Reviews in Neuroscience, 8*(5), 393–402.
Holland, R., & Lambon-Ralph, M. A. (2010). The anterior temporal lobe semantic hub is a part of the language neural network: selective disruption of irregular past tense verb by rTMS. *Cerebral Cortex, 20*(12), 2771–2775.
Honey, C. J., Kötter, R., Breakspear, M., & Sporns, O. (2007). Network structure of cerebral cortex shapes functional connectivity on multiple time scales. *Proceedings of the National Academy of Sciences of the United States of America, 104*(24), 10240–10245.
Ius, T., Angelini, E., Thiebaut de Schotten, M., Mandonnet, E., & Duffau, H. (2011). Evidence for potentials and limitations of brain plasticity using an atlas of functional resectability of WHO grade II gliomas: towards a "minimal common brain". *NeuroImage, 56*(3), 992–1000.
Keidel, J. L., Welbourne, S. R., & Lambon Ralph, M. A. (2010). Solving the paradox of the equipotential and modular brain: a neurocomputational model of stroke vs. Slow-growing glioma. *Neuropsychologia, 48*(6), 1716–1724.
Klein, M., Duffau, H., & de Witt Hamer, P. C. (2012). Cognition and resective surgery for diffuse infiltrative glioma: an overview. *Journal of Neurooncology, 108*(2), 309–318.
Krainik, A., Lehéricy, S., Duffau, H., Vlaicu, M., Poupon, F., Capelle, L., et al. (2001). Role of the supplementary motor area in motor deficit following medial frontal lobe surgery. *Neurology, 57*(5), 871–878.
Krainik, A., Duffau, H., Capelle, L., Cornu, P., Boch, A. L., Mangin, J. F., et al. (2004). Role of the healthy hemisphere in recovery after resection of the supplementary motor area. *Neurology, 62*(8), 1323–1332.
Lubrano, V., Draper, L., & Roux, F. E. (2010). What makes surgical tumor resection feasible in Broca's area? Insights into intraoperative brain mapping. *Neurosurgery, 66*(5), 868–875.
Maldonado, I. L., Moritz-Gasser, S., & Duffau, H. (2011). Does the left superior longitudinal fascicle subserve language semantics? A brain electrostimulation study. *Brain Structure and Function, 216*(3), 263–264.
Maldonado, I. L., Moritz-Gasser, S., de Champfleur, N. M., Bertram, L., Moulinié, G., & Duffau, H. (2011). Surgery for gliomas involving the left inferior parietal lobule: new insights into the functional anatomy provided by stimulation mapping in awake patients. *Journal of Neurosurgery, 115*(4), 770–779.
Mandonnet, E., Capelle, L., & Duffau, H. (2006). Extension of paralimbic low grade gliomas: toward an anatomical classification based on white matter invasion patterns. *Journal of Neurooncology, 78*(2), 179–185.
Mandonnet, E., Nouet, A., Gatignol, P., Capelle, L., & Duffau, H. (2007). Does the left inferior longitudinal fasciculus play a role in language? A brain stimulation study. *Brain, 130*(Pt 3), 623–629.
Mandonnet, E., Gatignol, P., & Duffau, H. (2009). Evidence for an occipito-temporal tract underlying visual recognition in picture naming. *Clinical Neurology and Neurosurgery, 111*(7), 601–605.
Mandonnet, E., Winkler, P. A., & Duffau, H. (2010). Direct electrical stimulation as an input gate into brain functional networks: principles, advantages and limitations. *Acta Neurochirurgica (Wien), 152*(2), 185–193.

Martino, J., Taillandier, L., Moritz-Gasser, S., Gatignol, P., & Duffau, H. (2009). Re-operation is a safe and effective therapeutic strategy in recurrent WHO grade II gliomas within eloquent areas. *Acta Neurochirurgica (Wien), 151*(5), 427–436.

Martino, J., Brogna, C., Gil Robles, S., Vergani, F., & Duffau, H. (2010). Anatomic dissection of the inferior fronto-occipital fasciculus revisited in the lights of brain stimulation data. *Cortex, 46*(5), 691–699.

Martino, J., De Witt Hamer, P. C., Berger, M. S., Lawton, M. T., Arnold, C. M., de Lucas, E. M., et al. (2013). Analysis of the subcomponents and cortical terminations of the perisylvian superior longitudinal fasciculus: a fiber dissection and DTI tractography study. *Brain Structure and Function, 218*(1), 105–121.

Meunier, S., Duffau, H., Garnero, L., Capelle, L., & Ducorps, A. (2000). Comparison of the somatosensory cortical mapping of the fingers using a whole head magnetoencephalography (MEG) and direct electrical stimulations during surgery in awake patients. *NeuroImage, 11*(5), S868.

Moritz-Gasser, S., & Duffau, H. (2009). Cognitive processes and neural basis of language switching: proposal of a new model. *NeuroReport, 20*(18), 1577–1580.

Moritz-Gasser, S., Herbet, G., Maldonado, I. L., & Duffau, H. (2012). Lexical access speed is significantly correlated with the return to professional activities after awake surgery for low-grade gliomas. *Journal of Neurooncology, 107*(3), 633–641.

Moritz-Gasser, S., Herbet, G., & Duffau, H. (2013 Aug). Mapping the connectivity underlying multimodal (verbal and non-verbal) semantic processing: a brain electrostimulation study. *Neuropsychologia, 51*(10), 1814–1822.

Ojemann, G., Ojemann, J., Lettich, E., & Berger, M. (1989). Cortical language localization in left, dominant hemisphere. An electrical stimulation mapping investigation in 117 patients. *Journal of Neurosurgery, 71*(3), 316–326.

Papagno, C., Gallucci, M., Casarotti, A., Castellano, A., Falini, A., Fava, E., et al. (2011). Connectivity constraints on cortical reorganization of neural circuits involved in object naming. *NeuroImage, 55*(3), 1306–1313.

Plaza, M., Gatignol, P., Cohen, H., Berger, B., & Duffau, H. (2008). A discrete area within the left dorsolateral prefrontal cortex involved in visual-verbal incongruence judgment. *Cerebral Cortex, 18*(6), 1253–1259.

Plaza, M., Gatignol, P., Leroy, M., & Duffau, H. (2009). Speaking without Broca's area after tumor resection. *Neurocase, 15*(4), 294–310.

Sarubbo, S., Le Bars, E., Moritz-Gasser, S., & Duffau, H. (2012). Complete recovery after surgical resection of left Wernicke's area in awake patient: a brain stimulation and functional MRI study. *Neurosurgical Review, 35*(2), 287–292.

Sarubbo, S., De Benedictis, A., Maldonado, I. L., Basso, G., & Duffau, H. (2013). Frontal terminations for the inferior fronto-occipital fascicle: anatomical dissection, DTI study and functional considerations on a multi-component bundle. *Brain Structure and Function, 218*(1), 21–37.

Schucht, P., Moritz-Gasser, S., Herbet, G., Raabe, A., & Duffau, H. (2012 Jun 19). Subcortical electrostimulation to identify network subserving motor control. *Human Brain Mapping*. http://dx.doi.org/10.1002/hbm.22122 (Epub ahead of print).

Schucht, P., Ghareeb, F., & Duffau, H. (2013 Aug). Surgery for low-grade glioma infiltrating the central cerebral region: location as a predictive factor for neurological deficit, epileptological outcome, and quality of life. *Journal of Neurosurgery, 119*(2), 318–323.

Sporns, O., Tononi, G., & Kötter, R. (2005). The human connectome: a structural description of the human brain. *PLoS Computational Biology, 1*(4), e42.

Stam, C. J. (2010). Characterization of anatomical and functional connectivity in the brain: a complex networks perspective. *International Journal of Psychophysiology, 77*(3), 186–194.

Szaliszny, K., Silverstein, D. N., Duffau, H., & Smits, A. (2013 Jul 26). Pathological neural attractor dynamics in slowly growing gliomas supports an optimal time frame for white matter plasticity. *PLoS One, 8*(7), e69798.

Teixidor, P., Gatignol, P., Leroy, M., Masuet-Aumatell, C., Capelle, L., & Duffau, H. (2007). Assessment of verbal working memory before and after surgery for low-grade glioma. *Journal of Neurooncology, 81*(3), 305–313.

Thiebaut de Schotten, M., Urbanski, M., Duffau, H., Volle, E., Levy, R., Dubois, B., et al. (2005). Direct evidence for a parietal-frontal pathway subserving spatial awareness in humans. *Science, 309*(5744), 2226–2228.

Thiebaut de Schotten, M., Dell'Acqua, F., Valabregue, R., & Catani, M. (2012). Monkey to human comparative anatomy of the frontal lobe association tracts. *Cortex, 48*(1), 82–96.

Varela, F., Lachaux, J. P., Rodriguez, E., & Martinerie, J. (2001). The brainweb: Phase synchronization and large-scale integration. *Nature Reviews in Neuroscience, 2*(4), 229–239.

Vidorreta, J. G., Garcia, R., Moritz-Gasser, S., & Duffau, H. (2011). Double dissociation between syntactic gender and picture naming processing: a brain stimulation mapping study. *Human Brain Mapping, 32*(3), 331–340.

Vigneau, M., Beaucousin, V., Herve, P. Y., Duffau, H., Crivello, F., Houdé, O., et al. (2006). Meta-analyzing left hemisphere language areas: phonology, semantics, and sentence processing. *NeuroImage, 30*(4), 1414–1432.

Werner, G. (2007). Brain dynamics across levels of organization. *Journal of Physiology Paris, 101*(4–6), 273–279.