Nuancing the Limitations of Axonal Plasticity in World Health Organization Grade II Gliomas: White Matter Tracts Compensation Is Driven by Cortical Remodeling

Hugues Duffau, MD, PhD *‡

*Department of Neurosurgery, Gui de Chauliac Hospital, Montpellier University Medical Center, Montpellier, France; ‡U1191 Laboratory, Team "Plasticity of Central Nervous System, Stem Cells and Glial Tumors", National Institute for Health and Medical Research (INSERM), Institute of Functional Genomics, University of Montpellier, Montpellier, France

Correspondence: Hugues Duffau, MD, PhD, Department of Neurosurgery, Gui de Chauliac Hospital, Montpellier University Medical Center, 80 Ave Augustin Fliche, Montpellier 34295, France. Email: h-duffau@chu-montpellier.fr

Received, January 08, 2023; **Accepted,** February 28, 2023; **Published Online,** April 19, 2023.

© Congress of Neurological Surgeons 2023. All rights reserved.

Diffuse World Health Organization grade II glioma (GIIG) is a slow-growing brain cancer that migrates along the white matter (WM) tracts. Neuroplastic changes were described in reaction to GIIG progression, opening the window to extensive cerebral surgical resection in patients able to resume an active life with no functional consequences. However, atlases of cortico-subcortical neural plasticity emphasized the limited potential of axonal reorganization. Yet, the removal of WM involved by GIIG can be possible, at least to some extent, without generating permanent neurological disturbances. Here, the aim was to discuss mechanisms underlying functional compensation which make feasible resection of the subcortical component of GIIG and to propose a new model of adaptative neural reconfiguration at the level of the axonal connectivity. In this model, 2 parts of the WM tracts are considered: (1) the stem of the bundle that represents the actual limitation of plastic potential, as supported by reproducible behavioral disorders elicited by intraoperative axonal electrostimulation mapping (ESM) and (2) the terminations/origins of the bundle that may no longer be critical in case of functional reallocation of the cortex to/from which these WM fibers run—thus inducing no behavioral troubles during direct ESM. Understanding that a certain degree of axonal compensation in specific portions of the tracts is driven by cortical remodeling may enable to rethink the concept of WM plasticity and to refine the preoperative estimation of extent of resection for GIIG. Identifying eloquent fibers by ESM, especially their convergence in the depth, is essential to achieve an individualized connectome-based resection.

KEY WORDS: WHO grade II glioma, Surgery, Awake mapping, Neuroplasticity, White matter tracts

Neurosurgery 93:E85–E91, 2023 https://doi.org/10.1227/neu.0000000000002508

Diffuse World Health Organization grade II glioma (GIIG)[1] is a slow-growing brain cancer that invades the parenchyma by migrating along the white matter (WM) tracts.[2] It usually arises in young adults with few functional consequences, who enjoy normal familial and professional activities.[3] Neuroplasticity enabled extensive brain surgical resections while preserving quality of life, including for GIIG within "eloquent" structures.[4,5] The slow time course of GIIG generates reactional redistribution of the neural circuits over years.[6] Such compensatory phenomena have nonetheless some limitations, especially concerning axonal connectivity, as defined from structural, functional, and neurophysiological perspectives.[7] Recent atlases of neural plasticity evidenced the limited potential of WM tracts reorganization.[8-10] The strong interactions between glioma infiltration and WM should be emphasized,[11] with an improved understanding of the cellular mechanisms explaining why infiltrative tumoral cells are extensively diffusing within the subcortical pathways.[12,13] Yet, the removal of WM involved by GIIG may be possible, at least to some extent, without permanent neurological disturbances.

ABBREVIATIONS: EOR, extent of resection; **ESM,** electrostimulation mapping; **GIIG,** WHO grade II glioma; **IFOF,** inferior fronto-occipital fasciculus; **WHO,** World Health Organization; **WM,** white matter.

Although cortical reorganization was extensively reported in adaptation to GIIG progression to allow functional compensation, the neural network redistribution at the level of the corresponding axons which underpin the WM connectivity was poorly described. In this opinion piece, the purpose was to discuss mechanisms underlying functional reshaping which may enable resection of the subcortical component of GIIG. The main goal

© Congress of Neurological Surgeons 2023. Unauthorized reproduction of this article is prohibited.

was to propose a new model of "adaptative neural reconfiguration" in reaction to GIIG by focusing on the axonal connectivity: According to this model, on the processes of axonal plasticity, WM fibers compensation is driven by cortical rearrangement.

TWO DISTINCT LEVELS OF NEUROPLASTIC POTENTIAL: CORTEX VERSUS AXONAL FIBERS

The cortex is highly plastic, both in physiology (eg, during learning) explaining the considerable degree of anatomical-functional variability across healthy individuals and after cerebral injury.[14] The effects of focal lesions to be understood for the global changes on functional complexity and neural network architecture rather than purely for functional localization were studied using functional neuroimaging.[15] These processes of cortical remodeling are particularly efficient in slow progressing lesions as GIIG.[6] Consequently, massive surgical excisions of GIIG infiltrating cortical regions traditionally thought to be inoperable were achieved with no persistent deteriorations, eg, removal of the Broca area, Wernicke area, or Rolandic area.[5,16,17] Such resections were mostly performed under the guidance of intraoperative electrostimulation mapping (ESM) in awake patients.[18] The principle of cortical-subcortical ESM permits to check in real time whether no behavioral disturbances are induced by stimulating the cortex and WM pathways before removing them.[19,20] The concept of neural preservation has dramatically evolved in glioma surgery in the recent years, by refining functional assessment in the perioperative and intraoperative phases regarding different aspects of behavior. For movement, beyond the classical neurological examination of motor strength, complex bimanual coordination was evaluated during stimulation mapping and after surgery.[21,22] For language, besides the rough traditional evaluation looking for aphasic symptoms (eg, anomia, paraphasias, articulatory disorders, etc…), more subtle parameters were assessed, such as speed for lexical access: This criterion that can be monitored intraoperatively is significantly correlated to the return to work.[23] Cognitive functions (as executive functions, semantics, visuospatial cognition, attention, etc…) and emotional aspects (mentalizing and mood) are evaluated in a more objective way.[24-27] Indeed, higher-order functioning can be monitored, thanks to constant multitasking with time constraint during resection, enabling to increase the cognitive demand without increasing the duration of surgery.[28] Although intraoperative ESM may have some limits, especially patient fatigue, it is possible to overcome this problem by switching from a traditional tumor debulking to a disconnection resection based on the rapid identification of the functional cortical-subcortical boundaries: The awake period may therefore be shorter, allowing the removal of the invaded parenchyma (once disconnected) in a second surgical period in the asleep patient, even in giant gliomas.[29]

The use of preoperative and/or postoperative functional neuroimaging revealed that functional compensation is possible thanks to the reallocation of the cortex invaded by GIIG, based on the recruitment of peritumoral and/or remote cortical zones in the ipsilesional and/or contralesional hemispheres.[30-33] These compensatory mechanisms were facilitated by postsurgical rehabilitation,[34] possibly leading to reoperation(s) with optimization of the extent of resection (EOR) while avoiding deficit.[35] Despite some degrees of neuroplasticity of WM networks,[36] such processes are less effective at the axonal level, both in physiology—explaining few interindividual variations regarding the functional anatomy of the WM tracts—and in brain-damaged patients, including with GIIG.[14] Indeed, accurate neuropsychological assessments performed at diagnosis in patients with GIIG detected troubles in more than 50% of cases,[24] correlated with the invasion of WM tracts.[2] For instance, the infiltration of the left inferior fronto-occipital fasciculus (IFOF) was associated with verbal semantic deficit,[37] or the invasion of the right superior longitudinal fasciculus was associated with visuospatial disorders.[38] It was modeled that epilepsy (ie, the inaugural symptom in most of GIIG) meant that the plastic potential of the WM fibers was overwhelmed because of tumor-induced connectivity loss.[11] Recent atlases of neuroplasticity were elaborated based on intraoperative ESM of the cortex and WM tracts,[39] correlated with the postoperative functional recovery. They revealed that the main limit of neural reallocation was constituted by the WM tracts (except for some specific cortical regions, namely, input as the primary visual cortex and output as the primary sensorimotor cortex), explaining why the major part of the residual glioma infiltration was commonly left within the axonal fibers.[8-10,40] Indeed, the concept of "connectome-based surgery" in GIIG relies on the principle of achieving a maximal resection pursued up to the critical neural networks for a given patient, so taking into account the individual pattern of functional reshaping that occurred before operation,[41] typically in the case of a more distributed reorganization with recruitment of remote structures (as illustrated by preoperative functional imaging), the chance to better preserve cognitive performance after surgery while performing an optimal EOR is higher.[42] Despite this limited resource of axonal reconfiguration, glioma removal may frequently involve a part of the WM invaded by GIIG. Here, a new model of axonal compensation is proposed to better predict the EOR and to optimize surgical indication and planning.

PROPOSAL OF A NEW MODEL OF AXONAL COMPENSATION: STEM VERSUS TERMINATIONS/ORIGINS OF THE WM TRACTS

Most of atlases computed on the basis of functional neuroimaging data are dedicated to an improved comprehension either of the cortical organization or of the structural WM connectivity[43,44]—based on tractography which is intrinsically incapable of mapping the actual functional role of the axonal fibers because it provides only an indirect reflect of the putative function of the segmented tracts.[45] Especially, the phenomenon of "kissing" (convergence) and "fanning" (divergence within the cortex) of the

© Congress of Neurological Surgeons 2023. Unauthorized reproduction of this article is prohibited.

WM fibers was described by diffusion MRI.[46] Furthermore, tractography was used to develop a connectomic map preoperatively[47] based on the concept of "stem" vs "fan" of axons.[48] However, in recent experience conducted by international experts, aiming of reconstructing WM tracts in 42 different teams which used the same data set, there was a "variability in the size, shape, densities, and connections of the reconstructed white matter pathways."[48] Figure 1 illustrates the considerable variations in the cortical terminations, ie, the "fan" of the pyramidal tract and arcuate fasciculus.

Because of this major limitation, this manuscript emphasizes the contribution of intraoperative ESM able to provide *direct individual functional information* about the actual spatial organization of the WM fibers from their converging trunk to their cortical terminations—by taking into account their redistribution in reaction to glioma growth: A connectome-based resection can therefore be achieved accordingly. The sole actual atlas of functional anatomy of human brain ever reported that described the cortical-subcortical networks critical for several cognitive domains relies on the intraoperative ESM findings directly collected in awake patients.[49] A better knowledge of the interplay within and across neural circuits which subserves complex adaptive behavior necessitates a more holistic approach able to capture the dynamics between the cortex and WM tracts—too often investigated in isolation rather than in combination.[50]

According to this model, the axons terminating to/originating from a cortical area invaded by GIIG and which has already been compensated, thanks to the recruitment of perilesional sites, are no longer essential for brain functions and can be surgically removed with no functional worsening. However, more deeply, when the "fan" of WM fibers converges to the stem of the bundle, the axons terminating to/originating from the cortical sites located around the infiltrated cortex (thus by definition the peritumoral cortical areas are still eloquent because of participating in the functional compensation) are also critical for neural functions and must be surgically preserved (Figure 2). This explains why ESM of both the reorganized cortex involved by the GIIG and its corresponding fibers does not generate any behavioral disturbances, whereas ESM of the perilesional cortical mosaic and its corresponding fibers evokes functional disorders—up to the convergence of these critical axons at the level of the trunk of the pathway, which should constitute the deep functional boundary of resection. This information regarding the "functional gradient" along the fascicle (fan vs stem) cannot be provided by preoperative tractography (because not able to give direct functional data)[45]: Thus, ESM with cognitive monitoring should be achieved more systematically to capture the functional role of the axonal connectivity throughout GIIG resection.

SURGICAL IMPLICATIONS OF THIS ORIGINAL MODEL

In practice, if the stem of a WM bundle is damaged by surgical resection, even when invaded by GIIG, the risk to induce a disconnectionism syndrome is high, resulting in permanent deterioration according to the injured function–specific fascicle(s). Typically, resection of the frontostriatal tract may generate not only a transitory supplementary motor area syndrome but also persistent impairment concerning complex bimanual coordination.[21,22] Surgical lesion of the superior longitudinal fasciculus can lead to executive functions troubles[25,51]; resection of the right uncinate fasciculus and/or right IFOF can generate subjective empathy impairment[26]; surgical damage of the left IFOF may result in personality and behavioral changes[27]; or injury of the fronto-medial network can lead to deficit in the voluntary deployment of the visuospatial attention.[52] Interestingly, although long-term recovery is possible after resection of the basal temporal language area despite the fact that cortical ESM elicited transitory disorders,[53] such a recovery can occur on the condition that the left inferior longitudinal fasciculus is preserved—otherwise decline of lexical access retrieval will persist.[54] In stroke, the Broca area damage does not contribute to long-term speech production outcome after left frontal infarction: nonetheless, the transitory acute aphasia may resolve in the long run only if there was no combination of cortical damage and injury of the underlying white matter tracts.[55] Moreover, although some degrees of functional improvement were observed after lacunar infarctions, these reports are rare, and the recovery was usually not complete.[56]

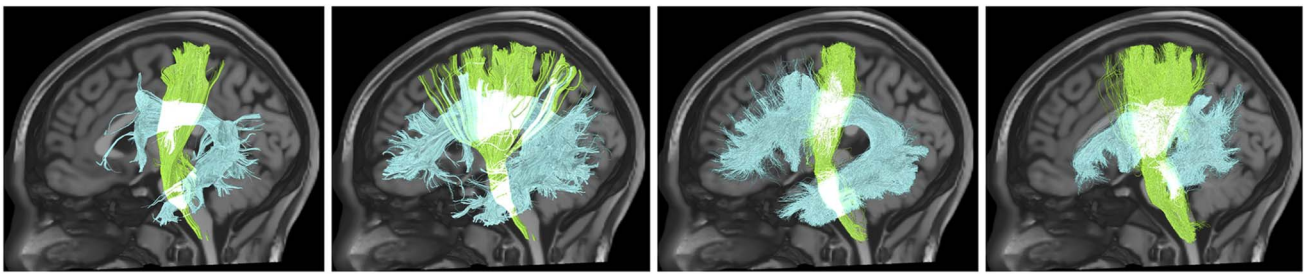

FIGURE 1. *Variation in white matter bundle segmentation. Four example segmentations of the corticospinal tract (green) and arcuate fasciculus (cyan) show variability in the size, shape, densities, and connections of these reconstructed white matter pathways (from[48] under original CC BY-NC-ND 4.0 license).*

© Congress of Neurological Surgeons 2023. Unauthorized reproduction of this article is prohibited.

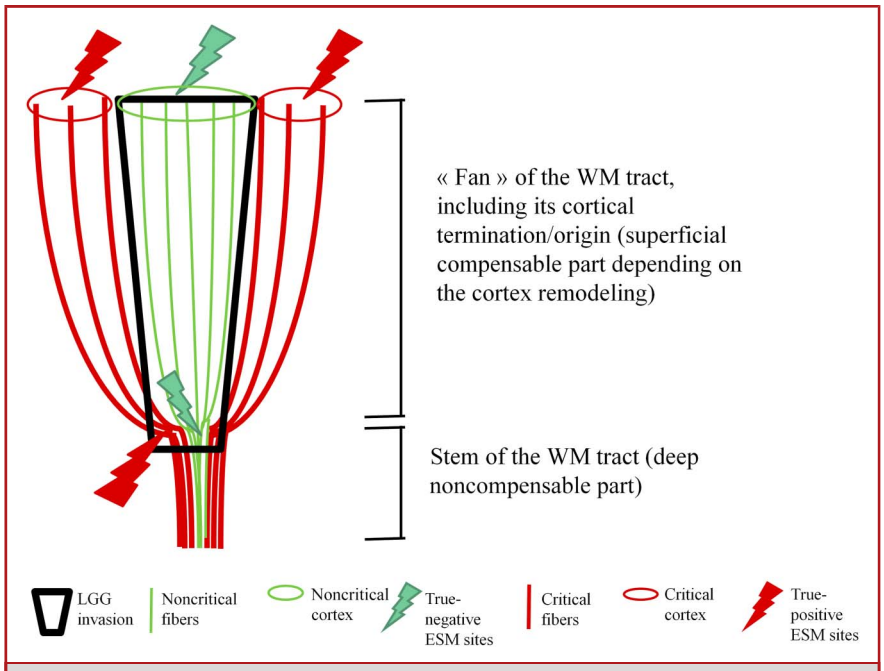

FIGURE 2. *Illustration of the functional gradient along the WM bundle, with a more superficial and partly compensable part depending on the cortical remodeling induced by GIIG growth and a deep noncompensable component corresponding to the stem of the tract in which the fibers converge, with a higher risk to leave tumor residue to preserve the axonal connectivity. Black form: schematic representation of the GIIG infiltration (dispersal of the infiltrative tumoral cells); green line: WM tracts no longer critical for the functions, because terminating to/originating from reorganized cortical regions; superficial green flash: true-negative ESM of the infiltrated cortex (no functional disturbances during its stimulation) which has been compensated by the recruitment of peritumoral cortical areas and which can be surgically removed (green circle); deep green flash: true-negative ESM of the infiltrated WM axons (no functional disturbances during their stimulation) which have been compensated by the recruitment of peritumoral fibers and which can be surgically removed up to the stem of the pathway in the depth; red line: WM tracts still critical for the functions, since terminating to/originating from perilesional cortical sites participating in the compensation of the cortex involved by the glioma; superficial red flash: true-positive ESM of the peritumoral cortex (inducing reproducible behavioral disturbances during its stimulation) which has been recruited for functional compensation and which must be surgically preserved (red circle); deep red flash: true-positive ESM of the WM axons (inducing reproducible behavioral disturbances during their stimulation) terminating to/originating from cortical areas still critical and which must represent the functional limits of the surgical resection, especially at the level of their convergence to the stem of the fascicle—even if invaded by tumoral infiltration which must be left to preserve the deep functional connectivity. ESM, electrostimulation mapping; GIIG, World Health Organization grade II glioma; WM, white matter.*

Taken as a whole, these observations made in different diseases support the critical role of intraoperative ESM of the subcortical connectivity which represents the limitation of neuroplastic potential. Both cortical and axonal ESM are needed to study the entire reorganized neural network as a whole throughout resection and not to map the cortex and/or the WM tracts separately. The bundles should be detected and followed from their cortical terminations/origins to the convergence of the fibers (the stem) in the depth, which must constitute the limits of resection. In clinical routine, this on-line identification of multiple cortical-subcortical circuits sustaining several functions is possible by asking the awake patient to perform multitasking without any rest from the superficial to the deep part of the resection: Achieving several tasks simultaneously is a mirror of the interactions between neural circuits.[28]

The structural integrity of the WM tracts can be indirectly investigated before surgery to help in the prediction of postoperative outcomes according to the preoperative invasion of the subcortical pathways by the glioma. Examining language fascicles by tractography was correlated to long-lasting language disorders, particularly when the dorsal stream was damaged.[57] The degree of glioma migration within associative bundles was a significant predictor of postsurgical impairments, eg, regarding mentalistic abilities.[26,58] Therefore, probabilistic atlases of functional resectability of GIIG were built, helpful for decision making based on a better individual estimation of the oncofunctional balance of surgery.[8,40,59] This reasoning can be applied for GIIG relapse after a first surgery: Reoperation may be decided according to the connectomal constraints, ie, with a lower chance

© Congress of Neurological Surgeons 2023. Unauthorized reproduction of this article is prohibited.

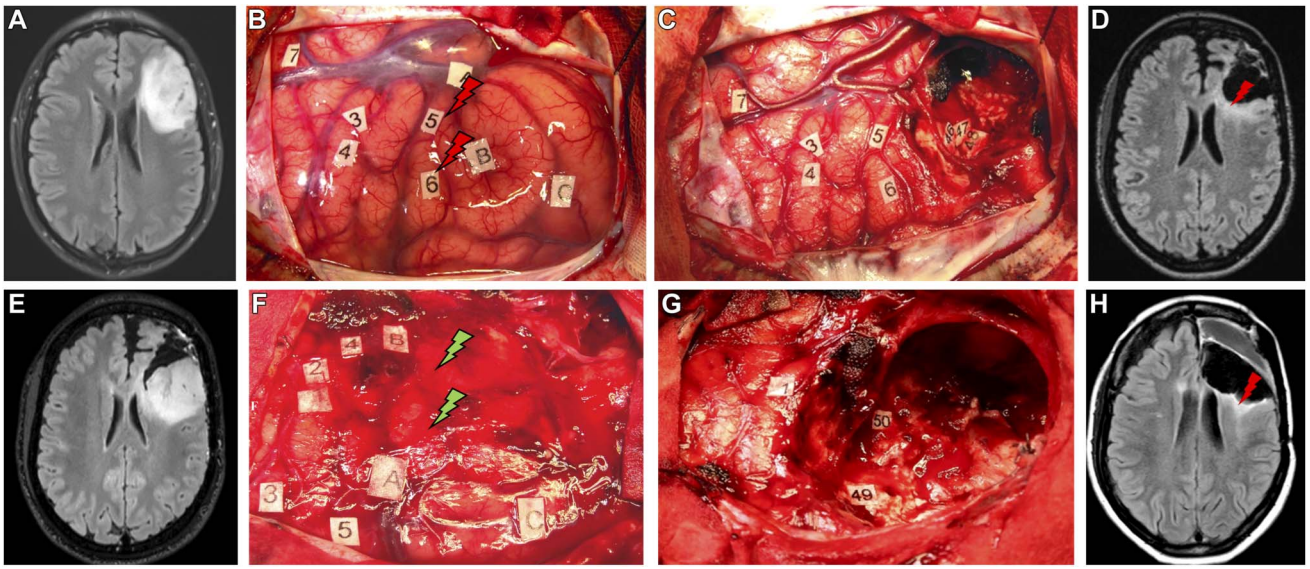

FIGURE 3. *Case illustration.* **A**, *Preoperative axial FLAIR-weighted MRI performed in a 21-year-old woman, student, who presented with seizures allowing the diagnosis of a left frontal GIIG. The neurological and neuropsychological evaluation was normal.* **B**, *Intraoperative photograph before resection in awake patient. The anterior portion of the left hemisphere is on the right. Letter tags represent the cortical tumor boundaries identified using ultrasonography. Number tags correspond to areas of positive ESM (2.5 mA) as follows: tags 3 and 4: ventral premotor cortex evoking speech arrest during stimulation; tags 5 and 6: pars opercularis of the left inferior frontal gyrus eliciting phonological paraphasias during stimulation (red flashes).* **C**, *Intraoperative photograph after glioma removal, achieved up to the pars opercularis which was preserved posteriorly, after removal of the pars orbitalis and pars triangularis. Subcortically, the resection was also achieved up to functional limits identified in the depth. ESM of the WM tracts allowed the detection of critical WM fibers as follows: tags 46 and 47: anterior portion of the arcuate fasciculus/superior longitudinal fasciculus complex, inducing phonological paraphasias during stimulation; tag 48: frontal part of the inferior fronto-occipital fasciculus, generating semantic paraphasias during stimulation.* **D**, *Postoperative axial FLAIR-weighted MRI (performed 3 months after surgery) showing an incomplete resection. Although the residual tumor invading the cortex (pars opercularis) was small, most of the residue involved the WM tracts, especially at the level of their convergence in the depth ("trunk," red flash). A diffuse WHO grade II oligodendroglioma (IDH1-mutated, with 1p19q codeletion) was diagnosed: No adjuvant medical therapy was given because of the small volume of residual GIIG. The patient resumed a normal life, with no functional deficit, no epilepsy, and a regular surveillance.* **E**, *Axial FLAIR-weighted MRI performed 6 years later, which showed a significant regrowth of the tumor leading to perform reoperation in a patient still asymptomatic (surgery was suggested earlier to the patient but she preferred to postpone it for personal reasons).* **F**, *Intraoperative photograph before resection in awake patient. Letter tags represent the tumor boundaries identified using ultrasonography. Number tags correspond to areas of positive ESM (2.5 mA) as follows: tags 1, 2, and 4: ventral premotor cortex eliciting speech arrest during stimulation (as during the first surgery); tag 3: primary motor cortex of the face, evoking face movement during stimulation; tags 5: dorso-lateral prefrontal cortex inducing semantic paraphasias during stimulation; Of note, ESM of the pars opercularis of the left inferior frontal gyrus no longer generated any disturbances (green flashes), showing cortical reorganization in comparison with the first surgery.* **G**, *Intraoperative view after resection, achieved up to the ventral premotor cortex which was preserved posteriorly, after removal of the pars opercularis. Subcortically, the glioma removal was again achieved up to functional limits identified in the depth. ESM of the WM tracts enabled the detection of critical tracts as follows: tag 50: anterior portion of the arcuate fasciculus/superior longitudinal fasciculus complex (which runs to the ventral premotor cortex), inducing speech arrest during stimulation; tag 49: frontal portion of the inferior fronto-occipital fasciculus (which runs to the dorsolateral prefrontal cortex), generating semantic paraphasias during stimulation.* **H**, *Postoperative axial FLAIR-weighted MRI (performed 3 months after reoperation) showing an almost complete resection. Although there was this time no residual tumor invading the cortex, thanks to the resection of the pars opercularis and its corresponding fibers (the "fan"); a small but objective residue was nonetheless still visible within the WM tracts at the level of their convergence in the depth ("trunk," red flash). A diffuse WHO grade II oligodendroglioma was confirmed, and no adjuvant medical therapy was given. The patient returned to a normal familial and socioprofessional life. ESM, electrostimulation mapping; FLAIR, fluid-attenuated inversion recovery; GIIG, WHO grade II glioma; WHO, World Health Organization; WM, white matter.*

improve EOR if the recurrent glioma migrates along the WM tracts (Figure 3).[60,61]

CONCLUSION

An original model of adaptative neural reconfiguration in reaction to GIIG progression was proposed with respect to the axonal connectivity. A functional gradient along the WM tracts was described, ie, the stem of the bundle that represents the actual limitation of plastic potential (even if infiltrated by the glioma) and the terminations/origins of the bundle that may no longer be critical, thanks to functional reallocation of the cortex (invaded by the glioma) in which these WM fibers run. Understanding that a certain degree of axonal compensation in specific portions of the tracts is driven by cortical remodeling may enable to rethink the concept of WM plasticity and to refine the preoperative estimation of the EOR for GIIG. Identifying critical fibers, especially their convergence in

© Congress of Neurological Surgeons 2023. Unauthorized reproduction of this article is prohibited.

the depth, by means of intraoperative ESM is of utmost importance to achieve an individualized connectome-based surgical resection.

Funding

This study did not receive any funding or financial support.

Disclosures

The author has no personal, financial, or institutional interest in any of the drugs, materials, or devices described in this article.

REFERENCES

1. Louis DN, Perry A, Wesseling P, et al. The 2021 WHO classification of tumors of the central nervous system: a summary. *Neuro Oncol*. 2021;23(8):1231-1251.
2. Duffau H. White matter tracts and diffuse lower-grade gliomas: the pivotal role of myelin plasticity in the tumor pathogenesis, infiltration patterns, functional consequences and therapeutic management. *Front Oncol*. 2022;12:855587.
3. Smits A, Jakola AS. Clinical presentation, natural history, and prognosis of diffuse low-grade gliomas. *Neurosurg Clin N Am*. 2019;30(1):35-42.
4. Duffau H. The huge plastic potential of adult brain and the role of connectomics: new insights provided by serial mappings in glioma surgery. *Cortex*. 2014;58: 325-337.
5. Andrews JP, Cahn N, Speidel BA, et al. Dissociation of Broca's area from Broca's aphasia in patients undergoing neurosurgical resections. *J Neurosurg*. 2023;138(3): 847-857.
6. Desmurget M, Bonnetblanc F, Duffau H. Contrasting acute and slow-growing lesions: a new door to brain plasticity. *Brain*. 2006;130(4):898-914.
7. Boyer A, Stengel C, Bonnetblanc F, et al. Patterns of axono-cortical evoked potentials: an electrophysiological signature unique to each white matter functional site? *Acta Neurochir (Wien)*. 2021;163(11):3121-3130.
8. Ius T, Angelini E, Thiebaut de Schotten M, Mandonnet E, Duffau H. Evidence for potentials and limitations of brain plasticity using an atlas of functional resectability of WHO grade II gliomas: towards a "minimal common brain". *Neuroimage*. 2011; 56(3):992-1000.
9. Herbet G, Maheu M, Costi E, Lafargue G, Duffau H. Mapping neuroplastic potential in brain-damaged patients. *Brain*. 2016;139(3):829-844.
10. Sarubbo S, De Benedictis A, Merler S, et al. Towards a functional atlas of human white matter. *Hum Brain Mapp*. 2015;36(8):3117-3136.
11. Szalisznyo K, Silverstein DN, Duffau H, Smits A. Pathological neural attractor dynamics in slowly growing gliomas supports an optimal time frame for white matter plasticity. *PLoS One*. 2013;8(7):e69798.
12. Venkataramani V, Yang Y, Schubert MC, et al. Glioblastoma hijacks neuronal mechanisms for brain invasion. *Cell*. 2022;185(16):2899-2917.e31.
13. Yang Y, Schubert MC, Kuner T, Wick W, Winkler F, Venkataramani V. Brain tumor networks in diffuse glioma. *Neurotherapeutics*. 2022;19(6):1832-1843.
14. Duffau H. A two-level model of interindividual anatomo-functional variability of the brain and its implications for neurosurgery. *Cortex*. 2017;86:303-313.
15. Hart M, Romero-Garcia R, Price SJ, Suckling J. Global effects of focal brain tumors on functional complexity and network robustness: a prospective cohort study. *Neurosurgery*. 2019;84(6):1201-1213.
16. Sarubbo S, Latini F, Sette E, et al. Is the resection of gliomas in Wernicke's area reliable? Wernicke's area resection. *Acta Neurochir (Wien)*. 2012;154(9):1653-1662.
17. Schucht P, Ghareeb F, Duffau H. Surgery for low-grade glioma infiltrating the central cerebral region: location as a predictive factor for neurological deficit, epileptological outcome, and quality of life. *J Neurosurg*. 2013;119(2):318-323.
18. Duffau H. New philosophy, clinical pearls, and methods for intraoperative cognition mapping and monitoring "à la carte" in brain tumor patients. *Neurosurgery*. 2021;88(5):919-930.
19. Gogos AJ, Young JS, Morshed RA, Hervey-Jumper SL, Berger MS. Awake glioma surgery—technical evolution and nuances. *J Neurooncol*. 2020;147(3):515-524.
20. Sanai N, Berger MS. Surgical oncology for gliomas—the state of the art. *Nat Rev Clin Oncol*. 2018;15(2):112-125.
21. Rech F, Herbet G, Moritz-Gasser S, Duffau H. Somatotopic organization of the white matter tracts underpinning motor control in humans: an electrical stimulation study. *Brain Struct Funct*. 2016;221(7):3743-3753.
22. Rech F, Duffau H, Pinelli C, et al. Intraoperative identification of the negative motor network during awake surgery to prevent deficit following brain resection in premotor regions. *Neurochirurgie*. 2017;63(3):235-242.
23. Moritz-Gasser S, Herbet G, Maldonado IL, Duffau H. Lexical access speed is significantly correlated with the return to professional activities after awake surgery for low-grade gliomas. *J Neurooncol*. 2012;107(3):633-641.
24. Lemaitre AL, Herbet G, Ng S, Moritz-Gasser S, Duffau H. Cognitive preservation following awake mapping-based neurosurgery for low-grade gliomas: a longitudinal, within-patient design study. *Neuro Oncol*. 2022; 24(5):781-793.
25. Cochereau J, Lemaitre AL, Wager M, Moritz-Gasser S, Duffau H, Herbet G. Network-behavior mapping of lasting executive impairments after low-grade glioma surgery. *Brain Struct Funct*. 2020;225(8):2415-2429.
26. Herbet G, Lafargue G, Moritz-Gasser S, et al. A disconnection account of subjective empathy impairments in diffuse low-grade glioma patients. *Neuropsychologia*. 2015; 70:165-176.
27. Lemaitre AL, Herbet G, Duffau H, Lafargue G. Personality and behavioral changes after brain tumor resection: a lesion mapping study. *Acta Neurochir (Wien)*. 2021; 163(5):1257-1267.
28. Duffau H, Ng S, Lemaitre AL, Moritz-Gasser S, Herbet G. Constant multi-tasking with time constraint to preserve across-network dynamics throughout awake surgery for low-grade glioma: a necessary step to enable patients resuming an active life. *Front Oncol*. 2022;12:924762.
29. Sauvageot S, Boetto J, Duffau H. Surgical, functional and oncological considerations regarding awake resection for giant diffuse lower-grade glioma of more than 100 cm3. *J Neurosurg*. Published online ahead of print March 24, 2023. doi: https://doi.org/10.3171/2023.2.JNS222755.
30. Bulubas L, Sardesh N, Traut T, et al. Motor cortical network plasticity in patients with recurrent brain tumors. *Front Hum Neurosci*. 2020;14:118.
31. Bryszewski B, Tybor K, Ormezowska EA, Jaskólski DJ, Majos A. Rearrangement of motor centers and its relationship to the neurological status of low-grade glioma examined on pre- and postoperative fMRI. *Clin Neurol Neurosurg*. 2013;115(12): 2464-2470.
32. Kristo G, Raemaekers M, Rutten GJ, de Gelder B, Ramsey NF. Inter-hemispheric language functional reorganization in low-grade glioma patients after tumour surgery. *Cortex*. 2015;64:235-248.
33. van Dokkum LEH, Moritz Gasser S, Deverdun J, et al. Resting state network plasticity related to picture naming in low-grade glioma patients before and after resection. *Neuroimage Clin*. 2019;24:102010.
34. Mosca C, Zoubrinetzy R, Baciu M, et al. Rehabilitation of verbal memory by means of preserved nonverbal memory abilities after epilepsy surgery. *Epilepsy Behav Case Rep*. 2014;2:167-173.
35. Duffau H. Repeated awake surgical resection(s) for recurrent diffuse low-grade gliomas: why, when, and how to reoperate? *Front Oncol*. 2022;12: 947933.
36. Yogarajah M, Focke NK, Bonelli SB, et al. The structural plasticity of white matter networks following anterior temporal lobe resection. *Brain*. 2010;133(8):2348-2364.
37. Almairac F, Herbet G, Moritz-Gasser S, de Champfleur NM, Duffau H. The left inferior fronto-occipital fasciculus subserves language semantics: a multilevel lesion study. *Brain Struct Funct*. 2015;220(4):1983-1995.
38. Liu D, Liu Y, Hu X, et al. Alterations of white matter integrity associated with cognitive deficits in patients with glioma. *Brain Behav*. 2020;10(7):e01639.
39. Duffau H. Stimulation mapping of white matter tracts to study brain functional connectivity. *Nat Rev Neurol*. 2015;11(5):255-265.
40. Mandonnet E, Jbabdi S, Taillandier L, et al. Preoperative estimation of residual volume for WHO grade II glioma resected with intraoperative functional mapping. *Neuro Oncol*. 2007;9(1):63-69.
41. Duffau H. Brain connectomics applied to oncological neuroscience: from a traditional surgical strategy focusing on glioma topography to a meta-network approach. *Acta Neurochir (Wien)*. 2021;163(4):905-917.
42. Ng S, Deverdun J, Lemaitre AL, et al. Precuneal gliomas promote behaviorally relevant remodeling of the functional connectome. *J Neurosurg*. Published online ahead of print October 28, 2022. doi: https://doi.org/10.3171/2022.9.JNS221723.

© Congress of Neurological Surgeons 2023. Unauthorized reproduction of this article is prohibited.

43. Glasser MF, Coalson TS, Robinson EC, et al. A multi-modal parcellation of human cerebral cortex. *Nature*. 2016;536(7615):171-178.
44. Catani M, Thiebaut de Schotten M. A diffusion tensor imaging tractography atlas for virtual in vivo dissections. *Cortex*. 2008;44(8):1105-1132.
45. Azad TD, Duffau H. Limitations of functional neuroimaging for patient selection and surgical planning in glioma surgery. *Neurosurg Focus*. 2020;48(2):e12.
46. Assaf Y, Johansen-Berg H, Thiebaut de Schotten M. The role of diffusion MRI in neuroscience. *NMR Biomed*. 2019;32(4):e3762.
47. Dadario NB, Brahimaj B, Yeung J, Sughrue ME. Reducing the cognitive footprint of brain tumor surgery. *Front Neurol*. 2021;12:711646.
48. Schilling KG, Rheault F, Petit L, et al. Tractography dissection variability: what happens when 42 groups dissect 14 white matter bundles on the same dataset? *Neuroimage*. 2021;243:118502.
49. Sarubbo S, Tate M, De Benedictis A, et al. Mapping critical cortical hubs and white matter pathways by direct electrical stimulation: an original functional atlas of the human brain. *Neuroimage*. 2020;205:116237.
50. Herbet G, Duffau H. Revisiting the functional anatomy of the human brain: toward a meta-networking theory of cerebral functions. *Physiol Rev*. 2020;100(3):1181-1228.
51. Mandonnet E, Vincent M, Valero-Cabré A, et al. Network-level causal analysis of set-shifting during trail making test part B: a multimodal analysis of a glioma surgery case. *Cortex*. 2020;132:238-249.
52. Herbet G, Duffau H. Contribution of the medial eye field network to the voluntary deployment of visuospatial attention. *Nat Commun*. 2022;13(1):328.
53. Luders H, Lesser RP, Hahn J, et al. Basal temporal language area. *Brain*. 1991; 114(2):743-754.
54. Herbet G, Moritz-Gasser S, Boiseau M, Duvaux S, Cochereau J, Duffau H. Converging evidence for a cortico-subcortical network mediating lexical retrieval. *Brain*. 2016;139(11):3007-3021.
55. Gajardo-Vidal A, Lorca-Puls DL, Team P, et al. Damage to Broca's area does not contribute to long-term speech production outcome after stroke. *Brain*. 2021; 144(3):817-832.
56. Ganesh A, Luengo-Fernandez R, Rothwell PM. Late functional improvement and 5-year poststroke outcomes: a population-based cohort study. *J Neurol Neurosurg Psychiatry*. 2020;91(8):831-839.
57. Caverzasi E, Hervey-Jumper SL, Jordan KM, et al. Identifying preoperative language tracts and predicting postoperative functional recovery using HARDI q-ball fiber tractography in patients with gliomas. *J Neurosurg*. 2016;125(1): 33-45.
58. Nakajima R, Yordanova YN, Duffau H, Herbet G. Neuropsychological evidence for the crucial role of the right arcuate fasciculus in the face-based mentalizing network: a disconnection analysis. *Neuropsychologia*. 2018;115:179-187.
59. De Witt Hamer PC, Hendriks EJ, Mandonnet E, Barkhof F, Zwinderman AH, Duffau H. Resection probability maps for quality assessment of glioma surgery without brain location bias. *PLoS One*. 2013;8(9):e73353.
60. Picart T, Herbet G, Moritz-Gasser S, Duffau H. Iterative surgical resections of diffuse glioma with awake mapping: how to deal with cortical plasticity and connectomal constraints? *Neurosurgery*. 2019;85(1):105-116.
61. Ribeiro L, Ng S, Duffau H. Recurrent insular low-grade gliomas: factors guiding the decision to reoperate. *J Neurosurg*. Published online ahead of print October 28, 2022. doi: https://doi.org/10.3171/2022.9.JNS22128.

© Congress of Neurological Surgeons 2023. Unauthorized reproduction of this article is prohibited.