Diagnostic and Interventional Imaging (2014) **95**, 945—955

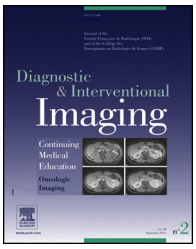

CONTINUING EDUCATION PROGRAM: FOCUS...

Diffuse low-grade gliomas and neuroplasticity

H. Duffau [a,b,*]

[a] *Department of Neurosurgery, Gui-de-Chauliac Hospital, Montpellier University Medical Center, 80, avenue Augustin-Fliche, 34295 Montpellier, France*
[b] *National Institute for Health and Medical Research (Inserm), U1051 Laboratory, Team ''Brain Plasticity, Stem Cells and Glial Tumors'', Institute for Neurosciences of Montpellier, Montpellier University Medical Center, 34091 Montpellier, France*

KEYWORDS
Neuroplasticity;
Diffuse low-grade glioma;
Awake brain surgery;
Connectivity;
Functional mapping

Abstract The traditional approach in neuro-oncology is to study the tumor in great detail and ultimately give little consideration to the brain itself. Choosing the best treatment strategy for each patient with a diffuse low-grade glioma, in other words optimizing the oncologic and functional balance, implies not only a full knowledge of the natural history of this chronic disease, but also an understanding of the adaptation of the brain in response to growth and spread of the glioma. The aim of this review is to examine the mechanisms underlying this neuroplasticity, allowing functional compensation when the tumor progresses, and opening the way to new treatments with the principle of shifting towards ''functional personalized neuro-oncology'', improving both median survival and quality of life.
© 2014 Éditions françaises de radiologie. Published by Elsevier Masson SAS. All rights reserved.

The traditional approach in neuro-oncology is to study the tumor extensively and ultimately with little consideration given to the brain itself. It is however crucial to take account of the ''onco-functional balance'', i.e. to find the optimal ratio both in terms of the tumor and quality of life to decide on a suitable treatment strategy, particularly in patients with diffuse low-grade gliomas (DLGG) [1]. In this context, whilst understanding the natural history of this chronic tumor is obviously essential, it is however not sufficient. It is also essential to study the reaction of the central nervous system which is induced by the growth and migration of the glioma. In other words because of the close relationships between the tumor and the brain, the brain may adopt adaptatory mechanisms to compensate for the spread of neoplastic cells [2].

* Department of Neurosurgery, Gui-de-Chauliac Hospital, Montpellier University Medical Center, 80, avenue Augustin-Fliche, 34295 Montpellier, France.
E-mail address: h-duffau@chu-montpellier.fr

http://dx.doi.org/10.1016/j.diii.2014.08.001
2211-5684/© 2014 Éditions françaises de radiologie. Published by Elsevier Masson SAS. All rights reserved.

The aim of this review is to examine these neuroplasticity effects in order to move towards individualized treatment based on the dynamic interactions between DLGG and functional reorganization of the brain in order to improve both median survival and the patient's quality of life.

From localizationism to the connectome

On the basis of phrenologic theories, the localizationist view of the functioning of the central nervous system has been the approach used for over a century. By this principle, each region of the brain corresponds to a given function, and a lesion in an ''eloquent'' area is therefore presumed to result in a massive and permanent neurological deficit. In reality, because of the many observations of recovery after brain damage, including damage to areas deemed to be ''functional'' by the conventional approach, the concept of a rigid modular organization of the brain has been questioned, moving towards a connectionist philosophy. In this model, the central nervous system is organized into parallel networks, which are dynamic, interactive and able to compensate for each other - at least to a certain extent [3]. This goes back to a hodotopic principle, through which the functions of the brain are supported by extensive circuits comprising both the cortical epicenters (topos, i.e. sites) and connections between these ''nodes'', created by associating bundles of white matter (hodos, i.e. pathways) [4]. Neurological function comes from the synchronization between different epicenters, working in phase during a given task, and explaining why the same node may take part in several functions depending on the other cortical areas with which it is temporarily connected at any one time. In this context, functional maps may be reorganized within remote networks, making neuroplasticity mechanisms possible, both physiologically (ontogenics and learning) and after brain injury [5,6].

The potential of this post-damage plasticity however has been shown to correlate directly with the temporal pattern of the neurological damage. Whilst only modest redistribution of neurosynaptic networks occurs in acute injury such as stroke, explaining the limited recovery in many patients, massive redistribution occurs in chronic slowly progressive injuries, particularly in DLGG, explaining why patients generally develop few if any deficits [7]. Furthermore, a probabilist atlas designed to study the plasticity index depending on tumor site has recently been reported [8] and shows that whilst the potential for cortical reorganization is considerable, it is very limited in terms of subcortical connectivity. In other words, it is crucial to preserve the connectome in order to achieve functional compensation after a cerebral injury. This is a very important concept in the treatment of patients with DLGG, particularly with respect to surgery [9].

Natural history of DLGG, neuroplasticity and functional state

DLGG is a rare primary brain tumor (with an incidence in about 1/100,000 people annually), which generally presents as an epileptic seizure (and occasionally incidentally) in young adults with an active family, social and occupational life [1]. Unlike claims made for decades, these lesions progress slowly but constantly. Examination of the tumor growth curve by comparing its mean diameter

(calculated from its volume from the equation:

$$d = \sqrt[3]{\frac{6Vol}{\pi}}$$

on two MRIs 6 weeks to 3 months apart before any treatment has shown linear radiological growth in mean diameter of approximately 4 mm per year [10]. As a result, the concept of ''progression-free survival'' has no meaning in untreated DLGG or following incomplete surgical excision, as by definition all DLGG progress continually (except after complete excision or if it stabilizes as a result of chemotherapy or radiotherapy). In this context, the conventional radiological criteria initially proposed by McDonald, or more recently by the RANO group [11], are not appropriate for DLGG, as they only take account of the calculation of two diameters and not of volume (from which however the mean diameter can be deduced secondarily, see above). In addition, these tumors spread along the white matter bundles and inevitably transform into malignant gliomas—which influences both functional prognosis and survival, as median survival is in about 6 years if only a diagnostic biopsy is taken after radiological diagnosis [12].

On one hand, the very gradual growth of the tumor over the years leaves the central nervous system time to reorganize itself as the tumor infiltrates. For this reason, a standard neurological examination at the time of diagnosis is usually normal, despite DLGG frequently being located in regions conventionally deemed to be ''eloquent'' (for example, the supplementary motor area, insula, Broca's area or the central area) [13].

On the other hand, extensive neuropsychological assessments have shown that cognitive disorders are very common, although have long been underestimated. Whereas these patients were conventionally considered not to have any higher function deficit, many cognitive abnormalities have recently been found with repercussions on quality of life. These problems generally involve the attention processes, working memory, executive functions, learning, and even emotional or behavioral aspects, and have been found in almost 90% in patients before any treatment. These suggest that the DLGG itself has a negative impact [14]. In more specific terms, the deficits have been shown to be significantly related to infiltration of the subcortical association pathways and not to infiltration of specific cortical regions. Specifically, spread of the glioma along the left inferior fronto-occipital fascicle correlates with semantic processing disorders [15]. These results support the theories described previously of a hodotopic and not locationist organization of the central nervous system, in which the connectome represents the major limitation to plasticity mechanisms [3]. Routine neuropsychological assessments with quality of life assessment scales are now recommended in all patients with DLGG, as the standard neurological examination is ultimately too crude to be able to identify subtle deficits [16].

Cerebral mapping and surgery for DLGG

The impact of surgical resection on survival in DLGG

Surgery is always required to obtain a tissue sample in order to distinguish between the different tumor subtypes, define tumor grade and examine its genetic status. In addition to this histological and molecular purpose, surgery is designed to achieve maximum resection and minimize the risks of malignant transformation and increase median survival, at the same time maintaining or even improving quality of life [17]. The extent of the resection should always be identified on a postoperative MR. One critical point is the definition of complete resection, which in the case of DLGG is removal of all of the hyperintense FLAIR regions, which can be confirmed by comparing pre- and postoperative MRs. Resection is deemed to be subtotal if the residual volume is under 10cc and partial if it is > 10cc [18]. Although there are no randomized trials, all surgical series based on objective postoperative MR assessment have shown complete or subtotal resection to have a significant impact on overall survival, delaying degeneration (evidence level II) [19—24]. One recent study compared survival in two cohorts of patients with DLGG. The first group of patients underwent biopsy together with follow-up, and had a median survival of only 5.9 years. Early surgical resection was carried out in the second group: median survival had not yet been reached over the same period showing that the procedure had a significant impact [12]. The largest surgical series of 1508 patients has just been reported by the French Glioma Study Network (REG) and showed a median survival of 13 years from first treatment and 15 years from the first symptom—i.e. overall double the length of survival compared to a watch and wait approach [25,26].

A prospective randomized trial would no longer be ethical and early surgery is recommended at the time of diagnosis. Biopsy (also bearing in mind the risk of underscoring tumor grade) should only be reserved for patients in whom surgery is contraindicated, particularly in gliomatosis [27]. Surgery is also starting to be considered in asymptomatic DLGG, leading to a large number of total resections on the basis that the tumor volume is lower in these patients [28].

In conclusion, according to current European Guidelines, surgical resection is at present the first line treatment in DLGG [29]. On the other hand, quality of life must be maintained especially in patients who have normal activities before the procedure. For this reason, surgical resection should be carried out within functional cortical and subcortical limits. As a result, and because of the large interindividual functional anatomical variability, which is increased by the reactive plasticity effects in response to tumor progression, mapping is necessary in each patient. The aim of mapping is to determine the best balance between the most complete resection as possible whilst preserving crucial neurological networks for the neurosynaptic processes, in other words moving towards ''functional oncologic neurosurgery'' [1,17,19].

Preoperative functional imaging

In this context, the development of neurofunctional imaging techniques such as functional MR (fMRI), white matter fiber tractography by diffusion tensor imaging and transcranial magnetic stimulation has enabled non-invasive whole brain mapping. These methods provide an estimate of the location of eloquent areas (i.e. those involved in sensorimotor, visual, language and cognitive functions) with respect to the tumor and provide information about lateralization of language in the hemispheres. Functional imaging is not however sufficiently reliable on an individual basis to be usable in clinical practice, as it does not directly reflect cerebral functional reality, but provides a very indirect approximation based on biomathematic reconstructions—explaining why results may vary depending on the model used [30].

Correlation studies between fMRI and intraoperative electrophysiology have shown a sensitivity ranging from 59% to 100% for language (with a specificity of 0% to 97%) [31]. In addition, fMRI could not distinguish regions which are essential for function (which must be preserved surgically) from regions of the brain which are involved but are not crucial for a given function (and which may therefore be surgically removed as functional compensation may occur). This therefore raises two risks of basing decisions on fMRI, i.e. not selecting a patient for a procedure because of a false positive imaging result (and therefore an oncologic loss of opportunity) or conversely removing a DLGG from a region which is ultimately essential for function but not found on the preoperative fMRI because of a false negative result (and therefore a loss of functional opportunity) [17]. With this in mind, the concept of the lateralization index and dominant hemisphere for language is extremely dangerous. Even if fMRI only detected under 10% active regions in a right-handed patient with a right hemisphere glioma, this ''left dominance'' does not however mean that the right side is not functionally crucial. It would simply need this area to be located in the immediate proximity of the tumor for surgical resection based on fMRI results on the lateralization index in favor of the left hemisphere to result in potentially irreversible cross-aphasia [32].

Diffusion tensor imaging, which enables tractography of the main white matter bundles to be carried out, needs to be validated. Different reconstructions are found from different models and software using the same data, showing that tractography is neither reliable nor reproducible. Correlation studies between tractography and intraoperative electrophysiology (direct subcortical electrostimulation) have shown concordance in only 82% of cases [33]. Negative tractography does not formally mean that no crucial fibers are present within the glioma, and in addition, the method only provides anatomical (indirect) information but never supplies information about the function of the subcortical bundles. Whilst tractography is both a didactic research tool, it is not at present reasonable to use this method as the basis to determine indications for surgery or to plan the surgical procedure [34].

With respect to transcranial magnetic stimulation, apart from the fact that this technique only examines the cortex and not subcortical connectivity, its specificity for language mapping is only 23.8%, with a positive predictive value of 35.6% [35].

Intraoperative functional mapping and awake surgery

The current limitations of imaging have led to an updating of a surgical technique popularized by Penfield in the 1930s [36], interest that was subsequently lost for several decades. This is resection of cerebral lesions in awake surgical patients in order to carry out mapping by electrical stimulations of crucial individual functional structures [37]. The principle of this technique involves inactivating cortical and subcortical areas (white matter and deep gray nuclei) which are essential to function, i.e. interfering for a few seconds with tasks performed continuously by the patient on the operating table when the areas are stimulated by a series of electric waves (60 Hz, 1 msec, 1 to 4 mA) mimicking a genuine ''virtual transient lesion'' [38]. The areas detected before corticectomy and then during the tumor ablation are therefore preserved (even if they are possibly infiltrated by glial tumor) in order not to reduce the patient's quality of life. As already stated, on the basis of this new concept, resections are performed not only within oncologic and/or anatomical limits, but within individual cortico-subcortical functional limits (cf. clinical case). This principle implies firstly leaving tumor cells which are invading essential functional neurosynaptic structures in some cases of very diffuse glioma, or conversely continuing to remove cerebral parenchyma occasionally beyond the tumor boundaries demonstrated on imaging (i.e. as long as ''eloquent'' areas are not affected) when the gliomas are located remote to functional areas. This has brought about the process of ''supracomplete'' resection which is justified by the fact that isolated tumor glial cells are present in DLGG within the margin of 1 to 2 cm around the FLAIR hyperintensity on MR, and have a very significant impact on malignant transformation [39]. The ideal balance between oncologic and functional imperatives can then be weighted for each patient, optimizing the benefit of surgery [40].

In summary, and as shown in a recent meta-analysis of over 8000 patients [41], awake surgery is a well tolerated procedure which (i) identifies crucial cortical and subcortical structures which are crucial for function, particularly sensorimotor language, visuospatial, cognitive and emotional functions (ii) reduces the risk of permanent postoperative neurological deficits to under 2%, including those ''eloquent'' areas (see below) (iii) enables resections to be made within functional limits, without a margin, optimizing these and (iv) delaying the risk of malignant transformation and therefore increasing overall survival.

Role of neuroplasticity in DLGG surgery

Ablation of DLGG from functional regions

On a hodotopic basis, the use of cortical map reorganization mechanisms are involved because of the slow progression of DLGG (i.e. recruitment of areas around the lesion and/or within the hemisphere remote to the glioma and/or contralateral to the lesion) has made it possible to undertake wide surgical resection of a tumor located in a region of the brain conventionally deemed to be inoperable, on the basis of a locationist philosophy. Extensive tumor resections have therefore been carried out without causing permanent neurological deficit, in the following areas [2,7]:

- *Resection of DLGG infiltrating Broca's area in the ''dominant'' left hemisphere:* Resection of the pars opercularis and/or pars triangularis of the left inferior frontal gyrus can be considered without risking aphasia [42,43]. This is possible, firstly, because Broca's area is not the final common pathway for speech as recently shown on a probabilist atlas based on over 700 cerebral stimulations [44] and, secondly, because this area can be compensated by recruitment of adjacent regions, primarily the ventral premotor cortex (the crucial epicenter for speech articulation), and the pars orbitaris of the inferior frontal gyrus, the prefrontal dorsal lateral cortex or the insula [42,43]. A transopercular surgical approach through Broca's area has even been proposed in insular tumor surgery, (non-infiltrated in this case) in order to avoid opening the Sylvian fissure and therefore reducing vascular risks. A zero complication rate has been reported with this approach, in contrast to perceived wisdom [45];
- *Resection of a DLGG infiltrating Wernicke's area:* The language compensation following resection of the posterosuperior part of the left temporal lobe (and its junction with the inferior parietal lobule) can be explained by organization of this complex function into remote networks. As a result, in addition to recruiting areas immediately around the lesion, reorganization may also involve remote lesions in the left hemisphere (particularly the supramarginal gyrus and also the pars triangularis of the inferior frontal gyrus) and contralateral sites in the right hemisphere because of transcallosal disinhibition [46];
- *Resection of insular DLGG:* In our experience, over 98% of patients have recovered active life after insular surgery (2 patients developed complications of hemiparesis because of a deep stroke due to injury to the lenticulostriate arteries) [47,48]. Quality of life was even improved in approximately a third of patients who had epilepsy which was refractory to preoperative medical treatment, and in whom removal of the insular tissue, and even where necessary, additional removal of the temporomesial structures controlled the seizures [49]. In addition, it has been possible to remove the claustrum with no cognitive deficit (despite the assumed role of this structure in awareness) [50], in some cases of fronto-temporo-insular DLGG also infiltrating the deep subinsular structures, together with the lateral part of the gray nuclei without causing movement disorders. This is after long-term follow-up of over 10 years. It is likely that recruitment of parallel circuits involving the pallido-luyso-pallidal network, striato-nigro-striatal, cortico-striato-nigro-thalamo-cortical and cortico-luysal networks explain this compensation [51];
- *Resection of DLGG infiltrating the primary sensorimotor area for the face:* Despite transient cerebral facial paralysis, the bilateral hemispheric cortical representation of this function explains why all patients have recovered. It is possible however that if the insula is also invaded, a non-permanent Foix-Chavany-Marie syndrome may be produced with bilateral transient orofacial pharyngeal laryngeal paralysis. [52];

- *Resection of DLGG from the primary motor area for the arm:* The ''rigid'' somatotopic organization of the homunculus needs to be replaced by a more dynamic vision of the functioning of sensorimotor areas, based on the fact that there are redundancies, both within the primary motor cortex and between the pre- and retrocentral regions. Stimulation of the precentral gyrus can consistently produce somatosensory responses, whereas stimulations of the retrocentral gyrus may lead to involuntary muscle contractions or even stop movement—indicating the existence of a complex central network and not a succession of discrete independent sites [53]. Unmasking of the latent subnetworks can therefore be demonstrated in real time in the operating theater, allowing sensorimotor maps to be reorganized within an hour and permitting more complete resection without causing deficit: these are short term plasticity mechanisms [54,55]. Conversely, long-term redistribution effects (such as years later during reoperation) may also occur, optimizing tumor resection, including surgery in the ''knob of the hand'' compared to the initial surgery [56];
- *Resection of DLGG in the primary sensorimotor area:* In addition to the dynamic organization of the whole central region referred to above, the same local mechanisms may be seen in the retrocentral region, as in the precentral region, i.e. unmasking of redundancies. In addition, recruitment of secondary somatosensory areas of the posterior parietal cortex and their contralateral equivalents contribute to functional compensation to various degrees, depending on the patient [57];
- *Resection of DLGG infiltrating the supplementary motor area:* This resection generally causes transient symptoms of akinesia (which may be complete) and mutism (particularly after surgery to the left supplementary motor area), which improves rapidly over around 10 days and then resolves after a few weeks (usually after intensive rehabilitation) [58]. Pre- and postoperative fMRI has shown activation of the supplementary motor area and contralateral premotor cortex contributing to recovery [59]. A more detailed cognitive examination however may nevertheless reveal persistent subtle but objective long-term problems, particularly with complex movements and/or bimanual coordination. For this reason, preservation of networks involved in movement control may be considered in some patients in order to preserve excellent quality of life (in a pianist for example) [60];
- *Resection of DLGG infiltrating the superior parietal lobe:* Despite the possibility of transient ataxia and/or hemineglect immediately after the procedure, patients recover in terms of their visuospatial cognition after appropriate functional rehabilitation. This includes surgery to the left hemisphere, occasionally even achieving improvements compared to the patient's preoperative state, particularly in pointing tests [7].

Serial surgery with induced plasticity

If complete resection cannot be performed for functional reasons, one or more revision procedures may be considered, which impact on survival and preserve cerebral functions [61]. Awake surgery has also enabled one or more revision procedures to be performed with preservation of function and improving the extent of resection, including eloquent areas, using cerebral plasticity mechanisms, which have developed between two surgical procedures. This reorganization has been seen in the same patient over time by repeating non-invasive functional neuroimaging investigations before and after excision [62]. Whilst fMRI suffers from poor reliability (as described above), a comparison between two investigations is however of some benefit, particularly if map remodeling is seen. In this context, several years after an initial complete resection of further fMRI has shown significant changes in the site of activations during the same task (for example activation in the precentral sulcus before initial surgery during movement, changing to activation in the central sulcus during the same movement in the same patient five years later) at the same time demonstrating recruitment of areas which were not initially inactivated (such as activations in the contralateral hemisphere on a postoperative follow-up fMRI, whereas no activation could be found before surgery) [62].

These widespread reorganizations appear to be due to several factors. Firstly, the surgical resection itself may cause hyperexcitability around the lesion, as in the case of any ''brain injury'' helping to unmask latent networks. This is occasionally seen in the short term as the resection proceeds [55]. In addition, wide resections, particularly if complete on imaging, improve control of the epilepsy in approximately 80% of cases, particularly in patients with prolonged preoperative epilepsy, which again may improve the plasticity potential, as the seizures have been modeled as a limitation to neuroplasticity [63]. In addition, progression of the residual DLGG probably helps to continue to trigger map remodeling, a process which was already ongoing before the surgery. Furthermore, provided that individualized cognitive and functional rehabilitation is provided in the early postoperative phase, neuropsychological improvements have even been seen in 30% of patients after resection—particularly in terms of working memory [64]. One recent randomized trial has shown that cognitive rehabilitation had a beneficial impact on short and long-term cognitive complaints and on mental fatigue in patients with gliomas [65], suggesting that such rehabilitation plays a significant role on neuroplasticity.

In summary, early surgery which is as radical as possible should be considered first line in DLGG, as it has a beneficial impact both on survival and quality of life, as a result of the recruitment of a plastic potential, which until now has been underestimated on the basis of a static view of central nervous system functioning, part of which is in fact a major component of the connectome model [3].

The connectome: a limiting factor for neuroplasticity

The paradox of this dynamic model is that on one hand, the connectome represents the bed for redistribution of subcircuits, which may be compensated by others in a complex large-scale network, but on the other hand, any damage to this neuronal network leads to a severe permanent deficit [3]. This implies that subcortical connectivity must be preserved because of the very low plasticity potential in the main white matter pathways, which represent the ''minimal

common brain'' [24]. Put in other words, cortical mapping is necessary, but not sufficient, to preserve the eloquent epicenters: direct stimulation of association bundles is absolutely crucial in this hodotopic organization in order to be able to benefit as a result of the recruitment mechanisms for areas around the lesions, remote intrahemispheric and contralateral areas.

Although the human cerebral connectome is far from having released all of its secrets, a number of essential pathways are now well known because of recent studies based on tractography, postmortem anatomical dissection and intraoperative axonal stimulation in awake patients:

- *Sensorimotor network:* Whilst it is well known that direct stimulation of pyramidal fibers causes involuntary muscle contraction (whether the stimulation is delivered to the corona radiata, posterior arm of the internal capsule or brain stem) and that direct stimulation of somatosensory thalamocortical fibers produces reproducible dysesthesia [66], limited information is available at present however on the ''negative motor network''. This is a large circuit which passes anterior to the corticospinal bundle (probably coming from the supplementary motor area, the lateral premotor cortex and the depth of the precentral sulcus) and also another posterior circuit with primary somatosensory fibers, both of these being interconnected by U fibers passing beneath the central region. In all situations, stimulation of this network generates movement control problems, which may range from complete arrest of movement (unilateral or even bilateral in a bimanual coordination task) to involuntary acceleration of movement [53,67]. Damage to this connectivity may cause a permanent deficit in complex movements even after recovery from a possible transient postoperative supplementary motor area syndrome [60]. Again, the dichotomy between ''precentral motor and retrocentral sensory' needs to be revisited in new connectionist models, which are the only ones that can explain the observations seen in the operating theater;
- *Visuospatial network:* Whereas any damage to the optic radiations leads to a permanent visual field deficit, which may be incapacitating in everyday life (particularly if it causes homonymous hemianopia as this prevents the patient from driving, if only for medicolegal reasons), very few studies have examined intraoperatively optic tract mapping. A new protocol intended to show two images to the conscious patient spread over two opposite quadrants on the same computer screen has recently shown that it is possible to generate a transient visual field deficit described by the patient, which can be confirmed objectively with this test (only one of the two objects was seen and therefore described) during direct axonal stimulation of the bundle. It has therefore become possible to avoid hemianopia in over 95% of patients with DLGG infiltrating (or in immediate contact with) the optic radiations [68]. Furthermore, stimulation of part of the superior longitudinal fascicle (SLF II) in the right hemisphere may produce spatial cognition problems. These stimulations generate right deviation in a line bisection test, a point when deep surgical resection must be stopped—otherwise any damage to the SLF II will cause hemineglect [69]. Finally, stimulation of another subcircuit in the right SLF can also cause a central vestibular syndrome with severe dizziness [70];
- *Language and cognitive network:* Schematically, the language network is supported by two main pathways, which work both in parallel and interact: the phonologic dorsal pathway and the semantic ventral pathway [71]. The dorsal pathway is supported by the SLF and is formed from two subparts [72]. The deep part is the classical arcuate bundle, which connects the posterior temporal structures (mostly the middle and inferior gyri) to the inferior frontal gyrus, and which results in conductive aphasia when stimulated (i.e., a combination of semantic paraphasia and a repetition disorder) [73,74]. The lateral portion, which is the classical ''SLF III'', connects the junction between the posterior part of the superior temporal gyrus and the inferior parietal lobe, with the ventral premotor cortex, and causes articulation problems when stimulated [75]. The ventral pathway is itself divided into a direct bundle, the inferior frontal occipital fascicle (IFOF), and an indirect pathway formed by the inferior longitudinal fascicle and the uncinate fascicle, relaying between each other in the temporal pole [76]. In both situations, these pathways connect the occipital areas and the occipito-temporal junction with the anterior frontal regions. This is the reason why the left anterior resection may be carried out with ablation of the indirect pathway (particularly the temporal pole) without causing language problems, because of compensation by the IFOF [77]. This itself is made up of two ''layers'', one superficial and one deep [78]. Stimulation of the superficial layer causes systemic semantic paraphasia, indicating a major contribution from this subnetwork in understanding of language [79]. Axonal stimulation of the deep layer causes non-verbal semantic information processing problems involving any comprehension of a task in a semantic association test. It even appears that the IFOF, the most important bundle in human beings (whereas it does not exist in the primate) is involved in noetic consciousness [80]. The specific role of the middle longitudinal fascicle in the semantic processes remains a subject of discussion [81];
- *Mentalization network:* Preserving movements, language and cognition (executive functions, judgments, working memory, etc.) is obviously essential in DLGG surgery, although these aspects alone are not sufficient. It is also essential to map the networks involved in behavior in order to enable patients to return to a normal occupational life by preserving social cognition [82]. For this reason, emotion recognition tasks are performed on awake patients in order to improve understanding of and preserve structures, which support mentalization [83]. It has recently been shown that this function itself is made possible by parallel functioning of at least two subcircuits: the first, in which the SLF plays a major role, is involved in theory of mind, the ability to appreciate other people's emotions; the second, supported mostly by the cingulum, is essential for high level mental processing, i.e. the ability to infer others' intentions. Damage to either of these fascicles may lead to behavioral problems, which may mimic some psychiatric disorders such as autism [84].

Because of this, resections in DLGG, a chronic diffuse disease, must be carried out as early as possible from the time of diagnosis, before massive invasion of the subcortical connectivity which, if it is infiltrated, should be preserved surgically, resulting in incomplete resection in order to avoid reducing quality of life and then has a more modest or no impact on median survival. Adjuvant oncology therapy with first line chemotherapy should then be considered in the case of partial resection [19].

Conclusions and future prospects

Improved our understanding of neuroplasticity mechanisms in a connectionist context has enabled the extent of surgical resection for DLGG infiltrating regions conventionally considered to be ''eloquent'' and therefore inoperable to be optimized with a very low permanent neurological deficit rate (under 2%) [38,85]. Quite the reverse, apart from significantly improving median survival, wide resections have also optimized quality of life by better control of epileptic seizures [26]. These results have led to the recent proposal for a routine MR screening policy in a selected group of the general population (particularly young adults) [86]. As the risk of causing postoperative functional problems is minimal and the likelihood of complete or even supratotal resection is optimized in asymptomatic patients (as the tumor volume is lower), this approach is wholly justified [87] particularly as the potential for plasticity has not yet reached its limit, as by definition no epileptic seizures have yet developed [63].

In parallel to oncological aspects, this hodotopic view of the functioning of the central nervous system, which is a complete departure from the locationist theory, now allows new functional anatomical models to be constructed which are useful not only for brain surgery, but also for neurology, psychiatry and fundamental neurosciences [71,84]. Based on this revisited knowledge of the cerebral connectome supporting neuroplasticity, the next stage may be to move towards functional restoration surgery, particularly for aphasic patients, by optimizing the neuromodulation principles of neurosynaptic networks, or even from research into the brain-machine interface [88].

TAKE-HOME MESSAGES

Diffuse low-grade gliomas

- Diffuse low-grade glioma is not a stable tumor, but invariably progresses.
- Its volume and growth curve should be calculated objectively in all patients before and after each stage of treatment.
- Diffuse low-grade glioma is not a benign tumor but a pre-malignant one and inevitably transforms into high-grade glioma.
- The tumor is a chronic diffuse disease which spreads along the white matter pathways.
- Infiltration of subcortical connectivity is responsible for cognitive disorders.
- The watch and wait approach after diagnosis should now be completely abandoned.
- Early wide surgical resection doubles median survival at the same time controlling epilepsy in the majority of cases.
- Resection of a low-grade glioma invading ''eloquent'' cerebral regions is made possible by neuroplasticity mechanisms induced by tumor growth.

Neuroplasticity

- Cerebral function cannot be explained by a locationist theory but by a hodotopic one, i.e. interactive and dynamic networks arranged in parallel.
- In a connectionist model, Broca's region is not the area responsible for speech.
- Cerebral plasticity potential has long been underestimated and enables massive resections to be made in the ''eloquent'' areas without causing complications.
- Functional imaging, despite not being reliable, is a valuable tool to study neuroplasticity by repeat investigations before and after the procedure(s).
- Awake surgery with direct electrical cerebral stimulation is the only current technique which provides not only cortical but also axonal mapping.
- The connectome is essential for neuroplasticity, i.e. the subcortical connectivity must be preserved surgically to avoid complications.
- Only an understanding of the dynamics between the natural history of the glioma and the individual plasticity index can be used to decide on an appropriate treatment strategy.

Clinical Case

This is a 34-year-old, right-handed female patient, who is a nurse, married with two children, and a normal family, social and occupational life until she developed an episode of partial epilepsy with transient language disorders. The patient completely recovered a few minutes after the seizure and her neurological examination was normal. A neurological assessment however showed minimal but objective problems with verbal working memory. A cerebral MR was performed (Fig. 1a).

Questions

1. What is the diagnosis?
2. What is the management?
3. How do you interpret the postoperative MR and what should be recommended?

Answers

1) This is a left, mostly fronto-insular, paralimbic lesion, hyperintense on FLAIR weighted imaging (sagittal section, Fig. 1a, left) and hypointense without enhancement on T1 weighted imaging (coronal section, Fig. 1a, right), 115 cc in volume, representing a diffuse low-grade

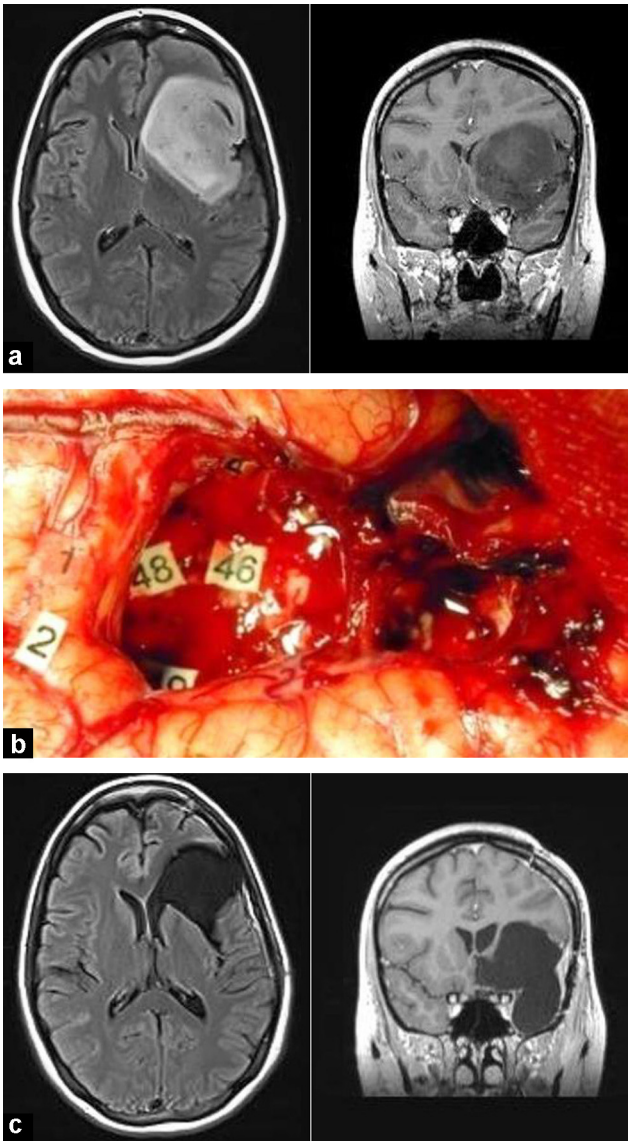

Figure 1. Left fronto-insular paralimbic lesion, hyperintense on FLAIR weighted imaging (a, left) and hypointense without enhancement on T1 weighted imaging (a, right): awake surgery with individual intraoperative mapping (b). Postoperative MR shows complete resection both on the FLAIR weighted image (c, left) and on the T1 weighted image after enhancement (c, right).

glioma in the context (first episode of partial epilepsy in a patient between 30 and 40 years old).

2) In view of the volume of the tumor and risk of malignant transformation, the patient should be referred to a neurosurgeon in order to consider maximal surgical resection. Such a resection may significantly reduce the risk of degeneration, at the same time providing reliable histological evidence as this is performed on the main part of the tumor (unlike a biopsy, where there is a serious risk of underscoring the grade of glioma). On the other hand, as it is closely located to ''eloquent'' structures, awake surgery with individual intraoperative mapping can be used to optimize the extent of the resection carried out within functional cortico-subcortical limits is indicated (Fig. 1b, the figures represent the crucial areas both in the cortex and the white matter association bundles).
3) The postoperative MR shows complete resection both on the FLAIR weighted view (coronal section, Fig. 1c, left) and on enhanced T1 weighted image (coronal section, Fig. 1c, right). The patient fully recovered neurologically and neuropsychologically because of neuroplasticity mechanisms, despite removal of Broca's area on the left in a right-handed patient. As a result of intensive cognitive rehabilitation during the immediate postoperative period, the patient even improved compared to her preoperative assessment (particularly in terms of working memory). She was able to return to her professional activities and had no further epileptic seizures. Histology confirmed a diagnosis of grade II glioma by the WHO classification and simple six-monthly MR follow-up was started without adjuvant oncology therapy (neither chemotherapy nor radiotherapy). No recurrence had occurred after follow-up for 4 years.

Disclosure of interest

The author declares that he has no conflicts of interest concerning this article.

References

[1] Duffau H. Diffuse low-grade glioma in adults: natural history, interaction with the brain, and new individualized therapeutic strategies. London: Springer; 2013.
[2] Duffau H. Lessons from brain mapping in surgery for low-grade glioma: insights into associations between tumour and brain plasticity. Lancet Neurol 2005;4:476—86.
[3] Duffau H. The huge plastic potential of adult brain and the role of connectomics: New insights provided by serial mappings in glioma surgery. Cortex 2013, http://dx.doi.org/10.1016/j.cortex.2013.08.005 [pii: S0010-9452(13)00207-4. Epub ahead of print].
[4] De Benedictis A, Duffau H. Brain hodotopy: from esoteric concept to practical surgical applications. Neurosurgery 2011;68:1709—23.
[5] Duffau H. Brain plasticity and tumors. Adv Tech Stand Neurosurg 2008;3:3—33.
[6] Duffau H. Brain plasticity: from pathophysiological mechanisms to therapeutic applications. J Clin Neurosci 2006;13:885—97.
[7] Desmurget M, Bonnetblanc F, Duffau H. Contrasting acute and slow-growing lesions: a new door to brain plasticity. Brain 2007;130:898—914.
[8] Ius T, Angelini E, Thiebaut de Schotten M, Mandonnet E, Duffau H. Evidence for potentials and limitations of brain plasticity using an atlas of functional resectability of WHO grade II gliomas: towards a ''minimal common brain''. Neuroimage 2001;56:992—1000.
[9] Duffau H. Brain mapping: from neural basis of cognition to surgical applications. New York: Springer Wien; 2011.
[10] Pallud J, Taillandier L, Capelle L, Fontaine D, Peyre M, Ducray F, et al. Quantitative morphological magnetic resonance imaging follow-up of low-grade glioma: a plea for systematic measurement of growth rates. Neurosurgery 2012;71:729—39.
[11] van den Bent MJ, Wefel JS, Schiff D, Taphoorn MJ, Jaeckle K, Junck L, et al. Response assessment in neuro-oncology (a report of the RANO group): assessment of outcome in trials of diffuse low-grade gliomas. Lancet Oncol 2011;12:583—93.

[12] Jakola AS, Myrmel KS, Kloster R, Torp SH, Lindal S, Unsgård G, et al. Comparison of a strategy favoring early surgical resection vs a strategy favoring watchful waiting in low-grade gliomas. JAMA 2012;308:1881—8.
[13] Duffau H, Capelle L. Preferential brain locations of low-grade gliomas. Cancer 2004;100:2622—6.
[14] Duffau H. Cognitive assessment in glioma patients. J Neurosurg 2013;119:1348—9.
[15] Almairac F, Herbet G, Moritz-Gasser S, de Champfleur NM, Duffau H. The left inferior fronto-occipital fasciculus subserves language semantics: a multilevel lesion study. Brain Struct Funct 2014 [Epub ahead of print].
[16] Klein M, Duffau H, De Witt Hamer PC. Cognition and resective surgery for diffuse infiltrative glioma: an overview. J Neurooncol 2012;108:309—18.
[17] Duffau H. The challenge to remove diffuse low-grade gliomas while preserving brain functions. Acta Neurochir (Vienna) 2012;154:569—74.
[18] Berger MS, Deliganis AV, Dobbins J, Keles GE. The effect of extent of resection on recurrence in patients with low-grade cerebral hemisphere gliomas. Cancer 1994;74:1784—91.
[19] Duffau H, Taillandier L. New concepts in the management of diffuse low-grade glioma: proposal of a multi-stage and individualized therapeutic approach. Neuro Oncol 2014, http://dx.doi.org/10.1093/neuonc/nou153 [Epub ahead of print, (PMID: 25087230)].
[20] Duffau H, Lopes M, Arthuis F, Bitar A, Sichez JP, van Effenterre R, et al. Contribution of intraoperative electrical stimulations in surgery of low-grade gliomas: a comparative study between two series without (1985-96) and with (1996-2003) functional mapping in the same institution. J Neurol Neurosurg Psychiatry 2005;76:845—51.
[21] Smits JS, Chang EF, Lamborn KR, Chang SM, Prados MD, Cha S, et al. Role of extent of resection in the long-term outcome of low-grade hemispheric gliomas. J Clin Oncol 2008;26:1338—45.
[22] Schomas DA, Lack NN, Rao RD, Meyer FB, Shaw EG, O'Neill BP, et al. Intracranial low-grade gliomas in adults: 30-year experience with long-term follow-up at Mayo Clinic. Neurooncol 2009;11:437—45.
[23] McGirt MJ, Chaichana KL, Attenello FJ, Weingart JD, Than K, Burger PC, et al. Extent of surgical resection is independently associated with survival in patients with hemispheric infiltrating low-grade gliomas. Neurosurgery 2008;63:700—7.
[24] Ius T, Isola M, Budai R, Pauletto G, Tomasino B, Fadiga L, et al. Low-grade glioma surgery in eloquent areas: volumetric analysis of extent of resection and its impact on overall survival. A single-institution experience in 190 patients. J Neurosurg 2012;117:1039—52.
[25] Capelle L, Fontaine D, Mandonnet E, Taillandier L, Golmard JL, Bauchet L, et al. Spontaneous and therapeutic prognostic factors in adult hemispheric WHO grade II gliomas: a series of 1097 cases. J Neurosurg 2013;118:1157—68.
[26] Pallud J, Audureau E, Blonski M, Sanai N, Bauchet L, Fontaine D, et al. Epileptic seizures in diffuse low-grade gliomas in adults. Brain 2014;137:449—62.
[27] Sanai N, Chang S, Berger MS. Low-grade gliomas in adults. J Neurosurg 2011;115:948—65.
[28] Duffau H. Awake surgery for incidental WHO grade II gliomas involving eloquent areas. Acta Neurochir (Vienna) 2012;154:575—84.
[29] Soffietti R, Baumert B, Bello L, et al. Guidelines on management of low-grade gliomas: report of an EFNS-EANO task force. Eur J Neurol 2010;17:1124—33.
[30] Duffau H. The dangers of magnetic resonance imaging diffusion tensor tractography in brain surgery. World Neurosurg 2014;81:56—8.
[31] Giussani C, Roux FE, Ojemann J, Sganzerla EP, Pirillo D, Papagno C. Is preoperative functional magnetic resonance imaging reliable for language areas mapping in brain tumor surgery? Review of language functional magnetic resonance imaging and direct cortical stimulation correlation studies. Neurosurgery 2010;66:113—20.
[32] Vassal M, Le Bars E, Moritz-Gasser S, Menjot N, Duffau H. Crossed aphasia elicited by intraoperative cortical and subcortical stimulation in awake patients. J Neurosurg 2010;113:1251—8.
[33] Leclercq D, Duffau H, Delmaire C, Capelle L, Gatignol P, Ducros M, et al. Comparison of diffusion tensor imaging tractography of language tracts and intraoperative subcortical stimulations. J Neurosurg 2010;112:503—11.
[34] Duffau H. Diffusion Tensor Imaging Is a Research and Educational Tool, but Not Yet a Clinical Tool. World Neurosurg 2013, http://dx.doi.org/10.1016/j.wneu.2013.08.054 [pii: S1878-8750(13)01085-1. Epub ahead of print].
[35] Picht T, Krieg SM, Sollmann N, Rösler J, Niraula B, Neuvonen T, et al. A comparison of language mapping by preoperative navigated transcranial magnetic stimulation and direct cortical stimulation during awake surgery. Neurosurgery 2013;72:808—19.
[36] Penfield W, Bolchey E. Somatic motor and sensory representation in the cerebral cortex of man as studied by electrical stimulation. Brain 1937;60:389—443.
[37] Ojemann G, Ojemann J, Lettich E, Berger M. Cortical language localization in left, dominant hemisphere. An electrical stimulation mapping investigation in 117 patients. J Neurosurg 1989;71:316—26.
[38] Duffau H, Gatignol P, Mandonnet E, Capelle L, Taillandier L. Intraoperative subcortical stimulation mapping of language pathways in a consecutive series of 115 patients with Grade II glioma in the left dominant hemisphere. J Neurosurg 2008;109:461—71.
[39] Yordanova Y, Moritz-Gasser S, Duffau H. Awake surgery for WHO grade II gliomas within ''noneloquent'' areas in the left dominant hemisphere: toward a ''supratotal'' resection. J Neurosurg 2011;115:232—9.
[40] Duffau H, Mandonnet E. The ''onco-functional balance'' in surgery for diffuse low-grade glioma: integrating the extent of resection with quality of life. Acta Neurochir (Vienna) 2013;155:951—7.
[41] De Witt Hamer PC, Robles SG, Zwinderman AH, Duffau H, Berger MS. Impact of intraoperative stimulation brain mapping on glioma surgery outcome: a meta-analysis. J Clin Oncol 2012;30:2559—65.
[42] Benzagmout M, Gatignol P, Duffau H. Resection of WHO Health Organization Grade II gliomas involving Broca's area: methodological and functional considerations. Neurosurgery 2007;61:741—52.
[43] Duffau H. The ''frontal syndrome'' revisited: lessons from electrostimulation mapping studies. Cortex 2012;48:120—31.
[44] Tate MC, Herbet G, Moritz-Gasser S, Tate JE, Duffau H. Probabilistic map of critical functional regions of the human cerebral cortex: Broca's area revisited. Brain 2014 [pii: awu168. Epub ahead of print].
[45] Duffau H, Moritz-Gasser S, Gatignol P. Functional outcome after language mapping for insular World Health Organization Grade II gliomas in the dominant hemisphere: experience with 24 patients. Neurosurg Focus 2009;27:E7.
[46] Sarubbo S, Le Bars E, Moritz-Gasser S, Duffau H. Complete recovery after surgical resection of left Wernicke's area in awake patient: a brain stimulation and functional MRI study. Neurosurg Rev 2012;35:287—92.
[47] Duffau H, Taillandier L, Gatignol P, Capelle L. The insular lobe and brain plasticity: lessons from tumor surgery. Clin Neurol Neurosurg 2006;108:543—8.

[48] Duffau H. A personal consecutive series of surgically treated 51 cases of insular WHO Grade II glioma: advances and limitations. J Neurosurg 2009;110:696—708.
[49] Ghareeb F, Duffau H. Intractable epilepsy in paralimbic Word Health Organization Grade II gliomas: should the hippocampus be resected when not invaded by the tumor? J Neurosurg 2012;116:1226—34.
[50] Duffau H, Mandonnet E, Gatignol P, Capelle L. Functional compensation of the claustrum: lessons from low-grade glioma surgery. J Neurooncol 2007;81:327—9.
[51] Duffau H, Denvil D, Capelle L. Absence of movement disorders after surgical resection of glioma invading the right striatum. J Neurosurg 2002;97:363—9.
[52] Duffau H, Karachi C, Gatignol P, Capelle L. Transient Foix-Chavany-Marie syndrome after surgical resection of a right insulo-opercular low-grade glioma. Neurosurgery 2003;53:426—31.
[53] Almairac F, Herbet G, Moritz-Gasser S, Duffau H. Parietal network underlying movement control: disturbances during subcortical electrostimulation. Neurosurg Rev 2014 [Epub ahead of print].
[54] Duffau H, Sichez JP, Lehéricy S. Intraoperative unmasking of brain redundant motor sites during resection of a precentral angioma. Evidence using direct cortical stimulations. Ann Neurol 2000;47:132—5.
[55] Duffau H. Acute functional reorganisation of the human motor cortex during resection of central lesions: a study using intraoperative brain mapping. J Neurol Neurosurg Psychiatry 2001;70:506—13.
[56] Duffau H, Denvil D, Capelle L. Long-term reshaping of language, sensory and motor maps following glioma resection: a new parameter to integrate in the surgical strategy. J Neurol Neurosurg Psychiatry 2002;72:511—6.
[57] Duffau H, Capelle L. Functional recovery following lesions of the primary somatosensory fields. Study of the compensatory mechanisms. Neuro-Chirurgie 2001;47:557—63.
[58] Krainik A, Lehéricy S, Duffau H, Capelle L, Chainay H, Cornu P, et al. Postoperative speech disorder after medial frontal surgery: role of the supplementary motor area. Neurology 2003;60:587—94.
[59] Krainik A, Duffau H, Capelle L, Cornu P, Boch AL, Mangin JF, et al. Role of the healthy hemisphere in recovery after resection of the supplementary motor area. Neurology 2004;62:1323—32.
[60] Rech F, Herbet G, Moritz-Gasser S, Duffau H. Disruption of bimanual movement by unilateral subcortical electrostimulation. Hum Brain Mapp 2014;35:3439—45.
[61] Martino J, Taillandier L, Moritz-Gasser S, Gatignol P, Duffau H. Re-operation is a safe and effective therapeutic strategy in recurrent WHO grade II gliomas within eloquent areas. Acta Neurochir (Wien) 2009;151:427—36.
[62] Gil Robles S, Gatignol P, Lehéricy S, Duffau H. Long-term brain plasticity allowing multiple-stages surgical approach for WHO grade II gliomas in eloquent areas: a combined study using longitudinal functional MRI and intraoperative electrical stimulation. J Neurosurg 2008;109:615—24.
[63] Szalisznyo K, Silverstein DN, Duffau H, Smits A. Pathological neural attractor dynamics in slowly growing gliomas supports an optimal time frame for white matter plasticity. PLoS One 2013;8:e69798.
[64] Teixidor P, Gatignol P, Leroy M, Masuet-Aumatell C, Capelle L, Duffau H. Assessment of verbal working memory before and after surgery for low-grade glioma. J Neurooncol 2007;81:305—13.
[65] Gehring K, Sitskoorn MM, Gundy CM, Sikkes SA, Klein M, Postma TJ, et al:. Cognitive rehabilitation in patients with gliomas: a randomized, controlled trial. J Clin Oncol 2009;27:3712—22.
[66] Duffau H, Capelle L, Denvil D, Sichez N, Gatignol P, Taillandier L, et al. Usefulness of intraoperative electrical subcortical mapping during surgery for low-grade gliomas located within eloquent brain regions: functional results in a consecutive series of 103 patients. J Neurosurg 2003;98:764—78.
[67] Schucht P, Moritz-Gasser S, Herbet G, Raabe A, Duffau H. Subcortical electrostimulation to identify network subserving motor control. Hum Brain Mapp 2013;34:3023—30.
[68] Gras-Combes G, Moritz-Gasser S, Herbet G, Duffau H. Intraoperative subcortical electrical mapping of optic radiations in awake surgery for glioma involving visual pathways. J Neurosurg 2012;117:466—73.
[69] Thiebaut de Schotten M, Urbanski M, Duffau H, Volle E, Levy R, Dubois B, et al. Direct evidence for a parietal-frontal pathway subserving spatial awareness in humans. Science 2005;309:2226—8.
[70] Spena G, Gatignol P, Capelle L, Duffau H. Superior longitudinal fasciculus subserves vestibular network in humans. Neuroreport 2006;17:1403—6.
[71] Duffau H, Moritz-Gasser S, Mandonnet E. A re-examination of neural basis of language processing: proposal of a dynamic hodotopical model from data provided by brain stimulation mapping during picture naming. Brain Lang 2014;131:1—10.
[72] Martino J, De Witt Hamer PC, Berger MS, Lawton MT, Arnold CM, de Lucas EM, et al. Analysis of the subcomponents and cortical terminations of the perisylvian superior longitudinal fasciculus: a fiber dissection and DTI tractography study. Brain Struct Funct 2013;218:105—21.
[73] Maldonado IL, Moritz-Gasser S, Duffau H. Does the left superior longitudinal fascicle subserve language semantics? A brain electrostimulation study. Brain Struct Funct 2011;216:263—4.
[74] Moritz-Gasser S, Duffau H. The anatomo-functional connectivity of word repetition: insights provided by awake brain tumor surgery. Front Hum Neurosci 2013;7:405.
[75] van Geemen K, Herbet G, Moritz-Gasser S, Duffau H. Limited plastic potential of the left ventral premotor cortex in speech articulation: Evidence from intraoperative awake mapping in glioma patients. Hum Brain Mapp 2014;35:1587—96.
[76] Mandonnet E, Nouet A, Gatignol P, Capelle L, Duffau H. Does the left inferior longitudinal fasciculus play a role in language? A brain stimulation study. Brain 2007;130:623—9.
[77] Duffau H, Herbet G, Moritz-Gasser S. Toward a pluricomponent, multimodal, and dynamic organization of the ventral semantic stream in humans: lessons from stimulation mapping in awake patients. Front Syst Neurosci 2013;7:44.
[78] Sarubbo S, De Benedictis A, Maldonado IL, Basso G, Duffau H. Frontal terminations for the inferior fronto-occipital fascicle: anatomical dissection, DTI study and functional considerations on a multi-component bundle. Brain Struct Funct 2013;218:21—37.
[79] Duffau H, Gatignol P, Mandonnet E, Peruzzi P, Tzourio-Mazoyer N, Capelle L. New insights into the anatomo-functional connectivity of the semantic system: a study using cortico-subcortical stimulations. Brain 2005;128:797—810.
[80] Moritz-Gasser S, Herbet G, Duffau H. Mapping the connectivity underlying multimodal (verbal and non-verbal) semantic processing: a brain electrostimulation study. Neuropsychologia 2013;51:1814—22.
[81] De Witt Hamer P, Moritz-Gasser S, Gatignol P, Duffau H. Is the human left middle longitudinal fascicle essential for language? A brain electrostimulation study. Human Brain Mapp 2011;32:962—73.
[82] Herbet G, Lafargue G, Bonnetblanc F, Moritz-Gasser S, Duffau H. Is the right frontal cortex really crucial in the mentalizing network? A longitudinal study in patients with a slow-growing lesion. Cortex 2013;49:2711—27.
[83] Herbet G, Lafargue G, Moritz-Gasser S, Bonnetblanc F, Duffau H. Interfering with the neural activity of mirror-related frontal

areas impairs mentalistic inferences. Brain Struct Funct 2014 [Epub ahead of print].
[84] Herbet G, Lafargue G, Bonnetblanc F, Moritz-Gasser S, Menjot de Champfleur N, Duffau H. Inferring a dual-stream model of mentalizing from associative white matter fibres disconnection. Brain 2014;137:944—59.
[85] Sanai N, Mirzadeh Z, Berger MS. Functional outcome after language mapping for glioma resection. N Engl J Med 2008;358: 18—27.
[86] Mandonnet E, De Witt Hamer PC, Pallud J, Bauchet L, Whittle I, Duffau H. Silent diffuse low-grade glioma: towards screening and preventive treatment? Cancer 2014;120:1758—62.
[87] Duffau H. The rationale to perform early resection in incidental diffuse low-grade glioma: towards a ''preventive surgical neuro-oncology''. World Neurosurg 2013;80:e115—7.
[88] Mandonnet E, Duffau H. Understanding entangled cerebral networks: a prerequisite for restoring brain function with brain-computer interfaces. Front Syst Neurosci 2014;8:82.