doi:10.1093/brain/awl300 *Brain* (2007), **130**, 898–914

REVIEW ARTICLE

Contrasting acute and slow-growing lesions: a new door to brain plasticity

Michel Desmurget,[1] François Bonnetblanc[1] and Hugues Duffau[2]

[1]Brain and Vision Research, INSERM, U 371, Bron and [2]Department of Neurosurgery, UMR 678, UMPC, Hôpital Gui de Chauliac, CHU de Montpellier, France

Correspondence to: Hugues Duffau, MD, PhD, Department of Neurosurgery, Inserm U678, Hôpital Gui de Chauliac, CHU de Montpellier, 80 avenue Augustin Fliche, 34295 Montpellier Cedex 5, France
E-mail: h-duffau@chu-montpellier.fr

The concept of plasticity describes the mechanisms that rearrange cerebral organization following a brain injury. During the last century, plasticity has been mainly investigated in humans with acute strokes. It was then shown: (i) that the brain is organized into highly specialized functional areas, often designated 'eloquent' areas and (ii) that a lesion within the eloquent area gives rise to major irrevocable deficits. However, in sharp contrast with these observations, it was recently found that patients with low-grade gliomas were able to undergo massive cerebral resections without detectable functional consequence. In this paper, we tackle this puzzling observation and address the idea that brain plasticity cannot be fully understood and fruitfully studied without considering the temporal pattern of the injury inflicted to the brain. To achieve this goal, we first review experimental evidence showing that functional recovery is considerably better in the context of slow-growing injuries than after acute lesions. Both human and animal data are considered. In a second step, we emphasize that slow and acute lesions involve very different patterns of reorganization. In agreement with this idea, we show that the recruitment of remote brain areas in the ipsi- and contralesional hemispheres is much more efficient in slow growing than acute lesions. Finally in a last section, we briefly discuss the main implications of these results.

Keywords: brain plasticity; stroke; low-grade glioma; brain surgery; functional mapping

Abbreviations: DES = direct electrical stimulation; LGG = low grade gliomas; SMA = supplementary motor area; TMS = transcranial magnetic stimulation

Received May 6, 2006. Revised September 14, 2006. Accepted September 26, 2006. Advance Access publication November 21, 2006.

Downloaded from http://brain.oxfordjournals.org/ by guest on December 28, 2015

Introduction

In 1861, P. Broca reported the case of a patient who became unable to speak after a lesion of the rostral part of the left inferior frontal circumvolution. A few years later, in 1874, C. Wernicke described a 'mirror' subject whose lesion, in the posterior part of the left superior temporal gyrus, prevented any word comprehension. These two cases proved very influential. They established the methods and hypotheses of our modern neurophysiology. They suggested in particular that: (i) the brain is organized into highly specialized functional areas, often designated 'eloquent' areas; (ii) a lesion within the eloquent areas gives rise to major irrevocable deficits. Based on these premises, patients with ischaemic strokes were extensively studied during the last few decades. It was then found, in agreement with the original finding of Broca and Wernicke, that only a minority of stroke patients completely recovered. In most cases ischaemic injuries were reported to induce mild to severe permanent deficits (Stallones *et al.*, 1972; Varona *et al.*, 2004). This result gave rise to the idea that cerebral plasticity has very limited healing potential in the context of brain injuries. However, recent data on slow-growing lesions have called the generality of this conclusion into question by showing impressive recovery after massive cerebral lesions. In particular, the field of low-grade gliomas (LGG) have

© The Author (2006). Published by Oxford University Press on behalf of the Guarantors of Brain. All rights reserved. For Permissions, please email: journals.permissions@oxfordjournals.org

demonstrated that large amounts of cerebral tissue could be removed, inside or outside the so-called eloquent areas, without detectable functional consequences (Duffau *et al.*, 2003*a*). This finding nicely parallels some old reports in humans and animals. In humans, for instance, it was shown that large brain tumours did not prevent the patients from living a normal life (Jackson 1879, von Monakow, 1914). In monkeys, it was demonstrated that functional recovery was much better in slow-growing cerebral lesions than in acute brain destructions (Finger, 1978; Finger and Stein, 1982). Although these animal studies have been widely disregarded, they are of primary importance. Indeed, they indicate that the difference between acute and progressively growing lesions cannot be dismissed by simply arguing that strokes cause undetected damages in the peri-lesional tissue, that acute infarcts are more likely to occur in older patients, or that the surgical release of a tumour-related compression explains the good post-operative recovery (an often mentioned idea which does, in fact, not even apply to the non-compressive nature of LGG; Daumas-Duport *et al.*, 2005). When all the potentially confounding factors are controlled, as can be done in animal studies, functional recovery remains considerably better in slow growing than in acute lesions.

Previous publications have addressed the issue of functional recovery in the context of slow-growing injuries or acute strokes. The specificity and originality of this review is to directly compare the neural and behavioural outcomes of these two types of lesions. We believe that such a direct comparison is needed for at least two reasons. First, it shows that neural plasticity cannot be fully understood and fruitfully studied without considering the temporal pattern of the injury inflicted to the brain. Second, it creates a bridge between two fields of research that should 'feed' each other but generally unfold along parallel paths. Regarding this second point, one may note that the literature on slow-growing lesions has not yet abandoned the comfortable nest of neurooncology to become an established experimental paradigm. As observed by the authors of this review in two recent meetings, lesion data associated with slow-growing lesions lead often to skepticism or even distrust, when presented outside the field of neurooncology. The reason for these negative reactions is probably that slow-growing lesions tend to question and challenge our classical, modular view of brain architecture (Finger, 1978).

For the sake of clarity, the present review is organized in three sections. The first section focuses on behavioural observations. It shows that functional recovery is substantially better in the context of slow-growing injuries than after acute lesions. Both human and animal data are considered. The second section deals with the neural processes of brain plasticity. It shows that slow and acute lesions give rise to very different patterns of reorganization. The last section discusses briefly the fundamental and clinical implications of these results.

Acute strokes and slow-growing lesions: behavioural observations

Clinical observations in humans

Strokes

Strokes occur with high frequency, at least in occidental countries. For every million people, 2400 strokes are observed every year (Hankey and Warlow, 1999). Almost 50% of the 2400 stroke victims are unable to return to work. More than 70% of the patients still exhibit mild to severe functional deficits after 11 years (Varona *et al.*, 2004). These numbers agree with more ancient observations provided by Stallones *et al.* (1972). According to these authors, of every 100 survivors of the acute phase of a stroke, 10 will return to work without disability, 40 will have 'mild' disability, 40 will be severely disabled and 10 will require institutionalization. At the scale of the United States (300 million inhabitants), these values predict that 720 000 subjects will suffer a stroke every year. Among these subjects, 72 000 will recover totally, 288 000 will keep 'mild' functional deficits, 288 000 will be left with severe irreversible disabilities and 72 000 will require placement in a medical institution.

Low-grade gliomas

LGG (WHO Grade II gliomas) are slow-growing primary tumours of the CNS. In comparison to ischaemic strokes, these gliomas have a relatively rare occurrence. For instance, within a population of one million people only 10–20 individuals will be diagnosed with a LGG every year (Wessels *et al.*, 2003; Walker and Kaye, 2003). This means 3000–6000 cases at the scale of the United States. LGG progress slowly (4 mm per year on average Mandonnet *et al.*, 2003) for 7–8 years, until undertaking a fatal anaplastic transformation (Walker and Kaye, 2003). During this slow progression, a majority of LGG patients exhibit normal clinical exams (Walker and Kaye, 2003), even if slight cognitive disorders can be detected using extensive assessments (Taphoorn and Klein, 2004). In fact, in 80% of the patients, LGG are not revealed by behavioural deficits, but by the sudden occurrence of seizures (DeAngelis, 2001).

During the last decade, preventive resection of LGG has become a major therapeutic option. It was then found that major 'eloquent' regions could be removed without inducing permanent deficits. These regions include Broca's area (Fig. 1; Duffau *et al.*, 2000*a*, 2001*c*, 2002*b*), the left (Duffau *et al.*, 2001*c*) and right insula (Fig. 2; Duffau *et al.*, 2003*c*), the sensorimotor cortex (Duffau *et al.*, 1999; Duffau and Capelle, 2001*b*; Duffau, 2001, Fig. 3), the supplementary motor area (SMA, Krainik *et al.*, 2001; Fig. 4), the striatum (Duffau *et al.*, 2002*c*), the corpus callosum (Duffau *et al.*, 2004), the frontal eye fields (Milea *et al.*, 2002), the left angular gyrus (Duffau *et al.*, 2002*d*), the left posterior parietal cortex (Duffau *et al.*, 1999, 2002*a*, *d*; Fig. 5) and the right (Fig. 6) and left (Fig. 7) temporal lobes (Duffau *et al.*, 2002*a*, *b*; Gatignol *et al.*, 2004). In agreement with these

Downloaded from http://brain.oxfordjournals.org/ by guest on December 28, 2015

data, a recent meta-analysis reported that 93% of 103 patients harbouring LGG in various regions were both able to return to work within a year and free of identifiable functional deficits when submitted to classical clinical and neurological evaluations. The remaining patients (7%) showed only mild deficits (Duffau *et al.*, 2003*a*).

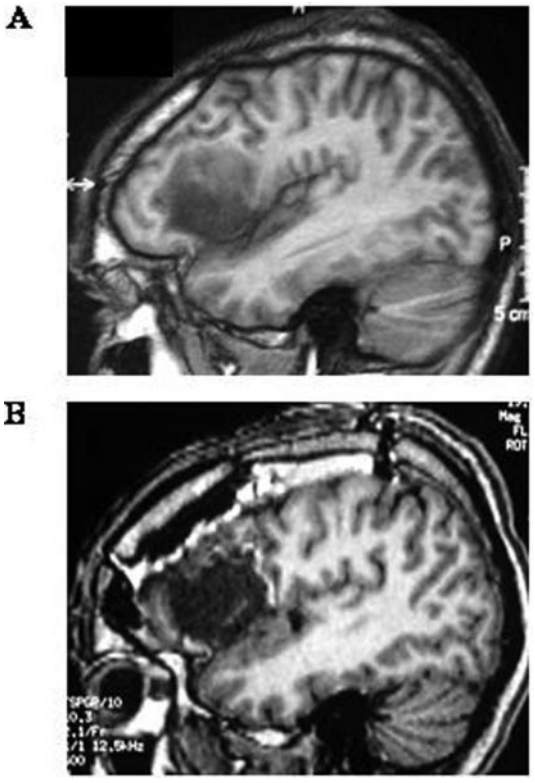

Fig. 1 (**A**) Pre-operative sagittal T_1-weighted MRI, showing a left LGG involving the fronto-opercular region (Broca's area). (**B**) Post-operative sagittal T_1-weighted MRI showing a total tumour removal. The patient neurological examination was normal before and after tumour removal.

The results above are even more impressive when contrasted with a similar, already mentioned, meta-analysis performed in stroke patients (Varona *et al.*, 2004, Fig. 8). In this analysis, 74% of patients presented mild to severe neurological deficits 11 years after the stroke. A complete recovery was only observed in 26% of the subjects. Only 30% of the patients were able to return to a normal professional life. An additional 20% were able to do so in an adapted environment. These high proportions of permanent deficits may seem puzzling when contrasted with stroke literature as a whole. Indeed, substantial levels of recovery are reported in many studies. This discrepancy is relatively easy to explain if one considers that stroke studies often aim to identify the neural processes underlying post-lesional plasticity. This leads to two biases: (i) focusing on very specific functions (e.g. language) without describing other non-relevant deficits (e.g. motor) potentially exhibited by the patients (e.g. Cao *et al.*, 1999; Calvert *et al.*, 2000; de Boissezon *et al.*, 2005; Longworth *et al.*, 2005); (ii) selecting patients for whom a good recovery is observed (e.g. Chollet *et al.*, 1991; Weiller *et al.*, 1993; Cao *et al.*, 1998; Cramer *et al.*, 2000; Johansen-Berg *et al.*, 2002*a*; Foltys *et al.*, 2003; Fridman *et al.*, 2004). As observed by Rijntjes and Weiller (2002) with respect to this latter point, 'for both the motor and language systems, it should be pointed out that usually only patients who have recovered well are reported. There is hardly any information about activation patterns in patients that recover poorly' (Rijntjes and Weiller 2002, p. 115).

Experimental observations in animals

The possibility that functional recovery is modulated by kinetic factors has been addressed in a series of animal

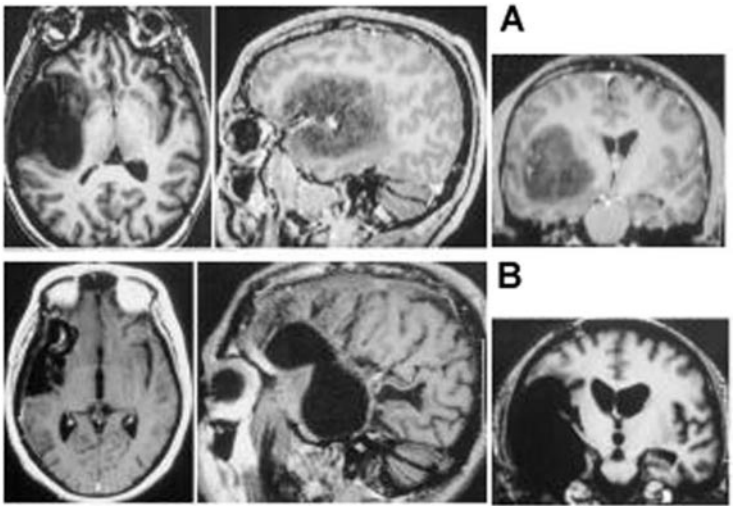

Fig. 2 (**A**) Pre-operative axial, sagittal and coronal views obtained by T_1-weighted MRI, showing a right fronto-temporo-insular non-enhanced LGG. (**B**) Corresponding post-operative views obtained by T_1-weighted MRI performed 3 months after surgery. The patient neurological examination was normal before and after tumour removal. (From Duffau *et al.*, 2000*a*.)

Downloaded from http://brain.oxfordjournals.org/ by guest on December 28, 2015

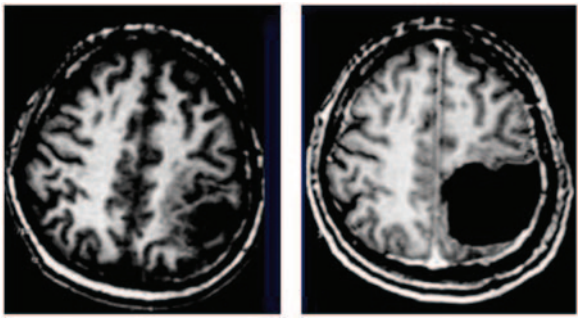

Fig. 3 Pre- (left) and post- (right) operative axial T_1-weighted MRI in a patient with a normal neurological examination, showing a left postcentral LGG.

studies. The main idea behind these studies was to mimic the development of slow-growing lesions by performing successive partial surgical ablations within a cerebral structure. These partial ablations were then compared to acute resections. In most experiments a control group was included. In this case several surgeries were performed but no cerebral tissue was removed ('sham' operation). Beyond some marginal disparities, the take-home message of all these studies is quite clear: the negative functional impact of large cerebral lesions is much smaller in progressive than acute lesions. For instance, in rats, it was shown that major deficits were still present 36 days after an acute ablation of the entire somatosensory cortex. These deficits were absent when the same area was removed in two stages. In this case, the experimental rats could not be differentiated from a non-operated control group (Finger *et al.*, 1971). Another similar, and even more spectacular, report was provided by Adametz (1959) in cats. The animals were submitted to a progressive (up to eight surgeries) or acute resection of the midbrain reticular formation. In this latter case, the cats fell into deep coma and died within a few days after the surgery. In the former case, by contrast, complete recovery was found. The same type of dissociation was observed in monkeys. Acute ablations of the prefrontal cortex were found to induce functional deficits that were much more severe than those produced by serial lesions (Rosen *et al.*, 1971).

Probably, the most direct demonstration that functional recovery is directly influenced by the kinetics of the lesion inflicted to the brain has been provided by Patrissi and Stein (1975). These authors trained a group of rats to retrieve water alternatively located in the right or the left branch of a conventional T-maze. Following a period of training, the rats were divided in four sub-groups: (i) one-stage bilateral resection of the frontal cortex; (ii) two-stage bilateral resection of the frontal cortex (one hemisphere per operation); (iii) one or two-stage sham operations (control group). For the two-stage groups, three inter-lesion intervals were considered: 10, 20 or 30 days. As shown in Fig. 9, the rats given sequential (two-stage) frontal lesions with either a 20 or 30 day inter-operative interval could not be differentiated from the sham-operated controls. Animals with two-stage lesions, produced 10 days apart, exhibited substantial deficits when contrasted with the sham-operated, the 20 or the 30 day two-stage groups. However, the two-stage 10 day animals performed significantly better than the one-stage rats. Similar results were found in other studies involving resections of the frontal cortex (Glick and Zimmerberg, 1972), the visual cortex (Meyer *et al.*, 1958) and the superior temporal gyri (Stewart and Ades, 1951). In all these studies, the animals were reported to exhibit a complete recovery when the different surgeries were spaced by a sufficient interval. This interval varied from study to study but it was never smaller than 6 days. Whatever the inter-lesion interval, the level of recovery was always better for the multi-stage surgeries than for the one-stage operations.

Of course, the positive effect of sequential lesions on functional recovery depends strongly on the amount of tissue resected at each surgical stage. This was clearly shown by Stein *et al.* (1977) in a monkey study involving the resection of the sulcus principalis. In this study, the total amount of tissue resected was kept constant. It was reported that four partial lesions performed three weeks apart produced a greater level of recovery than two partial lesions performed 10 weeks apart. This result pleads directly for the idea that the progressiveness of neural destruction is a key predictor of functional recuperation.

Acute strokes and slow-growing lesions: neurophysiological correlates

In the paragraphs above, we have shown that functional recovery was substantially better in the context of slow-growing lesions than after acute brain injuries. In the present section, we will investigate the neural counterparts of this disparity. It will be argued that progressive lesions allow a much greater and more thorough level of neural re-mapping than acute lesions. In this latter case, post-lesional recovery will be reported to involve mainly ipsilesional structures, especially in the regions adjacent to the injury. In the first case, by contrast, brain plasticity will be shown to rely on both adjacent and distant areas within the ipsi and contralesional hemispheres.

Stroke data

During the last decades, numerous studies have been performed with the purpose of identifying the functional anatomy of post-lesional recovery in stroke patients. At a first level, these studies have distinguished between passive and active recovery mechanisms (Seitz, 1997). Passive mechanisms refer to the non-plastic changes that take place during the acute phase of the infarct. With respect to this point, spontaneous reperfusions with subsequent regression of oxygen depletion, the progressive resolution of the injury response (oedema, inflammation) and the resolution of diaschisis have been shown to play an

Downloaded from http://brain.oxfordjournals.org/ by guest on December 28, 2015

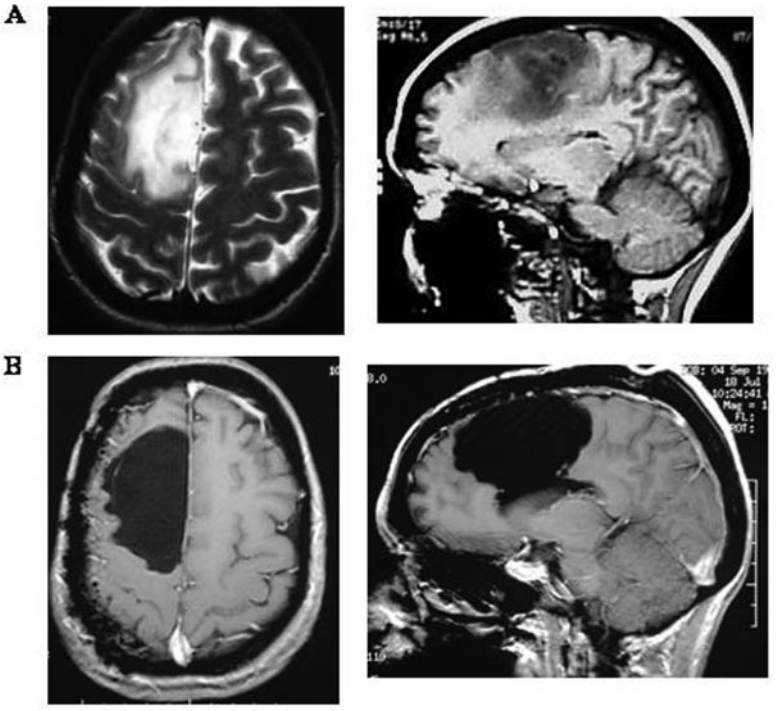

Fig. 4 (**A**) Pre-operative axial T_2-weighted and sagittal T_1-weighted MRI, showing a right medial precentral LGG, involving the supplementary motor area. (**B**) Post-operative axial and sagittal T_1-weighted MRI, showing a total glioma removal. The patient had an immediate post-surgical hemiplegia before recovering completely within 1 month.

important role in recovery (Inoue *et al.*, 1980; Kuhl *et al.*, 1980; Hakim *et al.*, 1987; Sakashita *et al.*, 1993; Heiss *et al.*, 1993; Furlan *et al.*, 1996; Cappa *et al.*, 1997; Toni *et al.*, 1997; Cramer and Bastings 2000; Croquelois *et al.*, 2003). Because the present review aims to investigate active brain plasticity, we will not discuss these passive recovery mechanisms any further.

Following the acute post-ischaemic phase, functional compensations start to take place. Of course, the nature of these reorganizations depends on the original architecture of the lesioned network. With respect to this point, the main message of the stroke literature may be that recovery is always substantially better when performed within the boundaries of the original (non-lesioned) network. For instance, language functions rely heavily on the left (dominant) hemisphere. As shown in several studies, when the left hemisphere regions are destroyed, some compensation occurs in the homologous structures of the right hemisphere (Gainotti 1993; Cao *et al.*, 1998; Heiss *et al.*, 2003). In this case however, the functional recovery is usually poor (Karbe *et al.*, 1998; Heiss *et al.*, 1999, 2003). As emphasized by Selnes (1999, p. 419), 'recruitment of right-hemisphere structures for language recovery is a last-resort type of strategy and one that yields a less than satisfactory overall degree of language recovery in most instances'. Within this context, it is not surprising that the best level of recovery is generally observed, in language functions, when compensatory recruitments take place in the peri-lesional area, along the rim of the injured tissue (Heiss *et al.*, 1993; Miura *et al.*, 1999; Herholtz *et al.*, 2000; Rosen *et al.*, 2000). It is worth mentioning, however, that some patients display good levels of recovery in the presence of non-dominant activations. For instance, Clavert *et al.* (2000) described the case of a patient who suffered a stroke in Broca's area and recovered well while showing an increased activation within the right homologous region. This type of compensation is usually thought to reflect the existence of an atypical, relatively large, bilateral language representation before the stroke (Rijntjes and Weiller, 2002).

Another well-documented example of 'intrinsic reorganizations' is provided by the motor system. In this case, functional control is not lateralized and the 'dominant' hemisphere is the one that is contralateral to the moving segment. After a stroke, physiological changes occurring in the damaged hemisphere seem to be more efficient in producing a good level of recovery than physiological changes occurring in the undamaged hemisphere. As emphasized by Hallett (2001, p. 172) 'contralateral control, even if reorganized, seems superior to ipsilateral control in recovery'. In agreement with this claim, transcranial magnetic stimulation (TMS) studies have repeatedly reported that the ability to trigger motor evoked potentials (MEP) from the lesioned hemisphere was the most reliable marker of good recovery (Heald *et al.*, 1993; Catano *et al.*, 1995, 1996; Misra *et al.*, 1995; Binkofski *et al.*, 1996; Rapisarda *et al.*, 1996; Turton *et al.*, 1996; Escudero *et al.*, 1998; Pennisi *et al.*, 1999; Bastings *et al.*, 2002; Ziemann, 2005). This observation is compatible with other data showing that

Downloaded from http://brain.oxfordjournals.org/ by guest on December 28, 2015

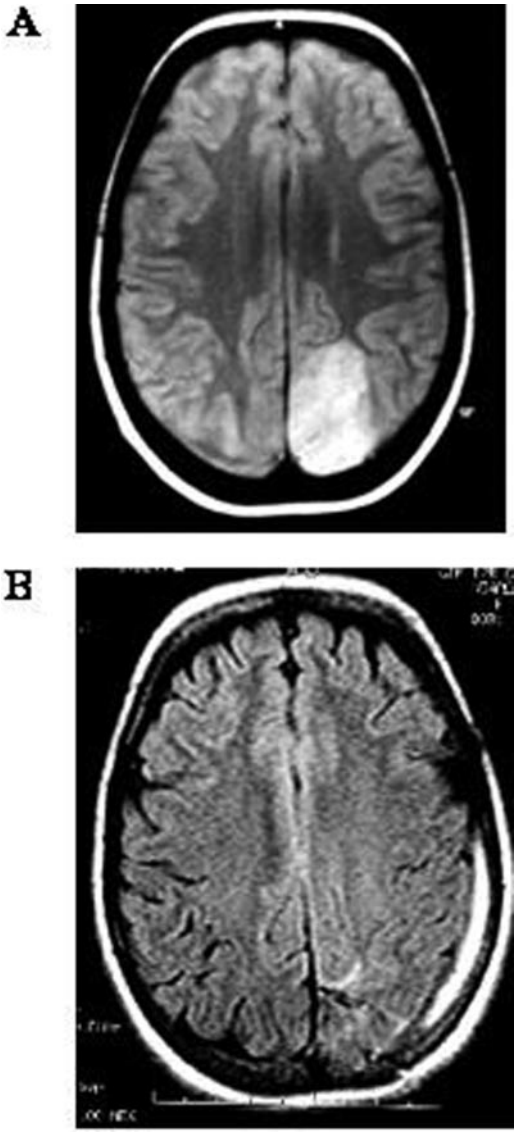

Fig. 5 (**A**) Pre-operative axial FLAIR-weighted MRI, showing a left LGG involving the superior parietal lobule. (**B**) Post-operative axial FLAIR-weighted MRI after surgery, showing a total tumour removal, with resection of the entire superior parietal lobule. The patient neurological examination was normal before and after tumour removal.

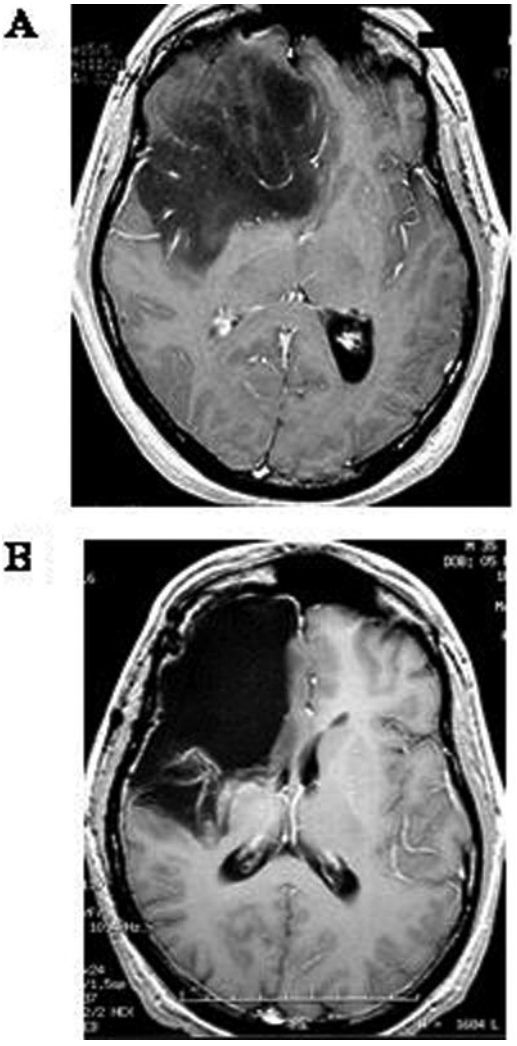

Fig. 6 (**A**) Pre-operative axial T_1-weighted MRI, showing a right fronto-temporo-insular LGG. (**B**) Post-operative axial T_1-weighted MRI, showing a total glioma removal, with resection of the entire right paralimbic system. The patient had an immediate post-surgical hemiparesia, and completely recovered within 3 months.

(i) contralesional TMS does not interfere with the performance of simple motor tasks, while ipsilesional TMS does (Werhahn *et al.*, 2003; Fridman *et al.*, 2004); (ii) motor maps are enlarged and/or displaced in the lesioned hemisphere of hemiparetic patients (Cicinelli *et al.*, 1997; Traversa *et al.*, 1997; Rossini *et al.*, 1998); (iii) motor improvements are associated with plastic reorganizations of the lesioned hemisphere during rehabilitative therapy (Liepert *et al.*, 2000; Johansen-Berg *et al.*, 2002*a*; Cramer, 2003). In line with this latter observation, several imaging studies have reported that the early recruitment of the contralesional sensorimotor cortex tended to vanish over time, as the paretic hand regained function (Marshall *et al.*, 2000; Calautti *et al.*, 2001). However, a recent study failed to reproduce this result (Feydy *et al.*, 2002).

Probably the best evidence for an intrinsic plasticity involving the original ipsilesional motor network comes from animal studies in which localized injuries were performed within the motor system. A good example of such studies is provided by Rouiller and colleagues who recently investigated the functional and neural consequences of brain lesions positioned within the hand territory of M1. Two experiments were conducted in newborn (Rouiller *et al.*, 1998) and mature (Liu and Rouiller, 1999) monkeys. In these experiments, the experimental lesions were combined with reversible inactivations to investigate cerebral reorganizations. As could be expected, very different results were obtained in the two studies. In the newborn investigation, the monkeys showed substantial, although partial, recovery

Downloaded from http://brain.oxfordjournals.org/ by guest on December 28, 2015

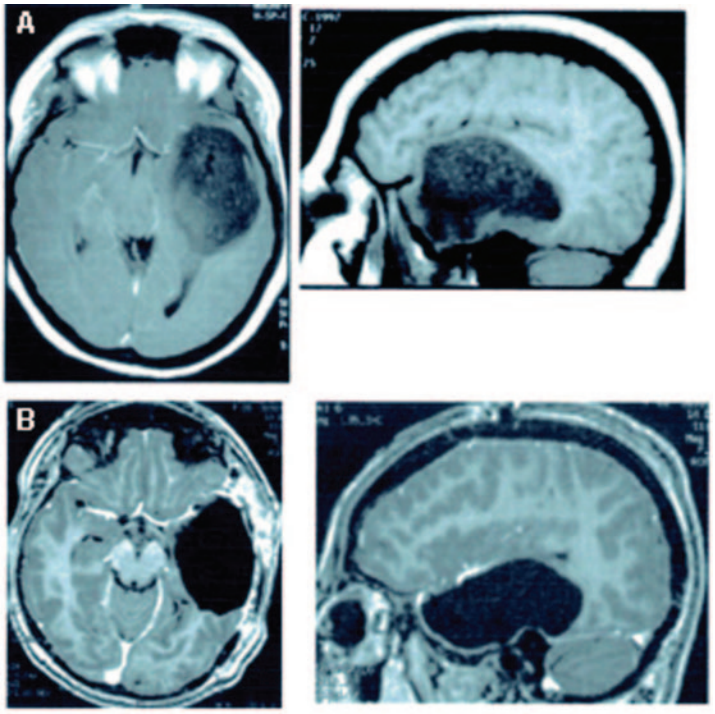

Fig. 7 (**A**) Pre-operative T_1-weighted axial and sagittal MRI showing a left temporal LGG. (**B**) Post-operative axial and sagittal MRI showing a total glioma resection. The patient neurological examination was normal before and after tumour removal. (from Duffau *et al.*, 2002*b*).

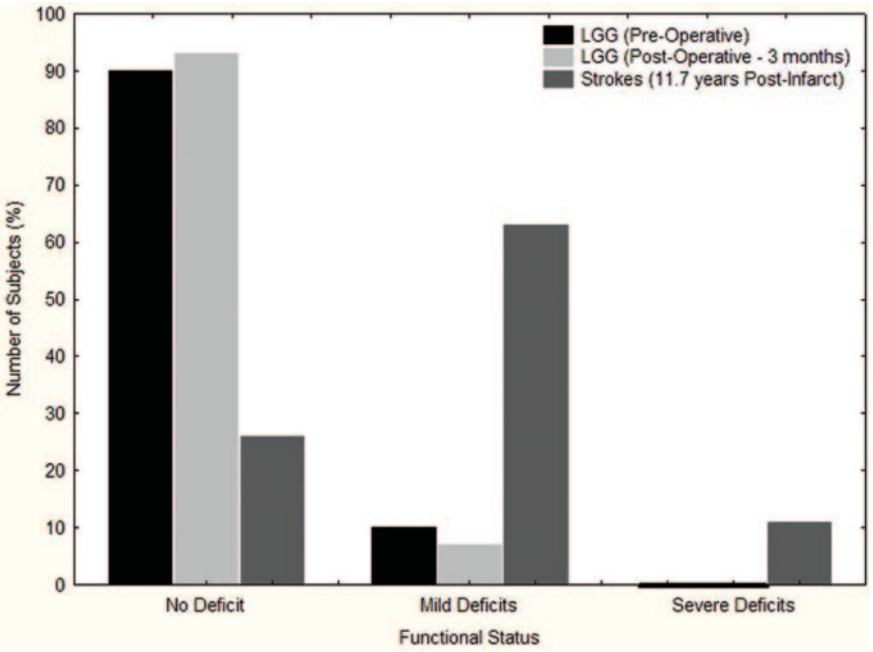

Fig. 8 Functional deficits as a percentage of the patient population following a stroke (dark grey) or a slow-growing tumoural invasion (black: LGG patients prior to resection; light-grey: LGG patients 3 months after resection). From Duffau *et al.* (2003*a*; 103 patients; mean age 36) and Varona *et al.* (2004; 272 patients; mean age 36).

(the functional score was >50% lower with the paretic than with the normal hand). This recovery was mediated by the development of a 'new' hand area in M1, adjacent to the lesioned territory. When this adjacent region was inactivated, the monkeys were no longer able to perform the prehension task for which they had been trained. In the adult study, more dramatic long-lasting deficits were observed. Nine months after the lesion, the functional

Downloaded from http://brain.oxfordjournals.org/ by guest on December 28, 2015

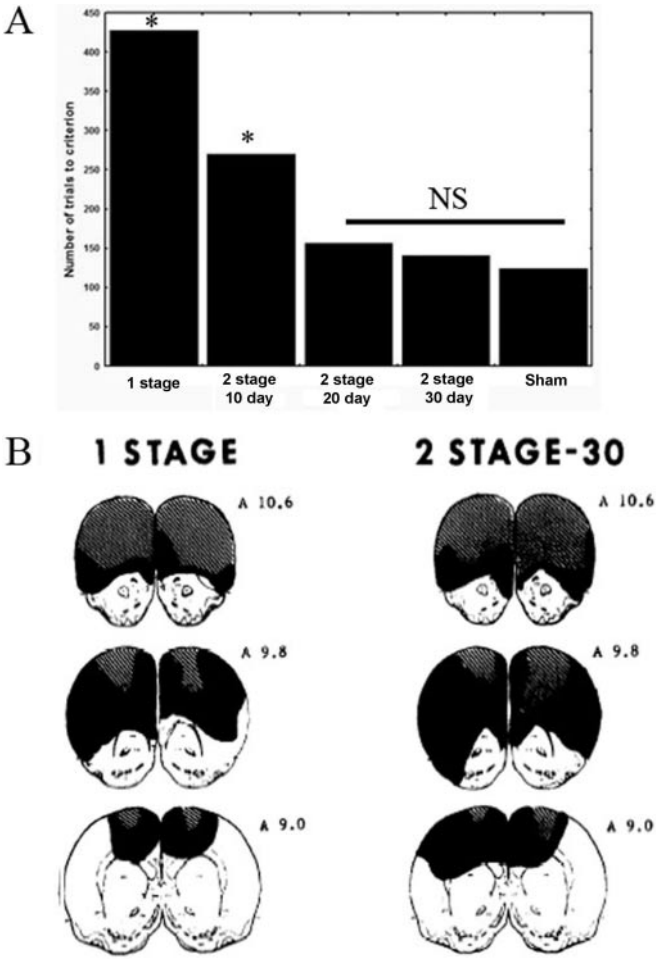

Fig. 9 (**A**) Number of trials necessary for rats submitted to different surgical patterns to reach the criterion level in a direct alternation task (two consecutive sessions of 16 trials, without errors). NS: no significant differences between groups; *: groups are different from all the other groups. (**B**) Coronal representation of the extent of damages for the one-stage and two-stages/30 days groups. (From Patrissi and Stein, 1975.)

score for the paretic hand reached a plateau at ~30% of the prelesion score. This partial recovery was found to be sustained by the non-primary motor areas within the lesioned hemisphere (premotor cortex and probably the supplementary and cingulate motor areas). In contrast to what had been observed in newborns, no reorganization was found within M1, around the lesioned area. Compatible results were provided by Frost *et al.* (2003) in an experiment requiring adult monkeys to retrieve pellets in wells of five different diameters. A peri-lesional re-mapping was however reported in another experiment in which the animals were submitted to a specific rehabilitative training (Nudo *et al.*, 1996).

In contrast with the human and animal data reported above, imaging studies have provided repeated indications that contralesional pathways are significantly involved in post-stroke recovery of motor functions. For instance, Chollet *et al.* (1991) used PET to investigate neural reorganizations in six patients who had recovered substantially from a capsular infraction. When motor activations associated with the recovered and normal hands were compared, increased responses were detected in the contralesional hemisphere in the sensorimotor cortex, the insula and the inferior parietal cortex. A significant signal was also identified in the cerebellum on the ispsilesional side. These data were replicated and generalized in subsequent studies. It was then shown, in hemiparetic patients, that the hand representation was displaced and/or enlarged bilaterally in most motor territories, including M1, the premotor cortex, the SMA, the retrocentral areas, the posterior parietal cortex and the insula (Weiller *et al.*, 1993; Maegaki *et al.*, 1995; Cramer *et al.*, 1997, 2000; Cao *et al.*, 1998; Seitz *et al.*, 1998; Chassoux *et al.*, 1999; Vandermeeren *et al.*, 2002; Pineiro *et al.*, 2001; Cramer, 1999). Three hypotheses have been proposed to account for these bilateral responses. First, some contralesional activations might be associated with the existence of mirror movements in the intact hand when intending to move the paretic hand (Weiller *et al.*, 1993; Marshall *et al.*, 2000). Second, the fact that ipsilesional motor regions play a dominant role in recovery does not mean that contralesional structures have no role to play. As emphasized in the previous paragraph, the contribution of distant contralesional structures may become more important, as a last-resort strategy, when the size of the infarct prevents ipsilesional recovery (Kolb, 1995; Kolb *et al.*, 2000; Hallett, 2001; Johansen-Berg *et al.*, 2002b; Ward, 2004). Third, contralesional activations may result from the suppression of transcallosal inhibition. The activations observed within the intact motor cortex in hemiparetic patients provide the best illustration for this idea. For M1, it has been shown that (i) the magnitude of the activations observed within the intact cortex did not correlate with functional recovery (Cao *et al.*, 1998); (ii) the neural activity in the contralesional M1 did occur after the onset of the motor response (Verleger *et al.*, 2003); (iii) a TMS-triggered disruption of the functioning of the contralesional M1 did not affect the response of the paretic hand in patients with various degrees of impairments (Werhahn *et al.*, 2003; Fridman *et al.*, 2004); (iv) the MEPs resulting from contralesional TMS did not correlate with the clinical improvement exhibited by the patients (Netz *et al.*, 1997). With respect to this latter point, it was even reported that contralesional MEPs were more prevalent in the patients who exhibited the poorest level of recovery (Turton *et al.*, 1996). When considered together, these observations suggest that the cortical activation observed in the contralesional M1 (i.e. ipsilateral to the limb) is reflective of a suppression of transcallosal inhibition (Liepert *et al.*, 2000; Feydy *et al.*, 2002; Shimizu *et al.*, 2002).

In summary, the data above suggest that functional recovery is substantially better when occurring within the boundaries of the original (non-lesioned) network. The best outcome is found when plastic neural reorganizations take place within the regions adjacent to the infarct zone. A poor

Downloaded from http://brain.oxfordjournals.org/ by guest on December 28, 2015

level recovery is generally observed when neural reorganizations involve the intact hemisphere.

LGG data

Pre-operative reorganizations

Numerous pre-operative neurofunctional imaging studies have shown that tumour invasions trigger major neural reorganizations. These reorganizations explain why most LGG patients appear either normal or only slightly impaired under standard neurological assessments (Duffau and Capelle, 2001*a*; Duffau *et al.*, 2003*b*; Duffau, 2005) (Fig. 8). Unsurprisingly, the nature of the reorganizations induced by slow-growing lesions has been shown to differ from patient to patient (Carpentier *et al.*, 2001). However, beyond individual variations four main plastic patterns have been reported.

First, the infiltrative character of LGG makes it possible for the function to persist within the tumour. Recently, magneto-encephalography studies have suggested that this intra-tumoural activity was present in up to 36% of the patients (Ganslandt *et al.*, 1997, 2004; Schiffbauer *et al.*, 2001, 2002; Daumas-Duport *et al.*, 2005). Similar results have been obtained in fMRI studies. For instance, Krainik *et al.* (2003) demonstrated that BOLD activation of the SMA did occur despite infiltration by an LGG. These authors reported that surgical resection of this region induced, for 50% of the patients, a 'SMA syndrome', in agreement with the idea that the fMRI activation really reflected a functional persistence within the glioma for these patients.

Second, eloquent areas can be redistributed immediately around the tumour. For instance, pre-operative neuroimaging techniques have revealed, for LGG located within the central region, that the hand representation was displaced and enlarged around the tumoural tissue (Yousry *et al.*, 1995). Anatomic deformations associated with the presence of the tumour were not able to account for these changes, suggesting that a true functional re-mapping had taken place (Atlas *et al.*, 1996; Mueller *et al.*, 1996; Righini *et al.*, 1996). Similar observations were described in the language domain. Non-aphasic patients harbouring a glioma within Broca's area were reported to exhibit speech-related activations in the left inferior frontal cortex adjacent to the tumour (Meyer *et al.*, 2003*a*).

Third, a distributed network of areas can be recruited within the lesioned hemisphere. For instance, in patients harbouring intracerebral gliomas within the motor system, activations of 'secondary motor areas' have often been reported during simple tasks such as finger tapping or grip force modulation. These activations commonly concern the SMA, the premotor cortex and the superior parietal lobe (Seitz *et al.*, 1995; Atlas *et al.*, 1996; Wunderlich *et al.*, 1998; Krings *et al.*, 2002; Meyer *et al.*, 2003*b*). A similar type of 'remote plasticity' was observed in patients harbouring intracerebral gliomas within the language system. In this case, speech-related activations were observed (i) in the left superior temporal gyrus following tumoural invasions of Broca's area (Heiss *et al.*, 2003; Meyer *et al.*, 2003*a*); (ii) in Broca's area following tumoural invasions of the left temporo-parietal region (Meyer *et al.*, 2003*a*). Interestingly, some patients with slowly evolving gliomas affecting language functions were also reported to recruit 'non typical' language areas in the left frontolateral regions, including Brodmann areas (BA) 46 and 47, and the SMA (Thiel *et al.*, 1998, 2001; Meyer *et al.*, 2003*a*). A recruitment of remote areas not typically involved in language functions was also observed following lesions of the left insula (a structure known to contribute to the planning of speech; Ackermann and Riecker, 2004). In this case, compensatory activations were reported, not only in Broca's area and the left superior temporal gyrus, but also in the left putamen (Duffau *et al.*, 2001*c*).

Finally, a network of areas can be recruited in the contralateral hemisphere. For instance, for LGG located within the rolandic region, several studies have reported activations within the contralesional primary motor cortex (Yoshiura *et al.*, 1997; Caramia *et al.*, 1998; Fandino *et al.*, 1999; Roux *et al.*, 2000; Baciu *et al.*, 2003), the contralesional premotor area (Fandino *et al.*, 1999) and the contralesional SMA (Krainik *et al.*, 2004). For language function, translocations of Broca's area to the right hemisphere were observed following the development of a LGG within the left inferior frontal cortex (Holodny *et al.*, 2002). Likewise, translocations of Wernicke's area to the contralesional hemisphere were reported in the context of left temporo-parietal tumours (Petrovitch *et al.*, 2004). However, the significance of these translocations is often questioned. A frequent criticism suggests, in particular, that the recruitment of the intact contralesional homologous reflects a decrease of transcallosal inhibition (Netz *et al.*, 1995; Heiss *et al.*, 2003; *see above*) or a compromised BOLD signal at the vicinity of the tumoural tissue (Ulmer *et al.*, 2003, 2004). A recent study seems to convincingly rebut these concerns by showing that TMS induces speech disruption when applied over the contralesional activation sites (Thiel *et al.*, 2005). Of course, the different plastic patterns reported above rarely occur in isolation. Generally, recovery takes the form of a mix between different types of compensatory recruitments. For instance, recent studies have reported a combination of peri-tumoural and contra-hemispheric activations in patients harbouring intracerebral gliomas within the sensori-motor (Fandino *et al.*, 1999) and language systems (Thiel *et al.*, 1998; Heiss *et al.*, 2003; Meyer *et al.*, 2003*a*). In the largest study to date, PET was used to study the plasticity of the language network in 61 patients harbouring gliomas in the left hemisphere (Thiel *et al.*, 2001). A combination of inter- and intra-hemispheric compensations was observed in >60% of these patients. Interestingly, while some patients exhibited pure intra-hemispheric compensations, no example of unmixed contralesional recruitment was provided. This suggests that the four different patterns of compensation described above are organized in a hierarchical manner.

Downloaded from http://brain.oxfordjournals.org/ by guest on December 28, 2015

According to this view, intrinsic reorganizations occurring within the injured and perilesional structures are the first factor of compensation (Thiel *et al.*, 2001; Heiss *et al.*, 2003). Remote recruitments in the ipsi- and contralesional hemispheres occur only at a second level, when local reorganizations become insufficient. In agreement with this model, it has been reported that activations in the contratumoural hemisphere were associated with a less complete recovery (Heiss *et al.*, 2003 for a discussion).

In summary, the data above suggest that different plastic processes compensate for LGG invasions. These processes seem to follow a hierarchical model similar to the one previously discussed in the context of acute strokes: local compensations take place before the occurrence of remote recruitments. Beyond this analogy, however, LGG recovery presents two major specificities. First, compensations can involve areas that are not part of the typical functional network (*e.g.* BA 46, BA 47, for speech; Thiel *et al.*, 2001). Second, remote compensations in the intact or lesioned hemisphere are not a marker of poor recovery. Concerning this latter point, one may argue that LGG resections would be impossible if this was not the case. Indeed, if efficient plastic compensations were only possible within and around the glioma, it would be impossible to resect the tumoural tissue without generating major functional deficits. With respect to this point, it may be noticed that neurosurgeons usually tend to remove a small layer of sound tissue around the tumour to increase the likelihood of obtaining a complete resection and decrease the probability of tumoural recurrence (Duffau *et al.*, 2005; Duffau, 2005).

Intra-operative reorganizations

LGG resection is bounded by two constraints: (i) removing as much as possible of the invaded tissue; (ii) minimizing functional sequelae. Unfortunately, this equation cannot be solved pre-operatively only, using imaging techniques. Indeed, the fMRI BOLD signal seems compromised at the vicinity of LGG (Holodny *et al.*, 1999, 2000; Roux *et al.*, 2003; Fujiwara *et al.*, 2004), which may both prevent reliable identification of significant responses in the peri-lesional region (Schreiber *et al.*, 2000; Murata, 2004; Aubert *et al.*, 2002) and lead to the observation of a false functional response in the intact hemisphere (Ulmer *et al.*, 2003, 2004). In addition, with imaging techniques it is not always possible to distinguish between essential (non-removable) and compensable (removable) structures (Price *et al.*, 1999; Duffau, 2005). These problems explain why the use of intra-operative DES is widely advocated during surgical resections (Berger and Rostomily, 1997; Keles and Berger, 2004*a*; Keles *et al.*, 2004*b*; Duffau, 2005). DES generates transient disturbances when applied on a neural epicentre essential for the function (Ojemann *et al.*, 1989). These disturbances allow to map functional systems in the motor (by inducing involuntary movements), somatosensory (by eliciting dysaesthesia) and cognitive domains (by inhibiting the function). In this latter case, functions such as language (spontaneous speech, object naming, comprehension, etc), calculation, memory, reading or writing can be investigated. Of course, most of these investigations require the surgery to be performed under local anaesthesia in an awake patient. Under this framework, the rule is quite simple: any reproducible functional disturbance induced by DES provokes the interruption of the resection (Duffau, 2005). From a theoretical point of view, the major difference between DES and the pre-operative approaches (evoked potentials, electrocortical recordings, imaging) lies in the fact that DES is a technique, not of neural recording, but of 'active' functional perturbation. This technique achieves a transient virtual lesion, thus allowing to isolate, at each stage of the resection, the structures that are essential for the function (Duffau, 2004). DES has been shown to propagate only along the stimulated white matter pathways (Matsumoto *et al.*, 2004; Thiebaut de Schotten *et al.*, 2005) and to induce a marginal amount of cortical spreading (Haglund *et al.*, 1993).

During the last decade, DES performed just before and during the resection has confirmed the possible persistence of functional responses within LGG (Ojemann *et al.*, 1996; Skirboll *et al.*, 1996; Danks *et al.*, 2000). For instance, when the somatosensory motor cortex is stimulated with DES, paraesthesias and facial movements can still be observed, despite tumoural invasions (Duffau *et al.*, 2003*b*). Likewise, speech disorders can be evident when DES is applied over the invaded surface of the left insular cortex (Duffau *et al.*, 2000*a*) or the left paralimbic cortex (Duffau *et al.*, 2006). Similar results were reported for invasions involving the subcortical white matter pathways (Skirboll *et al.*, 1996; Duffau *et al.*, 2003*a*). In fact, the most direct evidence of functional response within the tumoural tissue comes from the observation that the surgical resections driven by DES remain sub-optimal in >50% of the cases (Mandonnet *et al.*, 2006*b*). This result can be explained by the fact that LGG are not bulky but infiltrative lesions, which tend to travel along the white matter tracts (Mandonnet *et al.*, 2006*a*).

In most patients, DES reveals the existence of a redistribution of the eloquent areas in the regions just adjacent to the lesion (Duffau *et al.*, 2003*b*). This was shown, in particular, in patients harbouring 'silent' tumours within language structures. In these patients, peri-tumoural DES is generally able to induce language disturbances that are not present pre-operatively. For instance, a local reshaping of the language network is often observed following a tumoural invasion of Broca's area. In this case, functional compensations recruit adjacent regions including the left ventral premotor cortex, the middle frontal gyrus (BA 46) and the pars orbitaris of the inferior frontal gyrus (BA 47) (Duffau, 2003; Duffau *et al.*, 2003*b*).

Because brain exposure is performed around the invaded area, DES is generally not relevant for investigating distant compensations. However, a small set of data seems to

Downloaded from http://brain.oxfordjournals.org/ by guest on December 28, 2015

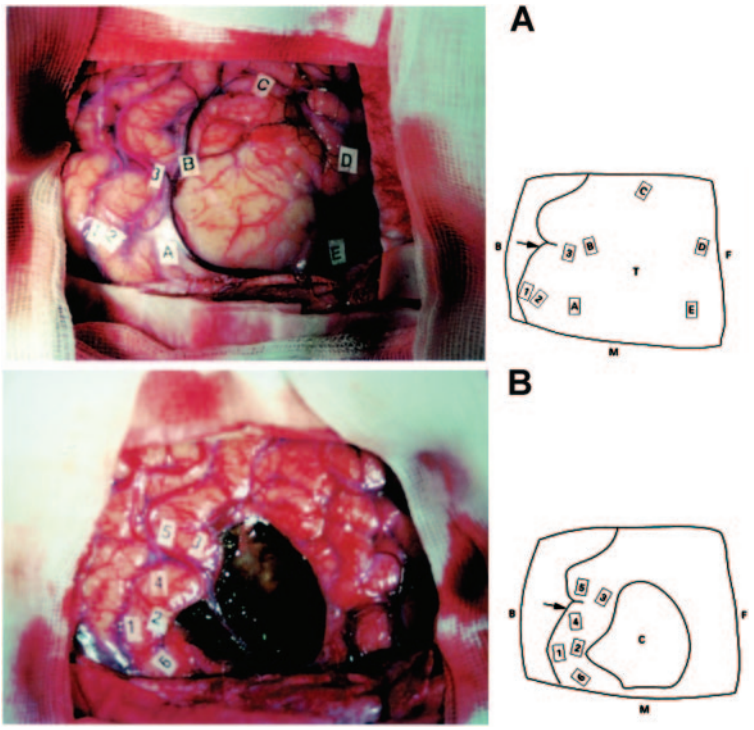

Fig. 10 (**A**) Intra-operative pre-resection view photograph (top) and schematic drawing (right) showing three functional sites in M1 inducing contralateral motor responses of respectively the forearm (tag 1), the wrist (tag 2) and the fingers (tag 3). (**B**) Corresponding post-resection photograph and drawing. The three original pre-resection sites still induce motor responses. Three new (previously silent) sites are also present (wrist: tag 4; fingers: tag 5; forearm: tag 6). Tags 1–3 are slightly raised with respect to the pre-resection state due to the anatomical deformation created by the tumour removal. For both panels: B = backward; C = cavity; F = forward; M = midline; T = tumour; arrow = central sulcus. (From Duffau, 2001.)

support the functional validity of remote recruitments for behavioural recovery. For instance, in patients harbouring a silent tumour within the left insula, compensations were found in the damaged hemisphere in Broca's area, the left superior temporal gyrus and the putamen (Duffau *et al.*, 2001*c*). These results support the conclusions of pre- (*see above*) and post- (*see below*) operative imaging studies.

Regarding intra-surgical plasticity, a very puzzling observation concerns the existence of acute functional re-mapping triggered by the resection itself and taking place within 15–60 min of beginning the surgical act. This type of acute reorganization is illustrated in Fig. 10. It has been very well documented in the sensorimotor system (Duffau *et al.*, 2000*b*; Duffau, 2001; Duffau and Capelle, 2001*b*; for a review *see* Duffau and Capelle, 2001*a*). The origin of these changes remains unfortunately unknown. The most likely hypothesis suggests that a local increase of cortical excitability allows to unmask latent intracortical connections (Duffau *et al.*, 2000*b*; Duffau, 2001). In agreement with this idea, animal models have shown that focal brain damages induce large zones of enhanced cortical excitability in both the lesioned and the intact hemisphere (Buchkremer-Ratzmann *et al.*, 1996). Likewise, human studies have provided evidence that the level of intracortical inhibition is reduced in the damaged hemisphere in stroke patients (Cicinelli *et al.*, 2003). Whether or not this hypothesis of increased excitability is true, it is tempting to speculate that the latent redundant networks revealed by the resection process participate in functional recovery (Nii *et al.*, 1996). This idea fits well with the importance of adjacent reorganizations for behavioural recuperation.

Post-operative reorganizations

While mechanisms of post-stroke recuperation have been thoroughly investigated during the last 50 years, the processes of post-resection recovery in slow-growing lesions have emerged only recently as a major subject of research. This explains why data associated with this topic remain scarce. However, this scarcity is counterbalanced by the existence of a relative consensus among studies. Schematically, the post-operative literature reinforces the pre-surgical observations by suggesting that functional recovery involves a large array of complementary mechanisms. For instance, using magneto-encephalography, it has been reported that resections of the somatosensory cortex (S1) caused peri-lesional sites to be recruited around the cavity, within the postcentral gyrus (Meunier *et al.*, 2000). In addition to this local re-mapping, contributions of S2, the posterior parietal cortex and the primary motor cortex were also reported

Downloaded from http://brain.oxfordjournals.org/ by guest on December 28, 2015

using post-operative DES (Duffau and Capelle 2001*b*). Similar combinations of local and remote reorganizations were found in the language domain, after resections of Broca's area. In this case, DES performed right at the end of the resection showed that plasticity involved a reorganization of the neural networks within the premotor cortex, the pars orbitaris of the inferior frontal gyrus and the insula (Duffau *et al.*, 2003*b*). These data are compatible with other results showing that the language networks evolve from surgery to surgery when successive operations have to be performed (Duffau *et al.*, 2002*b*). They also agree with the rapid regression of the functional deficits observed when the SMA proper is removed (Krainik *et al.*, 2003). Post-operative fMRI images taken after the regression of these deficits suggest that plastic functional compensations involve the contralesional SMA, the contralesional premotor cortex (Krainik *et al.*, 2004) and, potentially, the ipsilesional primary motor cortex (Duffau *et al.*, 2003*b*). Unfortunately, to date, no study has tried to directly investigate the actual functional role of these regions using, for instance, TMS.

Implications

At a therapeutic level, the most obvious message of the present review is clearly that LGG can be treated surgically without generating detectable functional deficits, even when the tumour is located in the so-called 'eloquent areas'. Another promising implication points to the possible development of iterative surgeries for LGG patients. Because these clinical issues have been discussed elsewhere they will not be examined here any further (Duffau, 2005).

At a fundamental level, the present review questions the growing localizationist trend of our modern neurophysiology. The anatomo-functional model has become so powerful that the issue of 'functional localization' has penetrated even our most complex human faculties. For instance, recent reports have claimed that visuomotor adaptation is mediated by the parietal area PEG (Clower *et al.*, 1996), that saccadic adaptation relies on the medio-posterior cerebellar cortex (Desmurget *et al.*, 1999, 2000), that imitation (Iacoboni *et al.*, 1999) and understanding (Gallese and Goldman, 1998) of actions depends on Broca's area, that our moral sense originates in the prefrontal cortex (Anderson *et al.*, 1999), that religious experience is built into our nervous system within a restricted frontal-parietal network (Azari *et al.*, 2001) and that romantic and maternal love engages the medial insula and the anterior cingulate cortex (Bartels and Zeki, 2000, 2004). During the last decade, a handful of authors have questioned the theoretical and methodological significance of these results (for a review *see* Farah, 1994; Uttal, 2001). The present review supports their effort. Indeed, both clinical data in LGG patients and experimental observations in brain lesioned animals demonstrate that the brain is not a rigid mosaic of independently encapsulated modules. Massive brain lesions within almost any area of the brain, including the supposedly untouchable eloquent areas, can often be effectively counterbalanced by adjacent and remote changes in neural organizations. Of course, this astonishing plasticity does not mean that the brain is equipotent and that it can compensate for any type of lesion, as was once suggested by Lashley (1950). Rather, it indicates that functional specializations are not the inevitable byproduct of local architectonic differences. The ability of 'non-canonical' speech areas (BA 46 and 47) to compensate for LGG invasion located in Broca's area provides an especially convincing support for this idea.

Beyond the remarks above, one major issue remains to be addressed: why is functional plasticity so limited following acute infarcts and so remarkable following slow tumoural invasions? Although this question cannot be answered irrefutably at this point, it is tempting to speculate that a gradual learning process mediates brain plasticity. According to this idea, plastic adaptations take place through supervised learning. Eloquent areas would then play the role of a 'distant teacher' (Jordan and Rumelhart, 1992). This teacher would instruct intact regions through direct or indirect pathways, providing these regions with new functional competences. Acute destruction would prevent this gradual learning process from taking place, thus leading to a poor recovery. Of course, further investigations are required to test this appealing, but still conjectural hypothesis.

Conclusions and perspectives

The take-home message of the present review might be summarized as follows. While major irrevocable functional impairments are generally reported following acute injuries, a complete or nearly complete recovery is commonly observed in the context of slow-growing lesions. Here, we have shown this latter conclusion to be true for slow tumoural invasions in humans and multiple surgical resections in animals. Although this is beyond the scope of the present paper, it may be worth mentioning that data associated with slow degenerative disease are also compatible with the idea that our brain possesses a very high potential for plasticity. For instance, in patients with Parkinson's disease, no behavioural symptom is observed until the neural destruction reaches 80% among the dopaminergic cells of the substantia niagra pars compacta (Bernheimer *et al.*, 1973). This 'preclinical period' has been estimated to last between 3 and 7 years (Morrish *et al.*, 1996, 1998), even if some older reports have suggested that the presymptomatic state could, infact, unfold over several decades (Vingerhoets *et al.*, 1994). It is now widely admitted that powerful adaptive mechanisms are responsible for the existence of this prolonged preclinical period (for a review *see* Bezard *et al.*, 2003). In agreement with this idea, it has been shown, in monkeys, that acute and chronic lesions of the niagral dopaminergic system were associated with very different patterns of behavioural deficits (Hantraye *et al.*, 1993; Bezard *et al.*, 1997).

Downloaded from http://brain.oxfordjournals.org/ by guest on December 28, 2015

With respect to the present review, the relevant (and probably trivial) message carried by the degenerative disease literature is that never-ending slow-growing lesions exhaust progressively the plastic potential of the brain. When a certain threshold is reached, the system can no longer cope with the neural destruction and behavioural deficits start to appear. It is very plausible that the same sort of mechanism is at work in ageing. In agreement with this idea, it has been shown that cognitive performance is maintained in older adults through the recruitment of neural networks that are more distributed and more bilateral than the networks recruited by younger subjects (Cabeza *et al.*, 2001, 2004). As the years pass by, however, the effects of small acute injuries and normal neural death add up making plastic compensations more and more uncertain. If one admits this premise as plausible, two important inferences follow. First, tumoural resections tax the plastic potential of the brain, leaving open the possibility that ageing will have a dramatic effect on the health of the patients. Because the systematic resection of LGG is a recent practice, it will unfortunately not be possible to investigate the validity of this concern for at least a decade. Second, the massive plastic potential revealed by slow-growing tumoural models might be critical, not only in pathological situations, but also in the context of 'normal' ageing. According to this view, plastic mechanisms would act, throughout our lives, to counterbalance the deleterious effects of time. This idea is compatible with the observation that slow-growing lesions, that mimic the effect of ageing, are compensated for much more efficiently than acute lesions. Of course, further investigations remain necessary to investigate the validity of these ideas.

Acknowledgements

The authors wish to thank Caroline Tricot for editing this manuscript. This work was supported by a post-doctoral fellowship to F.B. for the years 2005–2007 from the 'Association pour la Recherche sur le Cancer' (ARC-France).

References

Ackermann H, Riecker A. The contribution of the insula to motor aspects of speech production: a review and a hypothesis. Brain Lang 2004; 89: 320–8.

Adametz J. Rate of recovery of functioning in cats with rostral reticular lesions; an experimental study. J Neurosurg 1959; 16: 85–97.

Anderson SW, Bechara A, Damasio H, Tranel D, Damasio AR. Impairment of social and moral behavior related to early damage in human prefrontal cortex. Nat Neurosci 1999; 2: 1032–7.

Atlas SW, Howard RS II, Maldjian J, Alsop D, Detre JA, Listerud J, et al. Functional magnetic resonance imaging of regional brain activity in patients with intracerebral gliomas: findings and implications for clinical management. Neurosurgery 1996; 38: 329–38.

Aubert A, Costalat R, Duffau H, Benali H. Modeling of pathophysiological coupling between brain electrical activation, energy metabolism and hemodynamics: insights for the interpretation of intracerebral tumor imaging. Acta Biotheor 2002; 50: 281–95.

Azari NP, Nickel J, Wunderlich G, Niedeggen M, Hefter H, Tellmann L, et al. Neural correlates of religious experience. Eur J Neurosci 2001; 13: 1649–52.

Baciu M, Le Bas JF, Segebarth C, Benabid AL. Presurgical fMRI evaluation of cerebral reorganization and motor deficit in patients with tumors and vascular malformations. Eur J Radiol 2003; 46: 139–46.

Bartels A, Zeki S. The neural basis of romantic love. Neuroreport 2000; 11: 3829–34.

Bartels A, Zeki S. The neural correlates of maternal and romantic love. Neuroimage 2004; 21: 1155–66.

Bastings EP, Greenberg JP, Good DC. Hand motor recovery after stroke: a transcranial magnetic stimulation mapping study of motor output areas and their relation to functional status. Neurorehabil Neural Repair 2002; 16: 275–82.

Berger MS, Rostomily RC. Low grade gliomas: functional mapping resection strategies, extent of resection, and outcome. J Neurooncol 1997; 34: 85–101.

Bernheimer H, Birkmayer W, Hornykiewicz O, Jellinger K, Seitelberger F. Brain dopamine and the syndromes of Parkinson and Huntington. Clinical, morphological and neurochemical correlations. J Neurol Sci 1973; 20: 415–55.

Bezard E, Imbert C, Deloire X, Bioulac B, Gross CE. A chronic MPTP model reproducing the slow evolution of Parkinson's disease: evolution of motor symptoms in the monkey. Brain Res 1997; 766: 107–12.

Bezard E, Gross CE, Brotchie JM. Presymptomatic compensation in Parkinson's disease is not dopamine-mediated. Trends Neurosci 2003; 26: 215–21.

Binkofski F, Seitz RJ, Arnold S, Classen J, Benecke R, Freund HJ. Thalamic metbolism and corticospinal tract integrity determine motor recovery in stroke. Ann Neurol 1996; 39: 460–70.

Buchkremer-Ratzmann I, August M, Hagemann G, Witte OW. Electrophysiological transcortical diaschisis after cortical photothrombosis in rat brain. Stroke 1996; 27: 1105–9.

Cabeza R. Functional neuroimaging of cognitive aging. In: Cabeza R, Kingstone A, editors. Handbook of functional neuroimaging of cognition. Cambridge: MIT Press; 2001. p. 331–77.

Cabeza R, Daselaar SM, Dolcos F, Prince SE, Budde M, Nyberg L. Task-independent and task-specific age effects on brain activity during working memory, visual attention and episodic retrieval. Cereb Cortex 2004; 14: 364–75.

Calautti C, Leroy F, Guincestre JY, Baron JC. Dynamics of motor network overactivation after striatocapsular stroke: a longitudinal PET study using a fixed-performance paradigm. Stroke 2001; 32: 2534–42.

Calvert GA, Brammer MJ, Morris RG, Williams SC, King N, Matthews PM. Using fMRI to study recovery from acquired dysphasia. Brain Lang 2000; 71: 391–9.

Cao Y, D'Olhaberriague L, Vikingstad EM, Levine SR, Welch KM. Pilot study of functional MRI to assess cerebral activation of motor function after poststroke hemiparesis. Stroke 1998; 29: 112–22.

Cao Y, Vikingstad EM, George KP, Johnson AF, Welch KM. Cortical language activation in stroke patients recovering from aphasia with functional MRI. Stroke 1999; 30: 2331–40.

Cappa SF, Perani D, Grassi F, Bressi S, Alberoni M, Franceschi M, et al. A PET follow-up study of recovery after stroke in acute aphasics. Brain Lang 1997; 56: 55–67.

Caramia MD, Telera S, Palmieri MG, Wilson-Jones M, Scalise A, Iani C, et al. Ipsilateral motor activation in patients with cerebral gliomas. Neurology 1998; 51: 196–202.

Carpentier AC, Constable RT, Schlosser MJ, de Lotbiniere A, Piepmeier JM, Spencer DD, et al. Patterns of functional magnetic resonance imaging activation in association with structural lesions in the rolandic region: a classification system. J Neurosurg 2001; 94: 946–54.

Catano A, Houa M, Caroyer JM, Ducarne H, Noel P. Magnetic transcranial stimulation in non-haemorrhagic sylvian strokes: interest of facilitation for early functional prognosis. Electroencephalogr Clin Neurophysiol 1995; 97: 349–54.

Catano A, Houa M, Caroyer JM, Ducarne H, Noel P. Magnetic transcranial stimulation in acute stroke: early excitation threshold and functional prognosis. Electroencephalogr Clin Neurophysiol 1996; 101: 233–9.

Downloaded from http://brain.oxfordjournals.org/ by guest on December 28, 2015

Chassoux F, Devaux B, Landre E, Chodkiewicz JP, Talairach J, Chauvel P. Postoperative motor deficits and recovery after cortical resections. Adv Neurol 1999; 81: 189–99.

Chollet F, DiPiero V, Wise RJ, Brooks DJ, Dolan RJ, Frackowiak RS. The functional anatomy of motor recovery after stroke in humans: a study with positron emission tomography. Ann Neurol 1991; 29: 63–71.

Cicinelli P, Traversa R, Rossini PM. Post-stroke reorganization of brain motor output to the hand: a 2–4 month follow-up with focal magnetic transcranial stimulation. Electroencephalogr Clin Neurophysiol 1997; 105: 438–50.

Cicinelli P, Pasqualetti P, Zaccagnini M, Traversa R, Oliveri M, Rossini PM. Interhemispheric asymmetries of motor cortex excitability in the postacute stroke stage: a paired-pulse transcranial magnetic stimulation study. Stroke 2003; 34: 2653–8.

Clower DM, Hoffman JM, Votaw JR, Faber TL, Woods RP, Alexander GE. Role of posterior parietal cortex in the recalibration of visually guided reaching. Nature 1996; 383: 618–21.

Cramer SC. Stroke recovery. Lessons from functional MR imaging and other methods of human brain mapping. Phys Med Rehabil Clin N Am 1999; 10: 875–86, ix.

Cramer SC. Functional magnetic resonance imaging in stroke recovery. Phys Med Rehabil Clin N Am 2003; 14: S47–55.

Cramer SC, Nelles G, Benson RR, Kaplan JD, Parker RA, Kwong KK, et al. A functional MRI study of subjects recovered from hemiparetic stroke. Stroke 1997; 28: 2518–27.

Cramer SC, Moore CI, Finklestein SP, Rosen BR. A pilot study of somatotopic mapping after cortical infarct. Stroke 2000; 31: 668–671.

Cramer SC, Bastings EP. Mapping clinically relevant plasticity after stroke. Neuropharmacology 2000; 39: 842–51.

Croquelois A, Wintermark M, Reichhart M, Meuli R, Bogousslavsky J. Aphasia in hyperacute stroke: language follows brain penumbra dynamics. Ann Neurol 2003; 54: 321–9.

Danks RA, Aglio LS, Gugino LD, Black PM. Craniotomy under local anesthesia and monitored conscious sedation for the resection of tumors involving eloquent cortex. J Neurooncol 2000; 49: 131–9.

Daumas-Duport C, Koziak M, Miquel C, Nataf F, Jouvet A, Varlet P. Reappraisal of the Sainte-Anne hospital classification of oligodendrogliomas in view of retrospective studies. Neurochirurgie 2005; 51: 247–53.

de Boissezon X, Demonet JF, Puel M, Marie N, Raboyeau G, Albucher JF, et al. Subcortical aphasia: a longitudinal PET study. Stroke 2005; 36: 1467–73.

DeAngelis LM. Brain tumors. N Engl J Med 2001; 344: 114–23.

Desmurget M, Epstein CM, Turner RS, Prablanc C, Alexander GE, Grafton ST. Role of the posterior parietal cortex in updating reaching movements to a visual target. Nat Neurosci 1999; 2: 563–7.

Desmurget M, Pelisson D, Grethe JS, Alexander GE, Urquizar C, Prablanc C, et al. Functional adaptation of reactive saccades in humans: a PET study. Exp Brain Res 2000; 132: 243–59.

Duffau H, Capelle L, Sichez J, Faillot T, Abdennour L, Law Koune JD, et al. Intra-operative direct electrical stimulations of the central nervous system: the Salpetriere experience with 60 patients. Acta Neurochir (Wien) 1999; 141: 1157–67.

Duffau H, Capelle L, Lopes M, Faillot T, Sichez JP, Fohanno D. The insular lobe: physiopathological and surgical considerations. Neurosurgery 2000a; 47: 801–10.

Duffau H, Sichez JP, Lehericy S. Intraoperative unmasking of brain redundant motor sites during resection of a precentral angioma: evidence using direct cortical stimulation. Ann Neurol 2000b; 47: 132–5.

Duffau H. Acute functional reorganisation of the human motor cortex during resection of central lesions: a study using intraoperative brain mapping. J Neurol Neurosurg Psychiatry 2001; 70: 506–13.

Duffau H, Capelle L. Functional recuperation following lesions of the primary somatosensory fields. Study of compensatory mechanisms. Neurochirurgie 2001a; 47: 557–63.

Duffau H, Capelle L. Functional recuperation after resection of gliomas infiltrating primary somatosensory fields. Study of perioperative electric stimulation. Neurochirurgie 2001b; 47: 534–41.

Duffau H, Bauchet L, Lehericy S, Capelle L. Functional compensation of the left dominant insula for language. Neuroreport 2001c; 12: 2159–63.

Duffau H, Capelle L, Sichez N, Denvil D, Lopes M, Sichez JP, et al. Intraoperative mapping of the subcortical language pathways using direct stimulations. An anatomo-functional study. Brain 2002a; 125: 199–214.

Duffau H, Denvil D, Capelle L. Long term reshaping of language, sensory, and motor maps after glioma resection: a new parameter to integrate in the surgical strategy. J Neurol Neurosurg Psychiatry 2002b; 72: 511–6.

Duffau H, Denvil D, Capelle L. Absence of movement disorders after surgical resection of glioma invading the right striatum. J Neurosurg 2002c; 97: 363–9.

Duffau H, Denvil D, Lopes M, Gasparini F, Cohen L, Capelle L, et al. Intraoperative mapping of the cortical areas involved in multiplication and subtraction: an electrostimulation study in a patient with a left parietal glioma. J Neurol Neurosurg Psychiatry 2002d; 73: 733–8.

Duffau H. Electrophysiological bases of the language areas. In: Etard O, Tzourio-Mazoyer N, editors. Brain and language. Paris: Hermes Eds; 2003. p. 103–27.

Duffau H, Capelle L, Denvil D, Sichez N, Gatignol P, Taillandier L, et al. Usefulness of intraoperative electrical subcortical mapping during surgery for low-grade gliomas located within eloquent brain regions: functional results in a consecutive series of 103 patients. J Neurosurg 2003a; 98: 764–78.

Duffau H, Capelle L, Denvil D, Sichez N, Gatignol P, Lopes M, et al. Functional recovery after surgical resection of low grade gliomas in eloquent brain: hypothesis of brain compensation. J Neurol Neurosurg Psychiatry 2003b; 74: 901–7.

Duffau H, Karachi C, Gatignol P, Capelle L. Transient Foix-Chavany-Marie syndrome after surgical resection of a right insulo-opercular low-grade glioma: case report. Neurosurgery 2003c; 53: 426–31.

Duffau H. Peroperative functional mapping using direct electrical stimulations. Methodological considerations. Neurochirurgie 2004; 50: 474–83.

Duffau H, Khalil I, Gatignol P, Denvil D, Capelle L. Surgical removal of corpus callosum infiltrated by low-grade glioma: functional outcome and oncological considerations. J Neurosurg 2004; 100: 431–7.

Duffau H. Lessons from brain mapping in surgery for low-grade glioma: insights into associations between tumour and brain plasticity. Lancet Neurol 2005; 4: 476–86.

Duffau H, Lopes M, Arthuis F, Bitar A, Sichez JP, Van Effenterre R, et al. Contribution of intraoperative electrical stimulations in surgery of low grade gliomas: a comparative study between two series without (1985–96) and with (1996–2003) functional mapping in the same institution. J Neurol Neurosurg Psychiatry 2005; 76: 845–51.

Duffau H. New concepts in surgery of WHO grade II gliomas: functional brain mapping, connectionism and plasticity—a review. J Neurooncol 2006; 79: 77–115.

Duffau H, Taillandier L, Gatignol P, Capelle L. The insular lobe and brain plasticity: lessons from tumor surgery. Clin Neurol Neurosurg 2006; 108: 543–48.

Escudero JV, Sancho J, Bautista D, Escudero M, Lopez-Trigo J. Prognostic value of motor evoked potential obtained by transcranial magnetic brain stimulation in motor function recovery in patients with acute ischemic stroke. Stroke 1998; 29: 1854–9.

Fandino J, Kollias SS, Wieser HG, Valavanis A, Yonekawa Y. Intraoperative validation of functional magnetic resonance imaging and cortical reorganization patterns in patients with brain tumors involving the primary motor cortex. J Neurosurg 1999; 91: 238–50.

Farah M. Neuropsychological inference with an interactive brain: a critique of the locality assumption. Behav Brain Sci 1994; 17: 43–104.

Feydy A, Carlier R, Roby-Brami A, Bussel B, Cazalis F, Pierot L, et al. Longitudinal study of motor recovery after stroke: recruitment and focusing of brain activation. Stroke 2002; 33: 1610–7.

Finger S. Lesion momentum and behavior. Recovery from brain damage: research and theory. In: Finger S, editor. New-York: Plenum Press; 1978. p. 135–64.

Downloaded from http://brain.oxfordjournals.org/ by guest on December 28, 2015

Finger S, Stein D. Brain damage and recovery: research and clinical perspectives. Orlando, FL: Academic Press; 1982.

Finger S, Marshak RA, Cohen M, Scheff S, Trace R, Niemand D. Effects of successive and simultaneous lesions of somatosensory cortex on tactile discrimination in the rat. J Comp Physiol Psychol 1971; 77: 221–7.

Foltys H, Krings T, Meister IG, Sparing R, Boroojerdi B, Thron A, et al. Motor representation in patients rapidly recovering after stroke: a functional magnetic resonance imaging and transcranial magnetic stimulation study. Clin Neurophysiol 2003; 114: 2404–15.

Fridman EA, Hanakawa T, Chung M, Hummel F, Leiguarda RC, Cohen LG. Reorganization of the human ipsilesional premotor cortex after stroke. Brain 2004; 127: 747–58.

Frost SB, Barbay S, Friel KM, Plautz EJ, Nudo RJ. Reorganization of remote cortical regions after ischemic brain injury: a potential substrate for stroke recovery. J Neurophysiol 2003; 89: 3205–14.

Fujiwara N, Sakatani K, Katayama Y, Murata Y, Hoshino T, Fukaya C, et al. Evoked-cerebral blood oxygenation changes in false-negative activations in BOLD contrast functional MRI of patients with brain tumors. Neuroimage 2004; 21: 1464–71.

Furlan M, Marchal G, Viader F, Derlon JM, Baron JC. Spontaneous neurological recovery after stroke and the fate of the ischemic penumbra. Ann Neurol 1996; 40: 216–26.

Gainotti G. The riddle of the right hemisphere's contribution to the recovery of language. Eur J Disord Commun 1993; 28: 227–46.

Gallese V, Goldman A. Mirror neurons and the simulation theory of mind reading. Trends Cogn Sci 1998; 2: 493–501.

Ganslandt O, Steinmeier R, Kober H, Vieth J, Kassubek J, Romstöck J, et al. Magnetic source imaging combined with image-guided frameless stereotaxy: a new method in surgery around the motor strip. Neurosurgery 1997; 41: 621–8.

Ganslandt O, Buchfelder M, Hastreiter P, Grummich P, Fahlbusch R, Nimsky C. Magnetic source imaging supports clinical decision making in glioma patients. Clin Neurol Neurosurg 2004; 107: 20–6.

Gatignol P, Capelle L, Le Bihan R, Duffau H. Double dissociation between picture naming and comprehension: an electrostimulation study. Neuroreport 2004; 15: 191–5.

Giese A, Bjerkvig R, Berens ME, Westphal M. Cost of migration: invasion of malignant gliomas and implications for treatment. J Clin Oncol 2003; 21: 1624–36.

Glick SD, Zimmerberg B. Comparative recovery following simultaneous- and successive-stage frontal brain damage in mice. J Comp Physiol Psychol 1972; 79: 481–7.

Haglund MM, Ojemann GA, Blasdel GG. Optical imaging of bipolar cortical stimulation. J Neurosurg 1993; 78: 785–93.

Hakim AM, Pokrupa RP, Villanueva J, Diksic M, Evans AC, Thompson CJ, et al. The effect of spontaneous reperfusion on metabolic function in early human cerebral infarcts. Ann Neurol 1987; 21: 279–89.

Hallett M. Plasticity of the human motor cortex and recovery from stroke. Brain Res Brain Res Rev 2001; 36: 169–74.

Hankey GJ, Warlow CP. Treatment and secondary prevention of stroke: evidence, costs, and effects on individuals and populations. Lancet 1999; 354: 1457–63.

Hantraye P, Varastet M, Peschanski M, Riche D, Cesaro P, Willer JC, et al. Stable parkinsonian syndrome and uneven loss of striatal dopamine fibres following chronic MPTP administration in baboons. Neuroscience 1993; 53: 169–78.

Heald A, Bates D, Cartlidge NE, French JM, Miller S. Longitudinal study of central motor conduction time following stroke. 2. Central motor conduction measured within 72 h after stroke as a predictor of functional outcome at 12 months. Brain 1993; 116: 1371–85.

Heiss WD, Kessler J, Karbe H, Fink GR, Pawlik G. Cerebral glucose metabolism as a predictor of recovery from aphasia in ischemic stroke. Arch Neurol 1993; 50: 958–64.

Heiss WD, Kessler J, Thiel A, Ghaemi M, Karbe H. Differential capacity of left and right hemispheric areas for compensation of poststroke aphasia. Ann Neurol 1999; 45: 430–8.

Heiss WD, Thiel A, Kessler J, Herholz K. Disturbance and recovery of language function: correlates in PET activation studies. Neuroimage 2003; 20 (Suppl 1): S42–9.

Herholz K, Heiss WD. Functional imaging correlates of recovery after stroke in humans. J Cereb Blood Flow Metab 2000; 20: 1619–31.

Holodny AI, Schulder M, Liu WC, Maldjian JA, Kalnin AJ. Decreased BOLD functional MR activation of the motor and sensory cortices adjacent to a glioblastoma multiforme: implications for image-guided neurosurgery. AJNR Am J Neuroradiol 1999; 20: 609–12.

Holodny AI, Schulder M, Liu WC, Wolko J, Maldjian JA, Kalnin AJ. The effect of brain tumors on BOLD functional MR imaging activation in the adjacent motor cortex: implications for image-guided neurosurgery. AJNR Am J Neuroradiol 2000; 21: 1415–22.

Holodny AI, Schulder M, Ybasco A, Liu WC. Translocation of Broca's area to the contralateral hemisphere as the result of the growth of a left inferior frontal glioma. J Comput Assist Tomogr 2002; 26: 941–3.

Iacoboni M, Woods RP, Brass M, Bekkering H, Mazziotta JC, Rizzolatti G. Cortical mechanisms of human imitation. Science 1999; 286: 2526–8.

Inoue Y, Takemoto K, Miyamoto T, Yoshikawa N, Taniguchi S, Saiwai S, et al. Sequential computed tomography scans in acute cerebral infarction. Radiology 1980; 135: 655–62.

Jackson JH. On affections of speech from disease of the brain. Brain 1879: 323–56.

Johansen-Berg H, Dawes H, Guy C, Smith SM, Wade DT, Matthews PM. Correlation between motor improvements and altered fMRI activity after rehabilitative therapy. Brain 2002a; 125: 2731–42.

Johansen-Berg H, Rushworth MF, Bogdanovic MD, Kischka U, Wimalaratna S, Matthews PM. The role of ipsilateral premotor cortex in hand movement after stroke. Proc Natl Acad Sci USA 2002b; 99: 14518–23.

Jordan MI, Rumelhart DE. Forward models: Supervised learning with a distal teacher. Cogn Sci Multidiscipl J 1992; 16: 307–54.

Karbe H, Thiel A, Weber-Luxenburger G, Herholz K, Kessler J, Heiss WD. Brain plasticity in poststroke aphasia: what is the contribution of the right hemisphere? Brain Lang 1998; 64: 215–30.

Keles GE, Berger MS. Advances in neurosurgical technique in the current management of brain tumors. Semin Oncol 2004a; 31: 659–65.

Keles GE, Lundin DA, Lamborn KR, Chang EF, Ojemann G, Berger MS. Intraoperative subcortical stimulation mapping for hemispherical perirolandic gliomas located within or adjacent to the descending motor pathways: evaluation of morbidity and assessment of functional outcome in 294 patients. J Neurosurg 2004b; 100: 369–75.

Kolb B. Brain plasticity and behaviour. Mahwah, NJ: Lawrence Erlbaum; 1995.

Kolb B, Gibb R, Gorny G. Cortical plasticity and the development of behavior after early frontal cortical injury. Dev Neuropsychol 2000; 18: 423–44.

Krainik A, Lehericy S, Duffau H, Vlaicu M, Poupon F, Capelle L, et al. Role of the supplementary motor area in motor deficit following medial frontal lobe surgery. Neurology 2001; 57: 871–8.

Krainik A, Lehericy S, Duffau H, Capelle L, Chainay H, Cornu P, et al. Postoperative speech disorder after medial frontal surgery: role of the supplementary motor area. Neurology 2003; 60: 587–94.

Krainik A, Duffau H, Capelle L, Cornu P, Boch AL, Mangin JF, et al. Role of the healthy hemisphere in recovery after resection of the supplementary motor area. Neurology 2004; 62: 1323–32.

Krings T, Topper R, Willmes K, Reinges MH, Gilsbach JM, Thron A. Activation in primary and secondary motor areas in patients with CNS neoplasms and weakness. Neurology 2002; 58: 381–90.

Kuhl DE, Phelps ME, Kowell AP, Metter EJ, Selin C, Winter J. Effects of stroke on local cerebral metabolism and perfusion: mapping by emission computed tomography of 18FDG and 13NH3. Ann Neurol 1980; 8: 47–60.

Lashley K. In search of the engram. Society of Experimental Biology Symposium, no. 4: psychological mechanisms in animal behaviour. Cambridge: Cambridge University Press; 1950. p. 454–80.

Liepert J, Hamzei F, Weiller C. Motor cortex disinhibition of the unaffected hemisphere after acute stroke. Muscle Nerve 2000; 23: 1761–3.

Downloaded from http://brain.oxfordjournals.org/ by guest on December 28, 2015

Liepert J, Bauder H, Wolfgang HR, Miltner WH, Taub E, Weiller C. Treatment-induced cortical reorganization after stroke in humans. Stroke 2000; 31: 1210–6.

Liu Y, Rouiller EM. Mechanisms of recovery of dexterity following unilateral lesion of the sensorimotor cortex in adult monkeys. Exp Brain Res 1999; 128: 149–59.

Longworth CE, Marslen-Wilson WD, Randall B, Tyler LK. Getting to the meaning of the regular past tense: evidence from neuropsychology. J Cogn Neurosci 2005; 17: 1087–97.

Maegaki Y, Yamamoto T, Takeshita K. Plasticity of central motor and sensory pathways in a case of unilateral extensive cortical dysplasia: investigation of magnetic resonance imaging, transcranial magnetic stimulation, and short-latency somatosensory evoked potentials. Neurology 1995; 45: 2255–61.

Mandonnet E, Delattre JY, Tanguy ML, Swanson KR, Carpentier AF, Duffau H, et al. Continuous growth of mean tumor diameter in a subset of grade II gliomas. Ann Neurol 2003; 53: 524–8.

Mandonnet E, Capelle L, Duffau H. Extension of paralimbic low-grade gliomas: toward an anatomical classification based on white matter invasion pattern. J Neurooncol 2006a; 78: 179–85.

Mandonnet E, Jbabdi S, Taillandier L, Galanaud D, Benali H, Capelle L, et al. Preoperative estimation of residual volume for WHO II glioma operated with intraoperative functional mapping. Neurooncology 2006b. In press.

Marshall RS, Perera GM, Lazar RM, Krakauer JW, Constantine RC, DeLaPaz RL. Evolution of cortical activation during recovery from corticospinal tract infarction. Stroke 2000; 31: 656–61.

Matsumoto R, Nair DR, La Presto E, Najm I, Bingaman W, Shibasaki H, Luders HO. Functional connectivity in the human language system: a cortico-cortical evoked potential study. Brain 2004; 127: 2316–30.

Meunier S, Duffau H, Garnero L, Capelle L, Ducorps A. Comparison of the somatosensory cortical mapping of the fingers using a whole head magnetoencephalography (MEG) and direct electrical stimulations during surgery in awake patients. Neuroimage 2000; 15: S868.

Meyer D, Isaac W, Maher B. The role of stimulation in spontaneous reorganization of visual habits. J Comp Physiol Psychol 1958; 51: 546–8.

Meyer PT, Sturz L, Schreckenberger M, Spetzger U, Meyer GF, Setani KS, et al. Preoperative mapping of cortical language areas in adult brain tumour patients using PET and individual non-normalised SPM analyses. Eur J Nucl Med Mol Imaging 2003a; 30: 951–60.

Meyer PT, Sturz L, Sabri O, Schreckenberger M, Spetzger U, Setani KS, et al. Preoperative motor system brain mapping using positron emission tomography and statistical parametric mapping: hints on cortical reorganisation. J Neurol Neurosurg Psychiatry 2003b; 74: 471–8.

Milea D, Lobel E, Lehericy S, Duffau H, Rivaud-Pechoux S, Berthoz A, et al. Intraoperative frontal eye field stimulation elicits ocular deviation and saccade suppression. Neuroreport 2002; 13: 1359–64.

Misra UK, Kalita J. Motor evoked potential changes in ischaemic stroke depend on stroke location. J Neurol Sci 1995; 134: 67–72.

Miura K, Nakamura Y, Miura F, Yamada I, Takahashi M, Yoshikawa A, et al. Functional magnetic resonance imaging to word generation task in a patient with Broca's aphasia. J Neurol 1999; 246: 939–42.

Morrish PK, Sawle GV, Brooks DJ. An [^{18}F]dopa-PET and clinical study of the rate of progression in Parkinson's disease. Brain 1996; 119: 585–91.

Morrish PK, Rakshi JS, Bailey DL, Sawle GV, Brooks DJ. Measuring the rate of progression and estimating the preclinical period of Parkinson's disease with [18F]dopa PET. J Neurol Neurosurg Psychiatry 1998; 64: 314–9.

Mueller WM, Yetkin FZ, Hammeke TA, Morris GL III, Swanson SJ, Reichert K, et al. Functional magnetic resonance imaging mapping of the motor cortex in patients with cerebral tumors. Neurosurgery 1996; 39: 515–20.

Murata Y, Sakatani K, Katayama Y, Fujiwara N, Hoshino T, Fukaya C, et al. Decreases of blood oxygenation level-dependent signal in the activated motor cortex during functional recovery after resection of a glioma. AJNR Am J Neuroradiol 2004; 25: 1242–6.

Netz J, Ziemann U, Homberg V. Hemispheric asymmetry of transcallosal inhibition in man. Exp Brain Res 1995; 104: 527–33.

Netz J, Lammers T, Homberg V. Reorganization of motor output in the non-affected hemisphere after stroke. Brain 1997; 120: 1579–86.

Nii Y, Uematsu S, Lesser RP, Gordon B. Does the central sulcus divide motor and sensory functions? Cortical mapping of human hand areas as revealed by electrical stimulation through subdural grid electrodes. Neurology 1996; 46: 360–7.

Nudo RJ, Wise BM, SiFuentes F, Milliken GW. Neural substrates for the effects of rehabilitative training on motor recovery after ischemic infarct. Science 1996; 272: 1791–4.

Ojemann G, Ojemann J, Lettich E, Berger M. Cortical language localization in left, dominant hemisphere. An electrical stimulation mapping investigation in 117 patients. J Neurosurg 1989; 71: 316–26.

Ojemann JG, Miller JW, Silbergeld DL. Preserved function in brain invaded by tumor. Neurosurgery 1996; 39: 253–8.

Patrissi G, Stein DG. Temporal factors in recovery of function after brain damage. Exp Neurol 1975; 47: 470–80.

Pennisi G, Rapisarda G, Bella R, Calabrese V, Maertens DN, Delwaide PJ. Absence of response to early transcranial magnetic stimulation in ischemic stroke patients: prognostic value for hand motor recovery. Stroke 1999; 30: 2666–70.

Petrovich NM, Holodny AI, Brennan CW, Gutin PH. Isolated translocation of Wernicke's area to the right hemisphere in a 62-year-man with a temporo-parietal glioma. AJNR Am J Neuroradiol 2004; 25: 130–3.

Pineiro R, Pendlebury S, Johansen-Berg H, Matthews PM. Functional MRI detects posterior shifts in primary sensorimotor cortex activation after stroke: evidence of local adaptive reorganization? Stroke 2001; 32: 1134–9.

Price CJ, Mummery CJ, Moore CJ, Frakowiak RS, Friston K. Delineating necessary and sufficient neural systems with functional imaging studies of neuropsychological patients. J Cogn Neurosci 1999; 11: 371–82.

Rapisarda G, Bastings E, de Noordhout AM, Pennisi G, Delwaide PJ. Can motor recovery in stroke patients be predicted by early transcranial magnetic stimulation? Stroke 1996; 27: 2191–6.

Righini A, de Divitiis O, Prinster A, Spagnoli D, Appollonio I, Bello L, et al. Functional MRI: primary motor cortex localization in patients with brain tumors. J Comput Assist Tomogr 1996; 20: 702–8.

Rijntjes M, Weiller C. Recovery of motor and language abilities after stroke: the contribution of functional imaging. Prog Neurobiol 2002; 66: 109–22.

Rosen HJ, Petersen SE, Linenweber MR, Snyder AZ, White DA, Chapman L, et al. Neural correlates of recovery from aphasia after damage to left inferior frontal cortex. Neurology 2000; 55: 1883–94.

Rosen J, Stein D, Butters N. Recovery of function after serial ablation of prefrontal cortex in the rhesus monkey. Science 1971; 173: 353–6.

Rossini PM, Caltagirone C, Castriota-Scanderbeg A, Cicinelli P, Del Gratta C, Demartin M, et al. Hand motor cortical area reorganization in stroke: a study with fMRI, MEG and TCS maps. Neuroreport 1998; 9: 2141–6.

Rouiller EM, Yu XH, Moret V, Tempini A, Wiesendanger M, Liang F. Dexterity in adult monkeys following early lesion of the motor cortical hand area: the role of cortex adjacent to the lesion. Eur J Neurosci 1998; 10: 729–40.

Roux FE, Boulanouar K, Ibarrola D, Tremoulet M, Chollet F, Berry I. Functional MRI and intraoperative brain mapping to evaluate brain plasticity in patients with brain tumours and hemiparesis. J Neurol Neurosurg Psychiatry 2000; 69: 453–63.

Roux FE, Boulanouar K, Lotterie JA, Mejdoubi M, LeSage JP, Berry I. Language functional magnetic resonance imaging in preoperative assessment of language areas: correlation with direct cortical stimulation. Neurosurgery 2003; 52: 1335–45.

Sakashita Y, Matsuda H, Kakuda K, Takamori M. Hypoperfusion and vasoreactivity in the thalamus and cerebellum after stroke. Stroke 1993; 24: 84–7.

Schiffbauer H, Ferrari P, Rowley HA, Berger MS, Roberts TPL. Functional activity within brain tumors: a magnetic source imaging study. Neurosurgery 2001; 49: 1313–21.

Schiffbauer H, Berger MS, Ferrari P, Freudenstein D, Rowley HA, Roberts TP. Preoperative magnetic source imaging for brain tumor surgery: a

Downloaded from http://brain.oxfordjournals.org/ by guest on December 28, 2015

quantitative comparison with intraoperative sensory and motor mapping. J Neurosurg 2002; 97: 1333–42.

Schreiber A, Hubbe U, Ziyeh S, Hennig J. The influence of gliomas and nonglial space-occupying lesions on blood-oxygen-level-dependent contrast enhancement. AJNR Am J Neuroradiol 2000; 21: 1055–63.

Seitz RJ, Huang Y, Knorr U, Tellmann L, Herzog H, Freund HJ. Large-scale plasticity of the human motor cortex. Neuroreport 1995; 6: 742–4.

Seitz RJ. Recovery of executive motor functions. In: Boller F, Grafman J, editors. Handbook of neuropsychology. Vol. 11. New York: Elsevier; 1997. p. 185–207.

Seitz RJ, Hoflich P, Binkofski F, Tellmann L, Herzog H, Freund HJ. Role of the premotor cortex in recovery from middle cerebral artery infarction. Arch Neurol 1998; 55: 1081–8.

Selnes OA. Recovery from aphasia: activating the 'right' hemisphere. Ann Neurol 1999; 45: 419–20.

Shimizu T, Hosaki A, Hino T, Sato M, Komori T, Hirai S, et al. Motor cortical disinhibition in the unaffected hemisphere after unilateral cortical stroke. Brain 2002; 125: 1896–907.

Skirboll SS, Ojemann GA, Berger MS, Lettich E, Winn HR. Functional cortex and subcortical white matter located within gliomas. Neurosurgery 1996; 38: 678–84.

Stallones RA, Dyken ML, Fang H, Heyman A, Seltser R, Stamler JI. Epidemiology for stroke facilities planning. Stroke 1972; 3: 360–74.

Stein DG, Butters N, Rosen J. A comparison of two- and four-stage ablations of sulcus principals on recovery of spatial performance in the rhesus monkey. Neuropsychologia 1977; 15: 179–82.

Stewart JW, Ades H. The time factor in reintegration of a learned habit lost after temporal lobe lesions in the monkey (Macaca mulatta). J Comp Physiol Psychol 1951; 44: 479–86.

Taphoorn MJ, Klein M. Cognitive deficits in adult patients with brain tumours. Lancet Neurol 2004; 3: 159–68.

Thiebaut de Schotten M, Urbanski M, Duffau H, Volle E, Levy R, Dubois B, et al. Direct evidence for a parietal-frontal pathway subserving spatial awareness in humans. Science 2005; 309: 2226–8.

Thiel A, Herholz K, von Stockhausen HM, van Leyen-Pilgram K, Pietrzyk U, Kessler J, et al. Localization of language-related cortex with 15O-labeled water PET in patients with gliomas. Neuroimage 1998; 7: 284–95.

Thiel A, Herholz K, Koyuncu A, Ghaemi M, Kracht LW, Habedank B, et al. Plasticity of language networks in patients with brain tumors: a positron emission tomography activation study. Ann Neurol 2001; 50: 620–9.

Thiel A, Habedank B, Winhuisen L, Herholz K, Kessler J, Haupt WF, et al. Essential language function of the right hemisphere in brain tumor patients. Ann Neurol 2005; 57: 128–31.

Toni D, Fiorelli M, Bastianello S, Falcou A, Sette G, Ceschin V, et al. Acute ischemic strokes improving during the first 48 hours of onset: predictability, outcome, and possible mechanisms: a comparison with early deteriorating strokes. Stroke 1997; 28: 10–4.

Traversa R, Cicinelli P, Bassi A, Rossini PM, Bernardi G. Mapping of motor cortical reorganization after stroke. A brain stimulation study with focal magnetic pulses. Stroke 1997; 28: 110–7.

Turton A, Wroe S, Trepte N, Fraser C, Lemon RN. Contralateral and ipsilateral EMG responses to transcranial magnetic stimulation during recovery of arm and hand function after stroke. Electroencephalogr Clin Neurophysiol 1996; 101: 316–28.

Ulmer JL, Krouwer HG, Mueller WM, Ugurel MS, Kocak M, Mark LP. Pseudo-reorganization of language cortical function at fMR imaging: a consequence of tumor-induced neurovascular uncoupling. AJNR Am J Neuroradiol 2003; 24: 213–7.

Ulmer JL, Hacein-Bey L, Mathews VP, Mueller WM, DeYoe EA, Prost RW, et al. Lesion-induced pseudo-dominance at functional magnetic resonance imaging: implications for preoperative assessments. Neurosurgery 2004; 55: 569–79.

Uttal WR. The new phrenology. Cambridge, MA: MIT Press; 2001.

Vandermeeren Y, De Volder A, Bastings E, Thonnard JL, Duque J, Grandin C, et al. Functional relevance of abnormal fMRI activation pattern after unilateral schizencephaly. Neuroreport 2002; 13: 1821–4.

Varona JF, Bermejo F, Guerra JM, Molina JA. Long-term prognosis of ischemic stroke in young adults. Study of 272 cases. J Neurol 2004; 251: 1507–14.

Verleger R, Adam S, Rose M, Vollmer C, Wauschkuhn B, Kompf D. Control of hand movements after striatocapsular stroke: high-resolution temporal analysis of the function of ipsilateral activation. Clin Neurophysiol 2003; 114: 1468–76.

Vingerhoets FJ, Snow BJ, Lee CS, Schulzer M, Mak E, Calne DB. Longitudinal fluorodopa positron emission tomographic studies of the evolution of idiopathic parkinsonism. Ann Neurol 1994; 36: 759–64.

von Monakow C. Die Lokalisation im Groshirn und der Abbau der Funktion durch kortikale Herde. Wiesbaden, Germany: Bergman; 1914.

Walker DG, Kaye AH. Low grade glial neoplasms. J Clin Neurosci 2003; 10: 1–13.

Ward NS. Functional reorganization of the cerebral motor system after stroke. Curr Opin Neurol 2004; 17: 725–30.

Weiller C, Ramsay SC, Wise RJ, Friston KJ, Frackowiak RS. Individual patterns of functional reorganization in the human cerebral cortex after capsular infarction. Ann Neurol 1993; 33: 181–9.

Werhahn KJ, Conforto AB, Kadom N, Hallett M, Cohen LG. Contribution of the ipsilateral motor cortex to recovery after chronic stroke. Ann Neurol 2003; 54: 464–72.

Wessels PH, Weber WE, Raven G, Ramaekers FC, Hopman AH, Twijnstra A. Supratentorial grade II astrocytoma: biological features and clinical course. Lancet Neurol 2003; 2: 395–403.

Wunderlich G, Knorr U, Herzog H, Kiwit JC, Freund HJ, Seitz RJ. Precentral glioma location determines the displacement of cortical hand representation. Neurosurgery 1998; 42: 18–26.

Yoshiura T, Hasuo K, Mihara F, Masuda K, Morioka T, Fukui M. Increased activity of the ipsilateral motor cortex during a hand motor task in patients with brain tumor and paresis. AJNR Am J Neuroradiol 1997; 18: 865–9.

Yousry TA, Schmid UD, Jassoy AG, Schmidt D, Eisner WE, Reulen HJ, et al. Topography of the cortical motor hand area: prospective study with functional MR imaging and direct motor mapping at surgery. Radiology 1995; 195: 23–9.

Ziemann U. Improving disability in stroke with RTMS. Lancet Neurol 2005; 4: 454–5.

Downloaded from http://brain.oxfordjournals.org/ by guest on December 28, 2015