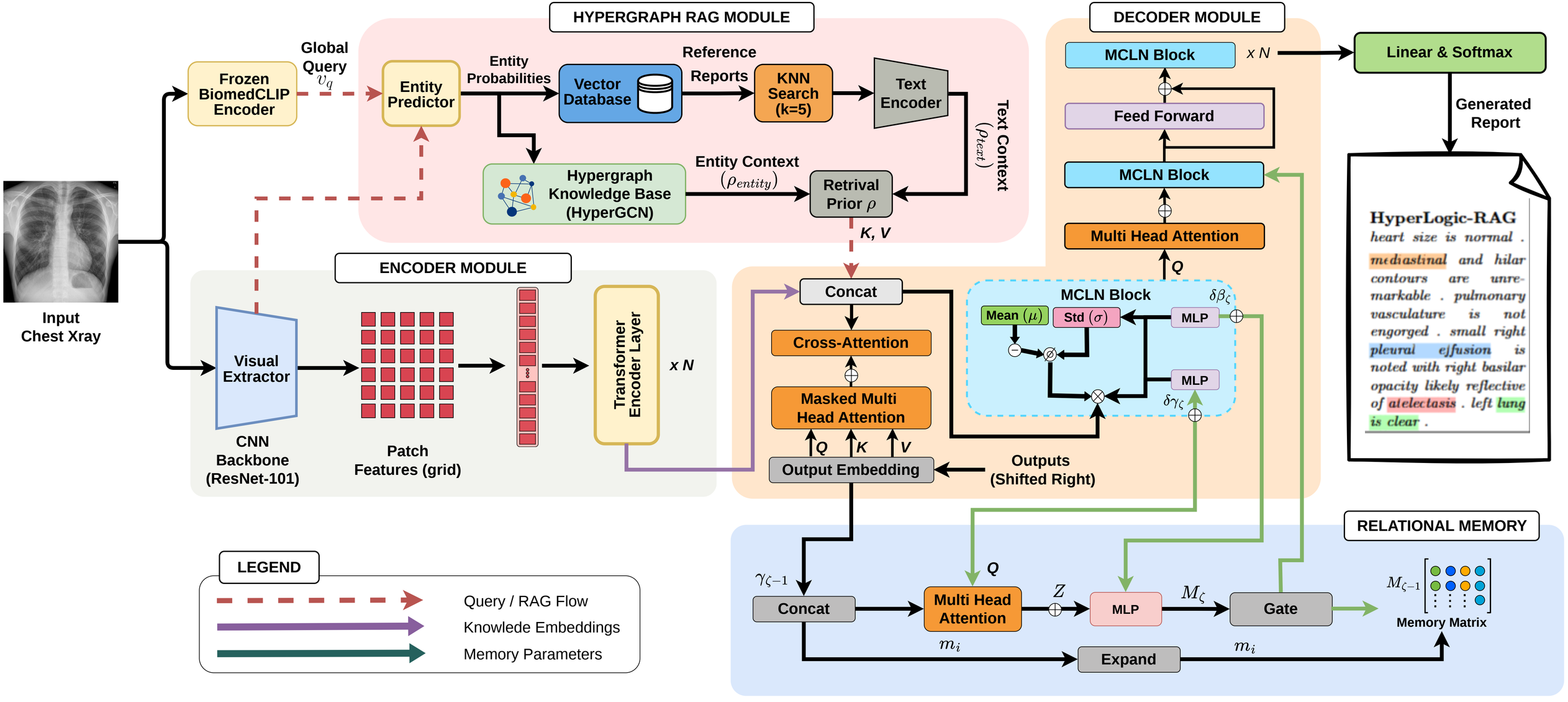
HYPERGRAPH RAG MODULE
DECODER MODULE
ENCODER MODULE
RELATIONAL MEMORY
LEGEND
Input Chest Xray
Frozen BiomedCLIP Encoder
Global Query v_q
Entity Predictor
Entity Probabilities
Vector Database
Reference Reports
KNN Search (k=5)
Text Encoder
Text Context (ρ_{text})
Hypergraph Knowledge Base (HyperGCN)
Entity Context (ρ_{entity})
Retrival Prior ρ
K, V
Visual Extractor
CNN Backbone (ResNet-101)
Patch Features (grid)
Transformer Encoder Layer
x N
Concat
Cross-Attention
Masked Multi Head Attention
Q K V
Output Embedding
Outputs (Shifted Right)
MCLN Block
x N
Feed Forward
MCLN Block
Multi Head Attention
Q
MCLN Block
Mean (μ)
Std (σ)
MLP
MLP
$\delta\beta_\zeta$
$\delta\gamma_\zeta$
Linear & Softmax
Generated Report
HyperLogic-RAG
heart size is normal . mediastinal and hilar contours are unremarkable . pulmonary vasculature is not engorged . small right pleural effusion is noted with right basilar opacity likely reflective of atelectasis . left lung is clear .
$\gamma_{\zeta-1}$
Concat
Q
Multi Head Attention
m_i
Z
MLP
M_ζ
Gate
Expand
m_i
$M_{\zeta-1}$
Memory Matrix
Query / RAG Flow
Knowlede Embeddings
Memory Parameters