ARDMS VASC CTL: Cerebrovascular Anatomy 21%

Start Assessment

ARDMS VASC CTL: Cerebrovascular Anatomy 21%
Completed: March 23, 2020 | Passing Score: 100 | Status: Failed

Correct Answers in Black | Incorrect Answers in Red

1. Which of the following anatomic variants of CA anatomy is most often associated with symptoms of cerebral ischemia? Points: 5 | 5

- tortuosity
- kinking
- coiling
- coiling

You answered: C

Feedback:
Kinking, coiling and tortuosity are all degrees or stages, the venous stenosis and is related to physical/mechanical formation. It is this anatomic variant most commonly associated with symptoms of ischemia.
Tortuosity - curved vessel
Kinking - sharp bend
Coiling - coiled 360 or more

2. Which of the following is **not** normally a branch of the ophthalmic artery? Points: 5 | 5

- frontal artery
- lacrimal artery
- central artery
- posterior ciliary artery

You answered: B

Feedback:
The posterior ciliary arise directly from the ICA and supplies the anterior segment/retina.

3. What are the standard windows used for a complete transcranial Doppler exam? Points: 5 | 5

- suboccipital, transtemporal, transorbital, and cervicothoracic windows
- suboccipital, transtemporal, and cervicothoracic windows
- suboccipital, transtemporal windows
- transtemporal, temporal only, other than performed if deoxyhemoglobin present

You answered: A

Feedback:
The four standard windows used for a TCD exam are the suboccipital, transtemporal, transcervical/cervicothoracic, and transorbital windows. The transorbital window is a supplemental window used to assess the blood flow of the ophthalmic artery.

4. The highest velocity in the normal common carotid artery is usually identified: Points: 5 | 5

- 1 cm from the bulb
- 1.5 cm from the bulb
- in the first 3cm of the vessel
- end CCA

You answered: D
Correct answer: A

Feedback:
The highest CCA velocity is usually identified in the first 3cm of the vessel. The highest CCA velocity is also usually identified in the proximal artery.

5. This image is probably was taken during a routine carotid reexamination. Points: 5 | 5

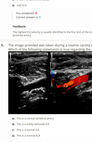

- This is a common carotid artery
- This is a CAS stenosis D
- This is a normal CCA
- This is a normal ECA

You answered: D

Feedback:
Note the branch originating from the proximal vessel. The ECA has no branches identified extracranially. The ventricular arteries circulate through the parenchyma of the ventricles and the cerebral is identified in the cerebral cortex.

6. Using the transtemporal window, the normal middle cerebral artery Points: 5 | 5

- will demonstrate flow toward the probe
- will demonstrate flow away from the probe
- will demonstrate biphasic flow
- will demonstrate a low spectral envelope

You answered: A

Feedback:
Using the transtemporal window, the normal MCA will demonstrate hemispheric flow toward the probe. Because the cerebral vessels are so small, no spectral envelope is demonstrated on the waveform.

7. Which of the following structures is supplied by branches of the internal carotid artery? Points: 5 | 5

- middle cerebral artery
- posterior cerebral artery
- anterior cerebral artery, but not the proximal sites
- pons, lateral cerebral and posterior lobes

You answered: D

Feedback:
Anterior cerebral internal carotid artery supplies the pons, lateral lobes and posterior lobes.

8. When scanning the internal carotid, which way would you angle your probe to image the internal carotid artery in most patients? Points: 5 | 5

- 45 degrees medially
- superior carotid sinus
- medial anterior artery
- lateral and/or anterior

You answered: B
Correct answer: C, D

Feedback:
When scanning the internal carotid artery, you angle your probe medial and anterior to locate the external carotid artery in most patients.

9. What is demonstrated on the image? Points: 5 | 5

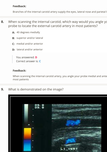

- normal internal jugular vein flow with reversed vertebral arteries flow
- normal internal jugular vein flow with normal vertebral flow
- normal carotid artery and vertebral arteries flow
- normal internal jugular vein flow with normal vertebral arteries flow

You answered: A
Correct answer: C, D

Feedback:
The carotid and vertebral arteries should normally demonstrate flow moving in the same direction. Because of the angle of the probe, the carotid artery is seen with flow moving away from the probe and the vertebral artery is seen with flow moving toward the probe. Reversed flow in the vertebral artery is the most commonly used to demonstrate the subclavian steal syndrome. Reversed flow in the vertebral artery is also seen in the presence of a hypoplastic vertebral artery. Reversed flow in the vertebral artery is not seen in normal patients.

10. Which artery supplies the brainstem with arterial blood? Points: 5 | 5

- anterior cerebral artery
- middle artery
- posterior cerebral artery
- posterior communicating artery

You answered: D

Feedback:
Branches from the vertebral and basilar arteries feed the cerebellum and portions of the brain stem.

11. In the Circle of Willis there is/are Points: 5 | 5

- 2 anterior communicator arteries and 1 middle communicator artery
- 2 anterior communicator arteries and 2 middle communicator arteries
- 1 anterior communicator artery and 2 posterior communicator arteries
- 2 anterior communicator arteries and 1 posterior communicator artery

You answered: D
Correct answer: C, D

Feedback:
In the Circle of Willis there is 1 anterior communicator artery and 2 posterior communicator arteries.

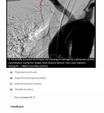

12. Which of the following describes the probe placement for a Doppler examination of the ophthalmic artery? Points: 5 | 5

- near the lateral canthus of the eye
- approximately 2cm above the supraorbital arch
- just above the lateral portion of the eyelid
- near the lateral canthus of the eye

You answered: A

Feedback:
Placement for a 2.0 MHz Doppler evaluation of the frontal artery branch of the ophthalmic artery: 2a-3b 1-3MHz pencil probe located near the lateral canthus of the eye. Probe direction will be toward the orbital.

13. Which of the following describes the probe placement for a Doppler examination of the ophthalmic artery? Points: 5 | 5

- Superior temporal artery
- Temporoparietal trunk
- Frontal artery
- Internal Maxillary artery

You answered: B
Correct answer: A, C

Feedback:
A. Internal Maxillary artery
B. Temporal trunk
C. Superior temporal artery
D. Frontal artery

14. Which of the following statements is true regarding the vertebral artery? Points: 5 | 5

- The right vertebral artery is normally smaller than the left.
- The right vertebral artery is the first branch of the aorta arch.
- Vertebral artery flow is normally biphasic due to turbulence at their junction with the basilar artery.
- The right and left vertebral arteries enter the cranium through the right and left foramen ovale.

You answered: A
Correct answer: B, C

Feedback:
The right vertebral artery is normally smaller than the left vertebral artery. It originates from the right subclavian artery. The vertebral arteries enter the cranium through the foramen magnum. Vertebral artery flow is biphasic because the vertebral arteries have tortuous, irregular vessels.

15. Which of the following describes the probe placement for a Doppler examination of the ophthalmic artery? Points: 5 | 5

- Temporoparietal trunk
- Superficial temporal artery
- Internal Maxillary artery
- Frontal artery

You answered: A

Feedback:
A. Internal Maxillary artery
B. Temporal trunk
C. Superficial temporal artery
D. Right CCA

16. Which of the following Doppler imaging characteristics will **not** assist in differentiating a stenosis in a CCA bifurcation? Points: 5 | 5

- Pulsing of flow
- Simple wave
- Simple transmitted
- Emission of flow

You answered: B
Correct answer: A, D

Feedback:
CCA stenosis by ultrasound evaluation determines the stenosis percentage from a ratio. The depth of the sample, flow velocity, and the angle of the sample are used to determine the percentage of stenosis. Pulsing of flow, simple wave, and simple transmitted are all characteristics of flow seen in a normal CCA. Emission of flow is not a characteristic of flow seen in a normal CCA.

17. Which of the following arteries will be compressed when evaluating the subclavian steal syndrome with Doppler? Points: 5 | 5

- ipsilateral brachial artery and vertebral artery
- ipsilateral carotid artery and vertebral artery
- ipsilateral temporal artery and ophthalmic artery
- ipsilateral artery and contralateral common carotid artery

You answered: B
Correct answer: A, C

Feedback:
A permitted Doppler exam involves using 5MHz Doppler to evaluate flow in the frontal artery (branch of the ophthalmic artery) and temporal artery (branch of the external carotid artery). Probe placement for the frontal artery is near the lateral canthus of the eye. Probe placement for the temporal artery is just anterior to the tragus of the ear. Probe direction is toward the orbital. Probe placement for the vertebral artery is in the posterior neck. Probe direction is toward the cranium. Probe placement for the ophthalmic artery is near the lateral canthus of the eye. Probe direction is toward the orbital. Probe placement for the carotid artery is in the anterior neck. Probe direction is toward the carotid artery and the orbital.

18. Which of the following arteries is supplied with blood from the ECA? Points: 5 | 5

- maxillary artery
- posterior communicator artery
- ophthalmic artery
- anterior cerebral artery

You answered: A

Feedback:
The maxillary artery is a branch of the ECA. The other choices are fed by the ICA.

19. When evaluating the carotid siphon from the submandibular window, the sample depth should be set to value between: Points: 5 | 5

- 10-40mm
- 40-60mm
- 60-80mm
- 80-100mm

You answered: A
Correct answer: C, D

Feedback:
The carotid siphon is evaluated when the sample depth is placed at an approximate depth of 70mm (between 60 and 80mm).

20. Branches of the _____ connect to branches of the _____ to provide collateral flow from the anterior circulation to the posterior circulation. Points: 5 | 5

- basilar artery
- ophthalmic artery
- vertebral artery
- carotid artery

You answered: A
Correct answer: B, D

Feedback:
The circle of Willis is a network of the ICA. Branches of the carotid arteries (internal carotid arteries) connect to branches of the vertebral arteries (basilar arteries) to provide collateral flow from the anterior circulation to the posterior circulation.


Head and Neck Arteries
Anterior cerebral artery
Middle cerebral artery
Posterior cerebral artery
Internal carotid artery
Vertebral artery
Basilar artery
Common carotid artery
Subclavian artery
Brachiocephalic artery
Aortic arch
Left common carotid artery
Left subclavian artery
Left vertebral artery
Left internal carotid artery
Left middle cerebral artery
Left anterior cerebral artery
Left posterior cerebral artery
Left internal jugular vein

Aortic	0.5	0.5	0.5	0.5

52. Which of the following is considered an abnormality that causes turbulence in a vessel? Points: **0 / 1**

- **A.** bifurcation
- **B.** tortuosity
- **C.** eccentric change in vessel course
- **D.** myointimal hyperplasia

You answered: **B**
Correct answer is: **D**

Feedback:

Abnormal causes of turbulence are acquired. Myointimal hyperplasia occurs with stent or bypass graft placement. Atherosclerosis formation or bypass grafts are acquired causes of turbulent flow in a vessel. The other choices offered are normal anatomic variants that can cause turbulence.

53. The angular artery is the terminal branch of the Points: **0 / 1**

- **A.** Ophthalmic artery
- **B.** Facial artery
- **C.** Anterior cerebral artery
- **D.** Nasal artery

You answered: **D**
Correct answer is: **B**

Feedback:

The angular artery is a terminal branch of the facial artery.

54. In most patients, the first branch of the ECA is: Points: **0 / 1**

- **A.** the internal thoracic artery
- **B.** the superior thyroid artery
- **C.** the ophthalmic artery
- **D.** the superficial temporal artery

You answered: **D**
Correct answer is: **B**

Feedback:

In most patients, the first branch of the ECA is the superior thyroid artery. The internal thoracic artery is a branch of the subclavian artery. The superficial temporal artery is a branch of the ECA but more distally. The ophthalmic artery is a branch of the ICA.

55. Which of the following vessels supply the majority of blood to the cerebellum? Points: **0 / 1**

- **A.** ICA and ECA
- **B.** ICA and Vertebral
- **C.** ECA and Basilar
- **D.** Vertebral and Basilar

You answered: **B**
Correct answer is: **D**

Feedback:

The cerebellum is located in the posterior fossa of the skull. The vertebral arteries course between the vertebral pedicles to converge into the basilar artery. Branches from the vertebral and basilar arteries feed the cerebellum and portions of the brain stem.

56. The supraorbital artery is a branch of the _____. Branches of the supraorbital artery connect with branches of the _____, which is a branch of the ECA. This is a common collateral pathway from the ECA to the ICA. Points: **0 / 1**

- **A.** ICA, ophthalmic artery
- **B.** ophthalmic artery, superficial temporal artery
- **C.** ophthalmic artery, maxillary artery
- **D.** ICA, facial artery

You answered: **C**
Correct answer is: **B**

Feedback:

The supraorbital artery is a branch of the ophthalmic artery. Branches for the supraorbital artery connect with branches of the superficial temporal artery, which is a branch of the ECA. This is a common collateral pathway from the ECA to the ICA.

57. What of the following describes the normal appearance of a waveform obtained in the middle cerebral artery? Points: **0 / 1**

- **A.** low resistance, laminar flow with clear spectral window
- **B.** low resistance flow that varies with patient respiration
- **C.** low resistance with spectral broadening
- **D.** low resistance, low velocity with small flow reversal component in diastole

You answered: **B**
Correct answer is: **C**

Feedback:

The intracranial arteries normally demonstrate low resistance flow due to the low resistance of the brain tissues. Spectral broadening is normal in these arteries due to the small size of the vessels. A spectral window would not normally be expected. Diastolic flow reversal would indicate an abnormality causing increased resistance to flow distally.

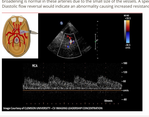

58. The suboccipital window is used in TCD exams to evaluate which of the following arteries? Points: **1 / 1**

- **A.** ICA siphon, vertebral and basilar
- **B.** vertebral and basilar
- **C.** ICA siphon
- **D.** MCA and ICA siphon

You answered: **B**

Feedback:

The suboccipital window is used to evaluate the vertebral and basilar arteries.

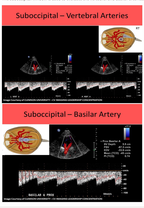

59. What blood vessel is used to cause the variations in diastolic flow on the ECA tracing? Points: **1 / 1**

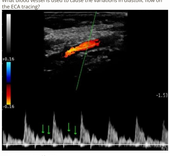

- **A.** common carotid artery
- **B.** supraorbital artery
- **C.** superficial temporal artery
- **D.** superficial thyroidal artery

You answered: **C**

Feedback:

The temporal tap is performed by lightly tapping the temporal artery located at the soft spot on the anterior aspect of the temporal bone. The temporal artery is a branch of the ECA and the vibrations from the tapping will be seen within the ECA waveform. The ICA does not communicate with the temporal artery and no response will be identified from the tapping maneuver. This technique is used to differentiate the ECA from the ICA.

60. Which of the following arteries is normally only an intracranial vessel? Points: **1 / 1**

- **A.** superficial temporal artery
- **B.** internal carotid artery
- **C.** vertebral artery
- **D.** basilar artery

You answered: **D**

Feedback:

The basilar artery is formed by the convergence of the left and right vertebral arteries inside the posterior aspect of the base of the skull.

61. Using the suboccipital window, the normal basilar and vertebral arteries _____. Points: **1 / 1**

- **A.** cannot be evaluated using this transcranial window
- **B.** will demonstrate flow away from the probe
- **C.** will demonstrate flow toward the probe
- **D.** will demonstrate bidirectional flow

You answered: **B**

Feedback:

The suboccipital window is performed by placing the transducer at the base of the skull and angling cephalad into the cranium. The normal basilar and vertebral arteries will demonstrate flow away from the probe, toward the brain.

62. The anterior cerebral artery and its branches feed which of the following lobes of the brain? Points: **1 / 1**

- **A.** occipital and frontal
- **B.** occipital and parietal
- **C.** frontal only
- **D.** parietal and frontal

You answered: **D**

Feedback:

The ACA and its branches feed the parietal and frontal lobes. The middle cerebral artery supplies large portions of the lateral surfaces of frontal, parietal, and temporal lobes. The vertebral and basilar arteries supply the brain stem, cerebellum, posterior parietal cortex. The posterior cerebral arteries originate from the basilar artery to supply the medial temporal and occipital lobes.

63. Which intracranial artery courses within the sylvian fissure? Points: **0 / 1**

- **A.** posterior cerebral artery
- **B.** basilar artery
- **C.** anterior cerebral artery
- **D.** middle cerebral artery

You answered: **A**
Correct answer is: **D**

Feedback:

The M2 segment courses within the sylvian fissure toward the lateral aspect of the cranium.

64. In most patients the right common carotid artery: Points: **0 / 1**

- **A.** originates directly from the aortic arch
- **B.** bifurcates at a lower level in the neck than the left CCA
- **C.** bifurcates at the level if the clavicle
- **D.** is nearly twice the diameter of the left CCA

You answered: **C**
Correct answer is: **B**

Feedback:

Right CCA originates from the innominate artery. Left CCA originates from the aortic arch (second branch from arch). In most patients the right CCA bifurcates at a lower level than the left CCA.

65. Normal brachial pressures should not differ more than _____ mmHg between arms. Points: **0 / 1**

- **A.** 5
- **B.** 10
- **C.** 30
- **D.** 20

You answered: **C**
Correct answer is: **D**

Feedback:

If the brachial pressures differ by more than 20mmHg, a subclavian steal should be suspected.

66. The posterior communicating arteries connect the: Points: **0 / 1**

- **A.** posterior cerebral artery and middle cerebral artery
- **B.** anterior cerebral artery and posterior cerebral artery
- **C.** basilar and posterior cerebral arteries
- **D.** vertebral and basilar arteries

You answered: **B**
Correct answer is: **A**

Feedback:

The posterior communicating arteries connect the ipsilateral PCA and MCA.

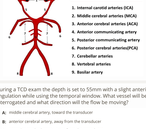

67. During a TCD exam the depth is set to 55mm with a slight anterior angulation while using the temporal window. What vessel will be interrogated and what direction will the flow be moving? Points: **0 / 1**

- **A.** middle cerebral artery, toward the transducer
- **B.** anterior cerebral artery, away from the transducer
- **C.** posterior cerebral artery, away from the transducer
- **D.** middle cerebral artery, away from the transducer

You answered: **D**
Correct answer is: **A**

Feedback:

MCA = 30-65mm depth at temporal window; normally demonstrates flow moving toward the transducer

Transtemporal Window

Intracranial Vessel	Average Depth (mm)	Flow Direction	Transducer Angulation	Direction of Flow
MCA (MC)	30 - 65mm	Anterior	15mm/5 ≤ 15mm/5	Toward
ACA	60 - 85mm	Anterior	15mm/5 ≥ 15mm/5	Away
PCA (P1)	60 - 75mm	Posterior - P1 Curve	20mm/5 ≤ 20mm/5	Toward
PCA (P2)	65 - 75mm	Posterior	45mm/5 ≥ 45mm/5	Away
Deep ICA	55 - 65mm	Anterior and Caudal	30mm/5 ≥ 30mm/5	Bi-directional

68. Transcranial Doppler most commonly uses which Doppler measurement to evaluate flow in the cerebral vessels? Points: **1 / 1**

- **A.** peak systolic velocity
- **B.** time average maximum velocity
- **C.** resistive index
- **D.** end diastolic velocity

You answered: **B**

Feedback:

Time average maximum velocity or mean flow velocity is used to assess flow in the cerebral arteries.

69. Which of the following is a branch of the ICA? Points: **1 / 1**

- **A.** Ophthalmic
- **B.** Temporal
- **C.** Lingual
- **D.** Superior thyroidal

You answered: **A**

Feedback:

The ophthalmic artery feeds the eye and surrounding structures. This is the only branch of the ICA before it enters the Circle of Willis. The ECA is responsible for feeding extracranial structures including the face, portions of the throat and neck, tongue and scalp.

Powered by ExamBuilder. Copyright ©2020