ARDMS VASC CTL: Extremity Artery Pathology/32%

Tutorial | Review

ARDMS VASC CTL: Extremity Artery Pathology/32%
Completed March 22, 2020 | Passing Score: 150 | Status: Failed

Correct Answers in Blue | Incorrect Answers in Red

1. Which of the following is an abnormal flow change caused by congenital heart failure? Points: 8/1=

- a. Hemiplegic pulse flow
- b. Pulsus bigeminus and pulsus alternans
- c. Systolic flow in the proximal hepatic vein
- d. Decreased arterial pressure

You answered: C
Correct answer: b, d

Feedback
CHF reduces cardiac output that leads to diastolic arterial vein flow, decreased reduction in the bilateral common carotid artery resistance, decreased arterial pressure, and decreased pulsatility in the hepatic artery. Pulsus bigeminus and pulsus alternans are the regular effects from cardiac tamponade. The possibility increases with CHF.

2. When evaluating a focal stenosis of the femoral artery, where should you place the scanner to obtain the highest velocity related to the stenosis? Points: 8/1=

- a. Immediately proximal to the first point of the stenosis
- b. 1 cm distal to the first point of the stenosis
- c. At the narrowest point in the vessel or immediately distal to the first point of the stenosis
- d. 1 cm proximal to the first point of the stenosis

You answered: C

Feedback
When evaluating a focal stenosis of an artery, you should place the scanner at the narrowest point in the vessel or immediately distal to the first point of the stenosis. Velocity increases as blood flows through the stenosis. It is important to move the Doppler cursor through the stenosis and manipulate the angle of the cursor to obtain the peak velocity.

3. A patient complains of right leg pain and color changes in the leg. When he lies down, the right calf and foot become pale. When he stands up, the right calf and foot become reddened. The left leg is normal. Which of the following vascular lab results are most suggestive of? Points: 8/1=

- a. Left carotid stenosis
- b. Deep venous reflux
- c. Significant aortic obstruction
- d. Significant right leg vascular obstruction

You answered: A
Correct answer: d

Feedback
Fabricant's Syndrome is an exclusive or significant arterial disease. The unilateral presentation indicates the obstruction is blocking the blood flow to the right leg. Since the leads the hypertension the color changes as the blockage must be at the level of the L2-L3 right lumbar vertebrae or higher.

4. Why does blood move into smaller collateral vessels when a larger vessel is occluded? Points: 8/1=

- a. The resistance in flow in the smaller collateral is lower than the resistance in the occluded vessel
- b. Because of the significant drop in venous pressure
- c. The resistance in flow in the smaller collateral is higher than the resistance in the occluded vessel
- d. Is compliance for loss of blood flow proximal to the obstruction

You answered: A

Feedback
Collateral flow around an occlusion develops to compensate for the reduction in flow to the distal tissues. When the native vessel is occluded, the resistance in the collateral vessel is lower than the resistance in the occluded vessel. Blood flow moves into the lower resistance flow in the smaller collateral is lower than the resistance in the occluded vessel. Blood flow moves into the vessel with the least resistance.

5. You are performing a lower extremity arterial Doppler exam due to claudication. You find a stenosis in the distal aorta. The PSV is 300 cm/sec and a band from the proximal left and right external iliac arteries. This image is the band. Is correct? Points: 8/1=

- a. Pseudoaneurysm of the iliac artery
- b. Lumbar spondylosis
- c. May Thurner syndrome
- d. Paget Schroetter syndrome

You answered: A, B
Correct answer: A, B

Feedback
Lumbar spondylosis is a disease of the distal aorta. If both iliac arteries demonstrate post-stenotic flow patterns, there is a lesion in the common iliac artery.

6. Which of the following describes the abnormal response to papaverine injection during a penile impotence exam? Points: 5/1=

- a. Decreased blood velocity surface
- b. Are PSA and EDV left unchanged
- c. Are PSA and EDV increase post-injection but distal venous flow left remain unchanged
- d. Are PSA and EDV increase post-injection and distal venous flow decreases
- e. Increased diameter of the cavernosal artery

You answered: C

Feedback
Papaverine injection increases the diameter of the cavernosal arteries with Doppler, pre- and post- stimulation injection papaverine increases peak systolic velocity and EDV and increases post-injection distal venous flow decreases.

7. Which of the following is the most likely cause of this Doppler exam? Points: 5/1=

- a. Arterial Doppler exam
- b. Fistula Doppler exam
- c. Venous Doppler exam
- d. Deep venous duplex exam

You answered: A

Feedback
Arterial pulsatility is characterized by a fast rise, a sharp, deep, primary negative notch, which is consistent with an intact Doppler waveform. Arterial pulsatility and signals are characterized by a primary negative notch. The primary negative notch is the result of vascular and cardiac impulses. Arterial pulsatility is a sign of the presence of a patent vessel.

8. What critical finding is associated with calf paresthesia, localized tenderness, and pain on stretching calf muscles, and drop foot? Points: 5/1=

- a. Claudication, a posterior
- b. Lymphatic arterial disease
- c. Lumbar compression syndrome
- d. Lymphatic entrapment

You answered: C

Feedback
Acute compartment syndrome is a medical emergency. It is usually caused by a severe injury and without intervention, it can lead to permanent muscle damage. Symptoms of compartment syndrome include paresthesia, localized muscle tenderness, and pain on stretching the affected muscles.

9. A patient presents for a lower extremity arterial exam with total blistered leg pain. The 2D evaluation demonstrates minimal diffuse atherosclerosis. The PSV is 300 cm/sec and a band from the distal aorta of both legs. Intermittent lightheadedness and with increased acceleration time. Which of the following could explain these findings? Points: 8/1=

- a. Anterior proximal angiosarcoma
- b. Lumbar spondylosis Fabricant SMS
- c. Lumbar compression syndrome
- d. Lumbar hypertrophic

You answered: A
Correct answer: b, d

Feedback
Distal stenosis in a lower extremity vascular can indicate a similar issue, especially in the absence of cervical or bilateral flow. Lumbar spondylosis is a disease of the distal aorta. Lumbar compression syndrome is a disease of the distal aorta. Lumbar hypertrophic is a degenerative condition also indicates lower extremities flow.

10. The common femoral artery velocity is 0.8 m/s and the proximal femoral artery demonstrates atherosclerosis formation causing an increase in the velocity to 1.2 m/s. This indicates what level of stenosis? Points: 5/1=

- a. 100
- b. 75%
- c. 50%
- d. 25%

You answered: C

Feedback
Doppler velocity between two severity vessel segments doubles, this indicates at least a 50% stenosis. When the velocity doubles, the narrowing vessel area is approximately 75% stenosis. A stenosis of 100% is occlusion.

11. You receive an order for an upper extremity arterial exam to rule out Buerger disease. What is the preferred method of evaluation? Points: 5/1=

- a. Evaluate the smaller arteries of the arm with Duplex and PPG techniques
- b. Evaluate the arteries of the wrists for normal compression with treadmill
- c. Evaluate the arterial flow in hot and cold exercise
- d. Evaluate the radial for vasospasm changes with contrasting testing

You answered: A
Correct answer: A

Feedback
Buerger's disease affects the smaller arteries of the wrists and arm and the 2 is some common in males and smokers. Buerger's disease affects smaller vessels. PPG technique can be employed and of the exam is where digital flow. Microvascular disease affects the smaller vessels. Raynaud's disease affects the smaller vessels. Raynaud's disease affects the smaller vessels. Thoracic outlet is Fabricant.

Source: https://www.youtube.com/watch?v=ZUCzFdbbbbY

12. What is the most common cardiac disorder associated with arterial embolus? Points: 5/1=

- a. Cardiomyopathy
- b. Mitral stenosis
- c. Myocardial infarction
- d. Atrial fibrillation

You answered: D

Feedback
80-90% of arterial emboli are from a cardiac source. Atrial fibrillation can lead to clot formation in the left atrium. If the clot dislodges, it can travel to the arterial system causing an embolus. Mitral stenosis can also lead to clot formation in the left atrium and result in the right heart and the pulmonary circulation.

13. Which of the following correctly describes thoracic outlet syndrome? Points: 5/1=

- a. PPG or PSP testing can be used to evaluate a patient with suspected TOS
- b. Thoracic outlet syndrome affects the arteries, veins, and nerves in the affected arm and pelvis
- c. The thoracic sign indicates a positive test result for TOS
- d. The Trout test is used during suspected for TOS

You answered: A

Feedback
Patients with TOS commonly experiencing left, and pain and paresthesia in the affected shoulder/arm. PPG or PSP testing can be used to evaluate a patient with suspected TOS using specific maneuvers during testing. The thoracic sign refers to pain or paresthesia in the affected shoulder/arm. The Trout test is used during suspected for TOS. Thoracic outlet syndrome affects the arteries, veins, and nerves associated with hypertrophic thoracic vertebrae.

14. An abnormality in which of the following vessels could be the cause of neurogenic claudication? Points: 8/1=

- a. Internal and external iliac arteries
- b. Lumbar and sacral arteries
- c. Lumbar and sacral lateral arteries
- d. Lumbar and gluteal arteries

You answered: B
Correct answer: b, d

Feedback
The external iliac artery supplies blood to the leg. The internal iliac artery supplies blood to the branches that supply the pelvic organs, the gluteal muscles, and the muscles of the thigh. The lumbar and sacral arteries are the branches that supply the lumbar and sacral vertebrae. The gluteal arteries originate from the pelvic and supply blood to the muscle and tendons.

15. Which of the following has no effect on the severity of an arterial stenosis? Points: 8/1=

- a. Lymphedema vera
- b. Peripheral angiosarcoma
- c. Small tortius
- d. Lumbar compression

You answered: C
Correct answer: b, d

Feedback
The pelvic venous plexus, not the arteries. Scleroser incompetence will not affect arterial stenosis.

16. An AV malformation is most commonly caused by: Points: 8/1=

- a. Immediate trauma
- b. Severe angiography procedure
- c. A congenital defect
- d. Trauma

You answered: B
Correct answer: a, c

Feedback
An AVM is a congenital defect, or AVF is caused by trauma or an interventional procedure.

17. Pannus is defined as: Points: 8/1=

- a. An abnormal skin sensation, such as numbness or tingling
- b. Loss of bone or one eye for a short period of time
- c. Anomaly related to change in patient position
- d. Trial of delay to move or anomaly or other body part

You answered: C
Correct answer: a, d

Feedback
Pannus is defined as a loss of ability to move an extremity or other body part. Paresthesia refers to an abnormal skin sensation, such as numbness or tingling.

18. A 70% stenosis in the proximal femoral artery will cause the _____ in the mid femoral artery. Points: 8/1=

- a. acceleration time to decrease
- b. velocity to increase
- c. Pulsatility Index to decrease
- d. resistance index to increase

You answered: A
Correct answer: b, d

Feedback
Stenosis causes velocity to rise since the total of systolic peaks spikes. High resistance vessels have short acceleration times. Low resistance vessels and arterial distal to a stenosis will demonstrate longer acceleration times.

19. The Scimitar sign is associated with: Points: 8/1=

- a. Renal aorta
- b. Hepatic artery
- c. Median arcuate ligament syndrome
- d. Pancreas or Pancreas hypo gyrl

You answered: C
Correct answer: b, d

Feedback
The Scimitar sign is associated with abnormal lung venous drainage. This abnormal vessel is recognized by the right and left lung fields and the right cardiac shadow.

20. Adventitial cysts: Points: 5/1=

- a. Arise commonly affect the popliteal artery
- b. Are a rare cause of peripheral arterial occlusion
- c. are a normal variant that can be seen up to 10% of patients
- d. are more common in women

You answered: A

Feedback
Adventitial cysts are a rare condition that involves the collection of mucinous material within the adventitial wall layer of the affected vessel. They predominantly affect the popliteal arteries with the popliteal artery most commonly affected. The cysts are most commonly seen in middle-aged men. They are a rare cause of peripheral arterial occlusion.

21. Patients with this risk factor have a greater incidence of atherosclerotic disease in walls of the vessels in the calf: Points: 5/1=

- a. Diabetes
- b. Raynaud syndrome
- c. Post-phlebitic syndrome
- d. Systemic SYN

You answered: A

Feedback
Diabetic patients suffer from medial calcification of the distal vessel walls. This leads to increased resistance in the vessels and decreased flow.

22. If there is a 75% stenosis of the distal aortic artery, which of the following pressures will demonstrate a hyphasic waveform? Points: 5/1=

- a. Lumbosacral
- b. Lumbar
- c. Ankle
- d. Brachial

You answered: A

Feedback
A 75% stenosis in the aortic artery will cause a significant loss of flow distally. The resistance in the distal vessels will drop and the waveform will become hyphasic. The lumbosacral pressure is proximal to the stenosis and will not show a significant change.

23. Which of the following is used to determine the capability of healing a venous ulcer of a leg? Points: 5/1=

- a. Arterial Doppler exam
- b. Transcutaneous oximetry
- c. Fistulotomy
- d. Photoplethysmography

You answered: B

Feedback
Transcutaneous oximetry evaluates oxygen supply and consumption in the tissues surrounding a wound. The partial pressure of the oxygen is recorded in the tissues around the wound. 30-40mmHg indicates normal pressures. 40mmHg indicates tissue hypoxia. Transcutaneous oximetry is a non-invasive test.

24. The pulsatility index demonstrates a 75% stenosis. Which of the following arteries will demonstrate monophasic flow due to the stenosis? Points: 8/1=

- a. Lumbar
- b. Lumbosacral
- c. Lumbar Vital
- d. Lower of the abdom

You answered: B
Correct answer: b, d

Feedback
The Fabricant sign is negative for a patient and calf vessels with blood. A stenosis in the proximal artery will not cause decreased blood flow in the distal vessels.

25. A velocity is recorded in the distal femoral artery of 2.75m/s, what hemodynamic changes will be seen in popliteal artery? Points: 8/1=

- a. Sigh velocity, peaked waveform
- b. Increased diastolic flow velocity
- c. Decreased acceleration time
- d. Increased acceleration time

You answered: C
Correct answer: b, d

Feedback
The stenosis distal to the stenosis will be decreased and flow will become monophasic. Acceleration time is prolonged with lower velocity flow.

26. If a patient suffers from ischemic rest pain in the foot, what maneuver should be done? Points: 5/1=

- a. Sitting
- b. Sitting with legs elevated
- c. Walking
- d. Isometric Vasoscan

You answered: A

Feedback
Isometric exercise is described as burning pain in the ball of the foot and toes that is worse at night when the patient is lying down. Sitting or hanging the legs is a dependent position would act quickly to ease the arterial flow in trending the foot and toes. Walking is a dynamic exercise that increases the blood flow to the muscles and results in a decrease in ischemic signs and symptoms.

27. Which of the following measurements is used to differentiate reflux from outflow disease in the lower extremity arteries? Points: 5/1=

- a. Systolic ratio
- b. Pulsatility index
- c. Ankle index
- d. Resistive index

You answered: B

Feedback
Acceleration Time is measured to differentiate reflux from outflow disease in the lower extremity. Measure the time from the onset of systole to the peak of systole to be accurate.

28. Which of the following is a sign of a significant femoral artery in 1 Mm, that slowed to suspected. If PSA of 1 both of the common femoral arteries 1 Mm, which, which, disease is suspected? Points: 5/1=

- a. Distal AT is associated with dead obstruction. With a distal obstruction, the systolic upstroke will become steeper + shorter time from onset to peak
- b. Distal AT is associated with dead obstruction. With a distal obstruction, the systolic upstroke will become steeper + shorter time from onset to peak

29. Lee classification, Fredericks and Hall grain, and asymmetric bracelet are used to describe which patients? Points: 5/1=

- a. Venous ulcers and gangrene
- b. Reactive gangrenous
- c. Arteriosclerosis obliterans
- d. gain left and rh

You answered: A

Feedback
Stasis Ulcer Severity. Temporal arteritis is associated with headache and tenderness over the temp. Experiments. Surgical blood vessel repair. Lee classification, Fredericks and Hall grain, asymmetric bracelet. Often associated with venous ulcers or the leak, and coagulation, and visual disturbances.

30. Which of the following is a sign of Buerger's disease? Points: 5/1=

- a. Thoracic outlet syndrome
- b. Raynaud's disease
- c. Lumbar compression syndrome
- d. Lumbar hypertrophic

You answered: A

Feedback
Buerger's disease affects the smaller arteries and veins of the wrists and arm and the 2 is some common in males and smokers. Buerger's disease affects smaller vessels. Thoracic outlet syndrome affects the arteries, veins, and nerves associated with hypertrophic thoracic vertebrae. Raynaud's disease affects the smaller vessels. Raynaud's disease affects the smaller vessels. Lumbar compression syndrome affects the arteries, veins, and nerves associated with hypertrophic lumbar vertebrae.

29. A patient presents with a history of right leg and thigh pain with numbness when he walks. The exercise time varies before the pain starts and it is relieved by sitting down. There are no symptoms in his left leg. What is the most likely diagnosis? Points: 8/1-5

- a. Lumbar spinal stenosis
- b. Chronic venous disease
- c. Peripheral vascular disease
- d. Ischiogenic claudication

You answered: **A**
Correct answer: **A**

Feedback:
The leg pain is exercise and neurogenic which are two components of claudication related to vascular disease. Peripheral vascular disease is related to venous compromised arterial in the symptoms. The feeling of pain and paresthesia is relieved by sitting down and lying down. Lumbar spinal stenosis is a cause of neurogenic claudication. Chronic venous disease and in the leading edge symptoms confirmed the same. Ischiogenic claudication is a consequence.

30. Which of the following is considered a risk factor for peripheral arterial disease? Points: 8/1-5

- a. Diabetes
- b. Chronic obstructive pulmonary disease
- c. Pregnancy
- d. Sclerosis, repetitive exercising

You answered: **B**
Correct answer: **A, D**

Feedback:
Diabetes will cause hardening of the arterial walls, especially in smaller arteries. The calf and digital arteries are first affected and the disease progresses to the proximal arteries. Chronic obstructive pulmonary disease is a risk factor for coronary artery disease. Effect on the development of arterial disease. A long list of risk factors affect the rate of atherosclerotic disease.

31. A patient presents with leg pain 2 days after a coronary artery catheterization. All of the following are an important part of the history and exam in this patient, **except**: Points: 8/1-5

- a. Evaluation of the site of the catheterization and femoral pulses and bruits
- b. Evaluation of the new flow disturbances
- c. Evaluation of the leg for signs of pallor
- d. Evaluation of the groin for a mass

You answered: **B**
Correct answer: **C**

Feedback:
Pulses, bruits, and skin and tissues are symptoms of chronic disease that would not really be expected in the acute onset of the pain complaint. Angiography procedures have a risk of arterial pseudoaneurysm, AV fistula (bruit), distal embolization (new bruit) and acute occlusion from the pressure.

32. Thromboangiitis obliterans involves inflammation of: Points: 8/1-5

- a. all vessel walls with no effect on connective tissue
- b. small wall layer
- c. all vessel walls and surrounding connective tissue
- d. critical and media wall

You answered: **D**
Correct answer: **C**

Feedback:
Thromboangiitis refers to diffuse inflammation of the critical wall layer. Thromboangiitis obliterans refers to inflammation of all vessel walls with surrounding tissue. Acute Rheumatic Fever affects the critical and media layers.

33. If the acceleration time is >140ms in both common femoral arteries: Points: 8/1-5

- a. Lesion proximal to the disease is suspected
- b. Pelvis is considered normal
- c. Aorta disease is suspected
- d. Lesion distal to the disease is suspected

You answered: **C**
Correct answer: **C, C**

Feedback:
If the acceleration time is >140ms in both common femoral arteries, aorta disease is suspected. Increased or longer GP waveform is suspected.
If the acceleration time is >140ms in one common femoral artery proximal but normal is suspected. Decreased or shorter GP indicates a distal obstruction.

34. Patients with lower extremity arterial disease may describe pain: Points: 8/1-5

- a. Pain is relieved by lifting
- b. Pain is relieved by resting the legs
- c. Pain is relieved by placing legs in a dependent position
- d. Pain is relieved by lying down

You answered: **D**
Correct answer: **C, C**

Feedback:
The dependent position helps blood to reach the lower leg veins easily. Walking and elevating the legs would increase the pain. Lying down would not relieve the pain because it is not the dependent position.

35. The most common color change demonstrated in a lower extremity with an acute arterial occlusion is: Points: 8/1-5

- a. Cyanosis
- b. pallor
- c. Cyanosis
- d. color

You answered: **A**
Correct answer: **A, A**

Feedback:
6 Ps of Acute Arterial Occlusion:
1. Pain
2. Pallor
3. Paresthesias
4. Paralysis
5. Pulse
6. Poikilothermia
7. Pulse Deficit
8. Poikilothermia
9. Pulse Deficit
10. Poikilothermia
11. Pulse Deficit
12. Poikilothermia
13. Pulse Deficit
14. Poikilothermia
15. Pulse Deficit
16. Poikilothermia
17. Pulse Deficit
18. Poikilothermia
19. Pulse Deficit
20. Poikilothermia
21. Pulse Deficit
22. Poikilothermia
23. Pulse Deficit
24. Poikilothermia
25. Pulse Deficit
26. Poikilothermia
27. Pulse Deficit
28. Poikilothermia
29. Pulse Deficit
30. Poikilothermia
31. Pulse Deficit
32. Poikilothermia
33. Pulse Deficit
34. Poikilothermia
35. Pulse Deficit
36. Poikilothermia
37. Pulse Deficit
38. Poikilothermia
39. Pulse Deficit
40. Poikilothermia
41. Pulse Deficit
42. Poikilothermia
43. Pulse Deficit
44. Poikilothermia
45. Pulse Deficit
46. Poikilothermia
47. Pulse Deficit
48. Poikilothermia
49. Pulse Deficit
50. Poikilothermia
51. Pulse Deficit
52. Poikilothermia
53. Pulse Deficit
54. Poikilothermia
55. Pulse Deficit
56. Poikilothermia
57. Pulse Deficit
58. Poikilothermia
59. Pulse Deficit
60. Poikilothermia
61. Pulse Deficit
62. Poikilothermia
63. Pulse Deficit
64. Poikilothermia
65. Pulse Deficit
66. Poikilothermia
67. Pulse Deficit
68. Poikilothermia
69. Pulse Deficit
70. Poikilothermia
71. Pulse Deficit
72. Poikilothermia
73. Pulse Deficit
74. Poikilothermia
75. Pulse Deficit
76. Poikilothermia
77. Pulse Deficit
78. Poikilothermia
79. Pulse Deficit
80. Poikilothermia
81. Pulse Deficit
82. Poikilothermia
83. Pulse Deficit
84. Poikilothermia
85. Pulse Deficit
86. Poikilothermia
87. Pulse Deficit
88. Poikilothermia
89. Pulse Deficit
90. Poikilothermia
91. Pulse Deficit
92. Poikilothermia
93. Pulse Deficit
94. Poikilothermia
95. Pulse Deficit
96. Poikilothermia
97. Pulse Deficit
98. Poikilothermia
99. Pulse Deficit
100. Poikilothermia
101. Pulse Deficit
102. Poikilothermia
103. Pulse Deficit
104. Poikilothermia
105. Pulse Deficit
106. Poikilothermia
107. Pulse Deficit
108. Poikilothermia
109. Pulse Deficit
110. Poikilothermia
111. Pulse Deficit
112. Poikilothermia
113. Pulse Deficit
114. Poikilothermia
115. Pulse Deficit
116. Poikilothermia
117. Pulse Deficit
118. Poikilothermia
119. Pulse Deficit
120. Poikilothermia
121. Pulse Deficit
122. Poikilothermia
123. Pulse Deficit
124. Poikilothermia
125. Pulse Deficit
126. Poikilothermia
127. Pulse Deficit
128. Poikilothermia
129. Pulse Deficit
130. Poikilothermia
131. Pulse Deficit
132. Poikilothermia
133. Pulse Deficit
134. Poikilothermia
135. Pulse Deficit
136. Poikilothermia
137. Pulse Deficit
138. Poikilothermia
139. Pulse Deficit
140. Poikilothermia
141. Pulse Deficit
142. Poikilothermia
143. Pulse Deficit
144. Poikilothermia
145. Pulse Deficit
146. Poikilothermia
147. Pulse Deficit
148. Poikilothermia
149. Pulse Deficit
150. Poikilothermia
151. Pulse Deficit
152. Poikilothermia
153. Pulse Deficit
154. Poikilothermia
155. Pulse Deficit
156. Poikilothermia
157. Pulse Deficit
158. Poikilothermia
159. Pulse Deficit
160. Poikilothermia
161. Pulse Deficit
162. Poikilothermia
163. Pulse Deficit
164. Poikilothermia
165. Pulse Deficit
166. Poikilothermia
167. Pulse Deficit
168. Poikilothermia
169. Pulse Deficit
170. Poikilothermia
171. Pulse Deficit
172. Poikilothermia
173. Pulse Deficit
174. Poikilothermia
175. Pulse Deficit
176. Poikilothermia
177. Pulse Deficit
178. Poikilothermia
179. Pulse Deficit
180. Poikilothermia
181. Pulse Deficit
182. Poikilothermia
183. Pulse Deficit
184. Poikilothermia
185. Pulse Deficit
186. Poikilothermia
187. Pulse Deficit
188. Poikilothermia
189. Pulse Deficit
190. Poikilothermia
191. Pulse Deficit
192. Poikilothermia
193. Pulse Deficit
194. Poikilothermia
195. Pulse Deficit
196. Poikilothermia
197. Pulse Deficit
198. Poikilothermia
199. Pulse Deficit
200. Poikilothermia
201. Pulse Deficit
202. Poikilothermia
203. Pulse Deficit
204. Poikilothermia
205. Pulse Deficit
206. Poikilothermia
207. Pulse Deficit
208. Poikilothermia
209. Pulse Deficit
210. Poikilothermia
211. Pulse Deficit
212. Poikilothermia
213. Pulse Deficit
214. Poikilothermia
215. Pulse Deficit
216. Poikilothermia
217. Pulse Deficit
218. Poikilothermia
219. Pulse Deficit
220. Poikilothermia
221. Pulse Deficit
222. Poikilothermia
223. Pulse Deficit
224. Poikilothermia
225. Pulse Deficit
226. Poikilothermia
227. Pulse Deficit
228. Poikilothermia
229. Pulse Deficit
230. Poikilothermia
231. Pulse Deficit
232. Poikilothermia
233. Pulse Deficit
234. Poikilothermia
235. Pulse Deficit
236. Poikilothermia
237. Pulse Deficit
238. Poikilothermia
239. Pulse Deficit
240. Poikilothermia
241. Pulse Deficit
242. Poikilothermia
243. Pulse Deficit
244. Poikilothermia
245. Pulse Deficit
246. Poikilothermia
247. Pulse Deficit
248. Poikilothermia
249. Pulse Deficit
250. Poikilothermia
251. Pulse Deficit
252. Poikilothermia
253. Pulse Deficit
254. Poikilothermia
255. Pulse Deficit
256. Poikilothermia
257. Pulse Deficit
258. Poikilothermia
259. Pulse Deficit
260. Poikilothermia
261. Pulse Deficit
262. Poikilothermia
263. Pulse Deficit
264. Poikilothermia
265. Pulse Deficit
266. Poikilothermia
267. Pulse Deficit
268. Poikilothermia
269. Pulse Deficit
270. Poikilothermia
271. Pulse Deficit
272. Poikilothermia
273. Pulse Deficit
274. Poikilothermia
275. Pulse Deficit
276. Poikilothermia
277. Pulse Deficit
278. Poikilothermia
279. Pulse Deficit
280. Poikilothermia
281. Pulse Deficit
282. Poikilothermia
283. Pulse Deficit
284. Poikilothermia
285. Pulse Deficit
286. Poikilothermia
287. Pulse Deficit
288. Poikilothermia
289. Pulse Deficit
290. Poikilothermia
291. Pulse Deficit
292. Poikilothermia
293. Pulse Deficit
294. Poikilothermia
295. Pulse Deficit
296. Poikilothermia
297. Pulse Deficit
298. Poikilothermia
299. Pulse Deficit
300. Poikilothermia
301. Pulse Deficit
302. Poikilothermia
303. Pulse Deficit
304. Poikilothermia
305. Pulse Deficit
306. Poikilothermia
307. Pulse Deficit
308. Poikilothermia
309. Pulse Deficit
310. Poikilothermia
311. Pulse Deficit
312. Poikilothermia
313. Pulse Deficit
314. Poikilothermia
315. Pulse Deficit
316. Poikilothermia
317. Pulse Deficit
318. Poikilothermia
319. Pulse Deficit
320. Poikilothermia
321. Pulse Deficit
322. Poikilothermia
323. Pulse Deficit
324. Poikilothermia
325. Pulse Deficit
326. Poikilothermia
327. Pulse Deficit
328. Poikilothermia
329. Pulse Deficit
330. Poikilothermia
331. Pulse Deficit
332. Poikilothermia
333. Pulse Deficit
334. Poikilothermia
335. Pulse Deficit
336. Poikilothermia
337. Pulse Deficit
338. Poikilothermia
339. Pulse Deficit
340. Poikilothermia
341. Pulse Deficit
342. Poikilothermia
343. Pulse Deficit
344. Poikilothermia
345. Pulse Deficit
346. Poikilothermia
347. Pulse Deficit
348. Poikilothermia
349. Pulse Deficit
350. Poikilothermia
351. Pulse Deficit
352. Poikilothermia
353. Pulse Deficit
354. Poikilothermia
355. Pulse Deficit
356. Poikilothermia
357. Pulse Deficit
358. Poikilothermia
359. Pulse Deficit
360. Poikilothermia
361. Pulse Deficit
362. Poikilothermia
363. Pulse Deficit
364. Poikilothermia
365. Pulse Deficit
366. Poikilothermia
367. Pulse Deficit
368. Poikilothermia
369. Pulse Deficit
370. Poikilothermia
371. Pulse Deficit
372. Poikilothermia
373. Pulse Deficit
374. Poikilothermia
375. Pulse Deficit
376. Poikilothermia
377. Pulse Deficit
378. Poikilothermia
379. Pulse Deficit
380. Poikilothermia
381. Pulse Deficit
382. Poikilothermia
383. Pulse Deficit
384. Poikilothermia
385. Pulse Deficit
386. Poikilothermia
387. Pulse Deficit
388. Poikilothermia
389. Pulse Deficit
390. Poikilothermia
391. Pulse Deficit
392. Poikilothermia
393. Pulse Deficit
394. Poikilothermia
395. Pulse Deficit
396. Poikilothermia
397. Pulse Deficit
398. Poikilothermia
399. Pulse Deficit
400. Poikilothermia
401. Pulse Deficit
402. Poikilothermia
403. Pulse Deficit
404. Poikilothermia
405. Pulse Deficit
406. Poikilothermia
407. Pulse Deficit
408. Poikilothermia
409. Pulse Deficit
410. Poikilothermia
411. Pulse Deficit
412. Poikilothermia
413. Pulse Deficit
414. Poikilothermia
415. Pulse Deficit
416. Poikilothermia
417. Pulse Deficit
418. Poikilothermia
419. Pulse Deficit
420. Poikilothermia
421. Pulse Deficit
422. Poikilothermia
423. Pulse Deficit
424. Poikilothermia
425. Pulse Deficit
426. Poikilothermia
427. Pulse Deficit
428. Poikilothermia
429. Pulse Deficit
430. Poikilothermia
431. Pulse Deficit
432. Poikilothermia
433. Pulse Deficit
434. Poikilothermia
435. Pulse Deficit
436. Poikilothermia
437. Pulse Deficit
438. Poikilothermia
439. Pulse Deficit
440. Poikilothermia
441. Pulse Deficit
442. Poikilothermia
443. Pulse Deficit
444. Poikilothermia
445. Pulse Deficit
446. Poikilothermia
447. Pulse Deficit
448. Poikilothermia
449. Pulse Deficit
450. Poikilothermia
451. Pulse Deficit
452. Poikilothermia
453. Pulse Deficit
454. Poikilothermia
455. Pulse Deficit
456. Poikilothermia
457. Pulse Deficit
458. Poikilothermia
459. Pulse Deficit
460. Poikilothermia
461. Pulse Deficit
462. Poikilothermia
463. Pulse Deficit
464. Poikilothermia
465. Pulse Deficit
466. Poikilothermia
467. Pulse Deficit
468. Poikilothermia
469. Pulse Deficit
470. Poikilothermia
471. Pulse Deficit
472. Poikilothermia
473. Pulse Deficit
474. Poikilothermia
475. Pulse Deficit
476. Poikilothermia
477. Pulse Deficit
478. Poikilothermia
479. Pulse Deficit
480. Poikilothermia
481. Pulse Deficit
482. Poikilothermia
483. Pulse Deficit
484. Poikilothermia
485. Pulse Deficit
486. Poikilothermia
487. Pulse Deficit
488. Poikilothermia
489. Pulse Deficit
490. Poikilothermia
491. Pulse Deficit
492. Poikilothermia
493. Pulse Deficit
494. Poikilothermia
495. Pulse Deficit
496. Poikilothermia
497. Pulse Deficit
498. Poikilothermia
499. Pulse Deficit
500. Poikilothermia

50. A patient is referred for an arterial ligation for leg pain. The patient describes brown discoloration of the calves and pronounced pedal edema. Which of the following is most likely responsible for this lesion?

Points: 0/1

- a. Lymphatic obstruction
- b. Venous stasis
- c. Thoracic outlet syndrome
- d. Arterial ischemia

You answered: C
Correct answer: a, b

Feedback:

Venous discoloration of the calf is usually a sign of venous disease. Prominent pedal edema implies strong arterial flow to the lower extremity. The patient will most likely demonstrate normal arterial flow.

51. If significant disease is identified on the arterial duplex evaluation, but a minutes of exercise has little effect on the ankle pressures:

Points: 0/1

- a. Pelvic vein obstruction is perhaps present
- b. Lumbar disc herniation hypothesis should be considered
- c. Spinal stenosis is the most likely cause of the patient's complaint
- d. Venous insufficiency is the most likely cause of the patient's complaint

You answered: C
Correct answer: a, b

Feedback:

If significant disease is identified on the arterial evaluation, but exercise has little effect on the ankle pressures, collateral circulation is adequate to compensate for the arterial occlusion. Pelvic vein obstruction is a possible cause of venous insufficiency. Thus, lumbar disc herniation hypothesis is deemed by those patients that cannot walk. If, on the other hand, it is not possible, this is not the case.

52. A bilateral decrease in the femoral pulses can be related to:

Points: 0/1

- a. Pelvic overdrive
- b. Gut formation
- c. Occlusion of the deep femoral artery
- d. Occlusion of the popliteal artery

You answered: C
Correct answer: a, d

Feedback:

Bilateral occlusions refer to the compromised of normal blood in the same venous distribution. It most commonly occurs in the and most distal to the origin of the left circumflex artery. Because the artery is occluded proximal to the lobe infarction, both the left ventricular and the right ventricular ejection fractions are significantly reduced.

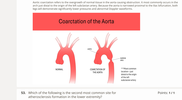

53. Which of the following is the second most common site for atherosclerosis formation in the lower extremity?

Points: 1/1

- a. Common iliac artery bifurcation
- b. Femoral bifurcation
- c. Distal PA trifurcation
- d. Proximal deep femoral artery bifurcation

You answered: D

Feedback:

The Deep Femoral artery is the most common site of atherosclerosis formation in the legs. The CFA bifurcation is the second most common site of atherosclerosis formation in the legs.

54. Which of the following are collagen disorders that have increased risk for arterial dissection?

Points: 0/1

- a. Ehlers-Danlos and Marfan Syndrome
- b. Paget Schlemann syndrome and Raynaud syndrome
- c. Ehlers-Danlos and Paget Schlemann syndrome
- d. Marfan syndrome and Paget Schlemann syndrome

You answered: D
Correct answer: a, c

Feedback:

Marfan syndrome and Ehlers-Danlos syndrome are collagen disorders that can lead to the formation of arterial aneurysm or dissection. Marfan syndrome is a group of similar defects that affects all the aortic and cardiac valves. Ehlers-Danlos syndrome is caused by a defect in the synthesis of collagen. Paget Schlemann syndrome is a rare disease that affects the bones and joints. It is a rheumatic disease that affects the bones and joints. Raynaud's syndrome is a vasospastic disorder.

55. Which of the following describes the correct protocol for evaluating suspected venous claudication?

Points: 0/1

- a. Duplex ultrasound evaluation the Pelvic Veins should be done only if an iliac vein stenosis is identified
- b. Use Doppler to evaluate the Iliac-Vein pressure area in one and with calves flexion
- c. Use Doppler to evaluate the Iliac-Vein pressure area in one and with calves flexion
- d. Evaluate the iliac pressures at rest and during plantar extension

You answered: C
Correct answer: b, d

Feedback:

Popliteal and peroneal venules the intermittent compression of the popliteal veins with flexing of the calf muscle. Arterial inflow is maintained by the calf muscle pump. The calf muscle pump is the key to venous return. The calf muscle pump is the key to venous return. Leg pain is the result of a venous insufficiency if the pain is caused by insufficient. PPG is the preferred method of evaluation. Duplex ultrasound evaluation is the preferred method.

56. If the distal femoral artery demonstrates a peak velocity of 3.2m/s, the waveform in the proximal tibial artery will most likely be _____.

Points: 0/1

- a. monophasic
- b. biphasic
- c. absent
- d. triphasic

You answered: A

Feedback:

Normal flow in the PT should be triphasic. A 3.0m/s PSV in the femoral artery indicates a hemodynamically significant stenosis. Distal to a significant stenosis, the waveform becomes damped. The proximal tibial artery waveform should be monophasic.

57. Thrombophlebitis therapy is used to treat:

Points: 1/1

- a. Chronic venous disease
- b. Chronic deep vein thrombosis
- c. Acute arterial occlusion caused by thrombosis
- d. Acute cerebrovascular

You answered: C

Feedback:

Thrombolytic agents are used in medicine to dissolve blood clots. Thrombolytic therapy is used to treat extensive acute DVT and acute arterial occlusion.

58. Which of the following can lead to an increase in the frequency shift detected in the common femoral artery?

Points: 1/1

- a. 80% stenosis of the superficial femoral artery
- b. Proximal superficial femoral artery occlusion
- c. Decreased pulse frequency
- d. 80% stenosis of the common femoral artery

You answered: D

Feedback:

Stenosis in the SFA will increase the Femoral frequency shift and calculated velocity. Changing higher frequency pulse will increase the frequency shift. Stenosis in the CFA will increase the frequency shift. Occlusion of the superficial femoral artery with collaterals is rare.

59. Which of the following provides the greatest risk for peripheral arterial disease?

Points: 0/1

- a. Excessive sweating
- b. Cigarette smoking
- c. Hypertriglyceridemia
- d. Polycythemia vera

You answered: A
Correct answer: b, c

Feedback:

Hypertriglyceridemia is high cholesterol which is a risk factor for arterial disease. Excessive eating or sweating can lead to dehydration. Dehydration increases blood viscosity and increases the risk of thrombosis. Polycythemia vera is a blood disease caused by excess of blood cells.

60. A patient presents complaining of pain and discoloration in their hands when they are cold, as seen in the image. The exposed area of the hands turned white, blue, and red. The affected area of the hands have been submerged in 40 degree water for 1 minute would include:

Points: 0/1

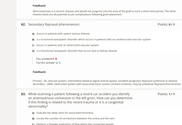

- a. Occluded peripheral with a prominent discrete count
- b. Footpad swellings
- c. Hemoptysis dermal swellings
- d. Raynaud's disease is characterized by Pain with fluctuate between low resistance and high resistance until hand warmed

You answered: D
Correct answer: a, d

Feedback:

The Grove PPG waveform has a sharp peak with a downstroke containing the dicrotic notch. In patients with Raynaud disease, the digital waveform changes from a normal to a damped waveform. The Raynaud's phenomenon is a condition in which the digital arteries become lower and lower in amplitude.

61. A patient presents for a follow up exam on a lower extremity femoral popliteal bi-ankle vein graft that was placed in the right leg 3 weeks ago. The patient's ankle brachial index is 0.9 on the right and 0.8 on the left. Which of the following is **not** an expected finding on the exam?

Points: 1/1

- a. Accelerometer narrowed by an aberrant suture
- b. Fibrinolysis around a valve removed
- c. Extension of atherosclerosis plaque into the graft
- d. Graft kinking

You answered: C

Feedback:

Atherosclerosis is a chronic disease and would not progress into the area of the graft in such a short time period. The other choices are common causes of lower extremity bypass graft failure.

62. Secondary Raynaud phenomenon:

Points: 0/1

- a. Occurs in patients with severe venous disease
- b. A connective tissue disorder which occurs in patients with an underlying vascular system
- c. Is a primary disease of the digital arteries
- d. A functional vasospastic disorder that occurs due to kidney disease

You answered: C
Correct answer: a, c

Feedback:

Primary: No vascular system, intermittent bilateral digital arterial spasm, accelerated progressive. Raynaud syndrome is disease of the digital arteries. Secondary Raynaud's phenomenon occurs in patients with an underlying vascular system disease.

63. While passing a patent following a severe car accident you detect an arteriovenous connection in the left groin. How can you determine if this finding is related to the lesion in question or it is a congenital abnormality?

Points: 1/1

- a. Evaluate the deep veins for associated thrombosis
- b. Locate the number of connections between the proxy and the vein
- c. Perform a Doppler evaluation of the distal veins the connected vessels
- d. Determine the location of the arteriovenous connection

You answered: B

Feedback:

A congenital malformation (AVM) will usually have multiple connections between the artery and the vein. An the hypothesis is correct, the patient will have a single connection. The presence of multiple connections between the artery and the vein suggests that the lesion is not congenital and is related to the patient, but they will be differentiated a congenital AVM from a traumatic AVF.

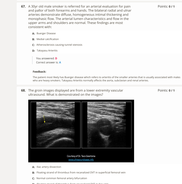

64. When Thrombin is injected into a pseudoaneurysm, the needle puncture site should be:

Points: 0/1

- a. Left alone
- b. Left in place for 24 hours
- c. Left in place of two days
- d. Treated as for hole that we as possible

You answered: A
Correct answer: b, d

Feedback:

After performing the procedure, the physician covers a 21-22g needle into the body of the pseudoaneurysm and confirms the location of the needle. Thrombin is injected a solution. Then the tract of the pseudoaneurysm is pressed distal from the needle puncture. Thrombin must be

Thoracic Outlet Syndrome

69. Which of the following symptoms is the most commonly seen with peripheral arterial disease? Points: 8/1-5

- Pitting edema
- Muscle pain/cramps
- Hair loss
- Pregnancy issues

You answered: **A**
Correct answer: **A**

Feedback

Claudication is defined as pain in muscles that subsides at rest. The pain only predisposes and injures/ischemia at the same level of exercise, so it will always occur exactly in the same place every time.

70. Which of the following describes a transcutaneous oximetry system of measurement? Points: 8/1-5

- The measurement is done in the lab, lower leg and thigh
- The measurement is done in the lab, 30 degrees Celsius to release oxygen
- A catheter reading is obtained first on the toes
- A video approximately 5 minutes to obtain a reading

You answered: **B**
Correct answer: **B**

Feedback

Transcutaneous oximetry determines capability of healing of a wound or specific site for the amputation. The sensor evaluates tissue capacity and transport of oxygen to tissues. Accordingly, the sensor is thermostatic that the skin will 30 degrees Celsius and oxygen escapes from the tissue to be measured by the sensor. It takes approximately 15-20 minutes to obtain a reading. System consists of a probe, a heating element, and a sensor. Probe is placed on the skin, heating element heats the skin to 30 degrees Celsius, high-tension (HT) is set to 7 kilovolts (kV) for healthy tissue, 10 kV for ischemic tissue.

71. Elevated erythrocyte sedimentation rate and C-reactive protein (CRP) are associated with which of the following? Points: 8/1-5

- Lower extremity ischemia
- Giant cell arteritis
- Aortic aneurysm
- Thoracoscoar dysplasia

You answered: **B**
Correct answer: **B**

Feedback

Giant cell arteritis is associated with elevated erythrocyte sedimentation rate and C-reactive protein (CRP) levels. These are both inflammatory markers associated with giant cell arteritis.

72. A patient presents with diminished pulses in the right radial and ulnar arteries. Which of the following could cause this symptom? Points: 1/1-5

- Left heart pulse and amplitude
- Right brachial artery stenosis
- Left superficial palmar and ulnar
- Left lateral palmar and venous

You answered: **B**

Feedback

Stenosis of the the brachial arteries leads to pulsatile pressure. The palmar arch is on the hand, distal to the radial and ulnar arteries. Stenosis of the brachial arteries causes diminished pulses in the radial and ulnar arteries. Stenosis of the brachial arteries causes diminished pulses in the radial and ulnar arteries.

73. Why would anyone want to cold increase symptoms of lower extremity arterial stenosis? Points: 8/1-5

- Increased resistance due to vasoconstriction and blood becomes less viscous with cold exposure
- Increased resistance due to vasoconstriction
- Increased resistance due to vasodilation
- Blood becomes less viscous with cold exposure

You answered: **C**
Correct answer: **A**

Feedback

Cold exposure can cause the smaller vessels via the beta2ferm to constrict which increases resistance to flow. This effect could be beneficial in patients with peripheral arterial disease.

74. What complication of Angioplasty is identified on the image? Points: 8/1-5

- Compartmental and arterial thrombosis
- AV fistula and superficial phlebitis
- Lymphedema/pain, AV fistula and DVT
- AV malformation

You answered: **B**
Correct answer: **B**

Feedback

The angiography procedure was performed on the right radial femoral artery. The image do not demonstrate that any, so the complication of the angioplasty procedure is not a compartmental and arterial thrombosis. Lymphedema/pain and AV malformation are not a possible complication. The image shows that there is a fistula and superficial phlebitis. The fistula is the most common complication that occurs in angiography procedures. The fistula is a connection between the artery and the vein. The fistula is a connection between the artery and the vein. The fistula is a connection between the artery and the vein. The fistula is a connection between the artery and the vein.

75. The common femoral artery velocity is 0.8 m/s and the proximal femoral artery demonstrates atherosclerotic formations causing an increase in the velocity to 2.1 m/s. This indicates what level of stenosis? Points: 1/1-5

- 25%
- 50%
- 75%
- 90-99%

You answered: **D**

Feedback

When the velocity between two extremity arterial segments doubles, this indicates at least a 50% stenosis. When the velocity increase between two extremity arterial segments quadruples, this indicates a 75% stenosis.

76. The common femoral artery velocity is 0.8 m/s and the proximal femoral artery demonstrates atherosclerotic formations causing an increase in the velocity to 2.1 m/s. This indicates what level of stenosis? Points: 1/1-5

- 25%
- 50%
- 75%
- 90-99%

You answered: **D**

Feedback

When the velocity between two extremity arterial segments doubles, this indicates at least a 50% stenosis. When the velocity increase between two extremity arterial segments quadruples, this indicates a 75% stenosis.

77. A patient presents with gore-tizen three days after percutaneous transluminal angioplasty procedure. The patient's pulse is 2+ on the left & 1+ on the right. The patient's blood pressure is 140/90 and the image on the right is taken. Which of the following is most likely? Points: 8/1-5

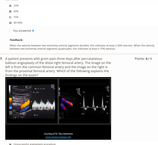

- Compartmental and arterial thrombosis
- AV fistula and superficial phlebitis
- Lymphedema/pain, AV fistula and DVT
- AV malformation

You answered: **B**
Correct answer: **B**

Feedback

The angiography procedure was performed on the left femoral artery. The images do not demonstrate that any, so the complication of the angioplasty procedure is not a compartmental and arterial thrombosis. Lymphedema/pain and AV malformation are not a possible complication. The image shows that there is a fistula and superficial phlebitis. The fistula is the most common complication that occurs in angiography procedures. The fistula is a connection between the artery and the vein. The fistula is a connection between the artery and the vein. The fistula is a connection between the artery and the vein. The fistula is a connection between the artery and the vein.

78. _____ uses a catheter with a rotating head to break up the plaque and suction capabilities to remove it from the artery. Points: 8/1-5

- An angioplasty procedure
- An atherectomy procedure
- A percutaneous transluminal angioplasty
- A calcaneoplasty procedure

You answered: **B**
Correct answer: **B**

Feedback

Atherectomy uses a catheter with a rotating head and suction capabilities to break up the plaque and remove it from the artery. Angioplasty uses a balloon angioplasty catheter to compress the atherosclerotic and expand the vessel lumen. An endoprosthesis is placed in the vessel lumen to keep it open. A percutaneous transluminal angioplasty is a procedure that uses a balloon catheter to compress the atherosclerotic and expand the vessel lumen.

79. If there is an acute occlusion of the proximal femoral artery, what will the Doppler waveform look like in the mid femoral artery? Points: 8/1-5

- Same with collateral formation
- Increase
- High resistance
- Absent

You answered: **D**
Correct answer: **D**

Feedback

There will be no flow in the mid femoral artery with an acute obstruction because there has not been time for collaterals to form.

80. Which of the following conditions would be treated with sympathectomy? Points: 8/1-5

- TO-RSD, carotid dancers
- Raynaud's disease
- Phlegmasia cerulea dolens
- Factor Ca11

You answered: **A**
Correct answer: **C**

Feedback

Sympathectomy is only used to break up a clot in patients with phlegmasia due to risk of arterial fibrinolysis. The benefits of the drug outweigh the risk of arterial fibrinolysis in patients with phlegmasia.

81. Which of the following correctly describes compartment syndrome? Points: 8/1-5

- Typically occurs below the diaphragm in the chest
- Most commonly occurs due to trauma
- Typically occurs below the diaphragm in the abdomen
- Caused by compression of tarsal ducts by fornix tissue

You answered: **B**
Correct answer: **B**

Feedback

Compartment syndrome is an emergency. Acc chronic compartment syndrome is an emergency. The acute onset of compartment syndrome affects the extremities and is usually associated with a traumatic/tear/ischemia. Acc chronic compartment syndrome affects the extremities and is usually associated with a traumatic/tear/ischemia. Acc chronic compartment syndrome affects the extremities and is usually associated with a traumatic/tear/ischemia.

82. Which of the following is associated with CREST syndrome? Points: 8/1-5

- Thoracic Outlet Syndrome
- Pulmonary arterial hypertension
- Acute anasarcoma
- Superficial phlebitis

You answered: **B**
Correct answer: **B**

Feedback

In contrast to Raynaud disease, Raynaud phenomenon presents concomitantly with CREST syndrome, in which tissue necrosis occurs secondary to ischemia. CREST syndrome is a form of systemic sclerosis characterized by calcinosis, Raynaud phenomenon, esophageal dysfunction, sclerodactyly, and telangiectasia.

83. Which of the following is an expected finding with a positive evaluation for thoracic outlet syndrome? Points: 8/1-5

- Antegrade blood pressure in the affected side with adduction
- Increased blood pressure in the affected side with adduction
- Increased resistance in the proximal subclavian artery on the affected side with adduction
- Increased resistance in the proximal subclavian artery on the affected side with abduction

You answered: **D**
Correct answer: **D**

Feedback

Due to compression of the distal subclavian with TOS, the flow in the proximal subclavian artery will demonstrate increased resistance with abduction. Increased resistance in the proximal subclavian artery on the affected side with adduction. Antegrade blood pressure in the affected side with adduction. The patient will not demonstrate this.

84. _____ refers to a collection of mucinous material within the adventitial wall layer of the arterial wall. Points: 8/1-5

- Adventitial cyst
- Arterial aneurysm
- Pseudoaneurysm
- Vulvar cyst

You answered: **D**
Correct answer: **D**

Feedback

Adventitial cyst is a collection of mucinous material within the adventitial wall layer of the affected vessel. This cyst commonly occurs in the popliteal artery and causes intermittent claudication. Arterial aneurysm is a focal dilation of an artery involving multiple layers and is often asymptomatic. Pseudoaneurysm is a hematoma that is partially contained by fibrous tissue. Vulvar cyst is a benign cyst that is not associated with peripheral vascular disease. Vulvar cyst is a benign cyst that is not associated with peripheral vascular disease. The adventitial cyst is the only choice that is not associated with peripheral vascular disease. The adventitial cyst is the only choice that is not associated with peripheral vascular disease.

85. A 32yr old male patient presents with persistent right calf pain with walking. The patient's pulse is 2+ on the left and 1+ on the right with the foot in plantar and flexed position. These findings are most suggestive of? Points: 1/1-5

- Popliteal entrapment
- Antegrade blood pressure
- Gastro of R. ischaemia
- Popliteal entrapment syndrome

You answered: **C**

Feedback

Positional entrapment is a diagnosis disorder that causes unknowing occurs with flexion of the foot. Relieve the vascular waveform with plantar flexion and with flexion of the foot. Popliteal entrapment syndrome.

86. What is the normal value for a transcutaneous oximetry exam? Points: 8/1-5

- 5-10mmHg
- 30mmHg
- 40mmHg
- 60mmHg

You answered: **C**
Correct answer: **B**

Feedback

Transcutaneous Oximetry determines capability of healing a wound or specific site for amputation. Evaluates oxygen supply and transport to tissues. Sensor is thermostatic that the skin will 30 degrees Celsius and oxygen escapes from the tissue to be measured the sensor itself. Using the surrounding tissues. Normal TCPO2 levels: 70-80mmHg. 30mmHg indicates tissue hypoxia.

87. If an abnormal transcutaneous oximetry reading is obtained, what should you do next? Points: 1/1-5

- Move the sensor locally
- Move the sensor proximally
- Let the patient rest for 30 minutes and do the exam
- Let the the nagel bed warming the patient's hand

You answered: **B**

Feedback

Transcutaneous oximetry is a test used to determine the necessary level of amputation. The amputation must be done at an area of tissue that will be healthy enough. If an abnormal reading is obtained, the sensor should be moved proximally. Move the sensor locally. Let the patient rest for 30 minutes and do the exam. Let the the nagel bed warming the patient's hand.

88. Which of the following correctly describes Buerger disease? Points: 1/1-5

- Commonly associated with aortic dissection
- Collagen disease also known as thromboangiitis obliterans
- Associated with uncontrolled diabetes
- Vitiligo commonly presents as multiple patches, well, oozing areas of the feet and ankles

You answered: **B**

Feedback

Buerger Disease/Thromboangiitis Obliterans is an ischemic disease of SMALL to MEDIUM size arteries caused by inflammatory lesions. Buerger Disease/Thromboangiitis Obliterans.

It is always associated with heavy smoking.

It is most common in men, age 20-35 years.

Collagen disease, such as lupus, is usually associated with Buerger disease.

The disease first affects the plantar or palmar arteries that cause ischemic ulcerations and gangrene of the extremities, digits, and occasionally the nose and ears.

Evaluation can be performed by Doppler and PPG techniques.

89. At the start of an arterial Doppler exam you identify monophasic flow in the left common femoral artery. What should you evaluate next to explain these findings? Points: 8/1-5

- Check the heart and start a PPG evaluation instead
- Check the heart and start a PPG evaluation instead
- Evaluate the aorta for a proximal aortic stenosis causing distal arterial obstruction
- Evaluate pelvical arteries looking for PTL such as the iliac and the ileal arteries

You answered: **D**
Correct answer: **D**

Feedback

Monophasic flow is an extremely sinisy indicate a proximal obstruction. If this CFA demonstrates monophasic flow, you should evaluate the vessels proximal to the CFA. Vessels.

90. What is the most common medication for an upper extremity arterial Doppler exam? Points: 1/1-5

- Nitroglycerin sublingual
- Prostacyclin Vasodilator gel/ointment
- Papaverin Pharmacoscar
- Prostat alcohol, lidocaine for atherosclerosis

You answered: **B**

Feedback

Vascular Doppler is a commonly needed procedure, hemodialysis grafts are common. These grafts are mature and have left over from the original surgery. Vascular Doppler is a commonly needed procedure, hemodialysis grafts are common. These grafts are mature and have left over from the original surgery.

91. Which of the following is an expected finding with Hypothenar Hammer Syndrome? Points: 8/1-5

- Negative Allen test
- Compartment syndrome
- Negative Tinel sign
- Slow urinary retention or emission

You answered: **B**
Correct answer: **B**

Feedback

Hypothenar Hammer Syndrome can be caused by repetitive compression or blunt trauma. The other arteries to commonly affected are the ulnar artery and the Tinel sign. Hypothenar Hammer Syndrome can be caused by repetitive compression or blunt trauma. The other arteries to commonly affected are the ulnar artery and the Tinel sign. Hypothenar Hammer Syndrome can be caused by repetitive compression or blunt trauma. The other arteries to commonly affected are the ulnar artery and the Tinel sign. Hypothenar Hammer Syndrome can be caused by repetitive compression or blunt trauma. The other arteries to commonly affected are the ulnar artery and the Tinel sign.

92. Which of the following is an expected finding with Hypothenar Hammer Syndrome? Points: 8/1-5

- Negative Allen test
- Compartment syndrome
- Negative Tinel sign
- Slow urinary retention or emission

You answered: **B**
Correct answer: **B**

Feedback

Hypothenar Hammer Syndrome can be caused by repetitive compression or blunt trauma. The other arteries to commonly affected are the ulnar artery and the Tinel sign. Hypothenar Hammer Syndrome can be caused by repetitive compression or blunt trauma. The other arteries to commonly affected are the ulnar artery and the Tinel sign. Hypothenar Hammer Syndrome can be caused by repetitive compression or blunt trauma. The other arteries to commonly affected are the ulnar artery and the Tinel sign. Hypothenar Hammer Syndrome can be caused by repetitive compression or blunt trauma. The other arteries to commonly affected are the ulnar artery and the Tinel sign.

93. Which of the following is an expected finding with Hypothenar Hammer Syndrome? Points: 8/1-5

- Negative Allen test
- Compartment syndrome
- Negative Tinel sign
- Slow urinary retention or emission

You answered: **B**
Correct answer: **B**

Feedback

Hypothenar Hammer Syndrome can be caused by repetitive compression or blunt trauma. The other arteries to commonly affected are the ulnar artery and the Tinel sign. Hypothenar Hammer Syndrome can be caused by repetitive compression or blunt trauma. The other arteries to commonly affected are the ulnar artery and the Tinel sign. Hypothenar Hammer Syndrome can be caused by repetitive compression or blunt trauma. The other arteries to commonly affected are the ulnar artery and the Tinel sign. Hypothenar Hammer Syndrome can be caused by repetitive compression or blunt trauma. The other arteries to commonly affected are the ulnar artery and the Tinel sign.

94. Where does the first pulse go when measuring the acceleration time of the left carotid artery? Points: 8/1-5

- Carotid artery
- Middle and left anterior arteries
- Left anterior arteries and middle arteries
- Internal thoracic artery and hypothenal artery

You answered: **B**
Correct answer: **C**

Feedback

Acceleration time is measured from the start of systole to the peak systolic velocity. Prolonged acceleration time can indicate hemodynamically significant stenosis. Prolonged acceleration time can indicate hemodynamically significant stenosis.

95. A 72yr old female presents for an upper extremity arterial Doppler exam. The patient's blood pressure is 140/90 and the image on the right demonstrates a pronounced hump of thickened vessel wall layer with calcified and noncalcified. These findings are most consistent with? Points: 1/1-5

- Takayasu disease
- Buerger disease
- Giant cell arteritis
- Vitiligo

You answered: **C**

Feedback

Giant cell arteritis is usually psoriatic in the cranial and extracephalic arteries, but can be seen in the extremities. It is usually seen in patients 70-80 years old. Giant cell arteritis is commonly in women. Giant cell arteritis is associated with polymyalgia rheumatica. Giant cell arteritis has relatively normal ESR and elevated C-reactive protein (CRP) levels. Biopsy is required for definitive diagnosis. Giant cell arteritis is associated with polymyalgia rheumatica. Giant cell arteritis has relatively normal ESR and elevated C-reactive protein (CRP) levels. Biopsy is required for definitive diagnosis. Giant cell arteritis is associated with polymyalgia rheumatica. Giant cell arteritis has relatively normal ESR and elevated C-reactive protein (CRP) levels. Biopsy is required for definitive diagnosis. Giant cell arteritis is associated with polymyalgia rheumatica. Giant cell arteritis has relatively normal ESR and elevated C-reactive protein (CRP) levels. Biopsy is required for definitive diagnosis.

96. Which of the following is an expected finding with a Doppler evaluation for acute dysfunction? Points: 8/1-5

- Common thrombosis
- Acute ischemia
- Acute ischemia
- Acute ischemia

You answered: **B**
Correct answer: **B**

Feedback

Acute ischemia is the most common cause of peripheral arterial aneurysms. A peripheral aneurysm is diagnosed when the vessel diameter exceeds 3cm.

97. Hypothenar hammer syndrome and thoracic outlet syndrome are both commonly associated with? Points: 1/1-5

- Compartment syndrome
- Nonstenotic disease
- Atherosclerotic disease
- Fibromuscular syndrome

You answered: **D**

Feedback

TOS involves compression of the vessels in the thoracic outlet. Hypothenar hammer syndrome involves compression of the ulnar artery. Legal pointers involves compression of the carotid arteries. Both compartment syndromes are affects the left lower extremity. Both compartment syndromes are affects the left lower extremity. Both compartment syndromes are affects the left lower extremity. Both compartment syndromes are affects the left lower extremity.

98. Where does the first pulse go when measuring the acceleration time of the left carotid artery? Points: 8/1-5

- Carotid artery
- Middle and left anterior arteries
- Left anterior arteries and middle arteries
- Internal thoracic artery and hypothenal artery

You answered: **B**
Correct answer: **C**

Feedback

Acceleration time is measured from the start of systole to the peak systolic velocity. Prolonged acceleration time can indicate hemodynamically significant stenosis. Prolonged acceleration time can indicate hemodynamically significant stenosis.

99. What is the external iliac artery is occluded, what vessels provide the collateral circulation? Points: 8/1-5

- Internal iliac artery
- Middle and left anterior arteries
- Left anterior arteries and middle arteries
- Internal thoracic artery and hypothenal artery

You answered: **A**
Correct answer: **A**

Feedback

The internal iliac artery provides collateral circulation, which includes circumflex iliac vessels, the obturator and inferior epigastric vessels. The iliac vessels provide collateral circulation to the iliac vessels.

100. Which of the following vessels are evaluated in a Doppler evaluation for erectile dysfunction? Points: 1/1-5

- Common thrombosis
- Acute ischemia
- Acute ischemia
- Acute ischemia

B: cavernous arteries and dorsal veins

C: cavernous veins and dorsal arteries

D: internal pudendal artery

> You answered: **B**

Feedback:

Doppler evaluation of erectile dysfunction includes assessment of the cavernous arteries and dorsal veins with Doppler pre- and post- medication injection (papaverine most common); Normally the PSV and EDV of the arteries will increase post injection but dorsal venous flow will remain unchanged; PSV >30cm/s considered normal

108. The displayed abnormality is most consistent with: Points: **1 / 1**

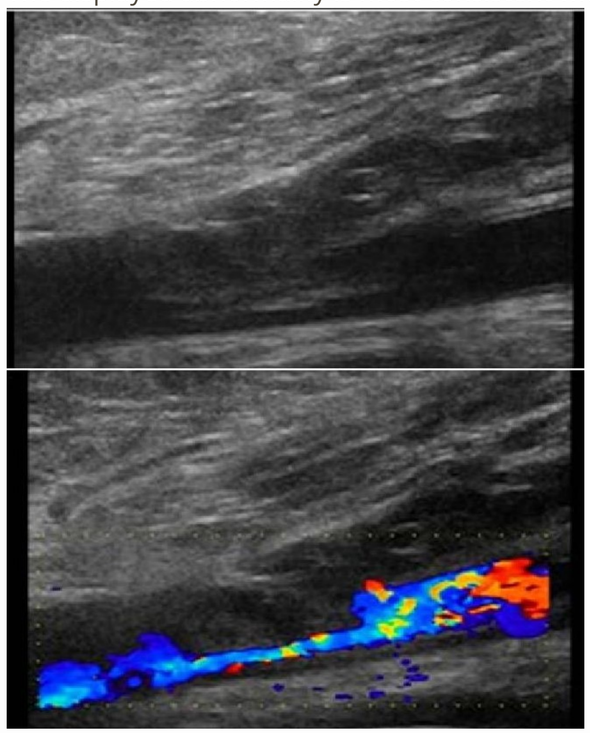

A: Soft plaque formation

B: Thrombus formation

C: Embolism formation

D: Tumor invasion

> You answered: **B**

Feedback:

Plaque forms in arterial vessels. An embolism is a piece of moving thrombus. Tumor invasion would disrupt the integrity of the venous wall layers. The image demonstrates thrombus adhered to the lining of the vessel wall.

Powered by ExamBuilder. Copyright ©2026