ARDMS VASC CTL: Extremity Venous Pathology(32%)

Start Review | Review Mode

ARDMS VASC CTL: Extremity Venous Pathology(32%)
Completed March 22, 2019 | Passing Score: 150 | Status: Failed

Exercise Answers in Blue | Exercise Answers in Red

1. The design and intended purpose of the Wallstent™ Points: 5 | +5

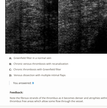

- Grafted filter that is a retrieval vein
- Filter placed therefore vein thrombosis
- Clinically thrombosis with Grafted filter
- Venous obstruction with multiple retrieval flaps

You answered: A

Feedback
Note the fibrous strands of thrombosis at a transverse deployed vein angiogram within the lumen. The anechoic areas are thrombus that could be seen on duplex ultrasound.

2. _____ cause primary varicose veins, while _____ cause secondary varicose veins. Points: 5 | +5

- Grafted filter venous pressure, Hypercoagulant state
- Incompetent valves, retrieval deep venous pressure
- Incompetent valves, incompetent perforators
- Grafted filter venous pressure, Retrieval venous pressure

You answered: B

Feedback
Primary varicose veins cause primary venous stasis, while decreased deep venous pressures in a diseased deep system (%of DVT or abnormal venous pressure measurements) cause secondary varicosity. Primary varicose veins are much more common than secondary.

3. The most common complication of lower extremity DVT is: Points: 0 | +5

- pulmonary embolism
- phlegmasia cerulea alba
- cellulitis lymphangitis
- phlegmasia cerulea dolens

You answered: D
Correct answer: C

Feedback
The presence of DVT damages venous valves (structure and function) and venous insufficiency is the most **common** sequelae and **most** chronic.

Pulmonary embolism is the most **critical** complication of DVT.

Phlegmasia alba dolens is an extensive iliofemoral thrombosis, usually due to stasis of venous blood with recent pelvic surgery, or pregnancy, in patients at a period ranging anywhere from 1 to 4 weeks after the event.

Phlegmasia cerulea dolens is an uncommon severe form of DVT which results from extensive thrombosis. Inclusion of the veins of the leg and pelvis, with the veins being distended by blood, leading to venous gangrene.

4. What is represented by the images from a lower extremity venous duplex? Points: 0 | +5

- Hepatic Fibrosis-Long Wellder Syndrome
- AV fistula
- Ischemic gain (pelvic-up-to-over Doppler, normal spectral waveform from the CFV
- pseudoaneurysm
- Arteriovenous fistula

You answered: A
Correct answer: B, D

Feedback
Note the pulsatility in the arterial waveform which is consistent with the presence of arterial inflow proximally in the vessel. This image is not suggestive of pseudoaneurysm or AV connection and lack of flow.

5. The image is a transverse view of the distal popliteal fossa. Which of the Points: 5 | +5

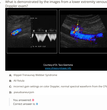

- AV fistula?
- Ischemic ischemia
- Tic-tac-toe(blue, just a stent-complex)
- Cryoprobe therapy

You answered: C

6. A patient presents for an upper extremity venous Doppler evaluation due to bilateral arm and face swelling. There are also superficial veins visible on the upper chest wall. These symptoms are most consistent with: Points: 0 | +5

- congenital heart failure and venous stasis
- occlusion thrombosis in the superior vena cava
- occlusion thrombosis in the internal jugular vein
- Paget's disease of the bone

You answered: B
Correct answer: C

Feedback
Classical venous, facial and bilateral arm swelling and indication of SVC thrombosis. SV thrombosis can be related to facial swelling but the arm would not be affected. CHF usually causes swelling in the legs.

7. A patient presents with a swollen left leg from hip to ankle and the right leg is normal. Points: 5 | +5

An lower extremity venous duplex exam shows compressible vessels and normal flow.

Doppler demonstrates normal flow in the right leg, but there is loss of phasicity of flow and decreased augmentation of the left common femoral vein and proximal femoral vein.

These findings are most suggestive of:

- left iliacvein stenosis or left external iliac vein thrombosis
- left iliac vein thrombosis with collateral flow
- contralateral iliac or femoral vein thrombosis
- left IVC thrombosis

You answered: A

Feedback
A left iliacvein stenosis could mimic this but rarely causes the swelling, left external iliac vein thrombosis could also cause unilateral swelling of the entire leg. IVC thrombosis or bilateral exterior iliac thrombosis would cause flow abnormalities in both extremities. Contralateral iliac or femoral vein thrombosis would not cause flow abnormalities in both extremities.

8. A patient presents with a seen ulcer located on the medial calf just above the medial malleolus. The ulcer is evaluated first as the most likely primary cause of the ulcer? Points: 0 | +5

- posterior tibial artery
- posterior accessory saphenous vein
- perforator vein
- anterior tibial artery

You answered: B
Correct answer: D

Feedback
Insufficiency of the perforator vein and posterior accessory saphenous vein are significantly less common compared to insufficiency of the great saphenous vein. Anterior tibial artery ischemia would be expected to cause ischemic ulcers on the lower leg, not just the ankle. A rare, young case does suggest posterior tibial artery ischemia causes ulcers.

9. Which of the following risk factors has the highest incidence of lower extremity thrombosis? Points: 5 | +5

- Recent hip surgery
- Polycythemia vera
- Diabetes
- Recent calf injury

You answered: D

Feedback
Diabetes (who have undergone any type of lower extremity surgery) are at the greatest risk (87%). The Chances of Venous Thromboembolism increase significantly after lower extremity surgery. Patients who have undergone lower extremity surgery are at risk for developing venous stasis and hypercoagulability. Patients who have undergone lower extremity surgery are at risk for developing venous stasis and hypercoagulability. Patients who have undergone lower extremity surgery are at risk for developing venous stasis and hypercoagulability.

10. Image of Deep Venous Thrombosis (DVT) Underneath the Inguinal Ligament Points: 0 | +5

- Normal aliasing
- Contrast therapy
- Jelly bean line
- compression sonology

You answered: B
Correct answer: D

Feedback
Contrast is a commonly treated with compression sonology. Normal or later aliasing and lifesaks changes that increase the Doppler Shift. Doppler Shift is caused by changing velocity of blood. Jelly bean lines (contrast therapy) would mimic the blood flow and would not be seen in a DVT.

11. Which of the following patients has the lowest risk of upper extremity venous thrombosis? Points: 0 | +5

- Central venous catheter for chemotherapy
- Hemophilia
- Recent shoulder surgery
- polycythemia vera

You answered: A
Correct answer: D

Feedback
Hemophilia (Factor VIII/Factor IX/Factor XI deficiency), central venous catheter (trauma), and recent surgery (transmission) will increase the risk of Deep Vein Thrombosis.

Hemophilia (deficiency in a coagulation factor) is a rare disease and would be a contraindication to anticoagulation.

12. The most common location of a Baker cyst is: Points: 5 | +5

- Medial sesamoid flexor
- Anterior popliteal space
- Medial popliteal fossa
- Sagittal cyst

You answered: C

Feedback
The most common location of a Baker cyst is in the medial popliteal fossa. Most are an incidental finding on a lower extremity exam.

13. Which of the following is an expected complication caused by a Baker cyst? Points: 0 | +5

- Aneurysm formation in the popliteal artery
- Venous stasis (due to popliteal vein venous compression)
- Thrombosis of the small saphenous vein due to vascular insufficiency
- Arteriovenous fistulas in the popliteal artery

You answered: B
Correct answer: C, D

Feedback
A Baker cyst can assist with swelling in the popliteal fossa. The exterior compression of the popliteal vein by the cyst can cause venous stasis and lower extremity swelling. Thrombosis of the small saphenous vein is not a common sequelae and is unlikely to affect the venous compression in the popliteal vessel.

14. Which of the following is a common reflection that causes skin discoloration in patients with venous insufficiency? Points: 5 | +5

- Staphylococcus epidermidis
- Lymphedema
- Lymph Nodes
- Staphylococcus aureus

You answered: A

Feedback
Staphylococcus is a common inflammatory skin disease. It is usually the secondary sequelae of chronic venous insufficiency with venous hypertension and causes discoloration of the ankle and calf.

15. If a patient is diagnosed with a pulmonary embolism, what should be the next step in their patient care? Points: 0 | +5

- ultrasound angiography
- V/Q Report
- Lung biopsy
- lower extremity venous Duplex exam

You answered: B
Correct answer: A, B

Feedback
If the patient has been diagnosed with PE, additional exams may or may not be required to locate the source of the embolism. Immediate V/Q Report findings should be administered.

16. Unilateral swelling of the lower extremity would be an expected venous finding with: Points: 5 | +5

- Pelvic Congestion Syndrome
- Thrombosis of the IVC
- Chronic kidney disease
- Left pulmonary DVT

You answered: B

Feedback
Bilateral swelling is associated with renal disease, CHF, and IVC thrombosis. Left pulmonary DVT would cause unilateral swelling of the left leg.

17. A patient presents for an exam due to a history of Lermanie's Syndrome. What structure should be evaluated for associated findings? Points: 0 | +5

- Deep veins of the lower extremity
- Deep veins of the upper extremity
- Superficial veins of the lower extremity
- Bilateral iliac/femoral/popliteal veins

You answered: B
Correct answer: C, D

Feedback
Lermanie Syndrome refers to thrombophlebitis of the jugular veins with endangerment infection, such as phlegmasia/mediastinitis. The most common sites affected are the superficial veins of the lower extremity and the iliac veins.

18. Which of the following describes abnormal lower extremity venous flow? Points: 0 | +5

- Augmentation increased because flow is pulsatile
- Augmentation increased because augmentation flow is pulsatile, flow reversal or flow stasis is not flow
- Augmentation increases because the lowest flow followed by flow reversal < 2.5 sec is lowest flow
- Augmentation increases because the lowest flow followed by flow reversal < 2.5 sec is lowest flow
- Augmentation increases because flow is pulsatile, flow reversal or flow stasis is not flow

You answered: C
Correct answer: D, E

Feedback
Normal flow is pulsatile with flow augmentation increased in response to exercise. Reflux is diagnosed when flow reversal lasts longer than 2.5 seconds. Flow stasis is not flow. Augmentation is increased when the lowest flow is followed by flow reversal lasts longer than 2.5 seconds. Flow is pulsatile in the normal leg.

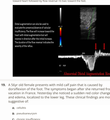

19. A 52yr old female presents with mild calf pain that is caused by dorsiflexion of the foot. The symptoms began after she returned from vacation in Florida. Yesterday she noticed a sudden red-color change in the calf and felt pain in the lower leg. These clinical findings are most suggestive of: Points: 0 | +5

- cellulitis
- Phlebitis
- pulmonary embolism
- acute DVT

You answered: D
Correct answer: C, D

Feedback
The patient received the problem after a vacation in Florida (long airplane ride) + venous stasis. The sudden onset of additional symptoms indicated phlegmasia cerulea dolens.

20. Bilateral leg and foot edema are present. What is the most common cause? Points: 5 | +5

- congestive heart failure
- Chronic insufficiency in the superficial system
- Chronic insufficiency in deep system
- Lymphedema

You answered: B

Feedback
Cardiac and systemic problems lead to bilateral swelling of the lower extremities, including the feet. Lymphedema can cause bilateral leg and foot swelling, but it is usually unilateral and less common than CHF. Chronic venous disease does not normally cause bilateral leg and foot edema, but it is a common cause.

21. What is the most common cause of upper extremity DVT in the normal ambulatory patient population? Points: 0 | +5

- Paget - Schrodder Syndrome
- shoulder surgery
- Central venous catheterization
- Unbalanced pressure

You answered: B
Correct answer: A, B

Feedback
The patient received the problem after a vacation in Florida (long airplane ride) + venous stasis. The sudden onset of additional symptoms indicated phlegmasia cerulea dolens.

22. _____ is the "gold standard" exam technique for diagnosis of venous disease in the lower extremities. Points: 5 | +5

- Venography
- Venogram
- Doppler Ultrasound
- MR Angiography (MRA)

You answered: C

Feedback
Doppler ultrasound has surpassed venography as the gold standard for evaluation of the veins in the lower extremities.

23. Which is demonstrated on this longitudinal image taken from the mid-thigh? Points: 5 | +5

- Chronic occlusive thrombosis of the femoral vein
- Left iliacvein stenosis/deep venous
- Occlusion of the superficial femoral vein
- Chronic occlusive thrombosis of the profunda femoral vein

You answered: D

Feedback
Chronic occlusive thrombosis of the profunda vein, the contralateral left iliac vein and complicated with chronic venous insufficiency. There is an error in the data set where the thrombus has contracted and hardened enough to produce pulsation shadowing, which is not typical.

24. Patients with lower extremity venous insufficiency may describe pain Points: 0 | +5

- Pain is relieved by walking
- Pain is relieved by lying down
- Pain is relieved by putting legs in dependent position
- Pain is relieved by elevating the legs

You answered: B

Feedback
The dependent position helps relieve or reduce the lower leg pain and swelling. Walking and elevating the legs would increase the pain and swelling. Lying down would not relieve the pain and swelling. Lying down helps relieve the pain and swelling because the venous flow rate, on already inflamed venous system. This can lead to increased pooling in the lower leg with swelling and pain.

25. Which of the following Doppler findings would indicate significant venous hypertension? Points: 0 | +5

- Phasic flow pattern in the lower extremity deep veins
- Increased spectral velocities with decreased phasicity velocities
- Phasic flow pattern in the lower extremity deep veins
- Continuous flow pattern in the lower extremity deep veins

You answered: D

Feedback
Continuous flow pattern is the deep veins of the lower extremity indicates increased venous pressure/venous hypertension. Phasic flow pattern is normal. Increased spectral velocities with decreased phasicity indicates a stenotic lesion.

Pulsatile flow means the flow has a pattern of movement in a single cardiac cycle. In the Doppler tracing, it means the waveform is phasic, and pulsatility is a measure of the waveform's fluctuation. Normal flow is pulsatile. Continuous flow pattern in the veins can be a sign of venous hypertension and is not normal.

27. A patient has a prior history of positive DVT and currently complains of the increasing appearance of small varicosities on the calf. Which statement is correct regarding the varicosities?

- This patient is suffering from secondary varicose vein formation
- The patient most likely has a recurrent acute DVT
- There is a high likely-ihood that this patient has a form of PAD
- There is a low likely-ihood in case in the patient flows causing varicose compression

Your answered: B
Correct answer: B

Feedback
Secondary varicosities form due to increased venous pressure within the superficial venous system.
Secondary varicosities form if there is an associated problem in the deep system, such as previous DVT

28. The images of the rack demonstrate which of the following?

- Acute DVT of the GS
- Acute DVT of the SSV
- Acute DVT of the GV
- Large main trunk varicose vein in CEAP

Your answered: A
Correct answer: A, B, C

Feedback
Color flow angiography with visibly hyperechoic debris within the lumen. The acute thrombosis in standing complaints observed of the GS, GV and SSV. Varicosities should not present as an engorged vein and the thrombus must be associated, disagree with chronic changes.

ANNAL Dr. Gianfranco Gianfranco

29. A patient presents for a lower extremity venous Doppler due to leg swelling and pain. Which of the following is the most likely-ihood seen among those findings on the venous Doppler exam, when should a venous Doppler be ordered?

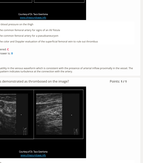

- perform a Valsalva maneuver on the flap
- perform a Valsalva maneuver on the right side of a left fistula
- compare the common femoral artery to a popliteal artery
- perform the calf and thigh evaluation of the superficial femoral vein to rule out thrombus

Your answered: C
Correct answer: D

Feedback
Note the proximity to the venous manifold which is consistent with the presence of arterial inflow proximally in the vessel. The venous vein needed to be evaluated distal to the anastomosis with the artery.

30. What vessel is demonstrated as thrombosed on the image?

- cystic vein
- cephalic vein
- short saphenous vein
- great saphenous vein

Your answered: D

Feedback
Note the large medial collateral on the image along with the location of the vein just beneath the subcutaneous fat and anterior to the Hunterian Canal. The lack of a corresponding artery also indicates a superficial vein.

31. Sclerotherapy

- is used to treat incompetent deep veins
- refers to the treatment of veins using a radiofrequency catheter
- refers to the treatment of deep venous reflux with compression stockings
- involves the injection of a sclerosing agent into varicosities

Your answered: D

Feedback
Sclerotherapy refers to the injection of a sclerosing agent that damages the vein and causes fibrosis to occur. Sclerotherapy is used to treat varicosities, reticular veins, and telangiectasia. Sclerotherapy agents are not inside the vessels leading to vessel wall injury and fibrosis.

32. Virchow's triad of symptoms includes blood stasis, vessel trauma and

- hypercoagulopathy
- venous hypertension
- anemia
- thrombotic vein

Your answered: B
Correct answer: A, B

Feedback
Virchow's Triad:
1. Stasis
2. Trauma
3. Hypercoagulopathy. Thrombotic vein refers to abnormally thickened blood.
Hypercoagulopathy is related to chronic vascular disease. Hypercoagulation and anemia would lead to thinner blood and less risk of thrombus formation.

33. A patient presents for a venous insufficiency expert, but is unable to perform the exam. Which of the following is the reason?

- Patient refuses the exam, the administrator's who place it is actually physical
- The PPG strength will be increased in amplitude
- The image on top is fine, but venous flow from is perform the heart rates.
- The segmental pressures will be falsely elevated

Your answered: A

Feedback
Rendering venous hypertension prevents the lumen demonstrate the reflux. If the patient is supine, a false negative exam could occur. Patients with venous insufficiency should be evaluated in the upright position. Segmental pressures in the lower extremities are not affected by the lower limb venous and by pressure which can mislead because the flow responsible to segmentation.

34. Which of the following are common risk factors for varicose vein formation?

- smoking and high cholesterol
- diabetes and smoking
- obesity and uncontrolled high cholesterol
- pregnancy and standing for long periods of time

Your answered: D
Correct answer: A, B

Feedback
Smoking, high cholesterol and diabetes are risk factors for atherosclerotic disease. Thus phlebitis syndrome, pregnancy, and standing for long periods of time.

35. The image demonstrates which of the following?

- Acute DVT
- Chronic DVT
- Superficial venous thrombosis

Your answered: D
Correct answer: A, C

Feedback
Note that engorgement with swelling and pigmentation, maximal within the lumen. The vein appears completely obstructed by acute thrombosis.

36. Which of the following causes of thrombosis is associated with varicose varicosities of the thoracic outlet?

- shoulder surgery
- collateral drainage impedimento to the chest
- crutwalking syndrome
- Paget - Schrodder Syndrome

Your answered: B
Correct answer: A, B

Feedback
Paget-Schrodder syndrome With spontaneous effort thrombosis
Most common cause of upper extremity DVT in the ambulatory patient population
Related to the presence of a cervical rib and thoracic outlet syndrome
Higher incidence in the dominant arm
Underlying collateral veins common cause of upper extremity thrombosis in patients that are of and require intravenous chemotherapy

37. A patient presents for a lower extremity venous Doppler to rule out DVT. Which of the following should be completely evaluated for the exam?

- femoral and popliteal veins
- great and short saphenous veins
- the calf and thigh superficial veins
- the calf and thigh deep veins and great saphenous veins

Your answered: D
Correct answer: A, B

Feedback
The deep veins should be evaluated for thrombosis before the whole exam is performed. The deep veins should also be evaluated for reflux along with the superficial veins.

38. A patient presents with a script for a "vascular ultrasound" due to a "swelling of the right upper extremity". What type of exam should be performed for this patient?

- arterial PPG of the toes
- segmental pressures on the lower extremities
- lower extremity venous Doppler exam
- upper extremity venous Doppler exam

Your answered: D

Feedback
Paget Schrodder syndrome refers to the formation of upper extremity DVT due to excessive traction. It is usually associated with thoracic outlet syndrome.

39. A transthoracic approach is used to prevent which of the following?

- CVP
- Cardiac tamponade
- Mitral valve prolapse
- Pulmonary hypertension

Your answered: B

Feedback
A Greenfield filter is inserted into the anterior portion of the IVC (below the level of the renal veins) to prevent any pulmonary embolism from reaching the lungs.

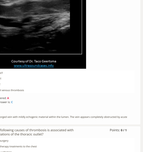

40. You perform a bilateral venous Doppler due to bilateral swelling and pain in the legs. Which of the following should be reported on your exam? Which of the following should be reported on your exam?

- Deep Venous Insufficiency is likely
- Deep Venous Insufficiency is ruled out
- Congenital Vein Valve is likely
- GS obstruction is suspected

Your answered: B
Correct answer: A, D

Feedback
Bilateral varicose are specifics from the vein, were contrast is provided which prove that affects from both. An TEE obstruction is suspected. Congenital vein valve is a rare condition and is not likely to be the cause of the patient's symptoms. Deep venous insufficiency is the common cause. Deep venous insufficiency is the most common cause.

41. The certification demonstrated on the image are most suggestive of which vascular abnormality?

- Acute superficial vein thrombosis
- Peripheral arterial disease
- Chronic venous insufficiency
- varicose vein aneurysm

Your answered: C

Feedback
Varicosities, hyperpigmentation and pitting edema of tissue due to increased fluid accumulation in the tissues. Peripheral edema is a sign of CVI. The venous system is unable to pump blood back to the heart, causing blood to pool in the lower limbs, which results in edema. Increased venous pressure causes fluid to leak into the surrounding tissues, causing swelling and discoloration. Varicosities are a sign of chronic venous insufficiency, not acute superficial vein thrombosis. Peripheral arterial disease does not cause varicosities. Varicose vein aneurysms are not a sign of CVI.

42. Significant venous disease in the right heart usually leads to

- congenital tricuspid atresia in the pulmonary vein
- cardiac pulsatility in the lower extremity veins
- pulmonary hypertension and right heart enlargement
- varicose flow in the central veins

Your answered: B

Feedback
Significant venous disease in the right heart usually leads to significant pulsatility in the lower extremities and portal veins. Significant veins disease can cause changes in the central veins flow.

- cystic fibrosis, Leukemia flow and varicose flow changes
- Acute Pyelonephritis - pulsatile flow changes

Cardiac Pulsatility

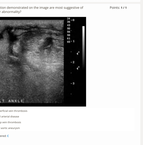

43. Which of the following will be administered to a patient with extensive DVT to cause lysis of the clot?

- Heparin
- Heparin or Coumadin
- Coumadin
- Streptokinase

Your answered: A
Correct answer: A, B

Feedback
Heparin, Coumadin and Warfarin are medicines that reduce the viscosity of Blood to prevent propagation of the clot but they have no clot lysing properties. Streptokinase and Urokinase are used to dissolve thrombus to cause clot lysis.

44. While scanning the popliteal artery, you notice a thrombus in the popliteal vein. Which vessels should be evaluated next for ascending propagation of the clot?

- VGS
- Distal femoral vein
- Common femoral vein
- common femoral vein

Your answered: C
Correct answer: A, B

Feedback
If a clot is identified in the popliteal vein, the distal femoral vein should be evaluated next for propagation of the thrombus.

45. A patient presents with gangrene of the foot and toes. The most likely cause of these symptoms is

- excessive deep and superficial vein thrombosis
- chronic occlusion of the popliteal artery
- coarctation of the aorta
- A VA aortic aneurysm with mural thrombus

Your answered: C
Correct answer: A, B

Feedback
Venous gangrene usually involves the foot and all toes, while arterial gangrene usually involves one or two toes.

46. Which of the following is related to the appearance of Rouleaux formation in the blood?

- Chronic ulcer pancreas
- neurovascular cutaneous flow
- Peripheral lymphoma
- DVT

Your answered: B
Correct answer: A, B

Feedback
Rouleaux is a red cells that may be very close and visible on 20 magnifying. The RBCs appear linear as or stacked in cells similar to coin stacks that are found which is called the Rouleaux Formation.

47. Which of the following does/does not/does/does symptoms of a patient with lymphedema?

- Pitting edema of swelling with severe pitting edema
- Unilateral non-pitting edema that is unaffected by leg elevation
- Unilateral non-pitting edema that is relieved by elevating the legs 30 minutes
- Edema not affected against gravity

Your answered: B
Correct answer: A, B

Feedback
Lymphedema does not normally cause skin discoloration, while acute DVT can be associated with warmth and redness. Lymphedema swelling and pitting edema. DVT causes swelling, which is not affected by leg elevation. The leg will remain edematous and swollen even when the patient lies down with the legs elevated.

Lymphedema

© 2007 Associate Medical Publishers of Texas
Www.AMPtexas.com

48. Lower extremity ulcers are most commonly caused by

- chronic venous disease
- chronic arterial disease
- chronic arterial disease
- neuromuscular cellulitis

Your answered: C
Correct answer: A, B

Feedback
Lower extremity ulcers are most commonly caused by chronic venous disease. CVAs.

49. Which of the following is a sonographic finding of acute DVT?

- Partial compressibility of the vein
- Venous insufficiency
- Engorged vein with increased echogenicity in the lumen
- Transmitted, compound and varied echogenicity of the wall

Your answered: D
Correct answer: A, C

Feedback
Acute thrombosis will demonstrate an echogenic material having a partially collapsed vein. Acute thrombus causes the vein to be partially compressible.

ANNAL Dr. Gianfranco Gianfranco

Courtesy of Dr. Tarsis Gianfranco

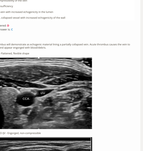

50. Which of the following correctly describes the effects of walking on the venous pressure in the lower extremity in a patient with venous insufficiency?

- Ischemic ulcers are painful and usually occur on the tips of the toes and on the heel of the foot
- Venous ulcers are painless and usually occur on the medial aspect of the lower leg
- Venous ulcers are associated with varicosities, edema, and hyperpigmentation
- Ischemic ulcers, Stasis ulcers and Diabetic ulcers are the three most common lower extremity ulcers
- Ischemic ulcers are associated with a cool, pale, and hairless lower extremity. The lower extremity may also be cyanotic or mottled. The lower extremity may also have a weak or absent pulse
- Venous ulcers are associated with a warm, edematous, and hyperpigmented lower extremity. The pulses are still strong, and there is no pain
- Diabetic ulcers are associated with a warm, edematous, and hyperpigmented lower extremity. The pulses are still strong, and there is no pain. Diabetic ulcers are associated with a "stocking" distribution of neuropathy. The lesions are commonly found on the tips of the toes and on the heel of the foot

51. Most lower extremity thrombosis begins in the Points: 1 / 1

- veins
- deep veins
- arterial veins
- lymph vessels
- Sentinel vein in the saphenous canal

You answered: C

Feedback

Most lower extremity thrombosis begins in the lymph vessels and progresses into the DVS and/or perforator veins.

52. A patient presents for a lower extremity venous Doppler exam due to a history of Klippel-Trenaunay. What vessel should you closely evaluate for retained findings? Points: 0 / 1

- Anterior tibial femoral vein
- Sapha Vein
- Posterior tibial femoral veins
- Gift Vein

You answered: B

Correct answer: A, B

Feedback

Key: Physician Syndrome refers to increased incidence of left DVT due to perinatal compression by RIGHT iliac artery.

53. When performing an upper extremity venous Doppler evaluation for thrombosis, what of the following veins should be evaluated on the exam? Points: 1 / 1

- deep, superficial, basilic and brachial veins
- subclavian, axillary, cephalic, basilic and brachial veins
- cephalic, basilic and brachial veins
- axillary, brachial and deep forearm veins

You answered: B

Feedback

When performing an upper extremity venous Doppler evaluation for thrombosis, the subclavian, axillary, cephalic, basilic and brachial veins should be evaluated for thrombosis. The deep forearm veins are not typically evaluated. Adding the cephalic and basilic veins ensures that the superficial veins are evaluated.

54. The most common location of valvular insufficiency is Points: 0 / 1

- great saphenous and common femoral vein junction
- soft tissue confluence
- ankle saphenous vein
- femoral and popliteal femoral vein junction

You answered: D

Correct answer: A

Feedback

The most common location of valvular insufficiency is at the GS junction of great saphenous and common femoral vein junction.

55. Which of the following is an expected clinical finding in a patient with a venous stasis ulcer? Points: 0 / 1

- 90-100 Unity
- Hard, well-defined medial malleolus
- Lower pain
- deep crater in the skin

You answered: A

Correct answer: B, D

Feedback

Venous ulcers are usually mildly painful, oozing, shallow ulcer located at the medial malleolus.

Arterial ulcers are usually painful, dry and crusty, deep ulcers located at the toes or heel.

Venous Ulcers	Arterial Ulcers
Mild pain	Severe pain
Shallow ulceration	Deep ulceration
Wet and oozing	Dry, scab formation
Typically found near medial malleolus	Typically found near lateral malleolus, heel and toes

56. Which of the following is a sign or symptom of chronic DVT? Points: 1 / 1

- Myositis
- Redness
- Positive Homan's Sign
- Anxiety Disorientation

You answered: D

Feedback

Hyperpigmentation refers to brawny discoloration of the distal 1/3 of the calf. It is caused by red blood cells and iron accumulating in the subcutaneous tissue. Hemosiderin is a brown pigment that results from the breakdown of red blood cells. It is a sign of chronic DVT. It is caused by an obstruction in the venous system causing venous stasis and hemosiderin deposition. Swelling, pain and redness are signs of acute DVT.

57. A patient presents for a lower extremity venous Doppler exam due to a history of Klippel - Trenaunay - Weber Syndrome. What are the expected findings? (Select all that apply) Points: 0 / 1

- extensive deep and DVT involvement of the superficial venous system
- absence of the deep veins in the leg with multiple dilated secondary phlebes
- extensive abnormalities of the arterial system causing venous outflow of the superficial venous system
- extensive lesions DVT causing venous outflow of the superficial venous system

You answered: B

Correct answer: A, B, C

Feedback

Klippel - Trenaunay - Weber Syndrome refers to congenital absence of the deep veins which causes numerous prominent superficial varicosities.

58. The most significant complication seen with DVT is Points: 0 / 1

- microvascular edema
- Cardiac Tamponade
- Pulmonary Edema
- Pulmonary embolism

You answered: D

Correct answer: D

Feedback

Pulmonary embolism is the most common complication of DVT and pulmonary embolism is the most significant complication of DVT. A pulmonary embolism occurs when a piece of thrombus breaks off and travels to the lungs. This occludes the blood vessel and causes a lung infarction. The patient may experience chest pain, shortness of breath, and hypoxemia. Death occurs if blood

59. You perform a bilateral venous Doppler due to bilateral swelling and pain in the legs. The patient has a history of Sickle Cell Anemia and Sickle Cell Trait. These findings are most consistent with Points: 1 / 1

- peripheral arterial disease
- sickle cell trait hypertension
- Deep Thrombosis Syndrome
- DT reduced blood
- Sickle Cell Anemia

You answered: D

Feedback

Sickle cell anemia is the most common anemia in the United States. It is caused by DNA mutation and results in hemoglobin S. Hemoglobin S causes red blood cells to become sickle shaped. Sickle cell trait means that one of the genes, HBS, inherited from each parent. Sickle cell trait does not have any symptoms.

60. During a color evaluation of the common femoral vein, the patient is asked to perform the Valsalva maneuver. The Valsalva maneuver is the CV changes to rest for approximately 5 seconds before returning to rest. The Valsalva maneuver is used to evaluate reduced Points: 0 / 1

- The CV flow remains unaffected
- Superficial venous insufficiency is present.
- There is deep fibrosis or stenosis DVT in the superficial femoral vein causing the venous occlusion is present.
- A significant reflux in the Superficial is present and should be further evaluated with PW or CW Doppler techniques

You answered: D

Correct answer: A, C

Feedback

CV physiology stress of the maneuver is considered normal in the superficial veins. It can, in fact, if the reversal is considered normal in the deep veins. It proceeds in greater of the reversal indicates significant venous reflux.

61. Which of the following are common symptoms of chronic venous disease? Points: 1 / 1

- microvascular pulsation
- sitting edema and **pronounced** or **great** toe
- Hyperpigmentation
- venous discoloration and sitting edema

You answered: D

Feedback

Hyperpigmentation and pronounced toe are signs of arterial disease. Varicosities, brawny discoloration and sitting edema are signs of chronic venous disease.

62. This is a great example of which of the following?

- Reflux Vein, and stagnation
- Venous pyogenic/ myogenic/ tone
- Time of venous segmentation
- Velocity of venous reflux

You answered: D

Feedback

The flow reversal is quantifying the time reflux is present following augmentation. 0.5 sec of reflux is normal in the superficial system and 1 sec of reflux is normal in the deep system.

63. A 65yr old female presents with left leg swelling for over one year. Upon exam, the patient has a brawny color of the left calf and ankle area. Venous pictures reveals an most suggestive of Points: 1 / 1

- Chronic Insufficiency
- Acute DVT
- Acute DVT
- Superficial Phlebitis

You answered: B

Feedback

Chronic swelling and brawny discoloration are characteristics of venous stasis. This is most commonly associated with chronic insufficiency. Acute DVT would result in pain swelling with a red discoloration.

64. Venous perforators with a diameter of _____ or greater will usually demonstrate reflux. Points: 1 / 1

- 4mm
- 6mm
- 3mm
- 4mm

You answered: D

Feedback

Venous perforators diameter is 3mm. Venous perforators with a diameter of 4mm or greater will usually demonstrate reflux.

65. Venous gangrene usually involves _____ while arterial gangrene usually involves _____. Points: 0 / 1

- toes, and toes
- all the toes and foot, just one or two toes
- just one or two toes, all the toes and foot
- the foot first toe toes, the toes but not the foot

You answered: D

Correct answer: A, B

Feedback

Venous gangrene usually involves the foot and all toes, while arterial gangrene usually involves one or two toes.

66. Warfarin is administered to a patient: Points: 0 / 1

- to increase platelet aggregation
- to prevent thrombus propagation
- to assist in the clot and recanalization
- to assist in arterial blood and recanalization

You answered: B

Feedback

Warfarin is administered to a patient to prevent thrombus propagation and reduce platelet aggregation. Streptokinase is used to assist in the clot and recanalization. Increased platelet aggregation would cause clot propagation.

67. How is Heparin administered to a patient with DVT? Points: 0 / 1

- orally
- intra-arterial
- intravenous
- subcutaneous injection

You answered: D

Correct answer: C, D

Feedback

DVT treatment can include 5-10 drips doses of intravenous Heparin to prevent clot extension. Such drips have dosing current thrombosis.

68. Which of the following causes flow reversal in venous perforators? Points: 0 / 1

- superficial thrombosis
- deep vein thrombosis
- compression stockings
- combination of superficial and deep thrombosis

You answered: B

Correct answer: A, B

Feedback

DVT is the deep system forms any remaining flow into areas of least pressure, the perforators. Flow starts the deep system through the perforators to the "storage" of superficial system.

69. _____ is a nonspecific sign of DVT. It is defined as pain experienced upon ankle dorsiflexion of the foot. Points: 1 / 1

- Homan Sign
- Russian Sign
- Allen Sign
- Hardman Sign

You answered: A

Feedback

Homan sign is a nonspecific sign of DVT. It is defined as pain experienced upon ankle dorsiflexion of the foot. Allen sign refers to the ability to palpate the radial artery after occluding the ulnar and radial arteries. The Allen Test is used to determine when arterial patency related to graft availability for revascularizing the radial artery.

70. An acute occlusive thrombosis is identified in the femoral vein in the adductor canal. Which of the following veins will demonstrate related thrombosis? Points: 1 / 1

- great saphenous
- SSAP saphenous
- common femoral
- proximal femoral vein

You answered: D

Feedback

When proceeding questions regarding GS propagation, consider what vessel is proximal to the GS. When proceeding questions regarding SSAP propagation, consider what vessel is distal to the SSAP. The SSAP is distal to the common femoral vein.

The SSAP is only factoral vein with cause crossing of blood in the popliteal vein. The GS empties into the popliteal vein and left unchanged. The SSAP empties into the femoral vein. The SSAP is the only factoral vein with cause crossing of blood in the popliteal vein. The GS empties into the popliteal vein and left unchanged. The SSAP empties into the femoral vein. The SSAP is the only factoral vein with cause crossing of blood in the popliteal vein.

71. A varicose vein is usually Points: 0 / 1

- a dilated lesser saphenous vein
- a dilated vessel of the perforator system
- a dilated tributary of the deep system
- a dilated tributary of the greater saphenous vein

You answered: D

Correct answer: A, D

Feedback

The greater saphenous vein and associated tributaries are most commonly associated with varicosity formation.

72. A patient in the ER has just been diagnosed with acute DVT of the femoral vein. What would be the physician's preferred treatment? Points: 0 / 1

- Insert a pulmonary into the popliteal vein and reposition the tumor.
- Insert a pulmonary into the femoral vein
- Begin the use of Heparin drips and continue for a follow up dose of 30 days
- Introduce 5 heparin with Heparin with 90 days of Warfarin medication once released from the hospital

You answered: B

Feedback

Acute DVT usually mostly treated with Heparin followed by Heparin 30 days of Warfarin/Coumadin therapy once the patient is out of the hospital.

73. Which of the following lower extremity vessels would most likely be occluded in a patient with Phlegmasia Alba Dolens? Points: 0 / 1

- common femoral artery
- saphenous vein only
- Common femoral artery and common femoral artery
- Second vein, deep vein, popliteal vein

You answered: D

Correct answer: A, B

Feedback

Phlegmasia Alba Dolens refers to a condition where all deep venous vessels are occluded in the extremity causing reduced venous outflow. The superficial veins are usually spared. The leg has a milky white appearance due to severe vasoconstriction secondary to reflex arterial spasm. The patient may experience severe pain, paresthesia, and paralysis.

74. The ideal field photo is most suggestive of what acute vascular Points: 0 / 1

- Phlegmasia Cerulea Dolens
- Gangrenous lesion
- Compact DVT
- Peripheral arterial disease
- Abscess DVT

You answered: B

Correct answer: A

Feedback

Phlegmasia Cerulea Dolens is a condition in the subcutaneous tissue. This is most commonly associated with Acute DVT. Peripheral arterial disease is a chronic, bilateral, CVI or diabetic DVT and usually causes DT presence.

75. A patient presents 5 days after left leg surgery for a DVT evaluation. There is severe edema from the hip to the ankle and the leg has a mild cyanotic appearance. The patient has a history of Sickle Cell Anemia. Venous flow through the left veins. The great saphenous vein is also occluded by thrombus. What is the diagnosis for this condition? Points: 0 / 1

- Phlegmasia Alba Dolens
- Deep venous occlusion
- Iliac Crest syndrome
- Phlegmasia Alba Dolens

You answered: D

Correct answer: A, B

Feedback

Phlegmasia Alba Dolens refers to extreme DVT, including deep system and superficial system. Arterial inflow is significantly reduced causing severe edema and cyanotic appearance. Arterial spasm is also present causing pain and paresthesia. Sickle cell anemia is a contributing factor. Contributing factor refers to conditions that increase the risk of DVT. Iliac Crest syndrome refers to a condition where the iliac crest compresses the common iliac artery. This causes DT presence. Phlegmasia Alba Dolens refers to extreme DVT, including deep system and superficial system. Arterial inflow is significantly reduced causing severe edema and cyanotic appearance. Arterial spasm is also present causing pain and paresthesia. Sickle cell anemia is a contributing factor. Contributing factor refers to conditions that increase the risk of DVT. Iliac Crest syndrome refers to a condition where the iliac crest compresses the common iliac artery. This causes DT presence. Phlegmasia Alba Dolens refers to extreme DVT, including deep system and superficial system. Arterial inflow is significantly reduced causing severe edema and cyanotic appearance. Arterial spasm is also present causing pain and paresthesia. Sickle cell anemia is a contributing factor. Contributing factor refers to conditions that increase the risk of DVT. Iliac Crest syndrome refers to a condition where the iliac crest compresses the common iliac artery. This causes DT presence.

76. Which of the following describes chronic lower extremity DVT? Points: 0 / 1

- changes are early
- Exaggerated tolerance presently
- Hyperpigmentation is present
- pronounced Rouleaux

You answered: D

Correct answer: A, B

Feedback

Chronic thrombosis formation can cause the vein walls to appear thickened and enlarged. The wall changes demonstrate the pronounced rouleaux is responsible. It can also lead to partial compressibility of the vein and continuous flow in the vessel thus of hyperpigmentation.

77. If greater saphenous venous flow velocity is approximately 20cm/s and the patient has varicosities, what vessel should be evaluated for a cause for the flow abnormality? Points: 1 / 1

- common femoral vein
- Gift Vein
- SSAP saphenous vein
- femoral and popliteal vein

You answered: D

Feedback

Venous pathology normally result from flow from superficial system into the deep system. If the flow reversal of the high velocity flow has not occurred thrombosis, the response of flow is the GS will be increased to flow go to enter the common femoral vein. This is known as the Compensatory Hypertrophy. Compensatory Hypertrophy is the response of

78. Which of the following is a cause for deep venous ATN? Points: 0 / 1

- Aortic coarctation
- Ischemic Vascular Spasm
- Chiari Primary Motion Syndrome
- Diffuse atherosclerotic disease

You answered: B

Correct answer: B

Venous ATPs are blocked due to increased venous stretch that causes fluid to leak into interstitial spaces between tissues. Related: Venous hypertension causes venous insufficiency.

79. What is the most common lower extremity venous disorder? Points: 6 | 5

- Deep Thrombosis
- Venous insufficiency
- Lymphoedema
- DVT

Your answered: B
Correct answer: B

Feedback

Venous insufficiency is the most common lower extremity venous disorder.

80. Proximal to a DVT in the femoral vein, the flow appears very slow and stable on US imaging. The vein blocks with Doppler Small up or slanted in US. What is this phenomenon called?

- Phlegmasia Cerulea Dolens
- Ischemic Ischemia
- Thrombosis Extension
- Venous Stasis

Your answered: D

Feedback

Venous stasis is the superficial femoral vein, the flow appears very slow and stable on US imaging. The vein blocks with Doppler Small up or slanted in US. This phenomenon is called Venous Stasis.

Venous Stasis Appearance in Duplex Ultrasound Imaging

81. Which of the following is the most common cause of venous ulcers occur formation on the distal medial calf? Points: 5 | 5

- Venous insufficiency in the deep venous system in the presence of calf vein
- Insufficiency in the perforator high pressure and the great saphenous vein
- Insufficiency in the perforator perforators and the posterior arch vein
- Insufficiency in the deep high pressure and the great saphenous vein

Your answered: A

Feedback

Insufficiency in the perforator (that perforators and the posterior arch vein most commonly leads to venous stasis and formation on the medial calf.

82. A thrombosis is identified in the soleal veins of the calf. The thrombus will propagate into what calf veins first? Points: 8 | 5

- anterior tibial and peroneal
- posterior tibial and anterior tibial
- posterior tibial
- great saphenous

Your answered: B
Correct answer: B, A

Feedback

The Basal vein which ID origin are not capable of demonstrating Reed flow characteristics. Venous valve movement may be uncertain. ID Vein Flow Direction Not Easily Identified.

84. Which of the following changes in flow can be seen with a Baker cyst? Points: 5 | 5

- continuous flow in the popliteal vein
- pulsatile flow in the popliteal vein
- pulsatile flow in the superficial femoral vein
- pulsatile flow in the popliteal vein

Your answered: B

Feedback

A Baker cyst can cause pain and swelling in the popliteal fossa. The extrinsic compression of the popliteal vein by the cyst can lead to a continuous flow pattern, blood stasis and DVT formation. The arterial walls are muscular and can protect the effects of external compression of the popliteal vein.

85. Lymphoedema is commonly related to: Points: 8 | 5

- cardiac symptoms
- a history of unilateral lifting or cancer
- bilateral swelling
- unilateral arterial disease

Your answered: B
Correct answer: A, B

Feedback

Lymphoedema occurs due to obstructed lymphatic system. It can be caused by many things, but is commonly seen with infectious injury, trauma or cancer that affects the lymphatic system. Radiation therapy or removal of lymph nodes related to cancer treatment is commonly seen.

86. Which of the following cardiac abnormalities will have an effect on venous return and cause venous stasis and secondary? Points: 5 | 5

- significant tricuspid regurgitation
- severe tricuspid stenosis
- prolonged ventricular contractions
- congenital heart failure

Your answered: C

Feedback

Prolonged ventricular contractions are a type of cardiac arrhythmia. A PVC will cause smaller stroke contractions before a normal contraction occurs. The diastolic filling time will be affected and the ventricle will not fill to its normal capacity. The atrial critical load is a buildup of blood in the RV. When the RV has ceased to dilate and impinged with blood, the cardiac pacemaking cells will be unable to pump. This is known as the critical load. Effect.

87. A venous insufficiency exam is performed for a patient with multiple varicosities. The patient has a history of DVT and venous ulcers. The insufficiency present in the great saphenous vein. Which of the following is the most likely cause of the insufficiency? Points: 5 | 5

- Venous insufficiency is normal in the superficial veins when varicosities are present
- This multiple varicosities are primary and secondary varicosities.
- This multiple varicosities are secondary varicosities.

Your answered: B

Feedback

Varicosities with superficial venous insufficiency related to deep venous system disease = secondary varicosities.

Varicosities with incompetent veins causing superficial venous insufficiency are normal deep system = primary varicosities.

89. What is the most accurate sonographic indicator for the presence of SVT? Points: 5 | 5

- Non-obstructive flood with Color Doppler
- Vein wall thickening
- Loss of augmentation response
- Non-obstructive flood with PW Doppler

Your answered: D

Feedback

The most accurate sonographic indicator for the presence of SVT is non-compressibility of the vein.

90. Which of the following is related to chronic DVT? Points: 8 | 5

- Swelling and erythema
- Pus excretion
- Skin ulceration
- Collateral non-compressible vein

Your answered: D
Correct answer: C, D

Feedback

A clot in the superior venous system can break loose and travel to the lungs. The vessel veins drain into IVC. The portal venous system drains into the liver and then into the IVC. Clots in the portal system can travel to the liver causing hepatic ischemia. Accordingly to the venous system clots drain south of the kidneys the biggest or smallest vessel drains south and travels.

91. Which of the following statements is true regarding a partial venous obstruction? Points: 8 | 5

- May cause continuous flow
- Also causes phasic flow
- Usually results in significant flow reversal during Valsalva maneuver
- May cause increased stasis of the vein with distal augmentation

Your answered: A
Correct answer: A, C

Feedback

Partial DVT will also impair the flexibility of the venous wall causing a more continuous/less phasic flow pattern. Insufficiency is present in the distal limb. The increased stasis of a partial obstruction information related to the degree of a partial.

Normal Venous Flow Pattern

92. A patient presents with intermittent left lower leg swelling for several months. The popliteal vein demonstrates a collapsed appearance with the proximal augmentation. These findings are most consistent with: Points: 8 | 5

- acute thrombosis
- chronic popliteal DVT
- varicosities of the popliteal vein
- proximal venous stenosis

Your answered: B

Feedback

Chronic DVT will demonstrate a collapsed or irregular vessel filling and blunting the vein wall. The fibrous scarring limits the ability of the vein leading to a venous collapsed appearance. Acute femoral DVT would cause a distended popliteal vein.

93. A patient presents with bilateral distention of the internal jugular veins and pink swelling. The lower extremities are normal on physical examination. These findings are most suggestive of: Points: 5 | 5

- Budd-Chiari Syndrome
- SVC Syndrome
- Subclavian vein syndrome
- Inferior vena cava syndrome

Your answered: B

Feedback

Swelling of the face typically lasts not occur with venous disease hydrophilic or cardiac disease, pits.

94. Which of the following carries an increased risk of developing varicose veins? Points: 5 | 5

- Prolonged standing jobs
- Sharing a temperature stockings
- Doing weight lifting exercises for long periods of time
- Wearing flat shoes instead of high heels

Your answered: A

Feedback

Extra pressure on the vein will increase the risk of developing varicose veins. Sharing, hiking, pregnancy and obesity also increase the risk. The other three choices would reduce the risk of developing varicose veins.

97. A clot in the gastrocnemius veins will first propagate into what veins? Points: 8 | 5

- popliteal vein
- deep femoral vein
- anterior tibial veins
- peroneal veins

Your answered: D
Correct answer: A, B

Feedback

Venous ATP valves impede the flow of venous blood causing a more continuous/less phasic flow pattern. Insufficiency is present in the distal limb. The increased stasis of a partial information related to the degree of a partial.

98. Which of the following is not an expected finding related to the phlebitis displayed on this image? Points: 8 | 5



- Arterial pulses are not seen
- Spontaneous flow in the deep great saphenous vein
- Venous valve incompetence
- venous wall is not soft

Your answered: C
Correct answer: A, B

Feedback

Venous ATP valves impede the flow of venous blood causing a more continuous/less phasic flow pattern. Insufficiency is present in the distal limb. The increased stasis of a partial information related to the degree of a partial. Venous valve movement may be uncertain. Arterial pulses are not seen. Spontaneous flow in the deep great saphenous vein. Venous valve incompetence. Venous wall is not soft. Blue Phlegmasia Cerulea Dolens. Phlegmasia Cerulea Dolens. Phlegmasia Cerulea Dolens.

[redacted]