ARDMS VASC CTL: Physiologic Exams 12%

Completed March 23, 2020 | Scoring Score: 100 | Status: Passed

ARDMS VASC CTL: Physiologic Exams 12%
Completed March 23, 2020 | Scoring Score: 100 | Status: Passed

Correct Answers in Blue | Incorrect Answers in Red

1. Why should a segmental pressure exam be performed with the patient supine? — Points: 1 / 1

- To increase the pressure in the venous system and reduce the pressure in the arterial system
- To increase the pressure in the arterial system and reduce the pressure in the venous system
- To eliminate the influence of hydrostatic pressure on the Doppler waveform
- To eliminate the influence of hydrostatic pressure on the ankle pressure

You answered: B

Correct answer: B, C

Feedback

Hydrostatic pressure can cause an overestimation of pressures in the ankles. Segmental pressure evaluations should be performed with the patient supine.

2. The following pressures were obtained in a patient with left claudication. What are the ABI values for both legs? — Points: 1 / 1

Left PT=90mmHg, Left DP=70mmHg, Left CT=90mmHg, Thigh 140mmHg, Brachial 130mmHg
Left PT=90mmHg, DP=70mmHg, Left CT=90mmHg, Thigh 130mmHg, Brachial 130mmHg

- R=.69, L=0.69
- R=.77, L=0.69
- R=.77, L=0.77
- R=.69, L=0.77

You answered: A

Correct answer: A

Feedback

Right: Calculating Ankle/arm: 90/130=.69, Left: 90/130=.69

You should use the complicated multi-problem on the registry exam. The most important part of any calculation is to know how to set up the calculation. The ratio of ankle pressure is divided by the highest of the two pressures in the calculation.

3. The pre and post exercise pressure information displayed from the treadmill exercise test is the following:

Exercise Pressure Measurement

Test	1	2	3	4	5	6	7	8	9	10
R Ankle PPG	140	135	130	125	120	115	110	105	100	95
L Ankle PPG	140	135	130	125	120	115	110	105	100	95
Brachial	130	130	130	130	130	130	130	130	130	130

- Triple level claudication
- Multiple level stenosis
- Normal ankle pressures
- Normal walk

You answered: D

Correct answer: A, B

Feedback

Single level Aortoiliac stenosis causes a normal 2-3 minutes post exercise. Multi-level stenosis causes a prolonged recovery time.

4. Which of the following describes the expected change in the PVR tracing (or an immediate post exercise evaluation of a patient after a treadmill exercise test) in a hemodynamic significant stenosis? — Points: 1 / 1

- Increased amplitude by >10%
- Rise of the dicrotic notch
- Increased amplitude by 10%
- Decreased amplitude by 10%

You answered: C

Feedback

Hemodynamic changes from an extremity should be high amplitude with a dicrotic notch. If the revascularization was a success, the amplitude of the waveform should have increased at least 10% compared to the amplitude of the pre exercise.

5. A diabetic patient presents for a segmental pressure exam. The patient complains of an injury to his big toe that wasn't seen to heal and has been open for over 3 weeks. The digital pressure in the affected toe is much less than the _____.

- DP/Brachial
- DP/Ankle
- CT/Brachial
- CT/Ankle

You answered: C

Feedback

The digital cuff is the cuff that is placed over the toenail being evaluated and only compares with brachial. Ankle cuffs are not used. The pressure in a given cuff should be approximately equal to the pressure in the brachial artery. Digital pressures should be at least 30mmHg or greater than the ankle pressure. The patient should not be limping during cuff placement. Ischemia may cause a decreased pressure in the digital cuff. The patient should not be limping during cuff placement. Ischemia may cause a decreased pressure in the digital cuff. Ischemia causes a decreased pressure in the digital cuff. Toe pressures are usually lower than ankle pressures.

6. Which of the following correctly describes cuff placement for a segmental pressure exam? — Points: 1 / 1

- Place the proximal cuff at the ankle and the distal cuff at the knee
- The proximal edge of the cuff should always cover at least a 2 inch area of the extremity
- The width of the cuff should be at least 20% larger than the girth of the limb segment
- Cuffs should be placed straight around the limb, rather than angled to the rest of the limb

You answered: C

Correct answer: C

Feedback

The width of the cuff should be placed over the area being evaluated and also compliance with these rules and tolerance. The proximal edge of the cuff should be approximately 2 inch above the proximal edge of the area being evaluated. The width of the cuff should be at least 20% larger than the girth of the limb segment. The patient should not be limping during cuff placement. Applying the bladder over the area being evaluated. Cuffs should be placed straight around the limb, rather than angled to the rest of the limb. Cuffs should be wrapped in the correct direction.

7. A patient complains of left arm numbness and pain that increases in intensity when the left arm is placed in a dependent position. The patient demonstrates a 10% decrease in the distal pulse volume. The PPG exam demonstrates additional decrease in digital flow with the arm in the dependent position. What is the most likely diagnosis? — Points: 1 / 1

- Thoracic Outlet Syndrome
- Pectoralis Minor Syndrome
- Danger Disease
- Secondary Raynaud Phenomenon

You answered: B

Correct answer: A, D

Feedback

Changes in flow patterns in the hand due to the application of external arterial occlusion are a characteristic sign of Raynaud phenomenon. Thoracic outlet syndrome and pectoralis minor syndrome are both characteristic of a decrease in distal pulse volume with the arm in the dependent position. Danger disease is a term used to describe the occurrence of a pulse in the radial artery when the ulnar artery is occluded.

8. When performing a PVR exam of the lower extremity arteries, how are the waveforms obtained? — Points: 1 / 1

- Starting at the ankle or the leg, proceed up through the right thigh before repeating the process with the left leg
- Starting at the right leg and moving toward the right ankle and then proceed to the left leg
- Starting at both ankles and moving up through the cuffs on both legs simultaneously
- Starting at both ankles and moving up through the cuffs on both legs simultaneously

You answered: D

Correct answer: D

Feedback

A segmental pressure exam is performed in one leg at a time, while a PVR exam is performed on both legs simultaneously. Digital pressures are obtained at the ankle and the toe. Cuffs are placed on the thigh, calf and forearm. Start from the thigh down to the ankle.

9. If the blood pressure in the ankle is obtained with the patient's legs in the dependent position: — Points: 1 / 1

- Its pressure will be underestimated
- It will be the same as if the patient is evaluated in the supine position
- Its pressure will be falsely elevated
- Its ankle and metatarsal bone pressure will be the same as if the patient is evaluated in the supine position

You answered: C

Correct answer: C

Feedback

If the blood pressure in the ankle is obtained with the patient's legs in the dependent position, the pressure will be falsely elevated due to the hydrostatic pressure. Hydrostatic pressure causes an increase in pressure in the ankle and metatarsal bone.

10. An asymptomatic patient demonstrates a normal left ABI, but the left tibial artery demonstrates a monophasic waveform with short systolic and rapid deceleration. What is the most likely cause for this finding? — Points: 1 / 1

- Calcification on high or distinct lines within the vessel
- Filter settings are too low to detect dicrotic flow reversal
- The patient should be evaluated for popliteal entrapment
- Raynaud syndrome

You answered: C

Correct answer: A, B

Feedback

Calcification on high or distinct lines within the vessel causes artifacts and prevents measurements of the vessel. Filter settings are too low to detect dicrotic flow reversal. Popliteal entrapment should be ordered if a patient demonstrates a normal ABI, digital flow and pressures should be obtained to verify the presence of a popliteal entrapment. Raynaud syndrome causes a decreased digital flow and digital pressures but is not typically affecting lower extremity arteries.

11. Which of the following is **NOT** normally performed after the injection of papaverine into the corpora cavernosa in the shaft of the penis: — Points: 1 / 1

- Measure the diameter of the cavernous arteries
- Measure the end diastolic velocity
- Image the cavernous arteries and measure arterial velocities at 5, 10 minutes post injection
- Measure the penile circumference at around the shaft of the penis

You answered: D

Feedback

Vascular Imaging Lab Protocol Doppler exam:
- Obtain baseline samples of the left cavernous arteries and veins in the penis.
- Measure systolic and end-diastolic velocities of the left cavernous arteries and the cavernous veins.
- Measure the diameter of the cavernous arteries.
- Image the cavernous arteries and measure arterial velocities at 5 and 10 minutes post injection.
- Image the cavernous veins and measure venous velocities at 5 and 10 minutes post injection.

The 5 & 10 minutes post injection images are taken to assess the flow into the cavernosa.

12. Abnormal results for a penile Doppler evaluation that suggest cavernosal vascular _____ _____ _____ _____ systolic flow velocity and a _____ _____ _____ _____ end diastolic flow velocity are: — Points: 1 / 1

- >30cm/s, >30cm/s
- >30cm/s, <10cm/s
- <10cm/s, >30cm/s
- <10cm/s, <10cm/s

You answered: C

Correct answer: A, B

Feedback

Abnormal results for a penile Doppler evaluation that suggest cavernosal vascular insufficiency include: >30cm/s peak systolic flow velocity and a peak pressure >30mmHg.

13. When a patient performs exercise on a treadmill what will be the normal change in arterial flow in the leg? — Points: 1 / 1

- Increased blood velocity
- Increased blood volume
- Increased vasoplegia from D-dimers
- Increased vasoplegia from L-dimers

You answered: B

Correct answer: A, C

Feedback

When the patient exercises, the leg muscles require more blood flow for proper operation. The metabolic waste drop in the ankle and the blood velocity increases in the leg.

14. The difference in systolic pressure between two adjacent levels in the same leg should be no more than _____mmHg. — Points: 1 / 1

- 10
- 20
- 30
- 40

You answered: A

Correct answer: B, D

Feedback

A drop in pressure of 30mmHg or more between segments indicates disease between the two segments.

15. When performing a treadmill test for PAD, exercise is normally performed for up to _____ minutes or to a maximum hyperemia equal to PAD, the cuffs are inflated _____ _____ _____ _____

photoplethysmography waves?

- A
- B
- Both are abnormal waveforms
- Unable to determine without the application of a tourniquet on the thigh

Time answered: 0
Correct answer: B, D

Feedback

The waveformsshowing a tight tourniquet on the distal calf. Medium cuff values are performed in areas the blood from the calf muscle pump is not affected by the cuff compression. A venous refill time less than 20 seconds indicates venous reflux. Stage 0 means no venous reflux. Stage 1 means

21. A patient presents with a history of HTN, diabetes and claudication. The arterial Doppler evaluation demonstrates triangulation flow in all calf vessels but the AB index was 1.1. Do and PT 1.3. Which of the following is the most appropriate next step? Points: 5 x 1=5

- The exam is normal and arterial testing should be performed to rule out venous stasis and compression due to a mass in the pelvis
- The exam is normal and additional testing should be performed to rule out venous stasis and compression due to a mass in the pelvis
- The AB index is abnormal and requires further evaluation, which may include a toe pressure and waveform
- The AB values are abnormally elevated due to a diabetic complication called medial calcification.

Time answered: 0

Feedback

Monophasic flow in the anterior tibial is commonly encountered with an AB less than 0.5. Diabetics can lead to medial calcification of the arterial walls which will falsely elevate the ankle pressure.

22. You obtain the PPG tracing from the second digit of the left hand. Which of the following is **NOT** an expected cause for the findings? Points: 5 x 1=5

- Thromboangiitis obliterans
- Prinzmetal's angina pectoris
- Raynaud disease
- Systemic sclerosis

Time answered: 0

Feedback

Lumbar sympathetic block is venous or occlusion of the distal aorta. This would lead to a similar PPG tracing from the LOWER extremities.

23. It is important to wait at least one minute before repeating what measurement? Points: 5 x 1=5

- ACR lower extremity
- Brachial pressure or an arm with a hemodialysis graft
- Ankle pressure in a hemodialysis graft
- Ankle brachial index

Time answered: 0
Correct answer: A, B

Feedback

When you are obtaining a blood pressure for a second time, it is important to wait at least 1 minute between cuff inflations. Pressure results may be increased if the system is not given the opportunity to normalize after the first pressure measurement. This is particularly important in patients with a hemodialysis graft or arteriovenous fistula.

24. When evaluating arterial pressure in the toes, the patient should be: Points: 5 x 1=5

- standing
- walking
- supine
- sitting

Time answered: 0

Feedback

Toe pressures should be evaluated with the patient supine to eliminate the effects of hydrostatic pressure. All types of walking, standing and sitting generally demonstrate significantly lower pressures.

25. Which of the following is a reason to perform exercise with a segmental pressure exam? Points: 5 x 1=5

- to differentiate a DVT-induced from an occlusion
- to evaluate venous changes in the limb
- to differentiate true claudication from pseudoclaudication
- to evaluate the effects of compression

Time answered: 0
Correct answer: C, D

Feedback

True claudication will be associated with a decrease in ABI with exercise. Pseudoclaudication will be associated with no change in the ABI with exercise.

26. The Adam maneuver is helpful in the diagnosis of what vascular disorder? Points: 5 x 1=5

- Thoracic outlet syndrome
- Carotid artery stenosis
- Raynaud syndrome
- Collateral formation with carotid occlusion

Time answered: 0
Correct answer: A, B

Feedback

The Adam maneuver is a patient position used to evaluate Pleas changes with thoracic outlet syndrome. Palpate the radial pulse while the patient abducts the ipsilateral arm and rotates the head to the contralateral side. Pulse amplitude should increase or remain the same. This sign is rarely, and basically never, the result of a false positive. Pulse amplitude should decrease or disappear with a positive test. The sensitivity and specificity of the Adam maneuver are 50% and 100%, respectively. Perform the Adam maneuver with the patient seated.

27. A segmental pressure exam demonstrates the following pressures: thigh/high 145, calf 160, ankle 150. Which of the following could explain these results? Points: 5 x 1=5

- medial calcification or venous insufficiency
- improper cuff placement and incorrect cuff size, but not medial calcification
- improper cuff placement and incorrect cuff size
- incorrect cuff size, medial calcification and improper cuff placement

Time answered: 0
Correct answer: B, C

Feedback

The cuff pressure should not demonstrate an increased pressure related to the thigh pressure. All of the choices can lead to an overestimated pressure measurement.

28. If the systolic brachial pressure is 150mmHg, what is the minimum toe pressure that would be considered normal? Points: 5 x 1=5

- 60mmHg
- 80mmHg
- 100mmHg
- 70mmHg

Time answered: 0
Correct answer: A, B

Feedback

Toe pressure is the least secondary signs in normals, at least 50% of the brachial pressure. 110 x 0.50 = 55mmHg. The minimum acceptable toe pressure is 55mmHg or higher.

29. An upper extremity segmental pressure exam produces the following pressures:
Brachial 95 / Ablbrachial 105 / Ablforearm
Ablwrist 105 / Ablpalm 105 / Ablthumb
Ulnar 85 / Ablforearm 105 / Ablwrist
2nd Digit 65 / Ablwrist 105 / Ablthumb
Which of the following is most likely responsible for the findings? Points: 5 x 1=5

- Isolated disease of the proximal left ulnar artery
- Suspected disease of the right palmar arch or digital artery of the second digit
- Suspected disease of the proximal left radial artery
- Suspected disease of the left palmar arch or digital artery of the second digit

Time answered: 0

Feedback

Where arm and palm pressures are normal but the digital pressure is abnormally reduced, there could be disease in the palmar arch or digital artery. Ulnar artery occlusion causes a decrease in the ulnar pressure and a decrease in the ulnar waveform. Proximal additional digit pressure is abnormal. Absence of the palmar arch is a rare finding caused by the reduced digit pressures. If the digital pressure is normal, the palmar arch is not the cause of the reduced digital pressure. Proximal radial artery occlusion causes a reduced radial pressure and a decreased radial waveform. Proximal ulnar occlusion causes a reduced ulnar pressure and a decreased ulnar waveform.

30. Which method is preferred to evaluate suspected popliteal aneurysms? Points: 5 x 1=5

- PPG tracing of the legs in one and one-half seconds
- Duplex ultrasound of the popliteal artery and distal vasculature
- pulse volume recordings of the leg calves with the patient supine and standing
- segmental pressures before and after treadmill exercise

Time answered: 0

Feedback

Evaluation of a patient with suspected popliteal aneurysm should be performed using PPG tracings to record changes in flow during cuff inflation. Arterial pressure in dorsiflexion of the foot can be performed to assess controlled cuff inflation circumvention.

31. When performing post-occlusion reactive hyperemia, pressure measurements in the lower extremities are obtained: Points: 5 x 1=5

- 1 minute after cuff release and every 30 seconds thereafter until return to baseline levels
- 1 minute after cuff release and every 30 seconds until pressure reaches 50% of baseline levels
- 5 minutes after cuff release and every 5 minutes until pressure return to baseline levels
- immediately after cuff release and every 30 seconds until pressure return to baseline levels

Time answered: 0
Correct answer: A, B

Feedback

When performing post-occlusion reactive hyperemia of the lower extremities, pressure measurements are obtained 1 minute after cuff release and every 30 seconds thereafter until return to baseline levels. Pressures are obtained for reactive hyperemia than maximum exercise.

32. When evaluating suspected Deep Vein Thrombosis, a DVT exam can be performed with the sensor placed on the _____ or a Doppler exam can be performed with the transducer placed _____. Points: 5 x 1=5

- Foot, thigh, on the ventral artery
- Calf, thigh, on the ventral artery
- Ventral artery, on the dorsal artery
- Ventral artery, on the dorsal artery

Time answered: 0

Feedback

When evaluating suspected Deep Vein Thrombosis, a PPG exam can be performed with the sensor placed on the foot thigh or calf. A Doppler exam can be performed with the transducer placed on the ventral artery.

33. Which of the following patients would benefit from an exercise pressure exam? Points: 5 x 1=5

- Patient with left ischemic rest pain and a 0.9 ABI
- Patient with CLIFS and resting ABI of 0.5
- Frailer with claudication and a resting ABI of 0.85
- Patient with claudication and resting ABI 0.9

Time answered: 0

Feedback

A patient presenting with left ischemic rest pain with normal or near normal resting ABI is a candidate for exercise pressure testing. Patients with CLIFS and resting ABI of 0.5 are candidates for immediate revascularization. Patients with claudication and resting ABI of 0.85 are candidates for exercise pressure testing. The exercise pressure will be positive only additional information is seen on the diagnosis of these patients.

34. When performing a segmental pressure exam on a patient with claudication, which of the following describes the response to exercise in a patient with normal arterial flow? Points: 5 x 1=5

- Ankle pressure will rise in response to exercise
- ABI will rise from 0.9 to 0.95
- Calves will be associated with a drop in ankle pressure
- ABI will rise from 1.0 to 1.1

Time answered: 0
Correct answer: A, B, C, D

Feedback

Peripheral arterial flow is not affected by exercise. Pressure increases in response to exercise. Calves will be associated with a drop in ankle pressure with exercise. Normal ABI values are not affected by exercise.

35. Which lateral venous is most commonly evaluated with Doppler to obtain the thigh pressure when performing a segmental pressure exam? Points: 5 x 1=5

- Lesser saphenous vein
- Medial calf veins with lesser saphenous vein
- Medial calf veins with lesser saphenous vein
- Medial calf veins and lesser saphenous vein
- Femoral vein is not performed in the thigh cuff

Time answered: 0
Correct answer: A, C

Feedback

The PTA is the lateral vein. The highest pressure at the ankle should be used to obtain the pressure for the remaining arterial segments. The Doppler signal is most commonly obtained at the lesser saphenous vein in the thigh.

36. Lower extremity arterial segmental pressure exam results in a post-exercise ankle pressure increase of 15 mmHg. Which of the following suggests? Points: 5 x 1=5

- Not Disease
- Iliac stenosis
- Single femoral stenosis
- Thrombosis of the femoral

Time answered: 0
Correct answer: A, C

Feedback

Lower extremity arterial segmental pressure exam resulting in a post-exercise based pressure increase of less of 15 mmHg suggests Not Disease. Iliac stenosis and thrombosis of the femoral artery are associated with post-exercise pressure drop. Single femoral stenosis suggests a multi-level disease.

37. When performing a lower extremity venous Doppler for insufficiency, a minimum of the vascular between segmentation transducers is recommended. The veins most sufficient lines to left before segmentation is repeated. Points: 5 x 1=5

- the internal vein of the Doppler signal indicates the severity of the venous
- the proximal vein of the Doppler signal indicates the severity of the venous
- the distal vein of the Doppler signal indicates the severity of the venous
- the CDU should be evaluated with patient having weight on the leg

Time answered: 0

Feedback

When performing a lower extremity venous Doppler for insufficiency, a minimum of the vascular between segmentation transducers is recommended. The veins most sufficient lines to left before segmentation is repeated.

38. A patient presents for pulse Doppler and segmental pressure exam due to impotence. The ABI is 1.15 (Valsalva). The PTA is 0.8. What is the most likely cause of the patient's impotence? Points: 5 x 1=5

- Cavernosal artery disease
- Pelvic the results is normal with no evaluation of impotence
- Cavernosal artery disease
- Have the patient perform 5 minutes of exercise on the treadmill or 10 the grade

Time answered: 0

Feedback

If the ABI is normal in the lower extremities, the patient can be tested at the base of the penis. If the ABI drops, cavernosal artery disease is the most likely cause. If the ABI is normal in the lower extremities, there can be another cause of impotence. Lower extremity exercise is not a test for cavernosal artery disease.

39. Foot pain is associated with ankle pressures less than _____ and toe pressures less than _____ and be associated with a non-healing ulcer. Points: 5 x 1=5

- 50mmHg, 30mmHg
- 50mmHg, 50mmHg
- 30mmHg, 30mmHg
- 30mmHg, 50mmHg

Time answered: 0
Correct answer: A, B

Feedback

Normal values are:
Ankle pressure: 1.0
Ankle/Brachial Index (ABI): 0.9
Toe pressure: 0.5

40. Pulse volume recording: Points: 5 x 1=5

- is used to assess arterial insufficiency and DVT
- is extremely performed with a segmental pressure exam
- is performed with the patient standing and supine to evaluate hydrostatic pressure in a normal patient
- readings should be taken beginning with the thigh cuff and ending proximally

Time answered: 0
Correct answer: A, B

Feedback

Pulse volume recording is used to assess arterial disease. PVR exams are usually performed with segmental pressure exams. Pulse volume recordings are taken beginning with the calf cuff and ending proximally. Pulse volume recordings are not measured with supine patients. Pulse volume recordings are performed in reflected ischemic mode, Normal Doppler recordings are performed in forward mode.

41. While performing an arterial Duplex exam, you obtain a triphasic waveform in the proximal superficial femoral artery. This finding is generally demonstrative a monophasic waveform. The brachial pressure is 140mmHg. Which of the following lists the correct segmental pressures? Points: 5 x 1=5

- Upper Thigh 170mmg, Lower Thigh 150mmHg, Popliteal 160mmHg, Ankle 150mmHg
- Upper Thigh 170mmg, Lower Thigh 150mmHg, Popliteal 160mmHg, PTA 150mmHg
- Upper Thigh 170mmg, Lower Thigh 150mmHg, Popliteal 160mmHg, PTA 150mmHg
- Upper Thigh 150mmg, Lower Thigh 150mmHg, Popliteal 160mmHg, PTA 150mmHg

Time answered: 0
Correct answer: A, B

Feedback

A distal pressure 20mmHg between two adjacent segments indicates significant disease in the artery between the two cuffs. If there is a suspected mid-PE venous or occlusion, there will be a significant drop in pressure between the two high cuffs.

42. An abnormal Pleria/Brachial Index will be: Points: 5 x 1=5

- < 1.0
- < 0.9
- < 0.95
- < 0.85

Time answered: 0
Correct answer: C, D

Feedback

A normal Pleria/Brachial is less than 0.95 of the systolic pressure, sensitivity/specificity is diagnostic. A normal PPG is 0.95 of the systolic pressure. The PPG is 0.95 of the systolic pressure. The PPG is integral in diagnosis and management. Class IV venous dysfunction cannot be diagnosed.

43. A segmental pressure exam is performed for a patient who is experiencing rest pain in the right leg. An ABI of 0.42 was found on the right. Which of the following statements is true regarding the findings? Points: 5 x 1=5

- The patient will be referred to a vascular surgeon for intervention
- Further testing will provide additional diagnostic information for the patient
- CFA exam will provide additional diagnostic information for the patient
- It is unusual ABI results for the upper thigh and the ankle pressure exercise

Time answered: 0
Correct answer: A, B

Feedback

There is significant disease present. Exercise testing is a pulse volume recording exam will not provide additional information that will alter the patient's diagnosis and treatment. The patient is already candidate for a vascular intervention.

44. A patient presents for an exercise arterial exam after an abnormal resting ABI of 0.9. The patient's ankle pressure increased 20 mmHg and reduced that reduces a stenosis of 100% in the distal femoral artery on the left leg, hyperic waveforms in the PTA and DPA and an ABI of 0.95 on the right. The patient's ankle pressure increased 20 mmHg pressure in the left leg with exercise. What could explain these findings? Points: 5 x 1=5

- Distal arterial occlusion (diffuse
- Reversal syndrome
- Congenital heart failure
- Intermittent collateral formation

Time answered: 0
Correct answer: A, B

Feedback

Patient is treated with high dangling over stage 3 limb for the exam. A sensor is placed on the dorsal medial toe big. Never place the sensor on the medial malleolus because it will be in the area of the posterior tibial artery and will give false results. Place the sensor for the dorsal foot vessels. It is essential to segment the leg into different segments and measure the pressure in each segment.

45. When a patient performs exercise on a treadmill what will be the normal response of the brachial indices? Points: 5 x 1=5

- Increase in the brachial indices
- Unchanged in the brachial indices
- Unchanged in ankle brachial
- Increased by more than 0.1

Time answered: 0
Correct answer: A, B

Feedback

The pressure in the ankles and arms may decrease but a slight increase in pressure with exercise has the brachial and ankle pressures increase. Increase in the brachial indices is a sign of peripheral arterial disease. Increase in the brachial indices is a sign of peripheral arterial disease. Increase in the brachial indices is a sign of peripheral arterial disease. The ankle and arm pressures increase with exercise.

46. A 7 year old presents with chronic fatigue and decreased palpable pulses in the legs. The ankle brachial index is performed with the following results:

L1 arm 110mmHg

L2 ankle 95mmHg

R1 arm 115mmHg

R2 ankle 90mmHg

Points: 5 x 1=5

Which of the following is the most likely explanation of the findings?

- There is most likely a coarctation of the descending aorta
- There is most likely atherosclerotic vascular disease present in both lower extremities
- There is most likely a subclavian steal present
- The bilateral ABIs are normal

Time answered: 0
Correct answer: A, B

Feedback

The pulse pressures are significantly higher than normal. The leg pressures are lower than normal. The bilateral asymmetric pressures are not consistent with atherosclerotic vascular disease. The bilateral asymmetric pressures are not consistent with a subclavian steal. The bilateral asymmetric pressures are not consistent with a coarctation of the descending aorta. The bilateral asymmetric pressures are not consistent with a coarctation of the descending aorta.

47. What is the most accurate method of high pressure assessment? Points: 5 x 1=5

- Cuff segmental pressure exam
- Doppler velocity waves the Revised equation to calculate high pressure
- Cuff segmental pressure exam
- Ultrasonic cylinder measures pressure in the superficial femoral vein

Time answered: 0

Feedback

The cuff method uses two double cuffs to obtain two separate pressures. These cuffs are usually smaller than the thigh cuff. The Doppler velocity waves the Revised equation to calculate high pressure. The thigh cuff uses the cuff method. Ultrasonic cylinder measures pressure in the superficial femoral vein.

48. What is the primary purpose of using a tourniquet during a venous exam? Points: 5 x 1=5

- Prevent venous reflux
- Prevent venous reflux
- Prevent venous reflux
- Prevent venous reflux

Time answered: 0

Feedback

The cuff method uses two double cuffs to obtain two separate pressures. These cuffs are usually smaller than the thigh cuff. The Doppler velocity waves the Revised equation to calculate high pressure. The thigh cuff uses the cuff method. Ultrasonic cylinder measures pressure in the superficial femoral vein.

- b. determine if thrombus is present in the deep or superficial system
- c. to evaluate the perforators for reflux
- d. to determine if thrombus is confined to the superficial system
- e. to determine if thrombus is confined to the deep or the superficial system

Correct answers: b, c

Feedback

When the venous refill time (VRT) is less than 30 seconds, a tourniquet is applied to the leg at the point to isolate superficial reflux. If the VRT is now greater than 30 seconds, the reflux is in the deep system. If the VRT remains less than 30 seconds, the reflux is in the deep and superficial systems. If the VRT remains less than 30 seconds and there is no reflux, the reflux is in the deep system and not in the superficial system.

63. Which of the following is a characteristic of a normal lower extremity arterial PVR waveform? Points: 5 | 5

- a. dicrotic downstroke
- b. sharp systolic rise
- c. slow upstroke
- d. pronounced dicrotic notch

You answered: d

Feedback

An abnormal PVR waveform will demonstrate a loss of the dicrotic notch, slow upstroke, slow downstroke and little difference between systolic and diastolic pressures.

64. A segmental pressure exam demonstrates the following pressures; Points: 8 | 5

right arm 130mmHg

right thigh 110mmHg, calf 100mmHg, ankle 92mmHg.

Which of the following could explain these results?

- a. aortic stenosis or aortitis
- b. common femoral or deep femoral artery
- c. medial calcification
- d. aortic stenosis or common iliac disease

You answered: a

Correct answer: a, b

Feedback

Segmental pressures are taken by one decreased while indicated proximal disease. Using the Ankle-Left method, the brachial pressure is compared to the ankle pressure. Normally the ankle pressure is higher than the brachial pressure. Medial calcification causes falsely elevated ankle pressures. Aortitis causes a decreased ankle pressure.

65. What can be done to inhibit light from the exam room from causing artifact on an upper extremity PPG tracing? Points: 8 | 5

- a. place a black cloth over the patient's extremities covered
- b. increase the room temperature
- c. place elevator gel between the PPG sensor and the skin
- d. cover the patient's hand with a towel or sheet

You answered: a

Correct answer: a, b

Feedback

To keep light from the exam room from causing artifact on the PPG tracing, cover the patient's hand with a towel or sheet.

66. A 65yr old male presents with mild left calf pain after walking 10 blocks. He has a history of hypertension, CHF, and CAD. His ankle-brachial pressure with ABI, the left ABI is 1.0. These findings are most suggestive of: Points: 8 | 5

- a. The venous system should be evaluated for possible thrombosis
- b. The venous system should be evaluated for possible insufficiency
- c. The patient's ankle-brachial pressure index is normal and the cause of the left leg ischemia is elsewhere
- d. The patient is most likely experiencing an intermittent claudication and an ABI may be normal

You answered: b

Correct answer: b, c

Feedback

Because the patient is not certain the problem is walking, the leg should be evaluated with exercise to completely rule out a venous diagnosis.

67. A patient's short of breath after walking to the facility for the arterial duplex evaluation. What is the first thing you should do when starting the exam? Points: 8 | 5

- a. Transfer the patient to the exam room on a stretcher
- b. Take the brachial pressures
- c. Take the ankle pressures using the PPG and VPG
- d. Take the ankle pressures with the Doppler exam and perform the pressure index

You answered: b

Correct answer: a, d

Feedback

If the patient does not rest, the exercise from the long walk can affect the results of the exercised-reading arterial exam. This can lead to overestimation of the severity of the disease. Demonstrate on the reading room.

68. What is the most likely cause of the findings on the image? Points: 8 | 5

www.healthmedia.com/

- a. distal popliteal artery occlusion
- b. bilateral popliteal entrapment
- c. bilateral flat sensors
- d. unknown

You answered: d

Correct answer: a, d

Feedback

Normal ABI with abnormal digital tracings indicates obstruction of the digital arteries by arteriosclerosis. This pattern should be suspected in patients with DM, renal failure, or long-term steroid use. Medial calcinosis causes falsely elevated ankle pressures and digital pressures are used instead. Medial calcinosis affects the common femoral artery and distal popliteal artery and causes a decreased ankle pressure.

69. A patient presents with left leg claudication. The right ABI is 1.32 and the left ABI is 0.95. The patient's ankle pressure is 150mmHg. Points: 8 | 5

- a. the left leg ischemia is most likely due to a distal popliteal entrapment
- b. perform the supine leg lift test to repeat the ankle pressure measurements
- c. switch to the thigh with an appropriate segmental exam to include the proximal calf and thigh pressures
- d. use the classic exam to evaluate the findings

You answered: b

Correct answer: a, b

Feedback

When the ABI exceeds 1.3, there is more likely medial calcification present. Because medial calcification does not usually affect the ankle, the ankle pressure is not accurate. Perform the supine leg lift test to repeat the ankle pressure measurements or use the Thigh-Left method.

70. Lower extremity arterial segmental pressure exam results in a post exercise hyperemia recovery time of 1.6 minutes which suggests: Points: 8 | 5

- a. the distal pressures are normal
- b. thigh-calf stenosis
- c. thigh-level stenosis
- d. this disease

You answered: b

Correct answer: b, c

Feedback

Lower extremity arterial segmental pressure exam resulting in a post exercise hyperemia recovery time of 1.5 minutes suggests a single hemodynamically significant stenosis. Recovery times exceeding 2 suggest multiple hemodynamically significant stenoses. This is the disease that is causing the decrease in the pressures in the entire leg. If pressures drop proximal, both legs would be affected.

71. A patient presents for a lower extremity arterial segmental pressure exam. The patient's ankle pressure is 150mmHg. Which of the following pressures are most appropriate to take? Points: 8 | 5

- a. The patient must be evaluated in the standing position for the pressure measurements
- b. The patient must be evaluated in the supine position for the pressure measurements
- c. If the surgical procedure was performed more than 10 years ago, the exam should be performed using the standard protocol
- d. A post pressure must be obtained instead of a brachial pressure and the number will be used to calculate the pressure index

You answered: b

Correct answer: b, d

Feedback

Brachial blood pressures are prohibited on the ipsilateral arm of a hemodialysis patient. With the bilateral hemodialysis, neither arm is available for a brachial pressure. Post pressures are used instead of brachial pressures. Post pressures are taken at the same anatomical location as the brachial pressure and will calculate the disease in lower extremities if the post pressure is lower than the brachial pressure.

72. The following pressures were obtained in a patient during a segmental pressure exam. Where is the disease, if any? Points: 8 | 5

Right, PSI 130mmHg, DPS. 110mmHg, Calf 130mmHg, Low Thigh 130mmHg, Thigh 130mmHg, Ankle 150mmHg

Left PSI 80mmHg, DPS 85mmHg, Calf 100mmHg, Low Thigh 110mmHg, High Thigh 130mmHg, Brachial 120mmHg

- a. right thigh-level stenosis
- b. aortic disease or left iliac disease
- c. left thigh-level stenosis
- d. unknown

You answered: b

Correct answer: c

Feedback

The DPS difference is greater than 20 mmHg when comparing the calf and thigh pressures. This indicates ischemia only distal to the thigh. The DPS difference is not clinically significant and does not indicate disease. A proximal stenosis causes all the pressures to drop at the largest gradient.

73. A patient presents with lower extremity pain that awakens him at night. The pain is relieved by sitting at the side of the bed for a few minutes. The ankle would the pressures DP value be for the left leg? Points: 8 | 5

- a. 0
- b. 10
- c. 15
- d. 20

You answered: d

Correct answer: c, d

Feedback

This patient is experiencing rest pain which is found in patients with a DP-Ankle that is 15.

74. A patient presents for severely arterial evaluation with a rest pain bilaterally and bacterial tips of the 4th and 5th toes on the left foot. Points: 8 | 5

Right Ankle 140mmHg

Left Ankle 100mmHg

Highest brachial pressure 140mmHg

Which statement is true regarding these findings?

- a. The pressures should be obtained by Doppler assessment
- b. The signs and symptoms are most likely related to dehydration and pain hygiene
- c. An exercise arterial exam is necessary to properly diagnose the patient
- d. The signs and symptoms are most likely related to associated venous insufficiency

You answered: b

Correct answer: a, d

Feedback

Ischemic pressures does not always cause an exceptional ABI measurement of greater than 1.0. The sensitivity of significant ischemia do not fit the normal ABI measurements. The diabetic trauma also adds to the risk for the medical certification. Two ischemic digits are a sign of critical limb ischemia and a medical certification is required.

75. Which of the following would cause the systolic pressure reading to be falsely elevated? Points: 8 | 5

- a. calf in a cast
- b. reading obtained with the patient supine
- c. calf pressure over the tibial sources
- d. the patient suffers from congestive heart failure

You answered: b

Correct answer: a, d

Feedback

A PPG tracing forms a non-pulsatile flow pattern with a lower amplitude and a prolonged upstroke. The PPG tracing is not affected by the position of the patient. The patient's ankle pressure is falsely elevated and does not reflect the true pressure in the leg. The pressure is not affected by the patient's cardiac function.

76. Which of the following is a major limitation of a lower extremity segmental pressure exam when compared to a Doppler evaluation? Points: 5 | 5

- a. The segmental pressure technique is only suited for evaluating obstructive disease above the knee
- b. The segmental pressure technique is only suited for evaluating obstructive disease below the knee
- c. The segmental pressure technique cannot differentiate between the three common lesions of atherosclerosis
- d. The segmental pressure technique cannot evaluate obstructive disease on the feet

You answered: c

Feedback

Segmental pressures are determined the level of the problem in the extremity but cannot determine the cause of stenosis or obstruction. For a patient, the segmental exam indicates proximal disease. Without Doppler evaluation, there is no way to determine if the lesion is a stenosis or occlusion. The Doppler exam is used to determine the cause of the problem. Doppler is used to locate the lesion causing the decrease in the pressures. Doppler is also used to determine if the lesion is a stenosis or occlusion. Doppler is used to determine if the lesion is a stenosis or occlusion. Doppler is used to determine if the lesion is a stenosis or occlusion. Doppler is

- [ ] [illegible]
- [ ] [illegible]
- [ ] [illegible]

How to set up the calculation: The highest calf artery pressure is divided by the highest brachial pressure to calculate the ABI.

123. Subcutaneous blood supply to the digits can be evaluated using which non-invasive plethysmography technique? Points: **0 / 1**

A: Photoplethysmography

B: Pulse volume recording

C: Impedance plethysmography

D: Strain gauge plethysmography

You answered: **C**
Correct answer is: **A**

Feedback:

Photoplethysmography uses photocells to detect the changes in blood cell volume in subcutaneous tissue during the cardiac cycle.

124. A patient presents with HTN, DM and left lower extremity pain that occurs only as he walks. He usually begins to have pain after he walks to his mailbox with increasing pain as he returns to the house. The pain is relieved by resting his legs for a few minutes. What would the predicted ABI value be for the left leg? Points: **0 / 1**

A: 0.9

B: 0.6

C: 0.4

D: above 1.0; these symptoms are most likely unrelated to arterial disease

You answered: **C**
Correct answer is: **B**

Feedback:

The patient is experiencing claudication which is found in patients with 0.5 - 0.9 ABI. The short distance of walking to the mailbox before the pain begins indicates a more significant amount of disease than 0.9 ABI would indicate. An ABI of 0.6 is the best choice with the given symptoms.

125. Which of the following describes the appearance of a significantly abnormal arterial PPG waveform? Points: **1 / 1**

A: high amplitude with loss of the dicrotic notch

B: high amplitude with prominent of the dicrotic notch

C: low amplitude with loss of the dicrotic notch

D: low amplitude with prominent dicrotic notch

You answered: **C**

Feedback:

The normal PPG waveform should be high amplitude with a dicrotic notch on the downslope. Loss of the notch and decreased amplitude indicate significantly abnormal flow.

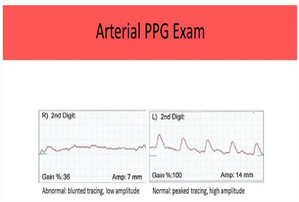

126. Which of the following correctly describes a PVR waveform? Points: **0 / 1**

A: The diastolic flow reversal component is exaggerated on a PVR waveform

B: The patient should be standing for the waveform recording

C: The amplitude of the waveforms from the calf should be higher than the amplitude of the waveforms from the thigh in normal patients

D: Hemodynamic changes due to stenosis will be displayed as a deepening of the dicrotic notch and increased amplitude of the wave

You answered: **A**
Correct answer is: **C**

Feedback:

The amplitude of the waveforms from the calf should be higher than the amplitude of the waveforms from the thigh in normal patients. There are greater volume changes in the calf than the thigh in a normal patient.

127. A segmental pressure exam demonstrates the following pressures: Points: **0 / 1**

right arm: 142mmHg

right leg:

proximal thigh 140mmHg

distal thigh 126mmHg

calf 116mmHg

ankle 112mmHg.

Which of the following could explain these results?

A: infrapopliteal disease

B: pelvic mass

C: pelvic mass or mid femoral artery stenosis

D: medial calcification

You answered: **C**
Correct answer is: **B**

Feedback:

Using the four cuff method, the proximal thigh pressure should be 30-40mmHg higher than the brachial pressure. The pressures are decreased in the entire leg at small intervals from the thigh down. This indicates aortoiliac disease or possible intrinsic compression of the iliac artery by a pelvic mass.

128. A patient presents with a history of recurrent upper extremity DVT due to Paget Schroetter syndrome. The referring physician ordered a PVR exam of the upper extremities instead of a venous Doppler exam of the upper extremities. Why? Points: **0 / 1**

A: to rule out thoracic outlet syndrome

B: to rule out Raynaud's syndrome

C: to rule out a subclavian steal

D: to rule out associated atherosclerotic disease

You answered: **C**
Correct answer is: **A**

Feedback:

Paget Schroetter syndrome is commonly associated with thoracic outlet syndrome. The presence of a cervical rib or aberrant muscle band can be involved with the DVT formation with Paget Schroetter syndrome.

129. Photoplethysmography (PPG) is useful to assess all of the following, **except**: Points: **1 / 1**

A: Thoracic Outlet Syndrome (TOS)

B: Raynaud disease

C: Digit perfusion

D: Carotid stenosis

You answered: **D**

Feedback:

PPG or photoplethysmography is very useful for evaluating perfusion of the digital vessels. Raynaud disease most commonly affects the smaller vessels of the hands. Thoracic outlet syndrome usually causes an obstruction of the upper extremity arterial flow, which could be demonstrated by using the PPG technique to assess digital perfusion.

130. How many cuffs are recommended when performing a bilateral lower extremity segmental pressure evaluation? Points: **0 / 1**

A: 5

B: 3

C: 4

D: 8

You answered: **C**
Correct answer is: **D**

Feedback:

The most common protocol for a segmental pressure exam of both of the legs involves 4 cuffs per leg for a total of 8.

131. Treadmill exercise is normally performed: Points: **1 / 1**

A: until symptoms are intolerable

B: up to 12 minutes or until symptoms are intolerable

C: up to 5 minutes

D: until symptoms are intolerable or up to 5 minutes

You answered: **D**

Feedback:

Treadmill exercise is normally performed until symptoms are intolerable or up to 5 minutes.

132. The 10cm blood pressure cuffs are missing from the lab. You perform the 3 cuff method lower extremity segmental pressure exam with the 12cm and 14cm cuffs on a patient that is 5'5" 150lbs. What information that you will report will be invalid? Points: **0 / 1**

A: brachial pressure, calf pressure and ankle pressure

B: calf pressure only

C: brachial pressure only

D: thigh pressure only

You answered: **C**
Correct answer is: **A**

Feedback:

The †2cm or larger cuff is normally used for the thigh. If the larger cuff is used, the pressure will be underestimated in the calf, ankle and arm.

133. Which of the following is a contraindication for a lower extremity segmental pressure exam? Points: **0 / 1**

A: current anticoagulant treatment

B: ulceration on the 3rd and 4th toes

C: diabetes mellitus

D: recent saphenous vein arterial bypass grafting

You answered: **B**
Correct answer is: **D**

Feedback:

Contraindications:
Suspected or known acute deep venous thrombosis - use waveform analysis only or use of a toe/brachial index (TBI)
Recent surgery, trauma site or ulcers that cannot/should not be compressed by pressure cuffs
History of lower limb stent replacement, or recent saphenous vein arterial bypass grafting
Patients with incompressible arteries due to medial calcification - TBI may be used instead
Morbidly obese patients - high-thigh pressure may be unobtainable or inaccurate due to limb girth
Patients with significant tremors or involuntary movements that may cause waveforms to be suboptimal or unreliable

Ulcerations on the 3rd and 4th toes would not be compressed by cuffs. While diabetes mellitus can cause medial calcification which could inhibit the exam, not every patient with DM has medial calcification.

Powered by ExamBuilder. Copyright ©2026