ARDMS VASC CTS, Prep & Reporting 8%

Created by Sharon Ellington

Edit Quiz | Preview Quiz

ARDMS VASC CTS, Prep & Reporting 8%
Completed March 22, 2022 | Passing Score: 70% | Status: Failed

Correct Answers in Red | Incorrect Answers in Red

1. You are about to perform a lower extremity arterial duplex on a patient that recently had an MRA cut-off exam. According to the attached image, what vessel will demonstrate reduced or absent flow in the right leg? Points: 8/1-1

- obturator artery
- anterior tibial artery
- posterior tibial artery
- common femoral artery
- superficial femoral artery

You answered: **A**
Correct answer: **D**

Feedback
Note the limited display of contrast in the superficial femoral artery of the right leg and the anterior tibial artery of the left leg. This discrepant finding is a common occurrence in these patients with demonstrated MRA cut-off.

2. You are performing a left upper extremity venous duplex exam. DVT is suspected in the left arm. The following sonographic findings are noted. Which one of the following must also be included in the exam protocol for this patient? Points: 8/1-1

- external free pattern in the veins associated with the thrombosed vein
- increased spectral broadening
- flow in the ventralateral collateral vein
- pulse wave tracking of the pulsatile pattern upon arm flexion

You answered: **C**

Feedback
For all venous extremity venous exams, the flow in the contralateral extremity should be documented for comparison. Spectral broadening is a non-specific finding and pulse wave tracking is not a standard part of the venous exam.

3. You are scanning an extremity duplex examination for suspected neurogenic ischemia. The findings are:
Left Brachial 120/mmHg, Left Radial 110/mmHg, Left Ulnar 110/mmHg
Right PT 180/mm, SDV 35/mm, monophasic flow with spectral window
Left PT 180/mm, SDV 25/mm, monophasic flow with spectral window

How will you report these findings? Points: 8/1-1

- Normal resting ankle-brachial index (ABI) in the contralateral limb
- Normal velocity of the MPA with monophasic flow in the calve artery and PT
- Suspected treatment ischemia with abnormal flow velocities and waveforms in the SMA, MA, and celiac artery
- Suspected treatment ischemia with abnormal flow velocities and waveforms in the SMA and celiac artery

You answered: **C**
Correct answer: **A, D**

Feedback
Always verify there is signs of a PTG report for monophasing.
The purpose of an exercise vasogenic provocation test is to convert PAD that is not diagnosed with the ankle or arm. The vasogenic provocation test is performed by having the patient exercise to fatigue and then repeat the ankle-brachial index. Normal resting ankle-brachial index has been adapted also when combating PAD using the exercise vasogenic provocation test. Complications from Treatment ischemia = Spectral window
Treatment ischemia = Monophasic waveform

4. All of the following should be included in the report from an exercise vasogenic provocation test, **except**: Points: 8/1-1

- Duration of exercise
- Pressure leaving limb at ankles
- Pressure leaving limb at ankles after exercise
- Ankle-Brachial Index(ABI)

You answered: **A**
Correct answer: **C, D**

Feedback
The purpose of an exercise vasogenic provocation test is to convert PAD that is not diagnosed with the ankle or arm. The vasogenic provocation test is performed by having the patient exercise to fatigue and then repeat the ankle-brachial index. Normal resting ankle-brachial index has been adapted also when combating PAD using the exercise vasogenic provocation test.
Complications from Treatment ischemia = Spectral window
Treatment ischemia = Monophasic waveform

5. You are about to perform a lower extremity arterial duplex on a patient that recently had an MRA cut-off exam. According to the attached image, what vessel will demonstrate reduced or absent flow in the right leg? Points: 8/1-1

- obturator artery
- superficial femoral artery
- common femoral artery
- anterior tibial artery

You answered: **A**
Correct answer: **D**

Feedback
Note the limited display of contrast in the superficial femoral artery of the right leg and the anterior tibial artery of the left leg. This discrepant finding is a common occurrence in these patients with demonstrated MRA cut-off.

6. What will be included in your preliminary report for this patient? Points: 8/1-1

- There is a possible stenosis of the brachial radial and/or ulnar arteries
- There is a possible stenosis of the right radial and/or ulnar artery
- There is a possible stenosis of the left radial and/or ulnar artery
- There is a possible stenosis of the bilateral brachial arteries

You answered: **B**

Feedback
The significant drop in pressure occurs to the right arm between the forearm and the digit cuff. This indicates a possible stenosis in the right radial and/or ulnar arteries. The significant drop in pressure occurs to the left arm between the brachial and the forearm cuff. This indicates a possible stenosis in the left radial and/or ulnar arteries. The brachial pressure is not the same between the right and the left arm. The significant drop in pressure occurs to the right arm between the brachial and the forearm cuff. This indicates a possible stenosis in the brachial arteries.

7. If the velocities in both carotid arteries are increased since last year's exam with no visible change in plaque formation, what should you review in the patient chart as a possible explanation? Points: 8/1-1

- Increased timing for coronaries CTA
- Lab values for decreased hematocrit levels
- Increased blood pressure levels
- Good anticoagulation for signs of decreased carotid output

You answered: **D**
Correct answer: **A, B**

Feedback
Decreased hematocrit will lead to increased blood velocities and increased blood pressure velocities. Polycythemia also leads to thickening of the blood and increased blood velocities. Good anticoagulation will lead to decreased blood velocities and increased blood pressure velocities.

8. A patient presents for a segmental pressure exam. The states she has had DVT in her right leg three times over the last 2 years. Today she presents with a swollen right leg and pain in the calve area. The MD states that the doctor could not find the pedal pulses on the right side. What should you review in the patient chart prior to starting the exam? Points: 8/1-1

- Lab values for hypercoagulation
- Surgical history for endovenous ablation
- Medical history for current Coumadin therapy
- Lab values for hematocrit levels

You answered: **C**

Feedback
The patient will be too obese for the tibial pressures to occur in the right leg. Current Coumadin therapy drastically reduces the INR. Lab values for hypercoagulation will not be helpful in determining the cause for the right leg pain. Lab values for hematocrit levels are the ones that assist you when considering the risk for embolism.

9. A coronthrean transducer can be used to better evaluate: Points: 8/1-1

- Area in the deep posterior tibial artery
- deep veins in deep calves
- connective covering in large arteries
- flow in the anterior tibial artery

You answered: **D**

Feedback
Deep DVT cannot ability performed with a 7 MHz linear transducer. A coronthrean transducer may be necessary to evaluate deep calve veins and the deep posterior tibial artery. Large aneurysms that are in the connective covering of the arteries are difficult to evaluate with a linear transducer.

10. You identify acute thrombosis of the left popliteal and femoral vein, and the proximal end of the clot has a free-floating tail. What should you do next? Points: 8/1-1

- Check the patient chart for a history of Coumadin therapy
- Call for a code blue due to the significant increased risk of embolism
- Check the patient chart for a history of hypercoagulation
- Call the patient to find out if anticoagulant has been the DVT is continued and you need to consult the leading physician for treatment

You answered: **C**
Correct answer: **A, C, D**

Feedback
Free-floating clot can be a critical finding. The cause history of DVT could indicate that the patient is on anticoagulant therapy if this is Coumadin. This greatly reduces the risk of pulmonary embolism from the clot. A preliminary report should be called to the ordering physician. Free-floating clot is not a code blue situation. Free-floating clot is not a common finding. Free-floating clot is not a common finding. Free-floating clot is not a common finding. Free-floating clot is not a common finding.

11. Identify the image shown. Points: 8/1-1

- Bronchoscopic duplexes of the right renal artery
- Bronchoscopic duplexes of the left renal artery
- cortical/hilar spectra artery
- normal right renal artery

You answered: **D**

Feedback
Not demonstrating a having tumor colour like a being of spleen.

12. What technique is recommended for evaluation of the mean portal vein to an obtuse patient with acute and significant bowel gas? Points: 8/1-1

- patient in the left lateral decubitus or oblique position with subcostal transducer position
- patient in the left lateral decubitus or oblique position with intercostal transducer position
- patient in the left lateral decubitus or oblique position with intercostal transducer position
- patient in the right lateral decubitus or oblique position with intercostal transducer position

You answered: **C**

Feedback
The patient will be too obese for the tibial pressures to occur in the right leg. Current Coumadin therapy drastically reduces the INR. Lab values for hypercoagulation will not be helpful in determining the cause for the right leg pain. Lab values for hematocrit levels are the ones that assist you when considering the risk for embolism.

13. You perform a carotid Doppler exam that demonstrates minimal atherosclerosis bilaterally. You record waveforms that demonstrate normal flow with the following velocities: Right Proximal ICA PSV 100cm/s, EDV 30cm/s Left Proximal ICA PSV 140cm/s, EDV 35cm/s Right CCA PSV 100cm/s, EDV 20cm/s What will you report your waveform? Points: 8/1-1

- Flow velocities are increased bilaterally, which is most likely related to increased cardiac output
- Flow velocities are increased bilaterally, which is most likely related to left ventricular hypertrophy
- Flow velocities are increased bilaterally, which is most likely related to left ventricular hypertrophy

You answered: **A**
Correct answer: **A, D**

Feedback
Minimal atherosclerosis is the ICA and CCA with no evidence of stenosis is usually related to increased cardiac output. Minimal atherosclerosis with increased velocities, secondary to a flow the result in increased cardiac output.

14. Which of the following is an important part of Sonographer- Patient communication? Points: 8/1-1

- Explaining the exam and the results
- Limiting the patient's stress and deal of tests
- Offering advice or ways to alleviate symptoms and the doctor knows the problem
- Letting the patient's they are allergic to saline

You answered: **C**
Correct answer: **A, D**

Feedback
Sonographer-Patient Communication involves limiting the patient's stress and deal of tests, explaining the exam and what to expect, and letting the patient know that their exam is finished.
Sonographers should not offer treatment advice to the patient. Always refer them to their doctor when they have questions about their treatment.
Contrast contrast is a safe alternative to gadolinium. If the patient is having high degree of protrusion, the sonographer should inform the doctor and discuss the options.

15. Why is an acute arterial occlusion in the lower extremity considered a critical finding? Points: 8/1-1

- Increase in ischemia
- The risk of amputation is significantly increased
- The risk of embolism figure is significantly increased
- Collateral flows not fast enough to form a to reinstitute the blood

You answered: **C**
Correct answer: **B, D**

Feedback
Minimal collateral present to reinstitute blood flow, the risk of tissue death and possible amputation is increased.

16. When preparing for a patient with suspected thoracic outlet syndrome, what other information should you review for pertinent information? Points: 8/1-1

- Chest x-ray
- Lab results for hemoglobin levels
- Aortogram
- CT of the heart

You answered: **A**

Feedback
A chest x-ray would demonstrate the cervical rib that is a common cause for TOS.

17. You are performing an upper extremity venous Doppler exam for a vein washing out pain. The image displayed is from the left brachial vein. What should you do next? Points: 8/1-1

- There is a venous thrombosis formation around an incompetent valve in the subclavian vein.
- There is a venous thrombosis formation around an incompetent valve in the axillary vein.
- There are megaflow flows around of elevated clots in thrombosis present in the subclavian vein.
- The subclavian vein is normal and completely patent with an incompetent valve in the vein.

You answered: **C**
Correct answer: **A, B**

Feedback
The proper thrombus formation is called the venous and Doppler sonography is the analogous to angiogram venous.

18. A patient presents with an order for a lower extremity venous Doppler exam to rule out a DVT. The patient should be evaluated in the _____ position in order to _____. Points: 8/1-1

- supine, reduce hydrostatic pressure
- semi-erect, increase hydrostatic pressure
- semi-erect, reduce hydrostatic pressure
- supine, increase hydrostatic pressure

You answered: **B**
Correct answer: **A, D**

Feedback
Patients are exposed to the supine position for complete venous emptying and Doppler exam is to reduce hydrostatic pressure.

19. Which of the following is important information to record on the final report for a carotid Doppler exam on a patient with 50-69% ICA stenosis? Points: 8/1-1

- Electrocardiogram tracings
- Recommendations for TCD exam for associated intracranial disease
- Doppler angle used on the exam
- Transducer frequency used for the exam

You answered: **C**

Feedback
In cases patients the right-handed venous can be a direct branch of the aorta distal to the left subclavian origin, it is called the innominate artery. Because the innominate artery is a direct branch of the aorta, it is the first vessel to receive blood from the heart. The proximal ascending aorta is the first vessel that receives blood. The proximal ascending aorta is the first vessel that receives blood. The proximal ascending aorta is the first vessel that receives blood. The proximal ascending aorta is the first vessel that receives blood.

20. What usually should be improved by the administration of Sonahancone during a carotid duplex exam? Points: 8/1-1

- Inter-hemispheric communication
- Cerebrovascular blood flow
- Lateral arteries spasm
- Carotid duplex

You answered: **C**

Feedback
Sonahancone is a medication that is used to reduce blood gas, it may be beneficial when performing abdominal duplex exams.

21. Which of the following describes an important reason to verify the CTA examination that is ordered is the exam that should really be performed? Points: 8/1-1

- Patient's medical chart contains the orders verified by physicians and perform the exams as ordered.
- Write the sonogram technical summary before evaluating the patient.
- Write the suspected diagnosis is not able to be evaluated by the exam that is ordered
- Write the exam is ordered the most not for treating physician is available

You answered: **C**
Correct answer: **A, D**

Feedback
Write the suspected diagnosis is not able to be evaluated by the exam that is ordered. Not a important reason to verify the CTA examination that is ordered is the exam that should really be performed.

22. A patient presents for a dedicated transcranial Doppler exam to rule out an AV fistula. What should you do first? Points: 8/1-1

- Send the patient to the MR department instead
- Start with the ICA on the affected side
- Start with the ACA on the opposite side from the suspected abnormality
- Consult the radiologist regarding the validity to evaluate the abnormality on TCD

You answered: **B**
Correct answer: **A, D**

Feedback
Start with the ICA on the affected side.
Start with the ACA on the opposite side from the suspected abnormality.
Consult the radiologist regarding the validity to evaluate the abnormality on TCD.

23. Which of the following describes an important reason to verify the CTA examination that is ordered is the exam that should really be performed? Points: 8/1-1

- Patient's medical chart contains the orders verified by physicians and perform the exams as ordered.
- Write the suspected diagnosis is not able to be evaluated by the exam that is ordered
- Write the exam is ordered the most not for treating physician is available

You answered: **C**
Correct answer: **A, D**

Feedback
Write the suspected diagnosis is not able to be evaluated by the exam that is ordered. Not a important reason to verify the CTA examination that is ordered is the exam that should really be performed.

24. When reporting spectral Doppler information the Sonographer must: Points: 8/1-1

- always record the highest velocity, resistance and angle
- classify each waveform as triphasic, biphasic or monophasic
- record the highest velocity and highest velocity signal to the heart measurements
- document the frequency of the transducer used to the exam should be indicated in the report

You answered: **B**
Correct answer: **C, D**

Feedback
Spectral Doppler measurements should be made at the most obstructive margin of the flow signal. Multiple samples may be needed to obtain the most accurate measurements. Spectral Doppler measurements should be made at the most obstructive margin of the flow signal. Multiple samples may be needed to obtain the most accurate measurements.

25. Which exam would be improved by the administration of Sonahancone during a duplex exam? Points: 8/1-1

- Inter-hemispheric communication
- Cerebrovascular blood flow
- Lateral arteries spasm
- Carotid duplex

You answered: **C**

Feedback
Sonahancone is a medication that is used to reduce blood gas, it may be beneficial when performing abdominal duplex exams.

26. Which of the following describes an important reason to verify the CTA examination that is ordered is the exam that should really be performed? Points: 8/1-1

- Patient's medical chart contains the orders verified by physicians and perform the exams as ordered.
- Write the suspected diagnosis is not able to be evaluated by the exam that is ordered
- Write the exam is ordered the most not for treating physician is available

You answered: **C**
Correct answer: **A, D**

Feedback
Write the suspected diagnosis is not able to be evaluated by the exam that is ordered. Not a important reason to verify the CTA examination that is ordered is the exam that should really be performed.

27. Which exam would be improved by the administration of Sonahancone during a duplex exam? Points: 8/1-1

- Inter-hemispheric communication
- Cerebrovascular blood flow
- Lateral arteries spasm
- Carotid duplex

You answered: **C**

Feedback
Sonahancone is a medication that is used to reduce blood gas, it may be beneficial when performing abdominal duplex exams.

28. Which of the following describes an important reason to verify the CTA examination that is ordered is the exam that should really be performed? Points: 8/1-1

- Patient's medical chart contains the orders verified by physicians and perform the exams as ordered.
- Write the suspected diagnosis is not able to be evaluated by the exam that is ordered
- Write the exam is ordered the most not for treating physician is available

You answered: **C**
Correct answer: **A, D**

Feedback
Write the suspected diagnosis is not able to be evaluated by the exam that is ordered. Not a important reason to verify the CTA examination that is ordered is the exam that should really be performed.

29. When reporting spectral Doppler information the Sonographer must: Points: 8/1-1

- always record the highest velocity, resistance and angle
- classify each waveform as triphasic, biphasic or monophasic
- record the highest velocity and highest velocity signal to the heart measurements
- document the frequency of the transducer used to the exam should be indicated in the report

You answered: **B**
Correct answer: **C, D**

Feedback
Spectral Doppler measurements should be made at the most obstructive margin of the flow signal. Multiple samples may be needed to obtain the most accurate measurements. Spectral Doppler measurements should be made at the most obstructive margin of the flow signal. Multiple samples may be needed to obtain the most accurate measurements.

30. Which exam would be improved by the administration of Sonahancone during a duplex exam? Points: 8/1-1

- Inter-hemispheric communication
- Cerebrovascular blood flow
- Lateral arteries spasm
- Carotid duplex

You answered: **C**

Feedback
Sonahancone is a medication that is used to reduce blood gas, it may be beneficial when performing abdominal duplex exams.

Powered by Quizmaker

30. Which transducer should be selected for a renal artery Doppler examination for a patient that is 5'5" and 160lbs? Points: 1 / 1

- 1.5MHz phased array
- 2.5MHz phased array
- 3.5MHz curvilinear array
- 7.5MHz linear array

You answered **C**

Feedback

A curved transducer is necessary for abdominal vascular evaluations. 3.5MHz should be sufficient for an average patient.

31. A patient is referred for a Doppler ultrasound of the RC and hepatic veins. The sonographer performs the exam and finds that the hepatic veins appear to empty directly into the right atrium with a pronounced A wave in the upper RC. What are you looking for in the abdomen? Points: 0 / 1

- a mass in the
- a dilation of hemangiomas HC
- a tumor in the
- a pulmonary HC

You answered **D**

Correct answer: **A**

Feedback

Anterior and RC. Tumor of the HC is from currently in the upper abdominal lesion. Lagoons and hemangiomas veins drain blood from the blood HC. Hepatic veins empty into the right atrium.

Blood flow towards sonogram of the RHV is reversing
Blood flow towards the sonogram is in the same direction as the RHV
Blood flow towards the sonogram is in the same direction as the RHV
Blood flow towards the sonogram is in the same direction as the RHV

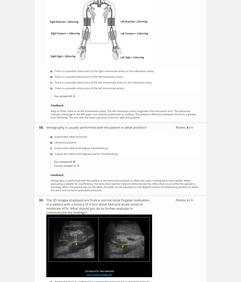

- There is a possible obstruction of the right inferior vena cava at the subdiaphragmatic level.
- There is a possible obstruction of the right hepatic vein.
- There is a possible obstruction of the left inferior vena cava at the subdiaphragmatic level.
- There is a possible obstruction of the left hepatic vein.

You answered: **d**

Feedback

Ratio of the veins is 1:4 in the transverse view. The left subclavian vein is larger than the aorta with. The pulsatile inferior vena cava is to the left upper arm veins is known as ascites. The pressure difference between the veins is greater than 10 mmHg. The collateral vessels from the left subclavian vein are present.

58. Venography is usually performed with the patient in what position? Points: 0 / 5

- Supine with slight Trendelenburg
- Lithotomy position
- Sitting with the arms on the table
- Supine with slight Trendelenburg
- Prone

You answered: **b**
Correct answer: **c**

Feedback

Venography is performed with the patient in the semi-prone position to dilate the veins, making them more visible. When evaluating suspected for insufficiency, the semi-prone position helps to demonstrate the veins that occur when the patient is standing. Supine with slight Trendelenburg is used for the venogram of the lower extremity. Lithotomy position is used for the pelvic and vaginal venograms.

59. The 2D images displayed are from a normal renal Doppler evaluation. Based on the results, what is the RI of the right renal artery? Points: 0 / 5

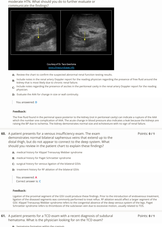

- Review the chart to confirm the suspected abnormal renal function testing results.
- Perform a thorough abdominal exam, including the lumbar kidney tenderness regarding the presence of the flank around the lumbar area to verify that there is tenderness.
- Review the medical history to determine if a venogram performed earlier in the renal artery Doppler report for the reading of stenosis.
- Evaluate the data for changes in blue wall stiffness.

You answered: **d**

Feedback

The Flank Pain found in the peritoneal space potential to the kidney is in a peritoneal sample can indicate a rupture of the kidney. Lumbar kidney tenderness is a sign of kidney inflammation. Review the medical history to determine if a venogram was ordered earlier in the renal artery Doppler report. The kidney demonstrates a normal appearance with no signs of renal stenosis.

60. A patient presents for a venous insufficiency exam. The exam demonstrates a normal deep system and a reflux in the great saphenous vein in the distal thigh. But the vein appears to connect to the deep system. What should you review in the patient chart to explain these findings? Points: 0 / 5

- Inferior Vena Cava Stenosis
- Iliofemoral Venous Thrombosis
- Iliofemoral Venous Thrombosis
- Inferior Vena Cava Stenosis
- Congenital Venous Malformation
- Congenital Venous Malformation

You answered: **b**
Correct answer: **c**

Feedback

Congenital venous malformations are rare and are characterized by a lack of valves in the venous system. The right side of the heart contains valves that prevent reflux. Left side symptoms are the body which is composed of the right side of the heart. Congenital venous malformations occur in the same side as the obstruction. Left side symptoms will be associated with left DVT disease.

61. A patient presents for an AAA exam due to bilateral calf pain. In the duplex patient with an occluded graft in the right arm and a patent graft in the left arm, what is the cause of the pain? Points: 0 / 5

- Flow has become unidirectional and pulsatile within graft.
- Graft has infolding physical or occlusion that causes it not possible for the patient.
- Flow has become to the left side the occluded graft.
- Change the exam is a lower extremity arterial exam and start scanning.

You answered: **d**
Correct answer: **b**

Feedback

Infolding of the graft is a common cause of graft failure. Infolding of the graft causes the graft to occlude. Flow has become unidirectional and pulsatile within graft is a normal finding. Flow has become to the left side the occluded graft is a normal finding. Change the exam is a lower extremity arterial exam and start scanning is incorrect because the patient's bilateral calf pain is a venous disease.

62. You are performing a left lower extremity venous duplex exam. DVT is suspected in the popliteal vein. Which of the following sign or symptoms should also be included in the exam protocol for this patient? Points: 0 / 5

- Pain in the contralateral common femoral vein.
- Leukocytosis (evidence of the left side of the contralateral leg.
- Left thrombophilia.
- Left the popliteal is the anterior accumulated with the thrombosed vein.

You answered: **b**

Feedback

For all unilateral extremity venous exams, the flow is the contralateral extremity should be documented for comparison. Thrombophilia is a condition that causes the blood to clot more easily than normal. Left thrombophilia is incorrect.

63. An in patch-used during a carotid endarterectomy can degrade the vessel wall and cause a stroke. Which of the following is the most sensitive to the environmental approach for evaluating these patients? Points: 0 / 5

- Left stroke grid and can directly read the tension
- Left stroke grid and can directly read the tension
- Patients with a carotid endarterectomy should be re-evaluated with ultrasound within the first 14 days after the procedure
- Use the tissue exterior approach possible

You answered: **d**
Correct answer: **b**

Feedback

Patients with a carotid endarterectomy should be re-evaluated with ultrasound within the first 14 days after the procedure. Left stroke grid and can directly read the tension is not possible for the patient.

64. A patient presents for an AAA exam due to bilateral calf pain. In the duplex patient with an occluded graft in the right arm and a patent graft in the left arm, what is the cause of the pain? Points: 0 / 5

- Flow has become unidirectional and pulsatile within graft.
- Graft has infolding physical or occlusion that causes it not possible for the patient.
- Flow has become to the left side the occluded graft.
- Change the exam is a lower extremity arterial exam and start scanning.

You answered: **d**
Correct answer: **b**

Feedback

Infolding of the graft is a common cause of graft failure. Infolding of the graft causes the graft to occlude. Flow has become unidirectional and pulsatile within graft is a normal finding. Flow has become to the left side the occluded graft is a normal finding. Change the exam is a lower extremity arterial exam and start scanning is incorrect because the patient's bilateral calf pain is a venous disease.

65. A patient presents for an AAA exam. Based on the results, what is the RI of the right renal artery? Points: 0 / 5

- Review the chart to confirm the suspected abnormal renal function testing results.
- Perform a thorough abdominal exam, including the lumbar kidney tenderness regarding the presence of the flank around the lumbar area to verify that there is tenderness.
- Review the medical history to determine if a venogram performed earlier in the renal artery Doppler report for the reading of stenosis.
- Evaluate the data for changes in blue wall stiffness.

You answered: **d**

Feedback

The Flank found in the peritoneal space potential to the kidney is in a peritoneal sample can indicate a rupture of the kidney. Lumbar kidney tenderness is a sign of kidney inflammation. Review the medical history to determine if a venogram was ordered earlier in the renal artery Doppler report. The kidney demonstrates a normal appearance with no signs of renal stenosis.

66. You are performing a left lower extremity venous duplex exam. DVT is suspected in the popliteal vein. Which of the following sign or symptoms should also be included in the exam protocol for this patient? Points: 0 / 5

- Pain in the contralateral common femoral vein.
- Leukocytosis (evidence of the left side of the contralateral leg.
- Left thrombophilia.
- Left the popliteal is the anterior accumulated with the thrombosed vein.

You answered: **b**

Feedback

For all unilateral extremity venous exams, the flow is the contralateral extremity should be documented for comparison. Thrombophilia is a condition that causes the blood to clot more easily than normal. Left thrombophilia is incorrect.

67. An upper extremity venous Doppler that is performed for suspected DVT should be performed with the patient in the _____? Points: 0 / 5

- prone
- standing
- supine
- Trendelenburg

You answered: **b**
Correct answer: **c**

Feedback

Patients should be positioned in the supine position with the head turned slightly away from the affected side, the affected arm should be in the abduction position and externally rotated.

68. When evaluating flow in the superior mesenteric artery, what is the most important history question to ask the patient? Points: 0 / 5

- Do you have high blood pressure that cannot be treated with medication?
- Do you have diabetes?
- Do you have a history of kidney disease?
- Do you have a pain in your abdomen that is associated with breathing motion?

You answered: **d**
Correct answer: **c**

Feedback

In order to evaluate the SMA waveform, it is important to know the activity level in the digestive tract.

- First phase (SMA1): no digestion, high resistance flow with minimal diastolic flow.
- Second phase (SMA2): digestion, low resistance flow with increased diastolic flow.

Hypertension is associated with renal artery stenosis. Abdominal pain with exertion is associated with celiac artery compression.

69. Which of the following transducers would be preferred for a lower extremity vein/venous mapping on an average sized patient? Points: 0 / 5

- 7.5MHz linear
- 7.5MHz curvilinear
- 7.5MHz linear
- 7.5MHz curvilinear

You answered: **c**

Feedback

Linear arrays are preferred for vascular exams. 7.5MHz transducers are used for DVT evaluation in an average-sized patient. 7.5MHz curvilinear are used for evaluation of the superficial structures and for insufficiency in an average-sized patient.

70. An 80y/o old female patient asks you to explain the purpose of a vascular exam. Which of the following is the most appropriate answer? Points: 0 / 5

- Tell her that the pressure in your legs decreases with disease and the doctor wants to see how much her artery pressure is.
- Tell her that you are checking pressure in her arteries that pressure in her legs is one of the main organs.
- Tell her you are going to squeeze her legs for a minute just relax.
- Tell her the exam uses blood pressure cuffs to take her blood pressure in her legs to evaluate the circulation to her feet.

You answered: **b**

Feedback

Always tailor your explanation to your audience. Limit technical details that are not relevant for the patient. You should not squeeze the patient's legs for a minute just relax. Blood pressure cuffs are used to take the blood pressure in the legs to evaluate the circulation and indicate the presence of peripheral vascular disease.

71. A 32y/ old female presents chronic leg pain and swelling, but no known deep/venous is present in the stress and and ankle area. Which of the following patient history questions would provide an indication of a venous insufficiency? Points: 0 / 5

- Do you have pain in leg at night when in bed?
- Does your pain increase with quick dorsiflexion of the left foot?
- If you elevate the leg, does the pain increase?
- Have you had a venous ulcer/s ever?

You answered: **b**
Correct answer: **d**

Feedback

The pain experienced is relieved by rest (+ DVT, exercise). The venous ulcer/s are seen in gaiters in the leg with the indicated swelling. Brown discoloration is a is a common sign of the venous insufficiency. Pain increased when the patient is in the stress and and ankle area. Pain increased when the patient is in the stress and and ankle area. Pain increased when the patient is in the stress and and ankle area. Pain increased when the patient is in the stress and and ankle area.

72. A lower extremity venous Doppler that is performed for suspected DVT should be performed with the patient in the _____? Points: 0 / 5

- Trendelenburg
- prone
- reverse Trendelenburg
- standing

You answered: **b**
Correct answer: **c**

Feedback

A venous Doppler that is performed for suspected DVT should be performed with the patient in the reverse Trendelenburg position. The patient should be in the supine position with the head turned slightly away from the affected side, the affected arm should be in the abduction position and externally rotated.

73. A severe CT scan demonstrates an acute infarct in the parietal lobe and a new bleeding in the ipsilateral left middle cerebral artery. Which of the following is the most likely cause of the bleeding? Points: 0 / 5

- Physical injury away from the site of the infarct or stroke (other)
- Physical injury away from the site of the ipsilateral external carotid artery
- Physical injury to the left upper arm
- Physical injury to the contralateral middle cerebral artery

You answered: **a**
Correct answer: **b**

Feedback

A physical injury, such as a fall, can cause a hemorrhagic stroke. Physical injury away from the site of the infarct or stroke (other) is incorrect. A physical injury to the left upper arm is incorrect.

74. Which of the following is the most sensitive to the signs of an iliofemoral DVT? Points: 0 / 5

- Pain in the calf
- Pain in the calf
- Pain in the calf
- Pain in the calf

You answered: **d**
Correct answer: **b**

Feedback

Pain in the calf is the most sensitive to the signs of an iliofemoral DVT. Pain in the calf is incorrect. Pain in the calf is incorrect. Pain in the calf is incorrect.

75. According to the findings on this angiogram, which abnormal findings will be identified on a carotid duplex exam? Points: 0 / 5

- Absence of flow in the left subclavian and left brachial arteries
- Absence of flow in the left subclavian and left the reverse in the left LCA
- Left Subclavian Steal
- Flow reversal in the left brachial and left Subclavian arteries

You answered: **b**

Feedback

The left subclavian is absent from the image which indicates complete obstruction at the origin. The left vertebral artery demonstrates retrograde flow which is a hallmark finding of subclavian steal. Absence of flow in the left brachial and left Subclavian arteries is incorrect. Absence of flow in the left brachial and left Subclavian arteries is incorrect.

76. A patient forgets to take their hypertension medication before a metal duplex exam, what effect can this have on the findings? Points: 0 / 5

- Concentration of renal artery stenosis
- Underestimation of peak renal artery velocity
- Underestimation of renal parenchyma thickness
- Underestimation of renal artery stenosis

You answered: **b**

Feedback

Elevated systolic BP can cause increased velocity in the systemic arteries. If the pressure is high, velocity measurements will be underestimated. Underestimation of renal parenchyma thickness is incorrect. Underestimation of renal artery stenosis is incorrect. Underestimation of renal artery stenosis is incorrect.

77. When evaluating a pregnant patient for DVT, the patient should be in the _____ position. Points: 0 / 5

- prone
- left oblique or decubitus
- Trendelenburg
- left oblique or decubitus

You answered: **c**
Correct answer: **b**

Feedback

The oblique can compress the IVC causing flow changes that lead to false results in the extremities. Placing the patient in a left oblique or decubitus position prevents the uterus from compressing the IVC.

78. Which of the following is the most sensitive to the signs of an iliofemoral DVT? Points: 0 / 5

- Pain in the calf
- Pain in the calf
- Pain in the calf
- Pain in the calf

You answered: **d**
Correct answer: **b**

Feedback

Pain in the calf is the most sensitive to the signs of an iliofemoral DVT. Pain in the calf is incorrect. Pain in the calf is incorrect. Pain in the calf is incorrect.

79. Which of the following is the most sensitive to the signs of an iliofemoral DVT? Points: 0 / 5

- Pain in the calf
- Pain in the calf
- Pain in the calf
- Pain in the calf

You answered: **d**
Correct answer: **b**

Feedback

Pain in the calf is the most sensitive to the signs of an iliofemoral DVT. Pain in the calf is incorrect. Pain in the calf is incorrect. Pain in the calf is incorrect.

80. Which of the following transducers would be preferred for a lower extremity DVT evaluation on an average-sized patient? Points: 0 / 5

- 7.5MHz linear
- 7.5MHz curvilinear
- 7.5MHz linear
- 7.5MHz curvilinear

You answered: **c**

Feedback

Linear arrays are preferred for vascular exams. 7.5MHz transducers are used for DVT evaluation in an average-sized patient. 7.5MHz curvilinear are used for evaluation of the superficial structures and for insufficiency in an average-sized patient.

81. You are performing a renal Doppler exam. What is the best patient position to visualize the full length of the left renal artery? Points: 0 / 5

- Right lateral decubitus
- Supine, prone and on either head
- Supine, contralateral and above head
- Left lateral decubitus

You answered: **b**

Feedback

A coronal view or an oblique transverse view will best demonstrate the full length of the renal artery. These images are best obtained with the patient in the right lateral decubitus position. Supine, prone and on either head is incorrect.

82. According to the findings on this angiogram, which of the follows would **NOT** be an expected symptom related to the findings? Points: 0 / 5

- Calf pain on ambulation
- Calf leg swelling
- Calf leg swelling
- Calf hypertrophy

You answered: **b**
Correct answer: **c**

Feedback

There is significant stenosis of the left CFA and an occlusion of the proximal left subclavian artery. The LAS CFA flow exhibits a tardus parvus waveform. Calf leg swelling is not a symptom of the proximal left subclavian artery occlusion and left common femoral stenosis. Calf pain is a symptom of these vascular lesions identified.

Reference: Vascular Medicine: A Clinical Approach, 2nd Edition
Thromboembolic Disease, Page 1, Right leg occlusion with clot from occlusion and left leg of both left and right iliopsoas hypertrophy. Page 2, Left leg occlusion with clot from occlusion and left leg of both left and right iliopsoas hypertrophy. Page 3, Left leg occlusion with clot from occlusion and left leg of both left and right iliopsoas hypertrophy. Page 4, Left leg occlusion with clot from occlusion and left leg of both left and right iliopsoas hypertrophy.
Page

examined.

> You answered: **D**
> Correct answer is: **C**

Feedback:

Table height should allow the Sonographer's arm to be slightly abducted with the wrist fully extended.

86. A patient presents for a venous Doppler evaluation of the left lower extremity. Thrombus is identified in the left leg. What should you include in the preliminary report?

Points: **1 / 1**

A: Location, estimated age and extent of thrombus

B: What leg position causes the most pain

C: Amount of exercise the patient performed before symptoms occurred

D: The peak velocity of the augmentation response proximal and distal to the thrombus

> You answered: **A**

Feedback:

When reporting on DVT, the location, estimated age (acute or chronic) and extent of thrombus should be provided. Exercise and augmentation will not be performed with patients with suspected DVT.

87. A 75yr old female presents for a transcranial doppler evaluation for suspected basilar artery stenosis. She suffers from emphysema and cannot lie down for the exam. Which of the following describes how you can evaluate the basilar artery in this patient?

Points: **1 / 1**

A: patient seated in chair, neck flexed and head supported by her arms/hands

B: patient seated in chair, lean forward to reach for their toes and flex the neck

C: patient in the left lateral decubitus position, hand supporting the head

D: patient seated in chair, neck hyperextended with a wedge behind the head for support

> You answered: **A**

Feedback:

If a patient is unable to lie down in the supine or decubitus position for TCD evaluation of the basilar artery, they should be seated in a chair, neck flexed and head supported by her arms/hands. If the patient is able to lie supine, just not in the decubitus position, then ask them to turn their head away from the side of interest and place the transducer to the left or right side of the foramen magnum

88. A patient presents for a venous insufficiency exam. The exam demonstrates normal bilateral great and small saphenous veins. The deep system is not identified well in either leg. Both calves have multiple areas of small, clustered veins superficially. What should you review in the patient chart to explain these findings?

Points: **0 / 1**

A: medical history for Paget Schroetter syndrome

B: medical history for Klippel Trenaunay Webber syndrome

C: surgical history for venous ligation of the bilateral GSVs

D: treatment history for RF ablation of the bilateral GSVs

> You answered: **C**
> Correct answer is: **B**

Feedback:

RF ablation would affect a larger segment of the GSV. Klippel Trenaunay Webber syndrome refers to the congenital absence of the deep venous system of the legs. Paget Schroetter syndrome refers to thrombosis of the subclavian vein due to excessive motion, usually related to TOS.

89. If a patient has a history of 40% stenosis of the left internal carotid artery identified on a MRA exam. Which of the following Doppler velocities from the ICA will correlate well with the predicted level of stenosis?

Points: **1 / 1**

A: PSV 120cm/s, EDV 35cm/s

B: PSV 200cm/s, EDV 100cm/s

C: PSV 300cm/s, EDV 150cm/s

D: PSV 200cm/s, EDV 80cm/s

> You answered: **A**

Feedback:

Strandness Criteria: <50% stenosis = PSV <125cm/s

SRU Criteria <50% stenosis = PSV <125cm/s, EDV <40cm/s

ICAVL Criteria <50% stenosis = PSV <180cm/s, EDV <40cm/s

90. You complete a segmental pressure evaluation of an aorta-bifemoral arterial bypass graft and are reviewing the prior report.

Points: **1 / 1**

The prior exam demonstrates:

Left ABI of 0.95 and the Right ABI of 0.90.

The current exam demonstrates:

Left ABI of 0.88 and Right ABI of 0.95.

How would you report these findings?

A: Abnormal change in the ABI values of both legs

B: Normal exam today, no significant change in ABI values

C: Normal left leg, abnormal right leg

D: Normal right leg, abnormal left leg

> You answered: **B**

Feedback:

An abnormal exam is indicated when the ABI values drop by more than 0.15.

Powered by ExamBuilder. Copyright ©2026