Summary

Link to repository:

https://github.com/dino-saur099/2026_PDS_C

GitHub usernames:

dino-saur099 → Emma Jacques Dupont

davidmo1995.dot → David Moreno Ollero

vemi-chy → Verokina Michálková

ektu7 → Ekramul Hasan Tuhin

nool_ITU → Nor Kudahl Olesen

Research-paper Overview

The research paper focused on the six most common skin lesions detected. These six consist of three types of skin cancers (BCC, MEL and SCC) and three types of skin diseases (ACK, NEV, and SEK). We are provided a table, that shows the representation of each type of skin lesion in the dataset. Approximately 53% of the samples are skin diseases and 47% samples of the samples are skin cancers. Notably, only 52 out of 2298 samples are Melanoma, making this skin cancer underrepresented in the dataset.

There are in total 1373 patients, 1641 skin lesions and 2298 images in the dataset. In the dataset a patient may have one or more skin lesions, and a skin lesion may have 1 or more pictures, which explains the different numbers. The images are taken with smartphones, so quality and lighting may differ between the different images.

Images were deleted during quality control if, a patient could be identified (tattoos), the quality of the pictures were too poor or if the lesion was covered by something.

The metadata associated with the skin lesions has in total 26 attributes, 21 of which are patient clinical features. The values for the attributes ‘patient_id’, ‘lesion_id’, ‘img_id’, ‘age’, ‘region’, and ‘biopsied’ are always present. All patients are from Brazil, and many patients are European descendants, and the average patient is 60 years old.

All 100% of cancerous skin lesions have been biopsy-proven, but only 58% of all skin lesions, including the cancerous skin lesions, are biopsy-proven

This dataset is intended for research in computer-aided diagnosis, medical image analysis, and dermatological classification and has been made public in support to future research and development in making new tools to detect skin cancer, in particular to train CAD systems. Since there is a lack in public clinical images available to test these CAD systems, the dataset aims to support the development of the CAD systems for skin lesion classifications.

Characteristics for skin diseases (all information gathered from Mayo Clinic):

Basal Cell Carcinoma (BCC)[1]

- A shiny skin-colored bump
- A brown, black or blue lesion
- A flat, scaly patch
- A white, waxy scarlike lesion

Squamous Cell Carcinoma (SCC)[2]

- A flat sore with scaly crust
- A new sore or raised area on an old scar or sore
- A rough scaly patch on the lip
- Bowen's disease is considered SCC in situ, so they are clustered together with Squamous Cell Carcinoma. This is stated in the research-paper

Malignant Melanoma (MEL)[3]

- Asymmetrical shape
- Change in original color of mole
- Change in original size of mole
- A mole with notched or scalloped borders

---

[1] https://www.mayoclinic.org/diseases-conditions/basal-cell-carcinoma/symptoms-causes/syc-20354187
[2] https://www.mayoclinic.org/diseases-conditions/squamous-cell-carcinoma/symptoms-causes/syc-20352480
[3] https://www.mayoclinic.org/diseases-conditions/melanoma/symptoms-causes/syc-20374884

Actinic Keratosis (ACK)[4]

- A rough, dry or scaly patch of skin
- Itching, burning, bleeding or crusting of the skin lesion
- A flat to raised bump on sun-exposed skin

Melanocytic Nevus (NEV)[5]

- Commonly known as a mole
- A round or oval shape
- Typically about 6 mm in size

Seborrheic Keratosis (SEK)[6]

- Itching
- A waxy or rough bump
- Size can vary from very small to 2.5 cm
- Number of growths can range from a single growth to multiple growths

Subset analysis and observations

We have a subset of the metadata consisting of 117 patients, 117 pictures and 117 masks.

The distribution of the different diagnostics in our subset looks like:

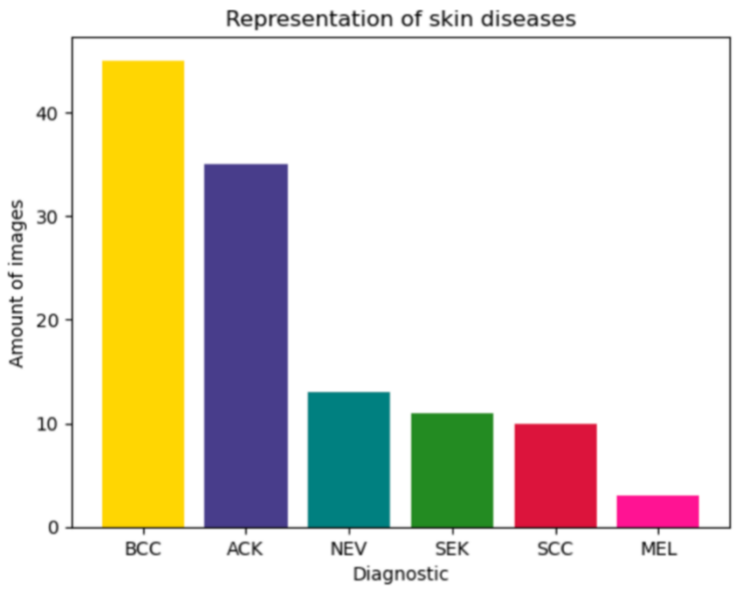

[4] https://www.mayoclinic.org/diseases-conditions/actinic-keratosis/symptoms-causes/syc-20354969
[5] https://www.mayoclinic.org/diseases-conditions/moles/symptoms-causes/syc-20375200
[6] https://www.mayoclinic.org/diseases-conditions/seborrheic-keratosis/symptoms-causes/syc-20353878

Where out of 117 diagnostics only 3 patients are diagnosed with melanoma, so if we only take this subset into account, we will have a high possibility of misrepresenting melanoma.

We have a representation of 59 non-cancerous skin lesions and 58 cancerous lesions, so there is an almost equal distribution of cancerous and non-cancerous skin lesions. It is only on the individual types of skin lesions, where there is a more non-equal distribution.

Image overview

Mask

All images that we are provided with has corresponding masks

Examples of ill-fitting masks:

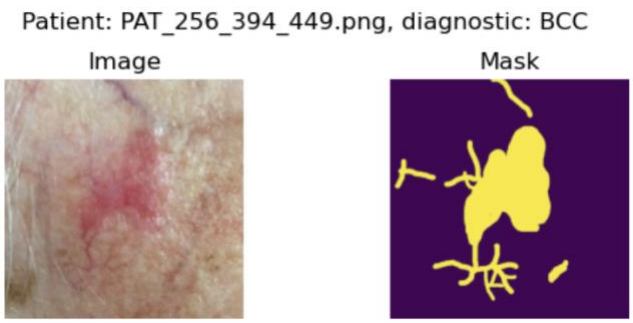

For this image, it looks like the mask took the veins into account as a part of the skin lesion. This causes the mask to possibly misrepresent the lesion and therefore can introduce segmentation noise, which could cause a misdiagnostic.

Wrinkles on the forehead could have obscured the mask, such that the mask representing the picture isn't a correct representation. This could introduce segmentation noise, which could cause a misdiagnostic.

Annotations

Hair annotations

Some images were interpreted differently depending on how each of us evaluated the visible hair structures. In most cases, however, we reached general agreement.

Example of an Image with Discrepancies

- PAT_665_1262_774.png – One person annotated 0, one annotated 2, and the others annotated 1

Main Reason for Discrepancies:

In general, the differences in annotations (0 vs. 1), (1 vs. 2), and (2 vs. 3) are not considered significant, as they mainly reflect subjective interpretation of the images.

In all cases, the majority decision will prevail.

Pen marks

Examples of Images Where a Change Was Recorded

- PAT_479_919_97.png – Nor chose 1, others chose 0
- PAT_1257_887_828.png – Veronika chose 1, others chose 0
- PAT_400_801_376.png – Nor and Veronika chose 1, others chose 0
- PAT_279_430_356.png – Nor chose 1, others chose 0
- PAT_541_3303_228.png – Veronika chose 0, others chose 1
- PAT_156_241_538.png – Veronika chose 0, others chose 1
- PAT_128_194_144.png – Veronika chose 0, others chose 1

The primary reason we often disagreed by one degree was due to an optical illusion. In many images, a vein was maybe more colored, creating the impression that it was a pen mark, even though it was not. After detailed consultation, we will naturally lean toward the majority opinion.

Observed patterns in characteristics of pictures of cancerous lesions

This section should highlight some patterns observed in the group's subset of the data set that presumably affect conclusions about correlation.

ABCD(E)

The ABCDE factors are of course expected to affect the correlation as these are medically indicative signs of cancerous skin lesions.

However, what should be made a note of is that whilst the metadata accounts for E (through the boolean for "grew" in the metadata), the images are stills and naturally do

not signify evolution. This means that ABCD can be represented with more nuance from the images rather than only from the metadata like E where it is also a binary value.

Surrounding skin

If disregarding the factor of age from the metadata, characteristics of the skin surrounding the lesion like wrinkles, grey hair, and discoloration are expected to affect correlation as these are indicative of older age.

Penmarks

The presence of penmarks may have an effect on the correlation since this would indicate medical attention.