Dental Beat

Imparting Knowledge

ISSUE:- April 2026 : Edition 8; Volume 1

Publication of

INDIAN DENTAL ASSOCIATION
MUMBAI WEST SUBURBAN BRANCH

DR. SORABH JAIN
EDITOR

@IDAMWSB www.idamwsb.com

Next Page

GENERAL INFORMATION

Dental Beat is the official magazine of IDA Mumbai West Suburban Branch (IDA MWSB), focusing on clinical cases, reviews, and research relevant to clinicians. Contributions from IDA MWSB members and dental colleges across India are encouraged.

Distribution Information

The digital magazine is distributed free to IDA MWSB members via WhatsApp. No printed copies are available. Members must keep their contact details updated for smooth communication.

Advertising Policy

Advertisements not aligned with the magazine's policies may be rejected. Ads do not imply endorsement by the magazine or publisher regarding the product's quality or claims.

Disclaimer

Opinions in articles and ads are those of the authors and advertisers, not the Editor or Publisher. The Editor and Publisher are not responsible for the authenticity of content, patient image consent etc and authors/advertisers bear full responsibility.

Copyright Assignment

Authors assign all rights of published articles to *Dental Beat*. For inquiries, contact the Editorial Office.

Editor: Dr. Sorabh Jain

Indian Dental Association
Mumbai West Suburban Branch

TABLE OF CONTENTS

Contents	Page Nos
From the Editor's Desk	4
List of Office Bearers for IDA-MWSB 2025	5
Announcements	6
Balancing Finances During Slack time – Mrs. Lata Shetty	7
Quiz Time – Dr. Surya Vamshi N.	9
Case Report Competition- Clinical management of perforation – a case series - Unmesh Kutwad, Girish Umashetty, Santosh Hugar	11
Pearls of Wisdom - Dr. Viral Parikh	16
Multidisciplinary Management of Previously Failed Endodontic and Aesthetic Treatment of a Maxillary Central Incisor – Dr. Harsh Haren Shah, Dr. Jigna Sanghavi	17
The Intraoral Scanner Dilemma: My 18 months update– Dr. Puneet Thirani	22
Non Dental Communication – Dr. Chirag Bhalu	25
Fluoride varnishes: should we be using them? – Dr. Abhishek Bhattacharya	26
Know Your Office Bearer – Dr. Yuga (Naik) Desai	28
CDH Activity – Dr. Jasmit Desai	29
Become IDA - MWSB Member	30
Yoga – Dr. Amruta Wadekar	31
Thank you	32

From the Editor's Desk

Dear Readers,

Welcome to the April edition of Dental Beat! This month's issue brings together clinical excellence and real-world practice wisdom. From managing endodontic perforations and failed anterior aesthetics to decoding fluoride varnishes and digital scanner dilemmas—each article offers valuable insights. Don't miss our piece on financial strategies during slower clinical periods.

We're also thrilled to share the successful completion of Dental Aura 2025—a celebration of knowledge, innovation, and collaboration. Kudos to everyone who made it a memorable event!

A special thanks to our President, Dr. Amruta Wadekar, Secretary, Dr. Pratibha Shetty, and the IDA-MWSB team for their unwavering support. And, as always, deep appreciation to my co-editor, Dr. Yuga Desai, for her dedication and effort.

Thank you for being part of this journey—stay inspired and stay connected!

Warm regards,

Dr. Sorabh Rakesh Jain

MDS Prosthodontist

Editor - IDA-MWSB

For further info, Connect us at:

+91-7303302651; doctorsorabhjain@gmail.com

Timing Matters: Objective Reduction of Disclusion Time in Myogenous Temporomandibular Disorder

audio description to the abstract

Listen totthe abstract

Dr. Sorabh R Jain MDS Prosthodontist.

Introduction:

Temporomandibular disorders (TMDs) affect approximately 5–12% of adults, with peak prevalence in women between 20 and 40 years of age.[1 2] TMDs are multifactorial and may involve muscular, intracapsular, neurologic, and psychosocial components.

Myogenous TMD is characterized by masticatory muscle pain in the absence of primary intracapsular pathology.[3] Disc displacement with reduction may coexist with joint noise but does not inherently require intervention unless associated with pain or dysfunction.

Current consensus emphasizes conservative management, reserving irreversible procedures for carefully selected cases.[4 5] The relationship between occlusion and TMD remains controversial; however, prolonged posterior contact during excursions (disclusion time) has been associated with increased elevator muscle activity.[8 10]

Traditional occlusal analysis methods (articulating paper, shimstock) are qualitative. Computerized occlusal analysis allows quantification of:

Occlusion time (OT)

Disclusion time (DT)

Force distribution

Center-of-force trajectory

When synchronized with electromyography (EMG), functional occluso-muscular relationships may be evaluated.[9]

This report presents a patient with myogenous TMD without arthralgia, where prolonged disclusion time was identified and modified using computerized occlusal analysis.

Case report:

A 32-year-old female presented with a 8 years history of intermittent right preauricular clicking and episodic discomfort during wide opening. She reported that her bite felt unstable following prior orthodontic therapy (Invisalign done in 2017-2018). Symptoms were intermittent over 8 years without progression to locking or persistent pain.

No significant psychosocial stressors were reported during evaluation.

Clinical Examination

No history or clinical signs suggestive of systemic inflammatory joint disease were identified.

- Maximum opening: 45 mm
- Deviation toward left at ~32 mm
- Audible right joint click & not associated with pain.
- No locking history
- No crepitus
- No persistent arthralgia
- Joint capsule palpation: Negative bilaterally
- Joint loading test: Negative
- Muscle palpation revealed:

- Bilateral lateral pterygoid tenderness (3/3 initially)
- Temporalis tendon tenderness
- Referred cervical discomfort

➢ Cotton roll disclusion reduced muscle tenderness, suggesting occluso-muscular contribution.
➢ No limitation of condylar translation observed clinically.
➢ The patient denied bruxism or clenching habits

Radiographic Findings

CBCT demonstrated:

- Preserved joint spaces. Superior and posterior joint spaces appeared preserved and symmetric bilaterally.
- No erosion
- No osteophytes
- No degenerative changes

Therefore:

- No intracapsular inflammatory pathology
- No degenerative joint disease
- No capsulitis
- No retrodiscitis

Joint noise fluctuated during neuromuscular relaxation but was not associated with pain.

Clinical examination revealed persistent posterior contacts during lateral excursions despite apparent canine guidance especially at all second molars.

So findings were consistent with DC/TMD Group I Myalgia without Arthralgia; joint noise present..

Diagnosis: **Myogenous TMD without arthralgia.**

Instrumented Evaluation

Synchronized T-Scan 10 and surface EMG were performed.
EMG electrodes were placed bilaterally over anterior temporalis and middle masseter muscles.

Diagnostic Sequence

1. Initial MIP and excursive recordings
2. 45-minute ULF-TENS
3. Repeat recordings
4. Selective enameloplasty
5. Final recordings

Baseline Occlusal Findings (Ref fig:- 1)

MIP:
Right: 62%
Left: 38%
OT: 0.15 sec
Left lateral DT: 2.33 sec
Right lateral DT: 2.29 sec
Physiologic DT reference: <0.5 sec.[8]
EMG showed elevated temporalis activity relative to masseter.

Post-TENS Findings (Ref fig:- 2)

No reproducible neuromuscular mandibular repositioning was observed, therefore orthotic repositioning therapy was not indicated.
OT: 0.16 sec
Force asymmetry persisted
Click intensity reduced transiently
No significant mandibular positional shift occurred.

Selective Occlusal Adjustment

Minimal enameloplasty (<0.5 mm per site) was performed on posterior cuspal inclines contributing to prolonged posterior contact during excursions.

Shimstock confirmed bilateral simultaneous MIP contact.

Post-Adjustment Findings (Ref fig:- 3-5)

MIP:- Right: 54.6% & Left: 45.4%

OT: 0.19 sec (Occlusion time remained within physiologic range following adjustment.) .[8]

Left DT: 0.27 sec **(Ref fig:- 4)**

Right DT: 0.66 sec **(Ref fig:- 5)**

EMG findings demonstrated redistribution of muscular activity rather than uniform reduction.

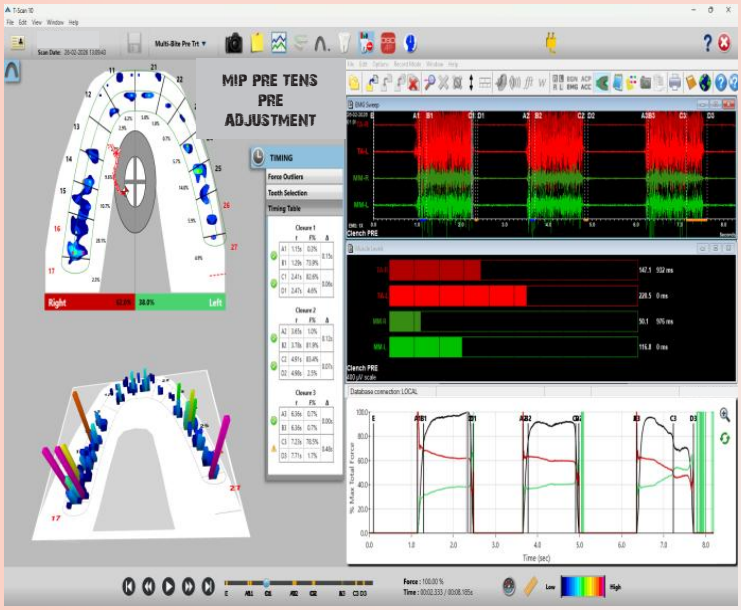

Figure 1. MIP Pre-TENS, Pre-Adjustment.
Three-dimensional force map demonstrating right-sided force predominance (62%) with posterior concentration.

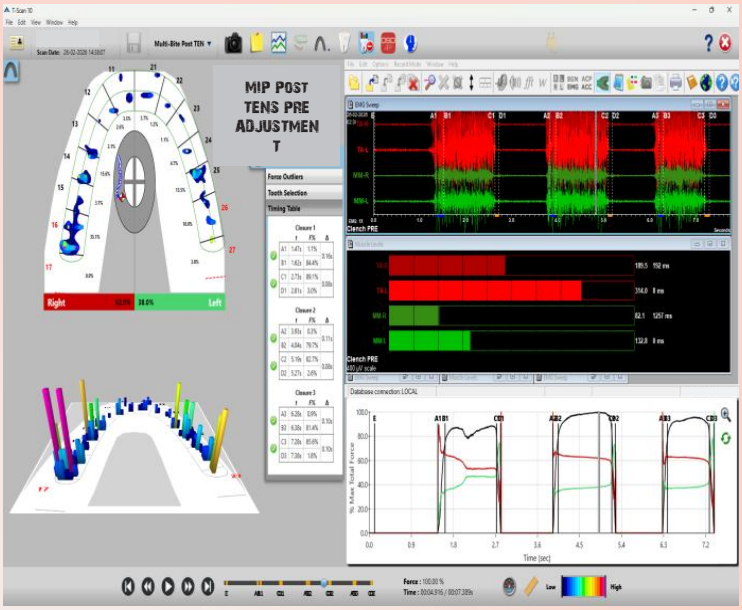

Figure 2. MIP Post-TENS, Pre-Adjustment.
Force distribution pattern similar to baseline despite neuromuscular relaxation.

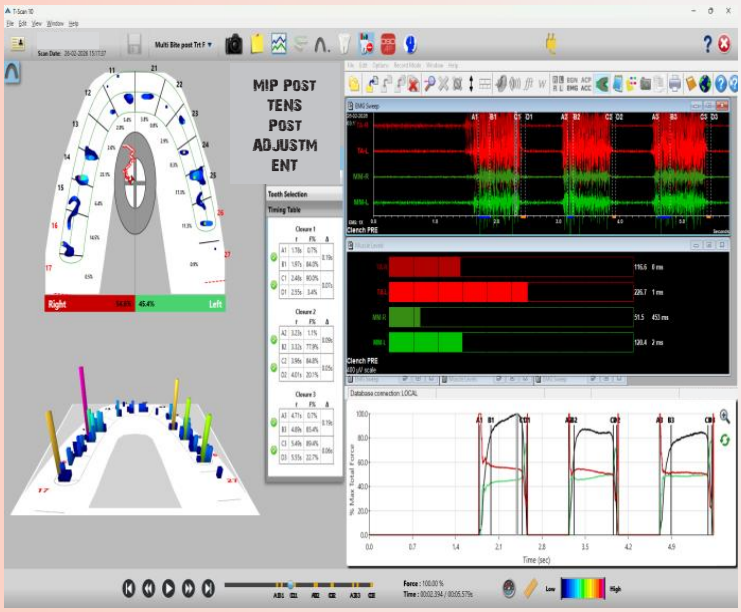

Figure 3. MIP Post-Adjustment.
Improved force symmetry toward midline.

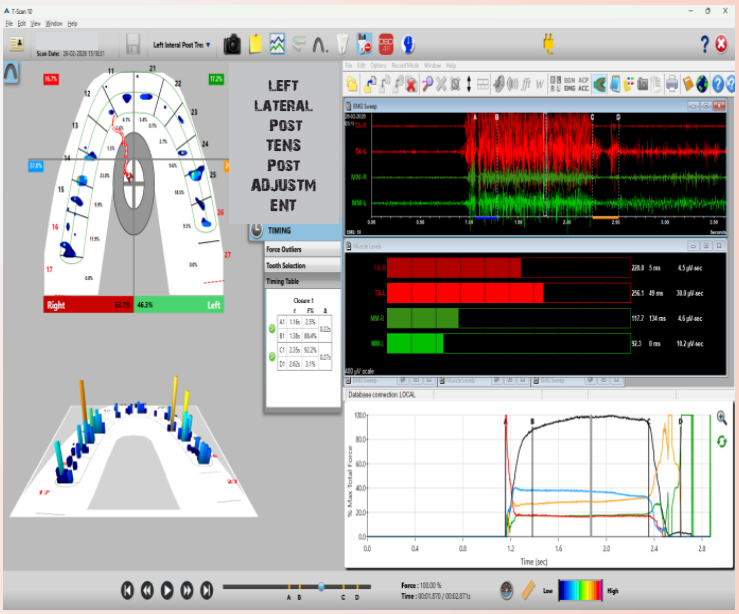

Figure 4. Left Lateral Post-Adjustment.
Marked reduction of disclusion time from 2.33 sec to 0.27 sec.

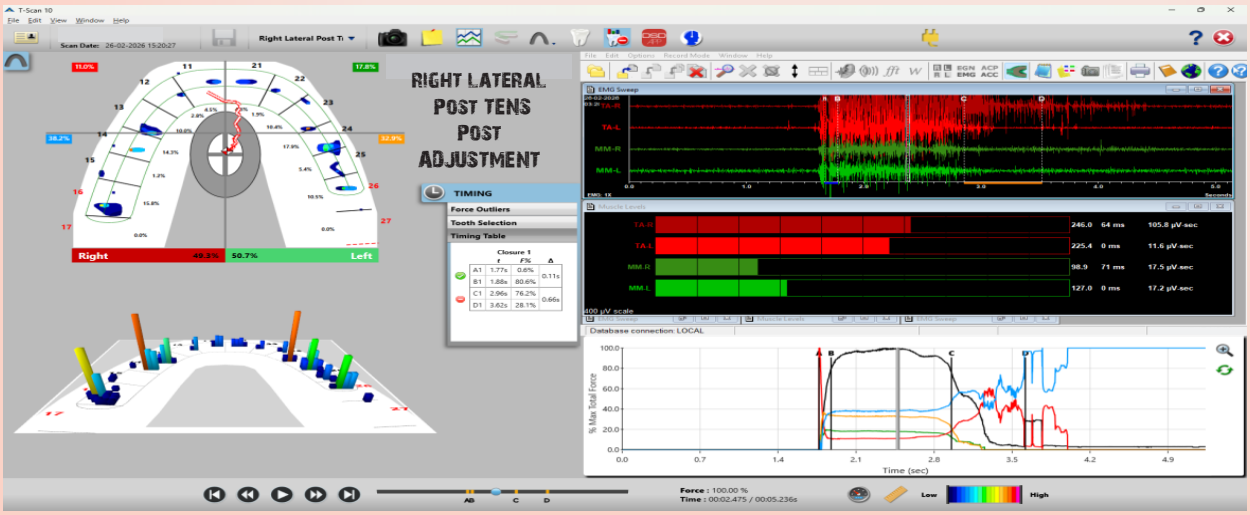

Figure 5. Right Lateral Post-Adjustment. Reduction in disclusion time with improved posterior separation

Figure 5. Right Lateral Post-Adjustment
Reduction in disclusion time with improved posterior separation

Surface Electromyographic Findings at Maximum Force (Point C)

Surface electromyographic peak amplitudes (µV) at maximum intercuspation (Point C) demonstrated modest redistribution of anterior temporalis and masseter activity following adjustment (TA-R: 83 µV pre-adjustment to 104.7 µV post-adjustment; TA-L: 122 µV to 165.8 µV). During left lateral excursion, a reduction in left temporalis hyperactivity was observed (TA-L: 282 µV to 195 µV), corresponding with significant reduction in left disclusion time. In right lateral excursion, right temporalis activity remained elevated (226 µV to 305 µV), consistent with residual right disclusion time of 0.66 seconds. These findings suggest partial neuromuscular adaptation corresponding with occlusal timing modification rather than uniform suppression of muscle activity.

Muscle tenderness decreased to 0–1/3 within 24 hours.

Deviation corrected, although not fully, but to a large extent the path is less curved, at maximum opening, consistent with functional disc coordination rather than persistent mechanical obstruction.

Short-term follow-up was limited to 7 days due to patient travel. At 7-day follow-up, occlusal stability and symptom reduction were maintained as reported by patient.

Discussion:

This case illustrates:

- Absence of arthralgia
- Absence of degenerative joint disease
- Negative loading tests
- No locking
- Fluctuating click influenced by muscle tone

These findings indicate a primarily **myogenous disorder** rather than intracapsular pathology.

The patient reported right-side dominant chewing, which may have contributed to asymmetric loading observed instrumentally.

Fluctuation of click intensity during neuromuscular relaxation suggests a functional muscular influence on disc-condyle coordination rather than fixed structural derangement.

Occlusal adjustment was considered only after reversible therapy and objective documentation of prolonged disclusion time exceeding physiologic norms.

The patient reported right-side dominant chewing, which may have contributed to asymmetric loading observed instrumentally.

Fluctuation of click intensity during neuromuscular relaxation suggests a functional muscular influence on disc-condyle coordination rather than fixed structural derangement.

Occlusal adjustment was considered only after reversible therapy and objective documentation of prolonged disclusion time exceeding physiologic norms.

Disclusion Time and Muscle Activity

Prolonged DT has been associated with increased elevator muscle contraction duration.[8 10] Reduction in DT may decrease cumulative muscular load.

In this case, left lateral DT reduction was substantial. Right lateral improvement was moderate but clinically meaningful. For Right lateral, Although Right Lateral disclusion time remained slightly above 0.5 seconds, further enameloplasty was not pursued to avoid excessive irreversible reduction given the absence of symptoms.

Prolonged posterior contact during excursions may increase elevator muscle contraction duration by delaying anterior guidance engagement, thereby increasing cumulative muscular load.[8 10]

Force Symmetry

Right-dominant occlusion (62/38) may promote asymmetric elevator recruitment. Redistribution toward 55/45 reduced imbalance.

Role of T-Scan

Computerized occlusal analysis provided:

- Quantifiable timing data
- Objective documentation
- Verification of post-adjustment outcomes
- Excursive timing assessment not possible with articulating paper alone

However, it was used selectively and only after conservative therapy.

This report does not propose occlusal adjustment as routine TMD therapy, but rather as a measured intervention in a patient with documented prolonged disclusion time and myogenous symptoms.

Limitations

- Single case report
- Short follow-up interval
- No long-term stability data

Findings from a single case cannot be generalized to all TMD presentations.

Conclusion

In a patient with myogenous TMD without arthralgia or degenerative joint disease, prolonged disclusion time was identified using computerized occlusal analysis. Selective, minimal enameloplasty reduced disclusion time and improved force symmetry, coinciding with reduction in muscle tenderness.

Computerized occlusal timing assessment may serve as a useful adjunct in selected cases of myogenous TMD where excursive timing abnormalities are identified.

References

1. Okeson JP. Management of Temporomandibular Disorders and Occlusion. 8th ed. Mosby; 2020.
2. Schiffman E et al. Diagnostic Criteria for TMD (DC/TMD). J Oral Facial Pain Headache. 2014.
3. Greene CS. The etiology of TMD. J Orofac Pain. 2001.
4. Klasser GD, Greene CS. J Can Dent Assoc. 2009.
5. Pullinger AG, Seligman DA. J Prosthet Dent. 2000.
6. Manfredini D et al. J Oral Rehabil. 2010.
7. Kerstein RB. Compend Contin Educ Dent. 2008.
8. Kerstein RB, Wright NR. Cranio. 1991.
9. Kerstein RB. Cranio. 2004.
10. Kerstein RB, Radke J. Cranio. 2012.
11. Dawson PE. Functional Occlusion. Mosby; 2007.

Dr. Sorabh Jain, MDS Prosthodontist, specializing in TMJ pain management and Dental Sleep Medicine, focused on comprehensive rehabilitation and functional stability.