Congenital anomalies of the ear, nose, paranasal sinuses, and soft and hard palate.

Name – Devi navadiya
Group – 16
Sem- 8th
Subject – ENT
Date- 17/03/2026

Index

- 1 – embryology of ear
- 2 – congenital abnormalities of external ear
- 3- congenital abnormalities of external auditory canal
- 4 – congenital abnormalities of middle ear
- 5- congenital abnormalities of external nose
- 6- congenital abnormalities of nasal cavity
- 7- congenital anomalies of paranasal sinus
- 8-Embryology of palate
- 9- cleft palate introduction
- 10- cleft palate types
- 11- cleft palate Clinical features
- 12- auditory system diagram
- 13- vestibular system diagram

Embryology of ear

- **External Ear**
- Develops from six auricular hillocks on the first and second pharyngeal arches.
- External auditory canal develops from the first branchial cleft.
- Middle Ear
- Derived from the first pharyngeal pouch.
- Ossicles originate from branchial arches:
- Malleus and incus → 1st arch
- Stapes → 2nd arch
- Inner Ear
- Develops from the otic placode → otic vesicle.

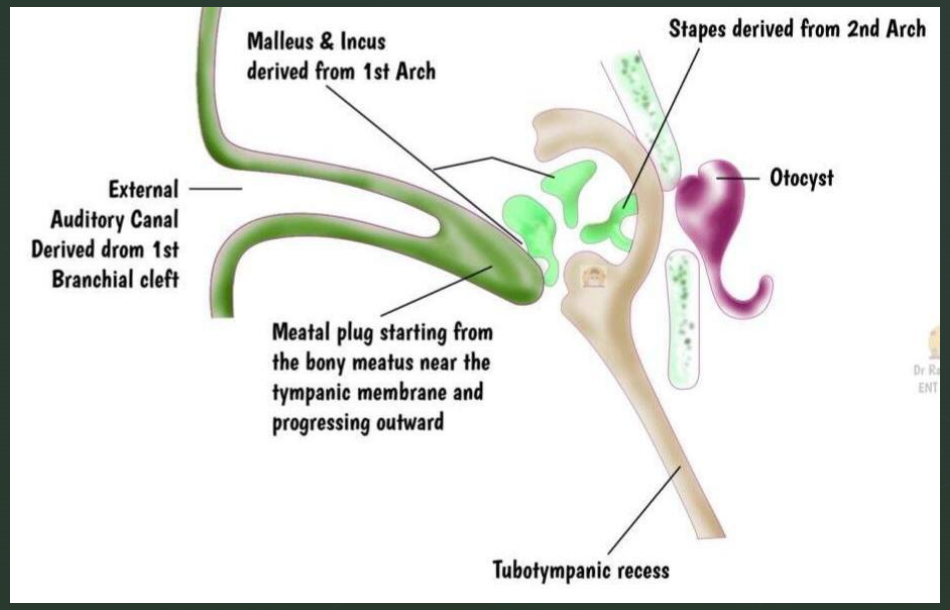

Congenital Anomalies of the External Ear

- A. Anotia. Complete absence of the auricle. (Severe conductive hearing loss)- management –Reconstructive surgery
- B. Microtia- Small or underdeveloped (T- oAuricular reconstruction)
- .Syndromes: Collins syndrome ,Goldenhar syndrome
- C. Prominent Ear (Bat Ear)- Most common congenital auricular deformity. (Otoplasty)
- D. Preauricular Sinus-Small congenital pit located anterior to the ear.(Small pit near tragus May become infected).
- E. Preauricular Tags (Accessory Auricles)- Small skin projections in front of ear.
- F. Macrotia- Abnormally large auricle.
- G. Cryptotia- Upper auricle buried under scalp skin.

Congenital Anomalies of the External Auditory Canal

Aural Atresia- Complete absence of the ear canal.

Types

Membranous atresia

Bony atresia

Clinical Features Conductive hearing lossOften associated with microtia

Diagnosis - CT scan of temporal bone,Audiometry

Treatment -Canal reconstruction,Bone conduction hearing devices

B. **Aural Stenosis**- Narrow ear canal.

Complications -Wax accumulatio, Hearing impairment. Risk of cholesteatoma

Congenital Anomalies of the Middle Ear

- A. Michel Aplasia- Complete absence of inner ear structures.
- B. Mondini Malformation -Incomplete cochlear development.Cochlea has 1.5 turns instead of 2.5,Congenital sensorineural hearing loss Cochlear implantation
- C. Scheibe Dysplasia -Malformation of cochlea and saccule.
- Congenital deafness
- D. Enlarged Vestibular Aqueduct – Common inner ear anomaly.
- Progressive hearing loss &Balance problems

Congenital Anomalies of the External Nose

- A. **Arhinia-** Complete absence of the external nose.Absence of nasal cavity ,Severe breathing difficulty in newborns
- B. **Hypoplasia of the Nose** -Underdeveloped nasal structuresSmall nose,Nasal obst..
- C. **Bifid Nose** Nose divided into two halves.Failure of medial nasal processes to fuse.
- Features -Wide nasal bridge,Midline nasal cleft
- D. **Proboscis Lateralis**-A tubular appendage resembling
- trunk located near the eye.
- Cause -Abnormal development of the nasal placode.

- E. **Nasal Dermoid** - Congenital midline cyst or sinus over the nose.
- Cause -Persistence of ectodermal tissue during development.

Congenital Anomalies of the Nasal Cavity

- A. Choanal Atresia -Failure of the posterior nasal aperture (choana) to open.
- Types -Bony atresia ,Membranous atresia ,Mixed type (most common)
- Bilateral choanal atresia: Cyanosis in newborn ,Difficulty breathing,Relief during crying
- Unilateral choanal atresia: Unilateral nasal discharge ,Nasal obstruction
- B. Congenital Nasal Stenosis- Narrow nasal passages due to bony narrowing.
- Types- Pyriform aperture stenosis &General nasal cavity narrowing
- C. Deviated Nasal Septum-
- Causes-Intrauterine pressure &Birth trauma
- Features- Nasal obstruction &Difficulty feeding in infants

Congenital Anomalies of Paranasal Sinuses

- A. Sinus Agenesis -Complete absence of one or more paranasal sinuses.
- Types -Frontal sinus agenesis (most common) ,Maxillary sinus agenesis,Sphenoid sinus agenesis
- Features-Usually asymptomatic ,Discovered incidentally on imaging
- B. Sinus Hypoplasia
- Underdevelopment or incomplete development of the sinus.Predisposes to sinus drainage problems
- Common Sites -Maxillary sinus ,Frontal sinus
- Features - Small sinus cavity & Reduced pneumatization
- C. Sinus Aplasia -Complete failure of sinus formation.
- Common Examples -Frontal sinus aplasia ,Sphenoid sinus aplasia

Embryology of the Palate

- **Primary Palate** -Develops from the intermaxillary segment (fusion of medial nasal prominences).
- Forms: Premaxilla &Alveolus containing incisors &Anterior hard palate
- **Secondary Palate** -Formed by palatine shelves of maxillary processes.
- These shelves: Grow vertically beside the tongue.
- Elevate to horizontal position.
- Fuse in the midline.
- Fuse with nasal septum and primary palate.
- Final Structures - Hard palate – anterior bony part.
- Soft palate – posterior muscular part with uvula.
- Critical Period -Development occurs between 6th–12th week of gestation.

Cleft palate

- A midline defect due to failure of fusion of palatal shelves, causing communication between oral and nasal cavities.
- Etiology -Genetic Factors ,Family history ,Chromosomal abnormalities
- Syndromes (e.g., Pierre Robin sequence, Treacher Collins syndrome)
- Environmental Factors -Maternal smoking ,Alcohol ,Radiation ,Drugs (phenytoin, retinoic acid) ,Maternal infections,Nutritional deficiency (folic acid)
- Types of Cleft Palate
- 1. Cleft of Soft Palate -Only the soft palate is split.
- Clinical appearance: Bifid uvula ,Midline cleft, Nasal speech,Feeding difficulty

- 2. Cleft of Hard Palate -Involves bony palate.
- Features: Visible defect in hard palate ,Communication between oral and nasal cavities ,Food regurgitation through nose
- 3. Complete Cleft Palate
- Involves: Hard palate ,Soft palate ,Often associated with cleft lip
- Severity: zooUnilateral ,Bilateral
- 4. Submucous Cleft Palate -Muscles of soft palate fail to fuse but mucosa remains intact.
- Classic triad: Bifid uvula ,Zona pellucida (midline bluish thin area) Notch in posterior border of hard palate

- Clinical Features
- Feeding Problems -Milk regurgitation through nose ,Difficulty sucking ,Poor weight gain
- Speech Abnormalities ,Hypernasal speech Nasal air escape Articulation defects
- Ear Problems -Due to Eustachian tube dysfunction: Recurrent otitis media ,Conductive hearing loss
- Dental Abnormalities - Malocclusion Missing or malformed teeth
- Facial Deformity -In severe cases.
- Treatment –Palatoplasty Surgical closure of palate.
- Timing: Usually 9–18 months of age

Auditory system

The auditory system is the sensory system responsible for detecting sound waves and converting them into nerve impulses that the brain interprets as sound.

Main Function

Hearing and sound perception

Sound localization

Speech recognition

Sound vibrations are converted into electrical signals and transmitted through the Vestibulocochlear nerve (cranial nerve VIII) to the brain, particularly the Primary auditory cortex in the temporal lobe.

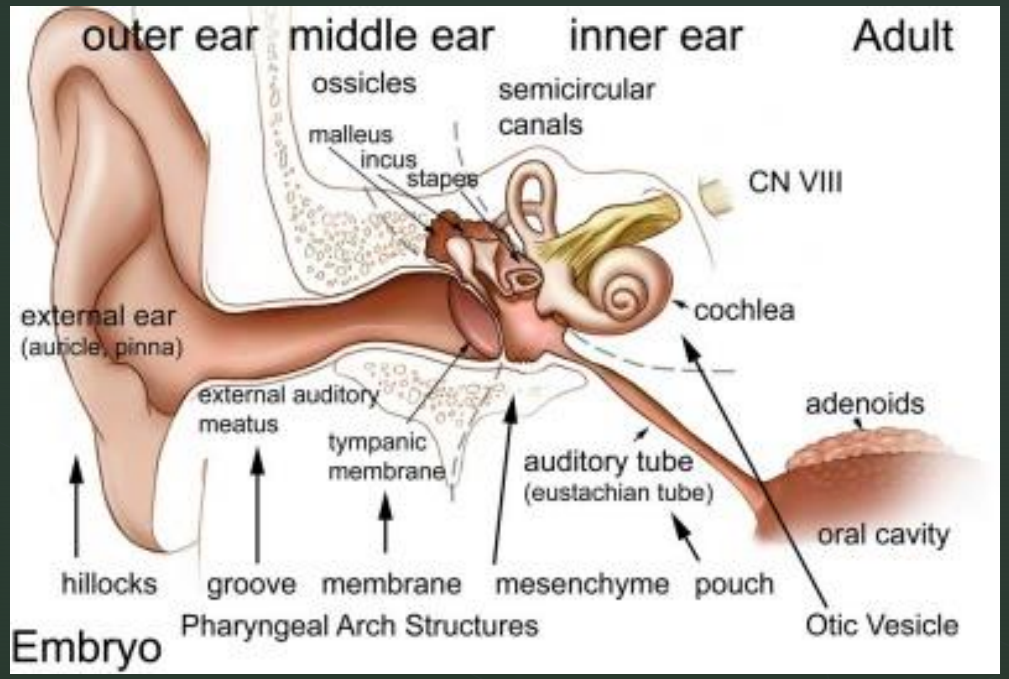

Vestibular system

The vestibular system is responsible for maintaining balance, posture, and spatial orientation, and for coordinating eye movements with head movements.

Main Functions

Maintenance of body equilibrium

Detection of head movement and position

Stabilization of gaze during motion (vestibulo-ocular reflex)

Sensory signals are transmitted through the **Vestibular nerve to the **Vestibular nuclei in the brainstem and then to the cerebellum and cerebral cortex.

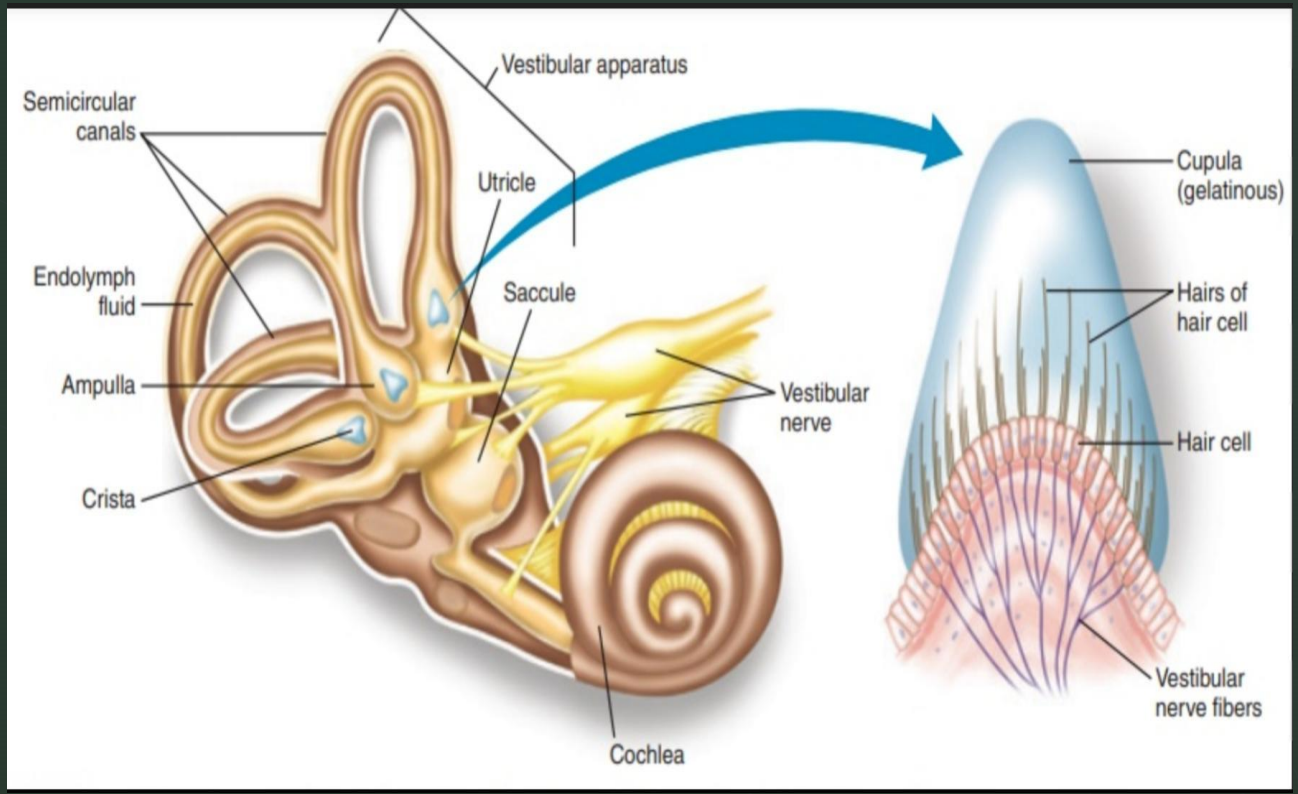

Reference

- Diseases of ENT(p.l.dhingra) 7th edition
- https://pubmed.ncbi.nlm.nih.gov/37537101
- https://www.mayoclinic.org/diseases-conditions/cleft-palate/symptoms-causes/syc-20370985
- https://my.clevelandclinic.org/health/diseases/21865-choanal-atresia
- https://pmc.ncbi.nlm.nih.gov/articles/PMC12409691/
- https://ncbegin.org/who-we-are/the-hearing-system.html
- https://www.neurolab360.com/blog/vestibular-system-and-balance

Thank you