PrediScan™

PREDISCAN HOSPITAL
IITM Rs Park Chennai

Contact: 7339286710
Mail: conatct@prediavn.com

DIAGNOSTIC NASAL ENDOSCOPY REPORT

MRN No	:	**PSMPL001005/26**
Name	:	**RAMKUMAR**
Age/Sex	:	**85 Years/Male**
Address	:	**N/A**
Report Date	:	**07 MAR 26/14:12**
Ref	:	**N/A**

Consultant Name : **Dr. Sarah**
Consultant Specialist

INDICATION

Indication for Endoscopy:	Chronic rhinosinusitis, Nasal obstruction, Epistaxis

PREPARATION

Topical decongestant used:	Yes
Topical lignocaine spray:	Yes
Patient tolerance:	Good

EQUIPMENT DETAILS

Endoscope type:	Rigid
Diameter:	4 mm
Angle:	0°
Light source & camera:	Item 1

(A) NASAL CAVITY

Nasal vestibule:	R:	Normal	L:	Normal
Septum:	R:	Central	L:	Central
Inferior turbinate:	R:	Normal	L:	Normal
Middle turbinate:	R:	Normal	L:	Normal
Superior turbinate:	R:	Normal	L:	Normal

(B) OSTEOMEATAL COMPLEX

Middle meatus:	R:	Clear	L:	Clear
Secretions:	R:	Nil	L:	Nil
Polyps:	R:	Absent	L:	Absent

(C) POSTERIOR NASAL CAVITY

Superior meatus:	Normal
Sphenoethmoidal recess:	Clear
Choana:	Patent

(D) NASOPHARYNX

Adenoids:	Normal
Eustachian tube opening:	Normal
Mass / Growth:	Absent

COMPLICATIONS & OUTCOME

Bleeding / Discharge:	Nil
Complications During Procedure:	None

IMPRESSION & PLAN

Impression:	Normal diagnostic nasal endoscopy.
Advice / Plan:	Medical management, Imaging (CT PNS), Surgical opinion

PRESCRIPTION / RX

Pantab()	after meal • 1-0-1 • 5 Days	After Food

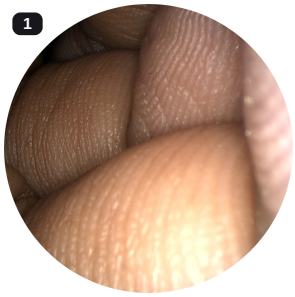
Fig 1

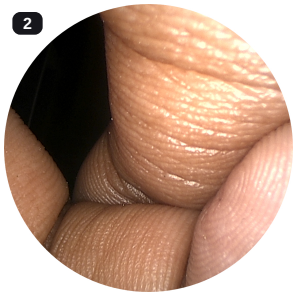
Fig 2

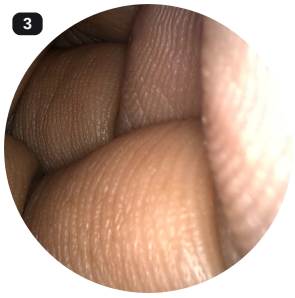
Fig 3

Dr. Sarah
Consultant Specialist