MRN No	Name	Age/Sex	Ref
PSMPL001005/26	RAMKUMAR	85 Yrs / Male	N/A

DIAGNOSTIC NASAL ENDOSCOPY

INDICATION

Indication for Endoscopy:	Chronic rhinosinusitis, Epistaxis, Post-nasal drip

PREPARATION

Topical decongestant used:	Yes
Topical lignocaine spray:	Yes
Patient tolerance:	Good

EQUIPMENT DETAILS

Endoscope type:	Rigid
Diameter:	4 mm
Angle:	0°
Light source & camera:	Item 1

(A) NASAL CAVITY

Nasal vestibule:	R: Normal	L: Normal
Septum:	R: Central	L: Central
Inferior turbinate:	R: Normal	L: Normal
Middle turbinate:	R: Normal	L: Normal
Superior turbinate:	R: Normal	L: Normal

(B) OSTEOMEATAL COMPLEX

Middle meatus:	R: Clear	L: Clear
Secretions:	R: Nil	L: Nil
Polyps:	R: Absent	L: Absent

(C) POSTERIOR NASAL CAVITY

Superior meatus:	Normal
Sphenoethmoidal recess:	Clear
Choana:	Patent

(D) NASOPHARYNX

Adenoids:	Normal
Eustachian tube opening:	Normal
Mass / Growth:	Absent

COMPLICATIONS & OUTCOME

Bleeding / Discharge:	Nil
Complications During	None

IMPRESSION & PLAN

Impression:	Normal diagnostic nasal endoscopy.

PRESCRIPTION / Rx

Pantab Aftermeal · 1-0-1 · 5 Days *After Food*

1

Fig 1

2
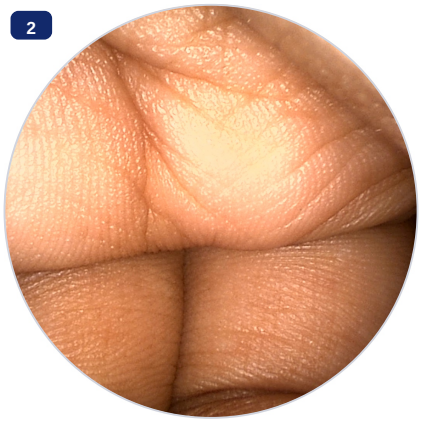
Fig 2

3
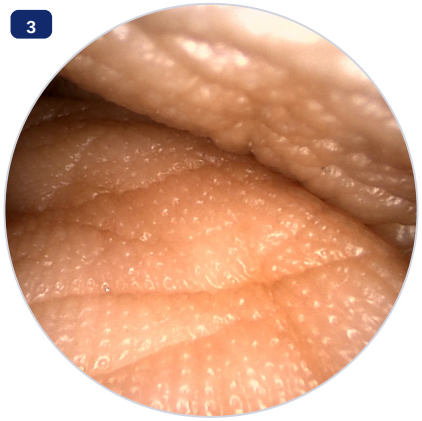
Fig 3

4
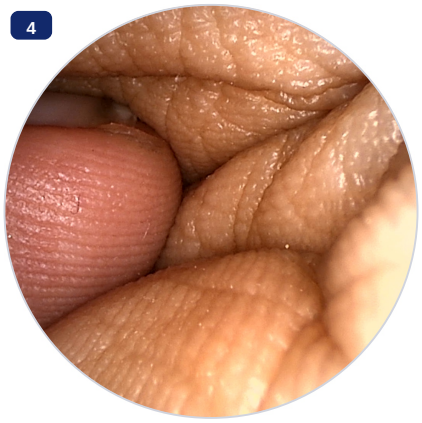
Fig 4

Dr. Sarah
Consultant Specialist