🔴La forme

En radiologie thoracique, les opacités pulmonaires peuvent être décrites selon leur forme. Voici les principales:

- ■Ronde ou arrondie
- ■Ovalaire
- ■Triangulaire
- ■Fusiforme
- ■Nodule
- ■En plage
- ■Linéaires
- ■En plage
- ■En bande
- ■Réticulo_micronodulaire.
- ■Aille de papillon

Opacité ronde

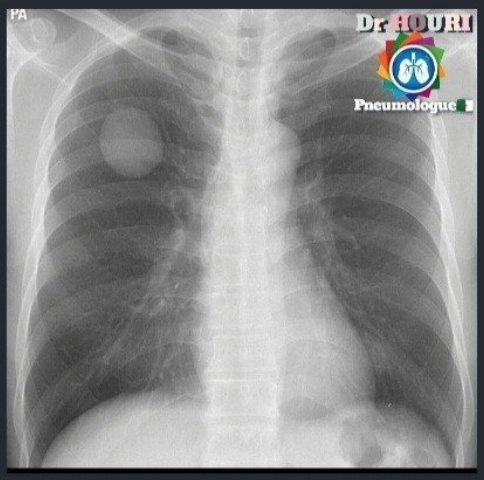

Opacité ovalaire

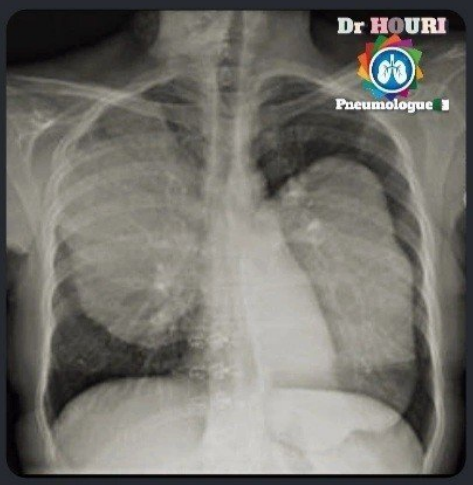

Opacité triangulaire

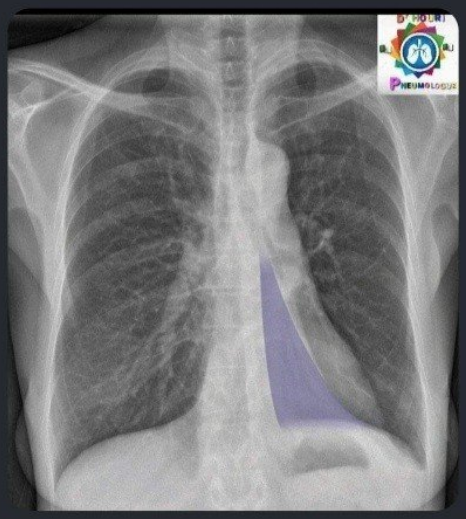

Opacité nodulaires

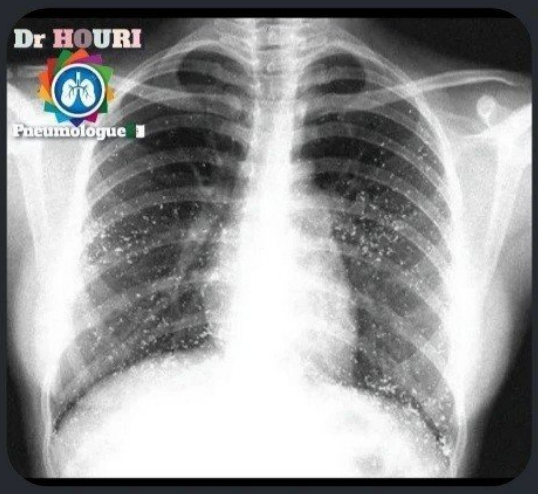

Opacité linéaires

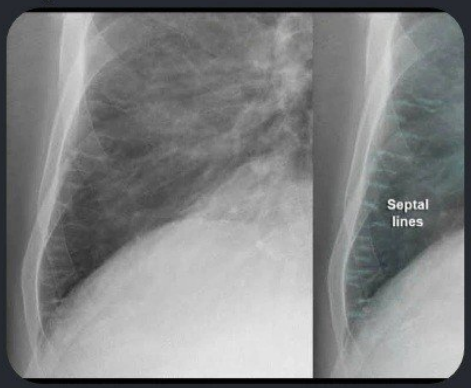

Opacité en aile
de papillon

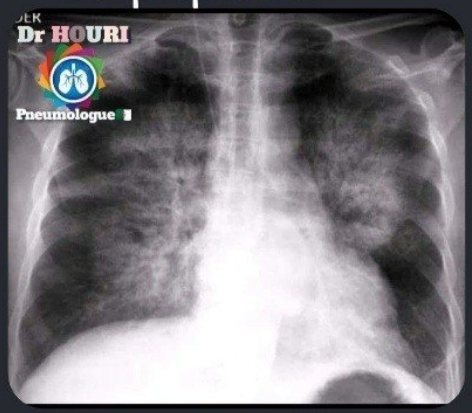

Opacités réticulomicronodulaires
(Nodules + Opacités linéaires).

Opacité fusiforme 🍐

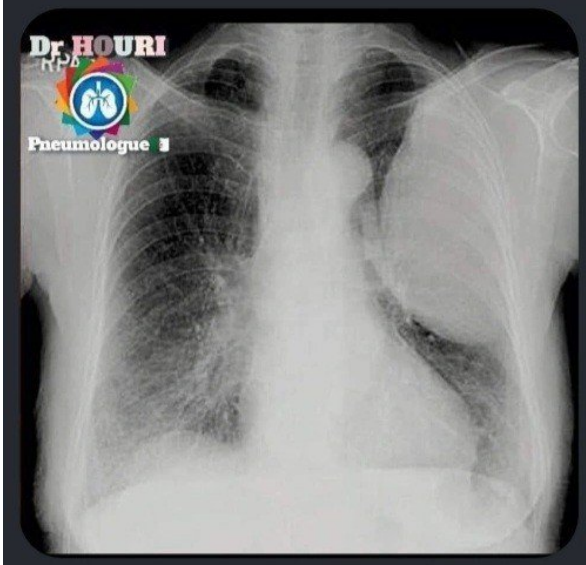
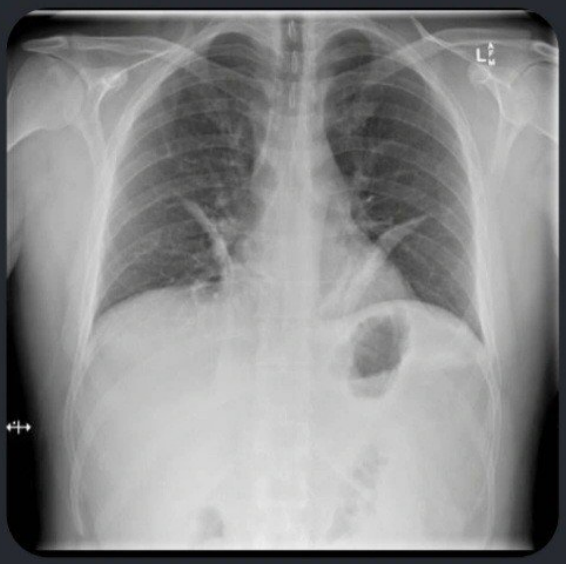
Opacités en bandes