WHIPPLES PROCEDURE

(While opening the abdomen, the falciform lig is preserved to cover the stump of gastroduodenal artery before divided)

→ STEP - I →

Cattel and Braasch manuoure:-

This manuoure is for the exposure of duodenum.

(a) Lesser sac is opened by dissecting greater omentum off the transverse colon.
(b) attachments from the ant. surface of duodenum and pancreas are directed
(c) hepatic flexure of the colon is mobilised downwards and towards left until you see middle colic vein.
d) duodenum and pancreas are exposed by mobilising the rest of small bowel
e) Middle colic vein and (rt) gastro-epiploic vein are ligated during the traction of colon to prevent traction on SMV

→ do not attempt to create any plane b/w the ant surface of SMV and pancreas because the tumor mostly involve the posterio-lateral aspect of SMV & PV.

Step-II →

Kocher manuovre:-

(a) It is started from the 3rd part of duodenum
(b) Duodenum and pancreas are seperated from the retroperitoneum and lifted up.
(c) KOCHERISATION IS DONE TILL THE LEFT LATERAL BORDER OF AORTA.
(d) it helps in dissecting the pancreatic head from SMV
(e) Injury to the right ureter is to be avoided by lying above the plane of gonadal vessels.

** FJ is placed - ???

falciform ligament is placed over the stump of GDA to prevent pseudoaneurysm formation post op in case of any pancreatic leak and abscess formation

STEP-III

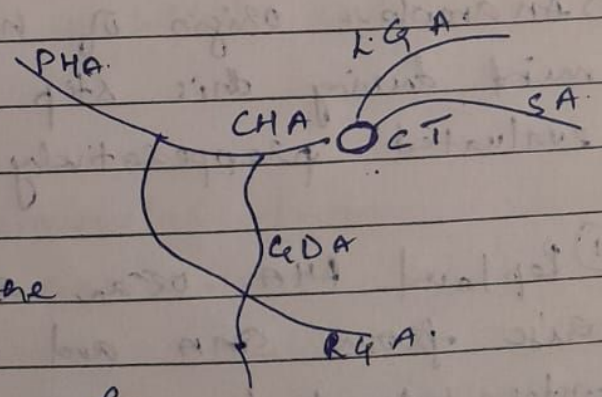

Portal dissection:-

This step is to expose the portal vein

(A) Gastroduodenal artery & right gastric artery are ligated to expose the portal vein by lifting up the stomach along with CHA.

(b) Portal vein is usually present in the triangle formed by CHA, GDA and superior border of pancreas.

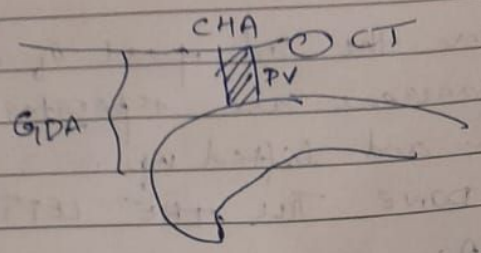

(c) Common hepatic duct is cut and a bulldog is applied towards the cranial end.

(d) Cholecystectomy is performed by dividing the cystic duct.

(e) Superior PD vein opens directly in to portal vein so it should not be injured.

- do not mobilise the supra-pancreatic portion of portal vein.

⇒ Anamolous origin of hepatic artery are kept in mind during this step and evaluated preoperatively by CT

(1) Replaced RHA or an accessory RHA may arise from SMA and may run postero-lateral to portal vein.
{ This is to identified by palpating at the foramen of Winslow }

② entire common hepatic may arise from SMA.
(called - type IX anomaly)

③ Rarely (Rt) hepatic artery arising from CHA may run posterior to PV.

④ Sometimes low lying RHA may be present which may be divided during dissection of CBD.

→ If the tumor involves the SMV, PV, SV confluence and the SMV and PV are reanastomosed



- If the tumor involves only SMV then the SMV is reconstructed using IJV graft or reanastomosed.

P - J

2-3 cm of pancreas is mobilised and end-to-side PJ is done in 2 layers.

Ist layer:- seromuscular from jejunum to pancreatic tissue by interrupted sutures.

2nd layer: full thickness PD (pancreatic duct) to full thickness jejunal wall by interrupted sutures.

- knots of the posterior wall sutures can come inside.
- Stent is placed in the PD lumen 2 cm on either side before closing ant. wall.

H-J
single layer interrupted, distal to PJ

G-J :-
done in 2 layers,
anterior, from the HJ,
end to side,

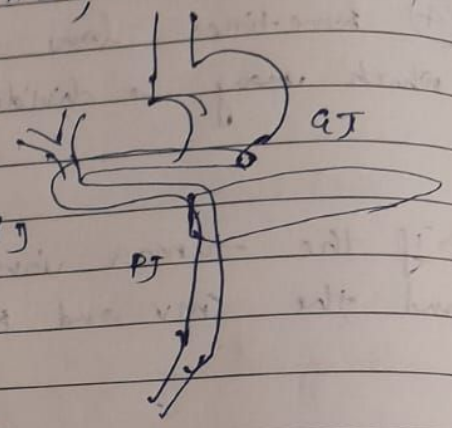

Step-IV →

Transection of stomach

stomach is transected at the lesser curvature caudal to the 4th transverse vein



at the greater curvature transection is at the junction of rt and left GE veins.

→ end arteries of left gastric artery are ligated.
→ Greater omentum is dissected
→ While dissecting the lesser omentum care is to be taken because sometimes

accessory and abnormal LHA may arise from LGA.

- duodenectomy done in large pancreatic masses
  T1 and T2 tumors and positive pre-pyloric LN
→ pylorus preserving can be done in small periampullary tumors.

Step - V → Jejunal transection



- ligament of Treitz is divided
- jejunum is transected 10 cm from the ligament of Treitz
- vessels of the mesentery are divided and tied

Step VI
Mobilisation of specimen from SMPV confluence and (R) border of SMA

(1) transection sutures are applied at superior and inferior borders of pancreas and pancreas is $\boxed{\text{sected at the level of portal vein}}$

Step 7 → uncinate process is seperated from SMV for adequate mobilisation of SMPV
Adequate mobilisation of SMPV to the left side is needed for proper dissection of SMV and cleaning the mesenteric tissue to the (R) of SMA.

→ proper ligation of SMA lead - because post-op bleed occurs from inferior pancreaticoduodenal artery. - (POST-OP HEMORRHAGE)

SMA in vivisection.

Step 5

Inferior pancreaticoduodenal artery is identified and ligated after dissecting the mesenteric fat tissue.

Naming it.

GASTRO-COLIC TRUNK OF HENLE

- drains the right gastroepiploic vein
- " Inf. sup. pancreaticoduodenal vein
- superior rt. colic vein into MV.

drains to MV
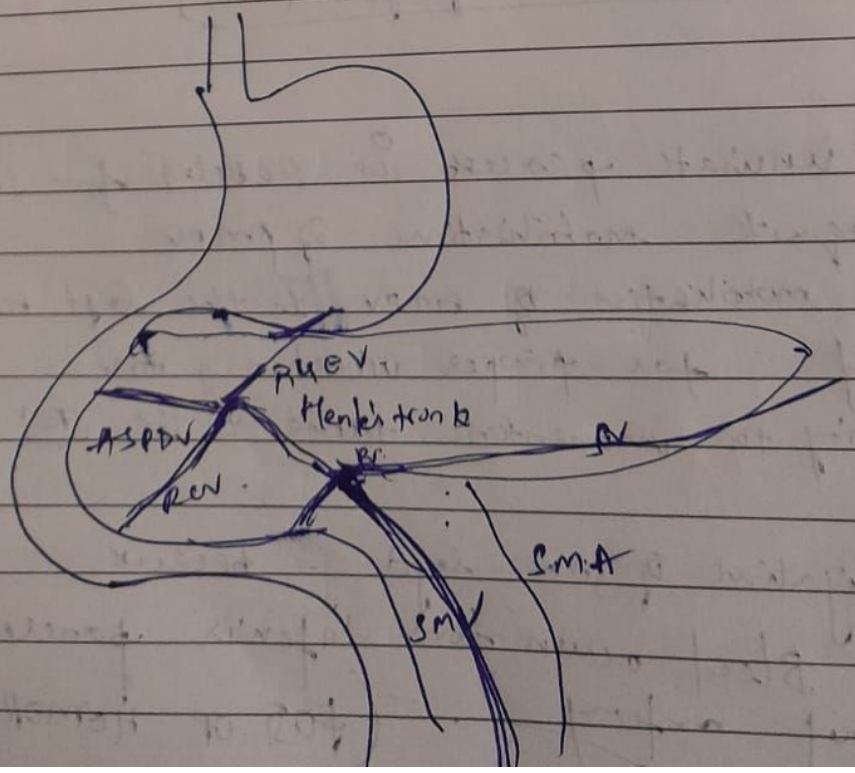
- at the lower border of pancreas.