CLINICAL GUIDELINE

Time is Spine: Non-Traumatic Spinal Emergencies (Adult)

TABLE OF CONTENTS

AUTHOR/S 1
TARGET AUDIENCE and SETTING 1
DEFINITIONS 1
STANDARD REQUIREMENTS 1
PRECAUTIONS/CONTRAINDICATIONS 2
CLINICAL GUIDELINE 2
CLINICAL PATHWAY/FLOWCHART/ALGORITHM 4
FURTHER INFORMATION 5
1.1 Clinical features of spinal emergencies 5
1.2 Spinal Epidural Abscess 6
1.3 Spinal Malignancy 7
RELATED DOCUMENTATION 8
KEYWORDS 8

AUTHOR/S

This Clinical Guideline has been developed by the Emergency Program, with consultation from Infectious Diseases, Neurosurgery, Diagnostic Imaging and General Medicine Programs.

TARGET AUDIENCE and SETTING

All Monash Health Clinicians including medical, nursing staff and allied health staff across all clinical areas.

DEFINITIONS

SCC – Spinal cord compression

CES – Cauda equina syndrome

PPM – Cardiac Pacemaker

PVR – post-void residual bladder volume

STANDARD REQUIREMENTS

When undertaking any clinical interaction with a patient, staff are expected to:

- Perform routine hand hygiene. Refer to the Hand Hygiene Procedure.

- Introduce yourself to the Patient and Carer/ Family if in attendance.
- Explain what you do and what you are there for
- Check patient identification. Refer to the Patient Identification Procedure.
- Obtain consent as per the Consent to Medical Treatment Procedure.
- Keep the patient/carer informed and involve them in decision making.
- Document interaction (such as patient review, assessments, care plans and procedures) in the appropriate location within the electronic medical record (EMR) **or** paper health record using black or blue pen; including date, time, signature and designation. Refer to Clinical Documentation in the Health Record

PRECAUTIONS/CONTRAINDICATIONS

- This procedure **does not** apply to patients who present following major trauma. Please refer to state trauma guidelines for these patients.

- Back/neck pain may be caused by serious non-musculoskeletal causes such as abdominal aortic aneurysm, which must be considered in the differential diagnosis.

- MRI may not be safe to perform in patients with certain metal implants, active electronic devices or other internal metallic objects. If MRI is required urgently for these patients, please contact the neuroradiology hotline (in-hours) or the diagnostic radiologist on-call (outside business hours) for guidance. Please make every reasonable effort to obtain relevant device information, including operation notes and implant cards, to avoid delaying care.

- For patients with implanted active cardiac devices (pacemakers and defibrillators), please refer to and follow the PROMPT document "MRI EXAMINATIONS FOR PATIENTS WITH INTERNAL CARDIAC DEFIBRILLATORS (ICD'S) AND PACEMAKERS (PPM'S)."

- Most patients presenting with acute lower back pain do not require imaging. For further guidance please refer to: https://www.choosingwisely.org.au/recommendations/ranzcr4

CLINICAL GUIDELINE

For the purposes of this document, the following syndromes are covered:

- Acute spinal cord compression (SCC) syndrome
- Cauda equina syndrome (CES)

Depending on the aetiology of these syndromes, **early intervention may prevent neurological deterioration and permanent disability**. Early intervention depends on early clinical identification of these syndromes and timely imaging (usually MRI) for confirmation.

MRI whole spine is indicated for suspected CES or SCC. *A normal CT spine does not adequately exclude CES or SCC.*

These syndromes may be caused by many different primary conditions. This document will highlight the two most amenable to early intervention and prevention of deterioration:

- Spinal epidural abscess

- Malignant compression of the spinal cord

Other potential non-traumatic aetiologies may include **compressive causes** such as haemorrhage (e.g. epidural haematoma), skeletal disease and disc herniation. **Non-compressive causes** of acute myelopathy that can present similarly include spinal cord infarct and transverse myelitis.

Clinicians should:

1. Consider the possibility of cauda equina syndrome or spinal cord compression whenever assessing any patient with back pain. **A post void residual volume and neurological examination must be routinely performed and documented.** Please escalate to a senior clinician for assistance with assessment, if appropriate.
2. Refer to the following flow chart (see next page) to assist identification and management of CES and SCC.
3. Follow the PROMPT procedure 'Ordering/ requesting Inpatient and Emergency Department MRI' and quote "**Time is Spine"** to request the MRI. A phone call to the Radiology Opinion MRI Referrals Neuroradiology role in Baret (in hours) or the on-call diagnostic radiology consultant (after hours) is necessary to expedite the scan.
4. Escalate cases thought to be contraindicated for MRI (e.g. on safety grounds because of a contra-indicated metallic implant or electronic device), to the duty Neuroradiology consultant (in hours) or on-call radiologist (after hours). If the consultant radiologist is uncertain, they can escalate to the head of MRI/MRI safety radiologist for advice.
5. Stabilise and initiate time critical medical therapy (e.g. antibiotics in suspected sepsis) before proceeding with imaging, when required. **Clinically unstable patients are not appropriate in the MRI environment.**
6. Order and administer analgesia if the patient is unable to tolerate lying still for up to 90 minutes. If the patient is claustrophobic, sedation may be required.
7. General anaesthesia may be required if the patient is agitated, confused or cognitively impaired. Please follow the PROMPT procedure 'Requesting MRI Scans under General Anaesthesia (Adults)'.
8. For patients at Casey, Kingston (or sites other than MMC, Dandenong or Moorabbin), please refer to the PROMPT document 'MRI Inter-site Transfer Procedure for Inpatients' to arrange transfer for MRI.

CLINICAL PATHWAY/FLOWCHART/ALGORITHM

(Please zoom in on flowchart for details)

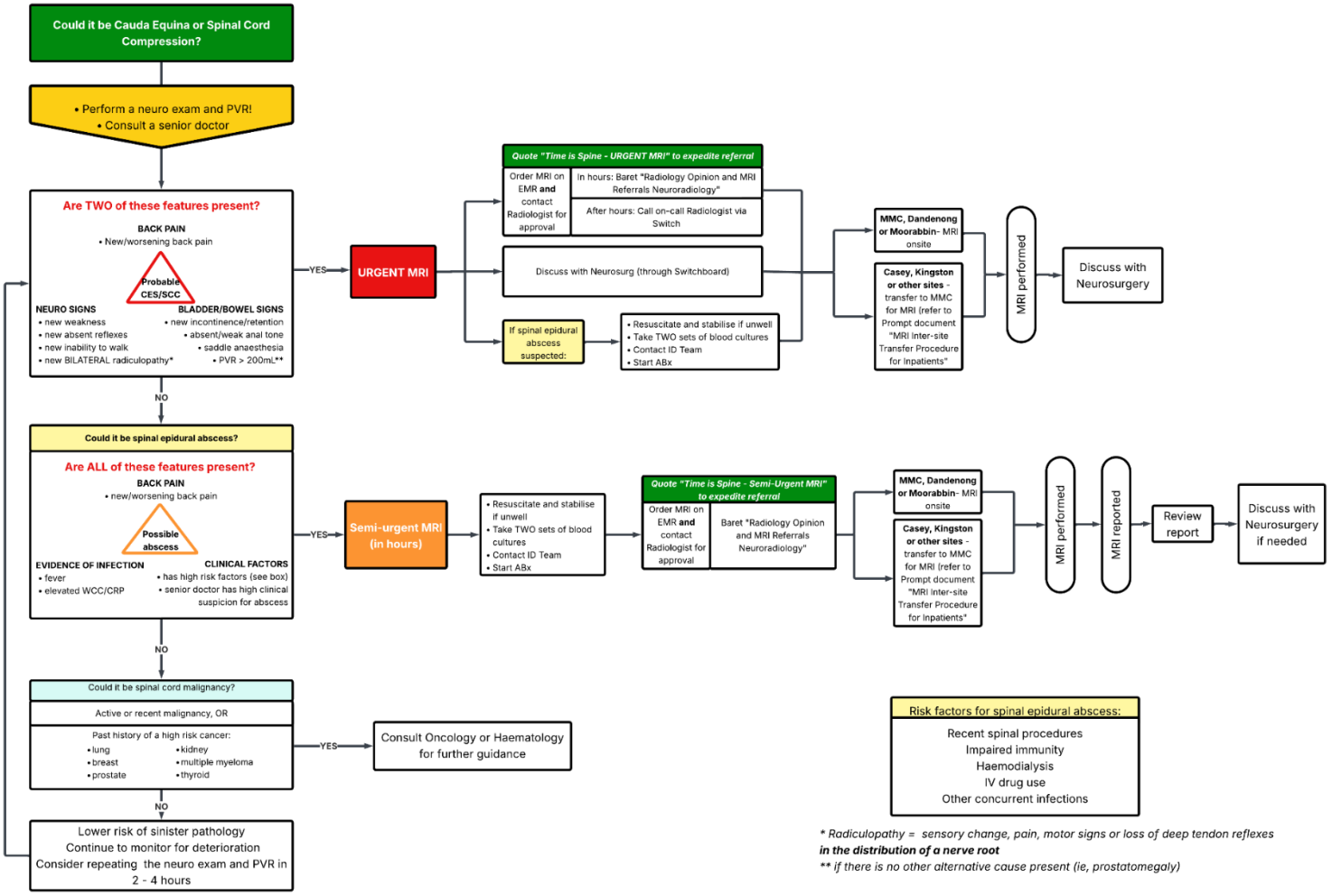

FURTHER INFORMATION

1.1 Clinical features of spinal emergencies

Neurological function deteriorates at an **unpredictable** rate – therefore, this is a time critical condition and MRI must be **expedited** to establish the diagnosis as early as possible.

Lesions at C1 – T12 levels cause a spinal cord compression (SCC) syndrome. The classic clinical features of this are:

- Weakness below the affected level
- Sensory disturbance below affected level
- Urinary dysfunction including retention/incontinence
- Decreased reflexes in acute pathology (note: may have hyperreflexia in chronic pathology)
- Gait disturbance

Depending on the area of the cord affected, these may present as one of the classic syndromes, ie, central, anterior or posterior cord syndrome. (Please see Spinal Cord - EMCrit Project for more details.)

Lesions below the spinal cord (at L2 – S5) cause cauda equina syndrome. The classic clinical features are:

- Bladder dysfunction (including high PVR – see below)
- Bowel dysfunction
- Saddle anaesthesia
- Sexual dysfunction
- Variable lower limb neurological deficit
- Radiculopathy – that is, pain or sensory disturbance that is in the distribution of a nerve root) – **particularly bilateral**

Lesions at T12 – L2 cause conus medullaris syndrome. This presents with features of SCC, CES or both.

SCC and CES need to be considered in any patient with TWO of the following features:

- New onset back pain
- New onset neurological dysfunction (motor or sensory deficit) referable to a spinal cord level, or BILATERAL radiculopathy
- New onset bowel/bladder/sexual dysfunction

These symptoms should prompt escalation to a senior doctor and consideration of URGENT MRI **WHOLE SPINE** (minimum sagittal T2 weighted imaging of whole spine).

Once an MRI has been performed, consult Neurosurgery URGENTLY for review and advice.

Bladder dysfunction and CES

Bladder dysfunction may include

- Altered urinary sensation, or loss of desire to void
- Poor urinary stream, sensation of incomplete emptying, need to strain to void
- Frank urinary retention and overflow incontinence
- **High PVR (>200mL is considered abnormal)**

Bladder dysfunction may be due to other causes (ie prostatism), or to pain itself. A careful history should elucidate the chronicity of the bladder dysfunction, with acute onset being concerning for CES. Please note that bladder dysfunction cannot safely be attributed to pain alone.

PVR is a convenient, objective and reproducible marker for bladder dysfunction, and must be routinely performed on patients presenting with acute lower back pain.

PVR must be routinely performed on patients presenting with acute lower back pain.

1.2 Spinal Epidural Abscess

This rare but life-threatening condition is a spinal emergency, **even in the absence of neurological deficit.**

Clinical features

Classic triad of symptoms of spinal epidural abscess:

- Fever
- Back pain
- Neurological deficit.

However, it is rare for all three features to be present. Diagnosis requires a high level of clinical suspicion. **Suspect epidural abscess if there are risk factors for spinal infection:**

Risk Factors for Spinal Infection:

- Recent spinal procedures
- Impaired immunity (including chemotherapy, diabetes mellitus, alcohol abuse)
- Haemodialysis
- Intravenous illicit drug use
- Other infections (e.g. contiguous bony or soft tissue infection such as discitis, UTI or bacteraemia)

Investigation

- **Imaging**: URGENT MRI whole spine with contrast. *NB: renal impairment is no longer a contraindication to gadolinium-based contrast agent, when it is necessary to make the diagnosis.*
- **Inflammatory markers:** For spinal infection (including epidural abscess) the sensitivity of an elevated ESR is 76 – 95% and the sensitivity of an elevated CRP is 82 - 98%
- **Blood cultures:** Two sets of blood cultures prior to starting antibiotics

Management of spinal epidural abscess

If neurological compromise or features of sepsis give antibiotics **urgently**.

*If there is suspicion of spinal infection without neurological compromise or sepsis, antibiotics **may be delayed** until definitive microbiological diagnosis is made either from blood cultures or tissue sample/aspirate. Please consult with the Infectious Disease and Neurosurgical team.*

- **Take two sets of blood cultures**
- **Antibiotics**:
  - If suspicion of spinal infection with neurological compromise or signs of sepsis: give **ceftriaxone** 2g (administer as a push dose), THEN **vancomycin** (link to dose calculator)
  - However, if recent spinal surgery: give **cefepime** 2g IV 8 hourly THEN **vancomycin** (link to dose calculator)
  - Discuss ongoing therapy with Infectious Diseases
- **Surgery:**
  - May need emergency surgical decompression/drainage
  - *Conservative management may be appropriate in some cases. Please consult with the Neurosurgical Team.*

1.3 Spinal Malignancy

Spinal malignancy usually represents metastatic disease rather than primary spinal malignancy. The thoracic spine accounts for approximately 60% of spinal metastases. The aim is to detect spinal malignancy before neurological impairment develops. Although neurological impairment is usually a late feature of spinal malignancy, in some cases it may be the presenting feature. It clinically presents as SCC, CES or radiculopathy depending on the site of compression.

Suspect spinal malignancy if the patient presents with
- Back/neck pain
- Spinal instability and pathological fracture
- Neurological deficit

AND
- has a history of active/recent cancer, or past history of a high-risk cancer (breast, prostate, lung, thyroid, kidney, multiple myeloma)

Investigation

- MRI is the first line investigation if there is any neurological deficit or suspicion of spinal cord or cauda equina compression.

Management

- Spinal malignancy with acute neurological deficit (usually SCC or CES):
  - Emergency surgical decompression, often with internal fixation
  - Steroids (dexamethasone 10mg IV, as a single dose) as a bridge to definitive treatment
  - Radiotherapy**,** sometimes as emergency primary therapy
- Spinal malignancy without acute neurological deficit: Treatment is multimodal and may include radiotherapy, chemotherapy, surgery and steroids (pls discuss with specialist team)

RELATED DOCUMENTATION

Prompt Documents:

MRI Inter-site Transfer Procedure for Inpatients

Requesting MRI Scans under General Anaesthesia (Adults)

Ordering/ requesting Inpatient and Emergency Department MRI

MRI EXAMINATIONS FOR PATIENTS WITH INTERNAL CARDIAC DEFIBRILLATORS (ICD'S) AND PACEMAKERS (PPM'S)

External Links:

Choosing Wisely

- https://www.choosingwisely.org.au/recommendations/ranzcr4
- https://www.choosingwisely.org.au/recommendations/apa1

Spinal Cord - EMCrit Project

KEYWORDS

Back pain, neck pain, spinal pain, lumbar pain, cauda equina syndrome, cord compression, epidural abscess, spinal malignancy, CES, SCC

Document governance	
Tier 1 Policy or Tier 2 Framework supported by this Guideline	High Quality Care (Policy)
Executive Sponsor	Divisional Director, Hospitals and Clinics
Responsible Program, Service, Unit, Department or Committee	Acute Medicine, Subacute and Community Program – Emergency Services
Primary Contact	Melody Hiew, Emergency Physician, Deputy Director Dandenong Emergency Department