Human-Like Artificial Intelligent System for Predicting Invasion Depth of Esophageal Squamous Cell Carcinoma Using Magnifying Narrow-Band Imaging Endoscopy: A Retrospective Multicenter Study

Lihui Zhang, MD[1,2,3,*], Renquan Luo, MA[1,2,3,*], Dehua Tang, MD[4,*], Jie Zhang, MD[5], Yuchen Su, MD[5], Xinli Mao, MA[6], Liping Ye, MA[6], Liwen Yao, MD[1,2,3], Wei Zhou, MD[1,2,3], Jie Zhou, MD[1,2,3], Zihua Lu, MD[1,2,3], Mengjiao Zhang, MA[1,2,3], Youming Xu, MD[1,2,3], Yunchao Deng, MD[1,2,3], Xu Huang, MA[1,2,3], Chunping He, MD[1,2,3], Yong Xiao, MD[1,2,3], Junxiao Wang, MA[1,2,3], Lianlian Wu, MD[1,2,3], Jia Li, MD[1,2,3], Xiaoping Zou, MD[4,#] and Honggang Yu, MD[1,2,3,#]

INTRODUCTION: **Endoscopic evaluation is crucial for predicting the invasion depth of esophagus squamous cell carcinoma (ESCC) and selecting appropriate treatment strategies. Our study aimed to develop and validate an interpretable artificial intelligence–based invasion depth prediction system (AI-IDPS) for ESCC.**

METHODS: **We reviewed the PubMed for eligible studies and collected potential visual feature indices associated with invasion depth. Multicenter data comprising 5,119 narrow-band imaging magnifying endoscopy images from 581 patients with ESCC were collected from 4 hospitals between April 2016 and November 2021. Thirteen models for feature extraction and 1 model for feature fitting were developed for AI-IDPS. The efficiency of AI-IDPS was evaluated on 196 images and 33 consecutively collected videos and compared with a pure deep learning model and performance of endoscopists. A crossover study and a questionnaire survey were conducted to investigate the system's impact on endoscopists' understanding of the AI predictions.**

RESULTS: **AI-IDPS demonstrated the sensitivity, specificity, and accuracy of 85.7%, 86.3%, and 86.2% in image validation and 87.5%, 84%, and 84.9% in consecutively collected videos, respectively, for differentiating SM2-3 lesions. The pure deep learning model showed significantly lower sensitivity, specificity, and accuracy (83.7%, 52.1% and 60.0%, respectively). The endoscopists had significantly improved accuracy (from 79.7% to 84.9% on average, $P = 0.03$) and comparable sensitivity (from 37.5% to 55.4% on average, $P = 0.27$) and specificity (from 93.1% to 94.3% on average, $P = 0.75$) after AI-IDPS assistance.**

DISCUSSION: **Based on domain knowledge, we developed an interpretable system for predicting ESCC invasion depth. The anthropopathic approach demonstrates the potential to outperform deep learning architecture in practice.**

KEYWORDS: esophagus squamous cell carcinoma; artificial intelligence; endoscopy; invasion depth

SUPPLEMENTARY MATERIAL accompanies this paper at http://links.lww.com/CTG/A957, http://links.lww.com/CTG/A958, http://links.lww.com/CTG/A959, http://links.lww.com/CTG/A960, http://links.lww.com/CTG/A961, http://links.lww.com/CTG/A962, http://links.lww.com/CTG/A963, http://links.lww.com/CTG/A964, http://links.lww.com/CTG/A965, http://links.lww.com/CTG/A966, http://links.lww.com/CTG/A967, http://links.lww.com/CTG/A968, http://links.lww.com/CTG/A969, http://links.lww.com/CTG/A970, http://links.lww.com/CTG/A971

Clinical and Translational Gastroenterology 2023;14:1–11. https://doi.org/10.14309/ctg.0000000000000606

[1]Department of Gastroenterology, Renmin Hospital of Wuhan University, Wuhan, P.R. China; [2]Hubei Key Laboratory of Digestive System, Renmin Hospital of Wuhan University, Wuhan, P.R. China; [3]Hubei Provincial Clinical Research Center for Digestive Disease Minimally Invasive Incision, Renmin Hospital of Wuhan University, Wuhan, P.R. China; [4]Department of Gastroenterology, Affiliated Drum Tower Hospital, Medical School of Nanjing University, Nanjing, P.R. China; [5]Department of Thoracic Surgery, Shanghai Chest Hospital, Shanghai Jiaotong University, Shanghai, China; [6]Department of Gastroenterology, Taizhou Hospital of Zhejiang Province Affiliated to Wenzhou Medical University, Linhai, China. **Correspondence:** Honggang Yu, MD. E-mail: yuhonggang@whu.edu.cn. Xiaoping Zou, MD. E-mail: zouxp@nju.edu.cn.
*Lihui Zhang, Renquan Luo, and Dehua Tang contributed equally to this work.
#Xiaoping Zou and Honggang Yu contribute equally to this work.
Received November 29, 2022; accepted May 23, 2023; published online June 9, 2023

© 2023 The Author(s). Published by Wolters Kluwer Health, Inc. on behalf of The American College of Gastroenterology

INTRODUCTION

Esophageal cancer is one of the most prevalent malignancies and a leading cause of cancer-associated mortality worldwide (1). Esophagus squamous cell carcinoma (ESCC) accounts for 84% of the new global cases of esophageal cancer (2). Endoscopic resection (ER) is recommended for treating esophageal neoplasia of epithelium (EP) to minute submucosal invasion (SM1) because it is associated with fewer complications and shorter hospital stay compared with surgical treatment (3). However, ESCC deeper than SM2 represented a formal contraindication for ER, with the risk of lymph node metastasis, which can reach up to 50% (4–7). Accurately differentiating SM2-3 lesions from other superficial lesions is crucial for determining the optimal treatment strategy for ESCC.

Gastroenterology societies, including European Society of Gastrointestinal Endoscopy and Japanese Endoscopic Society (JES), regard magnifying endoscopy with narrow-band imaging (ME-NBI) as one of the most effective methods for preoperative invasion depth prediction of ESCC (8–10). Multiple endoscopic classification criteria have been proposed for ESCC diagnosis, such as mucosal surface features, JES classification of intrapapillary capillary loop, avascular area (AVA), and others (11–14). However, the comprehensive application of these criteria in clinical practice remains challenging due to its reliance on personal experience and empirical knowledge (15,16). Numerous microstructures, including vascular density, dilation, and shape, have been identified as valuable indicators for evaluating ESCC. However, despite their potential usefulness, these indicators are seldom used in practice due to the inherent limitations of manual measurement, specifically cognitive bias (17,18).

Artificial intelligence (AI) has made several preliminary attempts to predict the invasion depth of ESCC (19,20). However, the lack of transparency in the diagnosis process of deep learning (DL) models may reduce trust in AI-assisted decisions and weaken their credibility. A previous observational study found that cases with SM2-3 ESCC account for only 6.14%–9.47% of superficial ESCC, resulting in limited data volume available for DL training, damaging the robustness (21). While endoscopists can learn from rare visual examples by incorporating prior knowledge, developing AI architecture with limited data volume and interpretability remains a challenge.

Based on human-like learning principles, we developed and evaluated an interpretable artificial intelligence–based invasion depth prediction system (AI-IDPS) for ESCC invasion depth. The AI-IDPS is designed to automatically evaluate and integrate prior knowledge for ESCC diagnosis, overcoming the inherent limitations of DL.

METHODS

Patients and cohorts

Multicenter data were retrospectively collected between April 2016 and October 2021, from Renmin Hospital of Wuhan University, Nanjing Drum Tower Hospital of Nanjing University, Shanghai Chest Hospital, and Taizhou Hospital of Zhejiang Province. A total of 5119 images obtained through ME-NBI from 562 patients with superficial ESCC and 33 videos were used to train and validate the system (Table 1; Figure 1). All endoscopic examinations were performed using a standard magnifying endoscope (GIF-H260Z; Olympus Medical Systems, Tokyo, Japan). Two expert endoscopists jointly established criteria for poor-quality images, including bleeding, halation, blur, defocus, or mucus, and excluded such images from all datasets. Unique images were selected from those with a high similarity. Invasion depth of lesions used for prediction was obtained from pathological examination after ER or esophagectomy with negative margins. This work followed the Standards for Reporting Diagnostic Accuracy Studies 2015 reporting guidelines.

Development of feature fitting model

DL and quantitative algorithm models were applied to develop feature extraction models. Nine invasion depth–related features were included in the system: mucosal flatness (11,22), background color, JES classification of IPCLs, diameter, tortuosity and cyclization of IPCLs, area size of AVAs, length of AVA major axis, and the spectral dominant color. Details of the development and validation of feature extraction models are provided in supplementary materials. A summary of typical endoscopic features for ESCC invasion depth in previous studies is available in Table 2.

To achieve optimal predicting efficiency, all visual feature indicators were integrated into AI-IDPS for invasion depth prediction. The model with superior performance in testing datasets was chosen for AI-IDPS (see Supplementary Table S5, Supplementary Digital Content, http://links.lww.com/CTG/A970; Supplementary Figure S2, Supplementary Digital Content, http://links.lww.com/CTG/A958).

Development of AI-IDPS

The AI-IDPS was constructed using 13 features extraction models and 1 feature fitting model. The accuracy of each model was optimized according to the ROC curve (23,24). All outcomes from previous models were provided as input to the feature fitting model for decision-making and presented in real time to illustrate the process of AI prediction reached (Figure 2). For real-time analysis, AI-IDPS could recognize the frozen screen during ME-NBI and conduct analysis automatically. This is a fully automatic procedure without requiring additional commands. All features captured and invasion depth prediction are presented on screen for 5 seconds (Video 1). Once AI-IDPS is activated, evidence for AI prediction, including invasion depth–associated features, IPCL, and AVA mapping, is presented to endoscopists, allowing endoscopists to trust the AI predictions and make informed decisions based on the provided evidence (Video 1). All models run on a server with an NVIDIA RTX3080Ti GPU (with 16 GB GPU memory). The frames per second for running the system in videos is 45 on the GPU, fulfilling the real-time processing speed requirement of 25 frames per second for endoscopic video.

Video validation and crossover study

To evaluate the efficacy of the AI-IDPS in practice, a crossover study was performed. Thirty-three videos were consecutively collected from Shanghai Chest Hospital between April 2021 and October 2021. Each video contained a representative ME-NBI clip from a unique lesion, focusing on the lesion inspection.

The video datasets of ESCC were provided for 3 board-certified experts, 2 senior endoscopists, and 2 junior endoscopists to predict invasion depth. First, all endoscopists were required to watch the videos and predict the invasion depth of each lesion. After a 5-month washout period, all endoscopists were provided with the same videos alongside AI-IDPS predictions and asked to predict the invasion depth. All videos were renamed before being

Table 1. Baseline characteristics

Baseline characteristics	Dataset for feature extracting model	Train dataset for feature fitting model	Test dataset for AI-IDPS	Video test set for AI-IDPS
Sex, n (%)				
Male	374 (73.2%)	125 (71.8%)	37 (72.6%)	28 (84.9%)
Female	137 (26.8%)	49 (28.2%)	14 (27.4%)	5 (15.1%)
Age (yr), median (range)	64 (31–88)	66 (45–81)	64 (43–80)	66 (52–81)
Tumor size (mm), median (range)	15 (3–130)	15 (3–130)	15 (3–40)	19 (5–35)
Depth of lesion				
Uncertain, n (%)	46 (8.5%)	0 (0%)	0 (0%)	0 (0%)
pEP-LPM, n (%)	349 (64.6%)	116 (66.7%)	24 (47.0%)	15 (45.4%)
pMM-SM1, n (%)	80 (14.8%)	28 (16.1%)	10 (19.6%)	10 (30.3%)
pSM2-SM3, n (%)	65 (12.0%)	30 (17.2%)	17 (33.3%)	8 (24.2%)
No. of images for each lesion depth				
Uncertain, n (%)	1517 (30.8%)	0 (0%)	0 (0%)	
pEP-LPM, n (%)	2083 (42.3%)	743 (69.5%)	101 (51.8%)	
pMM-SM1, n (%)	754 (15.3%)	177 (16.6%)	45 (23.1%)	
pSM2-SM3, n (%)	570 (11.5%)	149 (13.9%)	49 (25.1%)	
Case distribution (Hospital 1\Hospital 2\Hospital 3\Hospital 4)	41\352\24\94	22\100\12\40	8\10\25\8	0\0\33\0
Image distribution (Hospital 1\Hospital 2\Hospital 3\Hospital 4)	1025\2973\280\646	146\646\102\175	29\54\85\27	\

Hospital 1, Renmin Hospital of Wuhan University; Hospital 2, Nanjing Drum Tower Hospital of Nanjing University; Hospital 3, Shanghai Chest Hospital; Hospital 4, Taizhou Hospital of Zhejiang Province.
AI, artificial intelligence; EP, epithelium; IDPS, invasion depth prediction system; LPM, lamina propria; MM, muscularis mucosa; SM, submucosa; uncertain, lesions without definite invasion depth and inflammation.

represented to endoscopists, who were reminded of deliberately adopt or disregard the AI-IDPS prediction based on the evidence of AI decision and personal judgment. The performance of endoscopists was compared before and after AI assistance. For video validation, the overall prediction of each case was recognized as the final result of AI-IDPS. The gold standard was the pathological result after ER or esophagectomy.

Questionnaire survey

Endoscopists who participated in the crossover study were provided with a questionnaire survey. A seven-point Likert scale was used to estimate endoscopists' subjective understanding and satisfaction with AI-IDPS. Binomial options were used to validate endoscopists' preference for AI-IDPS or pure DL models. All questions in our survey are supplied in Supplementary Table S1 (see Supplementary Digital Content, http://links.lww.com/CTG/A970).

Ethical approval

This study was approved by the institutional review board of Renmin Hospital of Wuhan University (WDRY2019-K094), Nanjing Drum Tower Hospital (2019-204-01), Shanghai Chest Hospital (IS2143), and Taizhou Hospital (K20210719), with a waiver granted for the requirement of informed consent. The reader study was not an intervention trial and was performed under guidelines approved by the institutional review board. All data processed for this investigation were anonymous when transferred to the study investigators.

Statistical analysis

The area under the receiver operating curve, positive predictive value, negative predictive value, sensitivity, specificity, and accuracy were presented for the quantitative data. The χ^2 test was used to analyze the relationship between invasion depth and endoscopic features. The McNemar test was applied to compare the endoscopists' performance with that of AI-IDPS in identifying SM2-3 ESCC in images, and a generalized estimating equation (GEE) model was applied for man-machine video competition and crossover study. A 2-sided P value of <0.05 was considered statistically significant. All calculations were performed using SPSS 23 (IBM, Chicago, IL).

RESULTS

Characteristics of the patient cohort

A total of 5,119 images obtained through ME-NBI of esophageal lesions of 562 patients across 4 hospitals were included (Table 1, see Supplementary Table S2, Supplementary Digital Content, http://links.lww.com/CTG/A970), consisting of 82 (13.9%) SM2-3 lesions, 463 (78.3%) EP-SM1 lesions, and 46 (7.8%) lesions without definite pathological result.

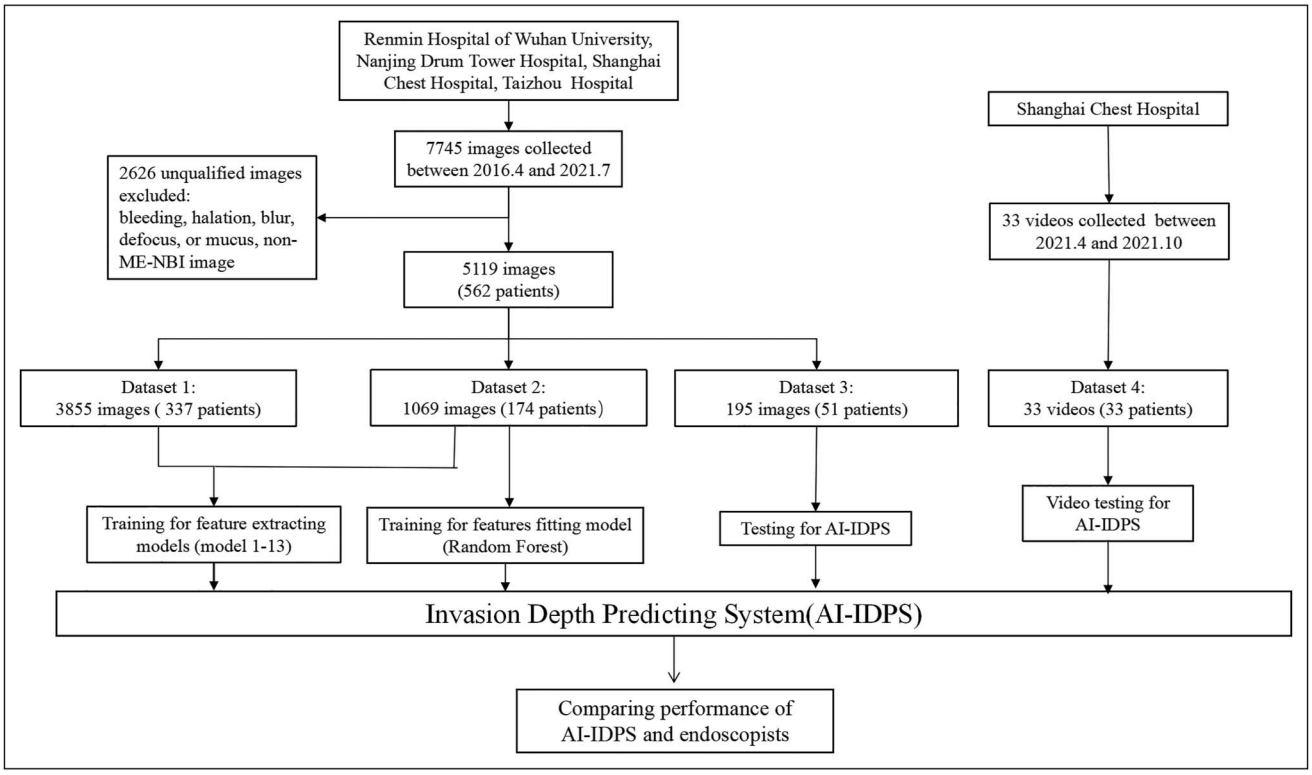

Figure 1. Flow chart. AI-IDPS, artificial intelligence–based invasion depth predicting system.

To evaluate AI-IDPS performance, an independent testing dataset of 196 images obtained through ME-NBI from 4 hospitals, comprising 34 (66.6%) EP-SM1 lesions and 17 (33.3%) SM2-3 lesions, was used. For real-time performance validation, 33 videos were consecutively collected for video validation, consisting of 25 (65.8%) EP-SM1 lesions and 8 (24.2%) SM2-3 lesions.

Efficiency validation of indices for ESCC prediction

Before AI-IDPS construction, the performance of quantitative and qualitative features was validated. Vessel diameter can differentiate SM2-3 with an accuracy of 71.4% (67.8%–75.0%), tortuosity with 68.70% (65.0%–72.4%), and cyclization with 66.0% (62.2%–69.8%). The types of mucosa flatness and background coloration were significantly different between lesions of EP-SM1 and SM2-SM3 (see Supplementary Table S7, Supplementary Digital Content, http://links.lww.com/CTG/A970).

The overall accuracy of IPCL classification was 91.5% and that of B2-IPCL recognizing was 93.8% (91.4%–96.1%) (Table 3, see Supplementary Table S3, Supplementary Digital Content, http://links.lww.com/CTG/A970). The size of AVAs was measured using quantitative analysis of AVA and length of the major axis achieving the accuracy of 87.28% and 93.64% in recognizing large AVAs, respectively.

AI-IDPS performance

After feature extraction, quantitative and qualitative features were automatically input into the feature fitting model to predict ESCC invasion depth. The useful features are summarized in Table 3 in order of contribution. On the independent dataset, AI-IDPS achieved an accuracy of 84.9% (81.3%–91.0%), sensitivity of 85.7% (75.9%–95.5%), specificity of 86.3% (80.7%–91.9%), and area under the receiver operating curve of 0.867 (Table 3). The ROC curve of AI-IDPS is provided in Figure 3.

Video validation

A total of 33 videos consecutively collected at Hospital 4 were used for video validation. The accuracy, sensitivity, and specificity of AI-IDPS in video validation were 84.9% (71.9%–97.8%), 87.5% (57.9%–100.0%), and 84.0% (68.6%–99.4%), respectively. The representative video identification results are presented in Supplementary Figure S3 (See Supplementary Digital Content, http://links.lww.com/CTG/A959).

Comparison with pure DL model

To explore whether AI-IDPS performance was superior to that of learning architecture, a pure DL model was established using the same training and testing dataset as AI-IDPS. As Table 4 summarizes, at similar sensitivity levels (85.7% vs 83.7%), AI-IDPS achieved a higher accuracy (86.2% vs 60.0%, $P < 0.001$) and specificity (86.3% vs 52.1%, $P < 0.001$) and a positive predictive value (66.7% vs 37.0%, $P < 0.001$) compared with the pure DL model.

AI-IDPS performance compared with that of endoscopists

In the man-machine contest, AI-IDPS achieved a significantly higher accuracy and sensitivity when analyzed by images (86.2% vs 69.2%, 85.7% vs 32.0%, respectively) and a comparable specificity (86.3% vs 81.7%, respectively) (Table 5). AI-IDPS had a significantly better performance than the average performance of endoscopist, when analyzed by patient (see Supplementary Table S6, Supplementary Digital Content, http://links.lww.com/CTG/A970).

Table 2. Summary of typical endoscopic classifications of ESCC diagnosis

Classification	Type	Description	Pathology
IPCL classification [27]	IPCL-I	Brown loops	Normal
	IPCL-II	Dilation and elongation of these capillaries, appearing at the margin of erosions.	Inflammatory
	IPCL-III	"Borderline" lesions with less vascular proliferation	Atrophic mucosa or low-grade intraepithelial neoplasia
	IPCL-IV	Vascular proliferation increased in "borderline" lesions	Noninvasive high-grade intraepithelial neoplasia
	IPCL-V1	Dilation, meandering, irregular caliber, and form variation	EP
	IPCL-V2	Extension of IPCL type V-1	LPM
	IPCL-V3	Advanced destruction of IPCL	MM, SM1 or deeper
	IPCL- VN	Generation of new tumor vessel	SM2 or deeper
Magnifying endoscopic classification of the Japan Esophageal Society [12]	IPCL-A	Normal IPCL or abnormal microvessels without severe irregularity	Normal epithelium, inflammation, and LGIN
	IPCL-B1	Abnormal microvessels with severe irregularity or highly dilated abnormal vessels (type B vessels with a loop-like formation)	EP-LPM
	IPCL-B2	Abnormal microvessels with severe irregularity or highly dilated abnormal vessels (type B vessels with a loop-like formation)	MM-SM1
	IPCL-B3	Highly dilated vessels which calibers appear to be more than 3 times that of usual B2 vessels	SM2 or deeper
	AVA-small	Smaller than 0.5 mm in diameter	EP-LPM
	AVA-middle	0.5 mm or between 0.5 and 3 mm	MM-SM1
	AVA-large	3 mm or larger	SM2 or deeper
Novel endoscopic criteria for mucosal and submucosal cancers [11]	Criteria for mucosal cancer	Any size of flat or slight elevation or slight depression with smooth/even surface	Mucosal
		Slightly elevated lesion of ≤1 cm with granular or uneven surface	
		Hyperemic flat lesion of ≤3 cm with granular or uneven surface	
		Slightly depressed lesion of ≤2 cm with uneven surface	
	Criteria for submucosal cancer	Irregularly (unevenly) nodular or protruded lesion of any size	Submucosal
		Slightly elevated lesion of >1 cm with granular or uneven surface	
		Hyperemic flat lesion of >3 cm with granular or uneven surface	
		Irregularly (unevenly) depressed lesion of >2 cm	
		Ulcerative lesion of any size	
Brownish epithelium in squamous neoplasia of the esophagus [28]	Negative	Lesion without brownish color change in the area between vessels	Low-grade intraepithelial neoplasia
	Positive	Brownish color changes in the areas between vessels	High-grade intraepithelial neoplasia or invasive cancer

AVA, avascular area; EP, epithelium; IPCLs, intrapapillary capillary loops; MM, muscularis mucosa; SM, submucosa.

Evaluation of AI-IDPS effect on endoscopists' prediction

In the objective evaluation, the crossover study showed that the endoscopists had significantly improved accuracy (from 79.7% to 84.9% on average, $P = 0.03$) and comparable sensitivity (from 37.5% to 55.4% on average, $P = 0.27$) and specificity (from 93.1% to 94.3% on average, $P = 0.75$) after AI-IDPS assistance.

In the subjective evaluation, the mean scores of interpretation of AI-IDPS were 5.86 ± 1.36, 4.86 ± 1.46, 4.86 ± 0.83, 4.29 ± 1.49, and 4.71 ± 1.83 when evaluating the extent to which users understood the AI decision process. The extent to which AI-IDPS influence users' judgment is higher (4.57 ± 1.4 vs 3.43 ± 1.51), and it achieved greater user satisfaction (5.71 ± 0.48 vs 3.57 ± 1.13) compared with the pure DL model. The visualized features of AI-IDPS mainly contribute to the users' trust in AI prediction (5.86 ± 0.99). Moreover, all participants in our questionnaire survey preferred AI-IDPS to the pure DL model.

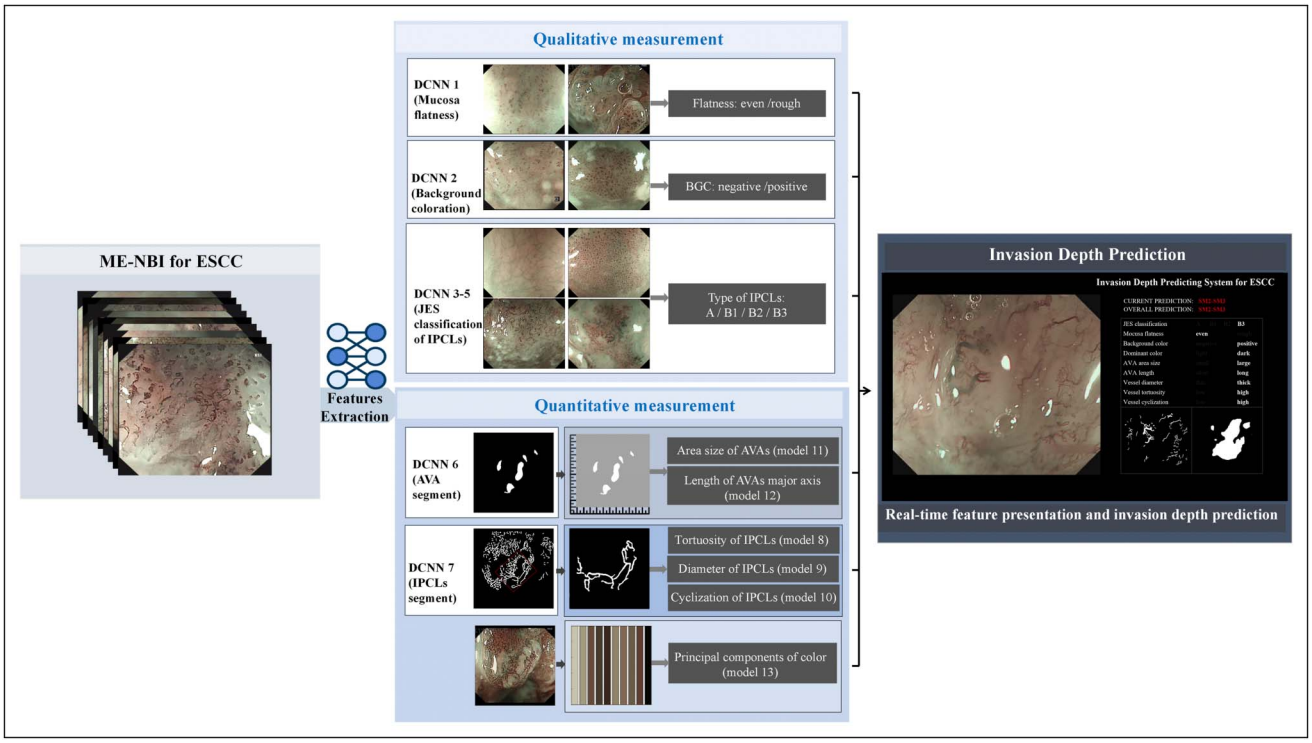

Figure 2. Framework of AI-IDPS. AI-IDPS, artificial intelligence–based invasion depth predicting system; AVA, avascular area; ESCC, esophagus squamous cell carcinoma; IPCLs, intrapapillary capillary loops; JES, Japanese Endoscopic Society; ME-NBI, magnifying endoscopy with narrow-band imaging.

DISCUSSION

In this study, we developed an interpretable AI-IDPS for ESCC based on prior knowledge. This system automatically identified 9 parameters of compound endoscopic visual features and provided an interpretable prediction for invasion depth. The system demonstrated superior performance compared with both pure DL models and expert endoscopists. To our knowledge, this is the first AI-IDPS with interpretable and transparent decision-making process for ESCC.

Accurate preoperative optical diagnosis is crucial for guiding optimal treatment approach for ESCC. Predicting the invasion depth of superficial ESCC before resection remains challenging, with overdiagnosis rates ranging from 20.0% to 40.0% and underdiagnosis rates between 4.3% and 60% in previous studies (12,14,16,25). While, AI-IDPS has demonstrated reliable performance in predicting ESCC invasion depth, achieving higher sensitivity (85.7% vs 32.0%) and accuracy (86.2% vs 69.2%) compared with experienced endoscopists. It revealed that AI-IDPS assistance enabled endoscopists to diagnose ESCC invasion depth in real time with greater accuracy, thereby preventing delays in appropriate treatment and minimizing additional harm caused by underestimating the extent of ESCC invasion.

In addition to established clinical indicators, various microstructure indicators, such as vascular density, diameter, and morphology, have been proposed for accessing ESCC invasion depth (21,26). However, the lack of efficient methods for quantitative measurement in clinical settings has hindered the adoption of these parameters, which are limited by manual evaluation (17). To optimize the diagnosis process, AI-IDPS integrated multiple endoscopic features derived from validated theories (11,12,27,28). In this study, we investigated the effectiveness of previously unused parameters and developed quantitative measurement methods to surmount the constraints of human visual perception, thereby enriching the existing knowledge base for ESCC invasion depth prediction.

Despite the existence of effective classification systems, the intricate decision-making process involving the mapping relationships of multiple indicators has deterred their widespread implementation (14,29). Owing to its practicality, the simplified JES classification has been recommended for clinical diagnosis and training courses (17). Computer-aided decision-making constitutes an important approach for predicting outcomes of multivariate events, such as the economic trend prediction and protein structure prediction (30,31). In this study, AI-IDPS streamlined the process by using a comprehensive and interpretable method. The decision-making process integrated all relevant indicators, transcending the biological limitations of the human brain. AI-IDPS holds promise as a potent tool for incorporating multiple features and facilitating computer-aided decision-making in endoscopic diagnosis.

The "black box" nature of AI systems remains one of the greatest challenges for AI application in medicine, alongside accuracy (32). Tokai et al and Shimamoto et al have made preliminary attempts at ESCC invasion depth prediction (19,33). However, these models performed comparably with endoscopists, and the opaque decision-making process could diminish physicians' acceptance and confidence in AI diagnosis, ultimately undermining overall benefits (34). Pure DL model provides only a diagnostic result without interpretation of the decision-making process or diagnostic basis. By contrast, AI-IDPS extracted visual

Table 3. Performance of AI-IDPS system and feature extracting models

Models	Accuracy	Sensitivity	Specificity	PPV	NPV
AI-IDPS	86.2% (81.3%–91.0%)	85.7% (75.9%–95.5%)	86.3% (80.7%–91.9%)	67.7% (55.9%–79.6%)	94.8% (91.0%–98.6%)
Mucosa flatness	90.8% (87.8%–93.9%)	89.9% (84.8%–94.9%)	91.5% (87.6%–95.3%)	87.9% (82.6%–93.3%)	92.9% (89.3%–96.5%)
Classification of A/B type IPCLs	96.0% (94.4%–97.6%)	98.5% (97.3%–99.7%)	90.6% (86.4%–94.9%)	95.8% (93.9%–97.8%)	96.5% (93.7%–99.2%)
Classification of B1/B2 type IPCLs	93.8% (91.4%–96.1%)	95.7% (92.8%–98.6%)	92.2% (88.8%–95.7%)	90.8% (86.8%–94.9%)	96.4% (93.9%–98.8%)
Classification of B3/non-B3 type IPCLs	99.7% (99.2%–100.0%)	83.3% (40.5%–100.0%)	99.8% (99.6%–100.0%)	83.3% (40.5%–100.0%)	99.8% (99.6%–100.0%)
Principal components of color	75.9% (72.6%–79.3%)	76.7% (72.8%–80.5%)	73.8% (66.9%–80.6%)	89.5% (86.5%–92.5%)	52.0% (45.5%–58.5%)
Cyclization of vessels	66.0% (62.2%–69.8%)	67.1% (59.8%–74.3%)	65.6% (61.1%–70.1%)	42.2% (36.1%–48.2%)	84.2% (80.3%–88.1%)
Background color	82.9% (77.5%–88.6%)	84.2% (77.5%–90.9%)	80.4% (70.0%–90.8%)	89.7% (84.0%–95.5%)	71.4% (60.3%–82.6%)
Diameter of vessels	71.4% (67.8%–75.0%)	72.1% (65.1%–79.0%)	71.2% (66.9%–75.4%)	48.3% (42.0%–54.7%)	87.2% (83.7%–90.7%)
Tortuosity of vessels	68.7% (65.0%–72.4%)	67.1% (59.8%–74.3%)	69.3% (64.9%–73.7%)	45.0% (38.7%–51.3%)	84.9% (81.2%–88.6%)
Length of AVA major axis	93.6% (91.1%–96.2%)	93.6% (89.1%–98.1%)	93.8% (90.7%–96.9%)	96.9% (93.8%–100.0%)	87.5% (83.2%–91.8%)
Area size of AVAs	87.3% (83.8%–90.8%)	87.5% (81.4%–93.6%)	87.2% (82.9%–91.5%)	76.6% (69.2%–83.9%)	93.6% (90.4%–96.8%)

Data are shown as % (95% CI).
AI-IDPS, artificial intelligent–based invasion depth predicting system; AVA, avascular area; IPCLs, intrapapillary capillary loops; NPV, negative predictive value; PPV, positive predictive value.

features into structural data, with feature vectors weighted differently for interpreting the AI outcome. The final endoscopic features were displayed on a monitor, enabling endoscopists to understand the rationale behind AI predictions, significantly influencing their decisions. Benefited from the transparency of AI-IDPS, endoscopists can correct and validate certain errors, such as when an artifact on the mucosal surface was incorrectly segmented into vascular area and AVA (See Supplementary Figure S3, Supplementary Digital Content, http://links.lww.com/CTG/A959). This represents an effective attempt to demystify the black box nature of DL models.

Insufficient data volume, constrained by data privacy and security concerns, remains challenging for DL (35). Unfortunately, large medical datasets are sometimes unavailable due to limited morbidity or short-term emerging diagnostic techniques, such as the endoscopic images of ESCC SM2-3 (36). Unlike computer vision approaches, endoscopists can learn from a single typical example, which is derived from the ability to use background knowledge. To simulate human logic, AI-IDPS extracted specific visual features for prediction because the texture features related to ESCC invasion depth were more accessible than direct ESCC SM2-SM3 lesions. This compensates for the deficiency of datasets and showed superior performance on accuracy (86.15% vs 60%) compared with pure DL model, using prior knowledge and human-like diagnostic approaches. This study advocates an innovative approach to overcome data volume limitation.

According to the statement of European Society of Gastrointestinal Endoscopy, there is no validated training course for optical diagnosis training of ESCC, which requires a lengthy process of cognitive theory and prospective practice experience (29). The overall endoscopic accuracy of invasion depth prediction for superficial ESCC was reported to be only 79%, necessitating the promotion of an efficient method incorporating literature theory in clinical practice (37). AI-IDPS could filter out noise and focus on specific characteristics, with greater clinical acceptability than conventional Dynamic Convolution Neural Networks It might shorten the learning period and enhance proficiency in ESCC optical diagnosis for endoscopists by presenting implications of AI decisions accurately and instantly.

This study has several limitations. First, it is a retrospective study without prospective validation, although we have validated it in the consecutive cases with ESCC to ensure reproducible clinical effects. Second, although it was a multicenter study for ESCC, the data scale of the validation cohorts was relatively small. Despite that this being a common issue in ESCC endoscopic diagnosis research, prospective data collection is necessary to enhance system performance. Third, there was a potential limitation of the ME-NBI technology because it may miss mucosal abnormalities located outside the areas

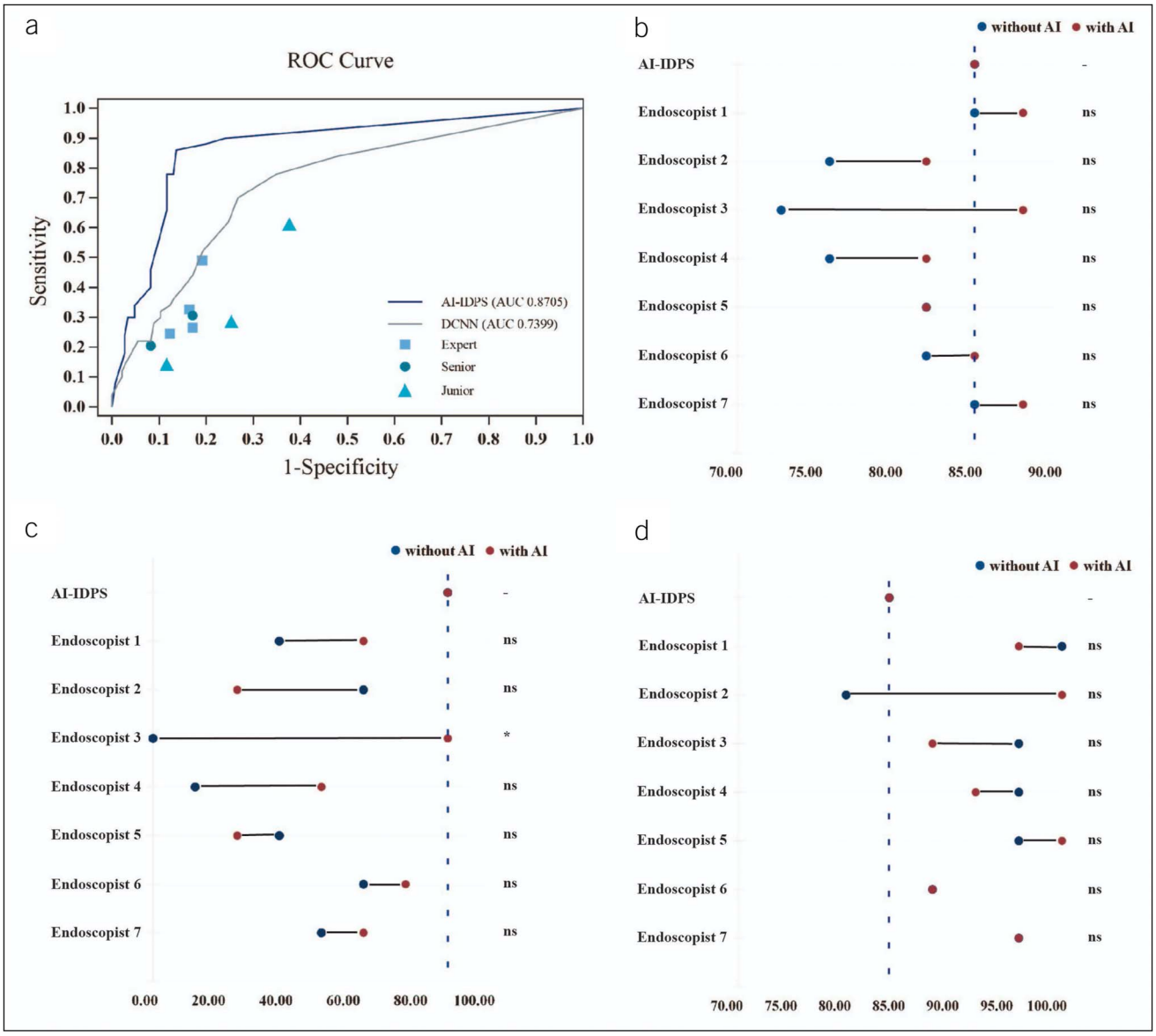

Figure 3. Performance of AI-IDPS. (**a**) ROC curves of pure deep learning model and AI-IDPS. The rectangle, round, and triangle dots denote the performance of expert, senior, and junior endoscopists in image testing datasets, respectively; and the comparation of endoscopists' performance with and without AI-IDPS assistance. The accuracy (**b**), sensitivity (**c**), and specificity (**d**) change for each endoscopist were presented. The blue dot represents performance without AI-IDPS, and the red dot represents performance with AI-IDPS assistance. AI-IDPS, artificial intelligence–based invasion depth predicting system; DCNN, Dynamic Convolution Neural Network; ROC, receiver operating curve.

Table 4. Comparison between AI-IDPS and pure deep learning model

	AI-IDPS	Pure deep learning	*P* Value
Accuracy	86.2% (81.3%–91.0%)	60.0% (53.1%–66.9%)	<0.001
Sensitivity	85.7% (75.9%–95.5%)	83.7% (73.3%–94.0%)	0.79
Specificity	86.3% (80.7%–91.9%)	52.1% (44.0%–60.2%)	<0.001
PPV	66.7% (54.8%–78.6%)	37.0% (28.0%–45.9%)	<0.001
NPV	93.3% (89.1%–97.5%)	90.5% (84.2%–96.8%)	0.442

Data are shown as % (95% confidence interval).
AI-IDPS, artificial intelligent–based invasion depth predicting system; NPV, negative predictive value; PPV, positive predictive value.

Table 5. Man-machine contest

	Accuracy	Sensitivity	Specificity	PPV	NPV	P^a value	P^b value	P^c value	P^d value	P^e value
AI-IDPS	86.2% (81.3%–91.0%)	85.7% (75.9%–95.5%)	86.3% (80.7%–91.9%)	67.7% (59.8%–79.7%)	94.7% (90.9%–98.6%)	—	—	—	—	—
Endoscopist 1	63.1% (56.3%–69.9%)	28.6% (15.9%–41.2%)	74.7% (67.6%–81.7%)	27.5% (14.8%–40.1%)	75.7% (68.6%–82.8%)	< 0.005	< 0.001	< 0.005	< 0.001	< 0.001
Endoscopist 2	62.1% (55.2%–68.9%)	61.2% (47.6%–74.9%)	62.3% (54.5%–70.2%)	35.3% (24.9%–45.7%)	82.7% (75.6%–89.9%)	< 0.001	< 0.05	< 0.001	< 0.001	< 0.005
Endoscopist 3	69.7% (63.3%–76.2%)	14.3% (4.5%–24.1%)	88.4% (83.2%–93.6%)	29.2% (9.6%–48.8%)	75.4% (68.9%–82.0%)	< 0.05	< 0.001	0.678	< 0.005	< 0.001
Endoscopist 4	73.9% (67.7%–80.0%)	20.4% (9.1%–31.7%)	91.8% (87.3%–96.2%)	45.5% (22.9%–68.1%)	77.5% (71.2%–83.8%)	0.123	< 0.001	0.152	0.064	< 0.001
Endoscopist 5	69.7% (63.3%–76.2%)	30.6% (17.7%–43.5%)	82.9% (76.8%–89.0%)	40.9% (28.7%–53.1%)	83.0% (76.4%–89.5%)	< 0.001	< 0.001	< 0.005	< 0.005	< 0.005
Endoscopist 6	72.8% (66.6%–79.1%)	49.0% (35.0%–63.0%)	80.8% (74.4%–87.2%)	45.3% (31.4%–59.1%)	82.4% (76.1%–88.7%)	< 0.001	< 0.001	0.064	< 0.05	< 0.005
Endoscopist 7	71.8% (65.5%–78.1%)	24.5% (12.5%–36.5%)	87.7% (82.3%–93.0%)	40.0% (21.4%–58.6%)	77.6% (71.1%–84.0%)	< 0.001	< 0.001	0.791	< 0.05	< 0.001
Endoscopist 8	68.7% (62.2%–75.2%)	26.5% (14.2%–39.0%)	82.9% (76.8%–89.0%)	32.5% (17.3%–47.7%)	76.8% (70.1%–83.5%)	< 0.001	< 0.001	0.189	< 0.001	< 0.001
Endoscopist 9	70.8% (64.4%–77.2%)	32.7% (19.5%–45.8%)	83.6% (77.6%–89.6%)	40.0% (24.1%–55.9%)	78.7% (72.2%–85.2%)	< 0.001	< 0.001	0.503	< 0.01	< 0.001

Data are shown as % (95% confidence interval).
Endoscopist 1–3 were junior, 4–5 were senior, and 6–9 were expert endoscopists.
AI-IDPS, artificial intelligent–based invasion depth predicting system; NPV, negative predictive value; PPV, positive predictive value.
[a]Analysis for accuracy.
[b]Analysis for sensitivity.
[c]Analysis for specificity.
[d]Analysis for PPV.
[e]Analysis for NPV.

specifically selected for imaging, and future research could focus on developing a region of interest labeling model for ESCC. Fourth, for the optimization of the system (38,39), we excluded poor quality and highly duplicated data for system construction, while it might introduce selection bias and necessitate further prospective validation. Last, AI-IDPS is not directly applicable to nonmagnifying endoscopy, and a more extensive system compatible with nonmagnifying analysis would be developed in the future.

In conclusion, AI-IDPS is an interpretable system to predict ESCC invasion depth, leveraging domain knowledge to achieve reliable accuracy and clinical practicality. With human-understandable rules, AI-IDPS demonstrated significantly better performance and acceptability than the DL approach. It selects and provides objective parameters in an explainable manner for endoscopists, fostering accurate treatment decisions for patients with ESCC. This study introduces an innovative artificial intelligence approach that transcends the intrinsic limitations of DL, addressing the black box phenomenon and excessive reliance on extensive datasets.

Study Highlights

WHAT IS KNOWN

- ✓ Esophagus squamous cell carcinoma (ESCC) is a prevalent malignancy and the major subtype of esophageal cancer.
- ✓ Invasion depth prediction is crucial for determining optimal treatment strategy for ESCC.
- ✓ Existing AI studies for ESCC prediction have been limited due to the "black box" nature of models and insufficient datasets.

WHAT IS NEW HERE

- ✓ We have developed an interpretable artificial intelligent system that predicts the invasion depth of ESCC, which outperforms even expert endoscopists.
- ✓ Our system automatically analyzes visual features using both quantitative and qualitative measurements.
- ✓ Our system surpasses pure deep learning model in performance and acceptance.

CONFLICTS OF INTEREST

Guarantor of the article: Honggang Yu, MD.

Specific author contributions: H.Y., X.Z.: conceived and designed the study. D.T., J.Z., X.M., L.Y., R.L., and Y.S.: collected and reviewed datasets of images and videos. M.Z., W.Z., X.H., C.H., Y.X., Y.D., Z.L., Y.X., L.W., J.L., J.W., L.Z., R.L., L.Y., and J.Z.: collected, collated, and analyzed the data. L.Z., L.Y.: wrote the manuscript. L.Z., R.L., Z.L. revised the manuscript and verified the underlying data. H.Y.: performed extensive editing of the manuscript. All authors reviewed and approved the final manuscript for submission.

Financial support: This work was partly supported by a grant from the Project of Hubei Provincial Clinical Research Center for Digestive Disease Minimally Invasive Incision (grant no. 2018BCC337); Hubei Province Major Science and Technology Innovation Project (grant no. 2018-916-000-008); Key Technology Research and Development Program of Zhejiang Province (grant no. 2019C03040).

Potential competing interests: None to report.

Data sharing: Individual anonymous participant data that underlie the results reported in this article and study protocol will be shared for investigators after publication. Data requester could contact the corresponding author to gain access.

Ethical approval: This study was approved by the institutional review board of Renmin Hospital of Wuhan University (WDRY2019-K094), Nanjing Drum Tower Hospital (2019-204-01), Shanghai Chest Hospital (IS2143), and Taizhou Hospital (K20210719), with a waiver granted for the requirement of informed consent.

ACKNOWLEDGMENTS

This work was partly supported by a grant from the Project of Hubei Provincial Clinical Research Center for Digestive Disease Minimally Invasive Incision (grant no. 2018BCC337); College-enterprise Deepening Reform Project of Wuhan University (to Honggang Yu); Hubei Province Major Science and Technology Innovation Project (grant no. 2018-916-000-008); National Natural Science Foundation of China-Youth Science Fund Project (grant no. 82202257); Key Technology Research and Development Program of Zhejiang Province (grant no. 2019C03040).

REFERENCES

1. Sung H, Ferlay J, Siegel RL, et al. Global cancer statistics 2020: GLOBOCAN estimates of incidence and mortality worldwide for 36 cancers in 185 countries. CA Cancer J Clin. 2021;71(3):209–49.
2. Arnold M, Ferlay J, van Berge Henegouwen MI, et al. Global burden of oesophageal and gastric cancer by histology and subsite in 2018. Gut. 2020;69(9):1564–71.
3. Ishihara R, Arima M, Iizuka T, et al. Endoscopic submucosal dissection/endoscopic mucosal resection guidelines for esophageal cancer. Dig Endosc. 2020;32(4):452–93.
4. Dermine S, Leconte M, Leblanc S, et al. Outcomes of esophagectomy after noncurative endoscopic resection of early esophageal cancer. Ther Adv Gastroenterol. 2019;12:1756284819892556.
5. Kitagawa Y, Ishihara R, Ishikawa H, et al. Esophageal cancer practice guidelines 2022 edited by the Japan esophageal society: Part 1. Esophagus. 2023:1–30.
6. Pimentel-Nunes P, Dinis-Ribeiro M, Ponchon T, et al. Endoscopic submucosal dissection: European Society of Gastrointestinal Endoscopy (ESGE) guideline. Endoscopy 2015;47(09):829–54.
7. Yamashina T, Ishihara R, Nagai K, et al. Long-term outcome and metastatic risk after endoscopic resection of superficial esophageal squamous cell carcinoma. Official J Am Coll Gastroenterol ACG. 2013; 108(4):544–51.
8. Goda K, Dobashi A, Yoshimura N, et al. Narrow-band imaging magnifying endoscopy versus lugol chromoendoscopy with pink-color sign assessment in the diagnosis of superficial esophageal squamous neoplasms: A randomised noninferiority trial. Gastroenterol Res Pract. 2015;2015:639462.
9. Yoshida T, Inoue H, Usui S, et al. Narrow-band imaging system with magnifying endoscopy for superficial esophageal lesions. Gastrointest Endosc. 2004;59(2):288–95.
10. Muto M, Minashi K, Yano T, et al. Early detection of superficial squamous cell carcinoma in the head and neck region and esophagus by narrow band imaging: A multicenter randomized controlled trial. J Clin Oncol. 2010; 28(9):1566.
11. Choi JY, Bae SE, Ahn JY, et al. Novel endoscopic criteria for predicting Tumor invasion depth in superficial esophageal squamous carcinoma. J Korean Med Sci. 2020;35(41):e336.
12. Oyama T, Inoue H, Arima M, et al. Prediction of the invasion depth of superficial squamous cell carcinoma based on microvessel morphology: Magnifying endoscopic classification of the Japan Esophageal Society. Esophagus. 2017;14:105–12.
13. Goda K, Tajiri H, Ikegami M, et al. Magnifying endoscopy with narrow band imaging for predicting the invasion depth of superficial esophageal squamous cell carcinoma. Dis Esophagus. 2009;22(5):453–60.
14. Arima M, Tada M, Arima H. Evaluation of microvascular patterns of superficial esophageal cancers by magnifying endoscopy. Esophagus. 2005;2:191–7.

15. da Costa-Seixas JP, López-Cerón M, Arnau A, et al. Compound endoscopic morphological features for identifying non-pedunculated lesions≥ 20 mm with intramucosal neoplasia. Cancers. 2021;13(21): 5302.
16. Ishihara R, Mizusawa J, Kushima R, et al. Assessment of the diagnostic performance of endoscopic ultrasonography after conventional endoscopy for the evaluation of esophageal squamous cell carcinoma invasion depth. JAMA Netw Open. 2021;4(9):e2125317.
17. Dobashi A, Goda K, Yoshimura N, et al. Simplified criteria for diagnosing superficial esophageal squamous neoplasms using Narrow Band Imaging magnifying endoscopy. World J Gastroenterol. 2016;22(41):9196.
18. Kikuchi D, Iizuka T, Hoteya S, et al. Vascular density of superficial esophageal squamous cell carcinoma determined by direct observation of resected specimen using narrow band imaging with magnifying endoscopy. Dis Esophagus. 2017;30(11):1–5.
19. Tokai Y, Yoshio T, Aoyama K, et al. Application of artificial intelligence using convolutional neural networks in determining the invasion depth of esophageal squamous cell carcinoma. Esophagus. 2020;17:250–6.
20. Nakagawa K, Ishihara R, Aoyama K, et al. Classification for invasion depth of esophageal squamous cell carcinoma using a deep neural network compared with experienced endoscopists. Gastrointest Endosc. 2019;90(3):407–14.
21. Tanaka I, Hirasawa D, Saito H, et al. The sub-classification of type B2 vessels according to the magnifying endoscopic classification of the Japan Esophageal Society. Dig Endosc. 2020;32(1):49–55.
22. Rey J-F, Inoue H, Guelrud M. Magnification endoscopy with acetic acid for Barrett's esophagus. Endoscopy. 2005;37(06):583–6.
23. Harpaz R, DuMouchel W, LePendu P, et al. Performance of pharmacovigilance signal-detection algorithms for the FDA adverse event reporting system. Clin Pharmacol Ther. 2013;93(6):539–46.
24. Jiménez-Valverde A. Insights into the area under the receiver operating characteristic curve (AUC) as a discrimination measure in species distribution modelling. Glob Ecol Biogeogr. 2012;21(4):498–507.
25. Inoue T, Ishihara R, Shibata T, et al. Endoscopic imaging modalities for diagnosing the invasion depth of superficial esophageal squamous cell carcinoma: A systematic review. Esophagus. 2022;19(3):375–83.
26. Kumagai Y, Inoue H, Nagai K, et al. Magnifying endoscopy, stereoscopic microscopy, and the microvascular architecture of superficial esophageal carcinoma. Endoscopy. 2002;34(05):369–75.
27. Inoue H, Kaga M, Ikeda H, et al. Magnification endoscopy in esophageal squamous cell carcinoma: A review of the intrapapillary capillary loop classification. Ann Gastroenterol Q Publ Hellenic Soc Gastroenterol. 2015;28(1):41.
28. Kanzaki H, Ishihara R, Ishiguro S, et al. Histological features responsible for brownish epithelium in squamous neoplasia of the esophagus by narrow band imaging. J Gastroenterol Hepatol. 2013;28(2):274–8.
29. Dekker E, Houwen BB, Puig I, et al. Curriculum for optical diagnosis training in Europe: European Society of Gastrointestinal Endoscopy (ESGE) position statement. Endoscopy. 2020;52(10):899–923.
30. Jumper J, Evans R, Pritzel A, et al. Highly accurate protein structure prediction with AlphaFold. Nature. 2021;596(7873):583–9.
31. Wang J, Tao B, Gong Z, et al. A mobile robotic measurement system for large-scale complex components based on optical scanning and visual tracking. Robot Comput Integr Manuf. 2021;67:102010.
32. Poon AI, Sung JJ. Opening the black box of AI-Medicine. J Gastroenterol Hepatol. 2021;36(3):581–4.
33. Shimamoto Y, Ishihara R, Kato Y, et al. Real-time assessment of video images for esophageal squamous cell carcinoma invasion depth using artificial intelligence. J Gastroenterol. 2020;55:1037–45.
34. Felder RM. Coming to terms with the black box problem: How to justify AI systems in health care. Hastings Cent Rep. 2021;51(4):38–45.
35. Gaonkar B, Hovda D, Martin N, et al. Deep learning in the small sample size setting: Cascaded feed forward neural networks for medical image segmentation. SPIE. 2016:646–53.
36. Mizumoto T, Hiyama T, Oka S, et al. Diagnosis of superficial esophageal squamous cell carcinoma invasion depth before endoscopic submucosal dissection. Dis Esophagus. 2018;31(7):dox142.
37. Ueda T, Dohi O, Naito Y, et al. Diagnostic performance of magnifying blue laser imaging versus magnifying narrow-band imaging for identifying the depth of invasion of superficial esophageal squamous cell carcinoma. Dis Esophagus. 2021;34(3):doaa078.
38. Goodfellow I, Bengio Y, Courville A. Deep Learning. MIT Press: Cambridge, MA, 2016.
39. Recht B, Roelofs R, Schmidt L, et al. Do Cifar-10 Classifiers Generalize to Cifar-10?. *arXiv preprint arXiv:180600451*; 2018.

Open Access This is an open-access article distributed under the terms of the Creative Commons Attribution-Non Commercial-No Derivatives License 4.0 (CCBY-NC-ND), where it is permissible to download and share the work provided it is properly cited. The work cannot be changed in any way or used commercially without permission from the journal.