Parts of the brain - not the cortex

In the previous section we discuss the different areas of the cortex and saw that different cortical areas served different functions; away from the cortex the degree of specialisation is more profound though the precise role of different brain areas and how this role relates to its structure is often subtle, or indeed, poorly understood. In this section we will look briefly at a few examples; this is only a very brief tour, touching on only a small number of brain regions and those only briefly as an introduction to the idea that different regions have often precise, but difficult to pin-down, functions.

The hippocampus

The **hippocampus** is found at the edge of the cortex, formally it is part of the so called allocortex; little was known about the function of the hippocampus until, sadly, a man called Henry Molaison, Fig 1, known as **patient H.M.**, had his removed in 1953 in an effort to cure his epilepsy.

From the early thirties until the late forties there had been a fashion in psychiatry to perform a brutal surgery called the frontal lobotomy as a treatment for mental health problems; in a frontal lobotomy the frontal lobe of the cortex was severed from the rest of brain, often in a crude fashion using a sharp spike called a leucotome pushed into the brain from the corner of the eye-socket. This surgery was held to alleviate severe mental illness; in fact, it served only to make people with mental illness more passive, and thus easier to care for in a negligent manner, while actually grievously injuring them and bringing them no actual medical benefit. It is disturbing how widespread this surgery was and how casually it was performed; the Nobel Prize was even awarded for its discovery. In this context of this abusive tradition, William Scoville, the surgeon who operated on Molaison was considered very enlightened and, indeed, made other contributions to neurosurgery.

Molaison had intractable epilepsy, severe enough to leave him incapacitated. Scoville believed the fits were starting in the hippocampus. This was actually very prescient, resecting the hippocampus remains a useful approach to some intractable epilepsy, though modern operations are much more targeted than the surgery Scoville performed on Molaison: he removed most of the hippocampus, an area of the brain whose purpose was unknown at the



Figure 1: **A picture of Henry Molaison**; a photograph of Henry Molaison taken before his surgery. Photo from `wikipedia`

time. In fact, the tragic consequence was that Molaison was no longer able to form new memories. Surprisingly, Molaison preserved his memories of the past, and his short term memory—the memory of what had happened in a moving window measured in seconds—but he was unable to form new memories.

This has lead to the realisation that the hippocampus stores memories for minutes, days and weeks and is the memory store that supports quick memorisation and recall; it is the system we use to remember where we have left our book. This distinguishes it from longer term memory, memories of our childhood or information we find useful or evocative; these memories are stored in the cortex and are thought to be copied there, or **consolidated**, from the hippocampus. The two memory systems are thought to differ in how they store memories, reflecting the different priorities for each; in the hippocampus it is important not to mix memories up, in the cortex it is useful to link related information.

In fact, the realisation that the hippocampus was responsible for certain types of memory lead to a new type of experimental investigation which involves recording neurons in the brain of awake behaving animals, in this case rats. These experiments led to the discovery of **place cells** by John O'Keefe and Jonathan Dostrovsky in 1971. Place cells are cells which fire when the animal is in a particular position; they can be thought of as storing a memory for a particular place and their firing as part of the process of remembering that place. This is illustrated in Fig. 2.

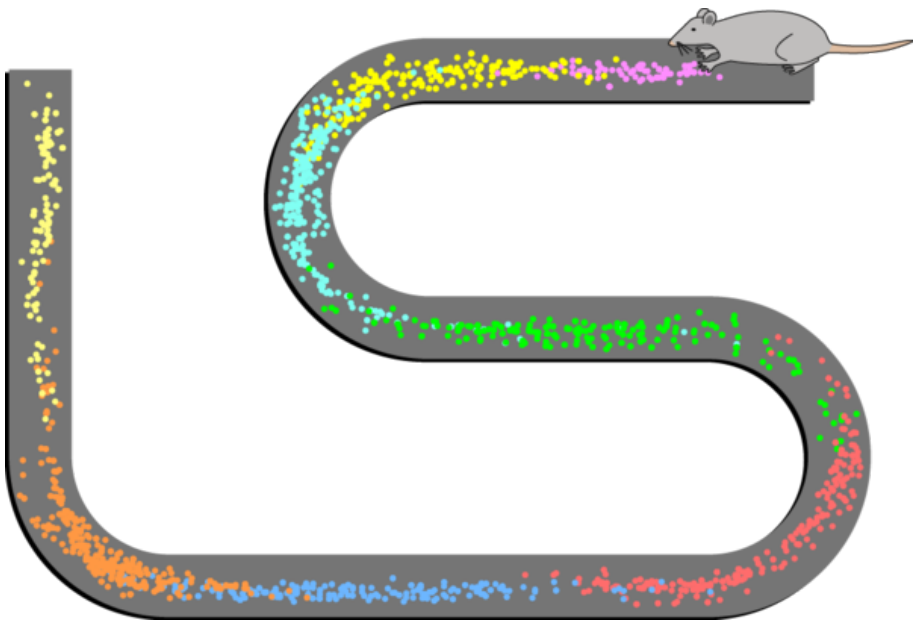

Figure 2: **Place cells**; each dot represents the position of the rat when one of eight different place cells fired a spike, the colours represents a different cell. Figure from `wikipedia`

The cerebellum

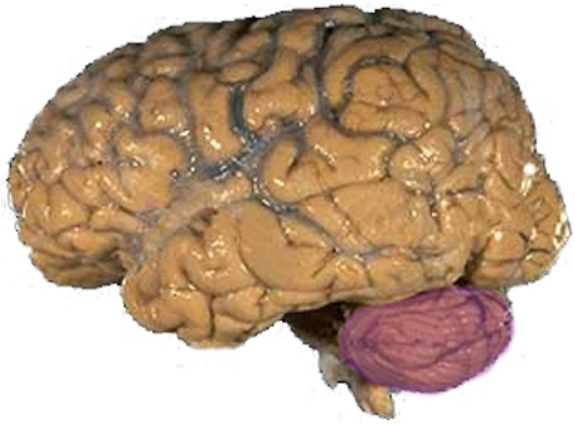

Figure 3: **The cerebellum**; a brain with the cerebellum marked in purple. Figure from the NIH

The **cerebellum**, sometimes called the hindbrain, is at the back of the head, Fig. 3, and has a very distinctive structure which is largely preserved across species. In contains the numerous cells of the brain, the cerebellar granule cell and one of the largest, the Purkinje cell. In order to decide the degree to which different functions are the preserve of different brain areas, the French neuroantatomist Jean Pierre Flourens performed a series of experiments in the early part of the nineteenth century in which he removed the cerebellum from living animals. He discovered that without a cerebellum animals were still able to move, but without their accustomed grace. This is consistent with what is observed for patients with cerebellar damage, see Fig. 4.

These days it is thought that the cerebellum performs very precise predictions in aid of movement control. A challenge in designing a control system is that the motor controls need to be based on a current estimate of position even though that estimate may not be available straight away because of the latency in sensory processing. A potential solution is to use a **forward model** to predict the current position from the available, past, sensory data and one common idea is that this is the role of the cerebellum.

Figure 4: **A woman with cerebellar damage**; this famous drawing from 1912 shows the distinctive gait associated with cerebellar damage, the patient is able to walk, but her walking seems self-conscious and awkward. Figure from `Wikipedia`.

The basal ganglia

The **basal ganglia** are a complicated group of subcortical brain areas thought to act as a gate to decision making and as a centre for processing rewards and their association with actions. One important aspect of the basal ganglia is how they relate to dopamine, one of the neuromodulators; the basal ganglia include the **substantia nigra**, one of the two main areas of the brain where **dopaminergic**, that is dopamine producing, neurons are found. The other area, the **Ventral Tegmental Area (VTA)** produces dopamine in reaction to rewarding events, or perhaps unexpectedly rewarding events; the prompt for release of dopamine by the substantia nigra is harder to summarise, but again, seems to be related to reward and reward-cued behaviours.

Parkinson's disease, a neurodegenerative disorder associated with stiff, even frozen, movements is associates with the loss of cells in the basal ganglia. It is believed that the basal ganglia provides a final 'go' signal allowing motor commands to travel to their muscle target and that with cell loss in the basal ganglia this 'go' signal does not occur. Providing L-**dopa**, a dopamine precursor, can alleviate this difficulty, though, of course, this broad uplift in dopamine is not a complete substitute for the more exquisitely modu-

lated provision of dopamine we can assume is provided by the substantia nigra

Summary

After Henry Moliason had a surgery to remove his hippocampus, it was realised that the hippocampus has an important role in the sort of memory we use to recall where we have left our book or when we agreed to come home; this is also required for forming long-term memory. The hippocampus includes place cells, cells that fire in a particular location, presumably this place memory is a part of and possibly a precursor to a more complicated and abstract memory system. The cerebellum is found at the back of the head and is thought to help the brain control movements, possibly by predicting the consequence of motor commands. The basal ganglia play a role in decision making and Parkinson's disease is associated with loss of neurons in the basal ganglia.